Research Square

Preprints are preliminary reports that have not undergone peer review.
They should not be considered conclusive, used to inform clinical practice,
or referenced by the media as validated information.

Tissue-based detection of macrophage-associated YAP1-positive material in human acute liver injury: an exploratory immunopathological biopsy series

Hiroteru Kamimura

hiroteruk@med.niigata-u.ac.jp

Niigata University

Kenya Kamimura

Niigata University

Shuji Terai

Niigata University

Short Report

Keywords: acute liver injury, CD68, ductular reaction, immunofluorescence, Kupffer cell, liver biopsy, Yes-associated protein 1

Posted Date: June 18th, 2026

DOI: https://doi.org/10.21203/rs.3.rs-9939763/v1

License: This work is licensed under a Creative Commons Attribution 4.0 International License. Read Full License

Additional Declarations: No competing interests reported.

Version of Record: A version of this preprint was published at Diagnostic Pathology on July 16th, 2026. See the published version at https://doi.org/10.1186/s13000-026-01805-8.

Abstract

Background

Yes-associated protein 1 (YAP1), a downstream effector of the Hippo pathway, is implicated in hepatocellular stress, ductular reaction, and tissue repair. Experimental studies suggest that injured YAP1-activated hepatocytes can be cleared by Kupffer-cell phagocytosis, but corresponding evidence in human acute liver injury remains limited.

Methods

We retrospectively analyzed seven adults who underwent clinically indicated liver biopsy within 1 week after the first attack of acute liver injury. Liver biopsy sections were assessed by hematoxylin and eosin staining, periodic acid-Schiff-diastase staining, YAP1 immunohistochemistry, and double immunofluorescence for YAP1 and CD68. Macrophage-associated YAP1-positive structures were defined as YAP1-positive signals located within or immediately adjacent to CD68-positive macrophages in portal or periportal areas. A YAP1/CD68-positive portal-tract index was calculated as the number of macrophage-associated YAP1-positive structures divided by the number of portal tracts examined, multiplied by 100. Associations with peak Model for End-Stage Liver Disease (MELD) score and days to alanine aminotransferase (ALT) normalization were evaluated as exploratory analyses.

Results

The median age was 52 years, and etiologies included autoimmune hepatitis, primary biliary cholangitis-autoimmune hepatitis overlap, drug-induced liver injury, acute hepatitis B, and idiopathic acute liver injury. A median of nine portal tracts and five macrophage-associated YAP1-positive structures were evaluated per biopsy, yielding a median YAP1/CD68-positive portal-tract index of 58.3%. ALT normalized after a median of 26 days. The index showed an inverse correlation with days to ALT normalization (Pearson $r = -0.79$, $p = 0.034$; Spearman rho = -0.86, $p = 0.014$), whereas MELD score was not significantly associated with the index or recovery time. YAP1 immunostaining was observed in ductular reaction and periportal hepatocytes, and double immunofluorescence showed YAP1-positive material spatially associated with CD68-positive macrophages.

Conclusions

Macrophage-associated YAP1-positive material was detectable in early human acute liver injury and may represent an exploratory tissue-based feature reflecting local macrophage-associated handling of injured YAP1-positive cellular material. Larger, etiology-specific studies with standardized biopsy timing, multiplex immunofluorescence, and digital pathology are warranted.

Background

The liver can recover rapidly from acute injury, but biopsy-based features that distinguish effective tissue repair from delayed biochemical recovery remain incompletely defined. The Hippo pathway effector YAP1 regulates organ growth, cell fate, and tissue remodeling, and its activation has been described in hepatocytes, biliary/progenitor-like compartments, and regenerative liver lesions [1–3]. In the setting of injury, YAP1 should therefore be interpreted not merely as a proliferation marker, but as a context-dependent signal linked to cellular stress, plasticity, and repair.

An important experimental observation is that injured YAP1-activated hepatocytes can migrate into sinusoids, undergo apoptosis, and be engulfed by Kupffer cells [4]. This cell-removal mechanism provides a biological rationale for examining whether YAP1-positive cellular material is spatially associated with macrophages in human liver biopsy tissue. However, most human studies have focused on YAP1 expression in epithelial or progenitor-like compartments rather than on macrophage-associated handling of YAP1-positive material.

Ductular reaction is a common histological response to severe hepatobiliary injury. It comprises reactive ductular cells, progenitor-like cells, and hepatocytes undergoing phenotypic plasticity, with accompanying inflammatory and stromal remodeling [5–7]. Depending on the microenvironment, ductular reaction may facilitate epithelial repair, but persistent or excessive ductular reaction is also linked to inflammation, fibrogenesis, and disease progression [6, 7, 12]. Macrophage-epithelial crosstalk is thus likely to be central to the balance between resolution and progression.

We hypothesized that macrophage-associated YAP1-positive material in portal or periportal areas may provide a tissue-level snapshot of local clearance and repair activity in acute liver injury. This exploratory biopsy series examined whether such a feature is detectable in early human acute liver injury and whether it relates to the time required for ALT normalization.

Methods

Study design and patients

This retrospective exploratory biopsy series included seven adult patients who underwent clinically indicated liver biopsy within 1 week after the first attack of acute liver injury at Niigata University. Etiologies were determined from clinical presentation, serological testing, histological findings, medication history, and treatment response. The cohort included drug-induced liver injury, autoimmune hepatitis, primary biliary cholangitis-autoimmune hepatitis overlap, acute hepatitis B, and idiopathic acute liver injury. Peak MELD score during the acute episode was recorded as a systemic severity marker. Biochemical recovery was defined as normalization of serum ALT according to the institutional reference range, and the number of days from onset to ALT normalization was used for analysis. In the two patients with primary biliary cholangitis-autoimmune hepatitis overlap, treatment was selected according to the dominant clinical phenotype and disease activity; both recovered without corticosteroid therapy.

Histology and immunofluorescence

Formalin-fixed, paraffin-embedded liver biopsy sections were evaluated by hematoxylin and eosin staining to assess hepatocellular injury, inflammatory infiltration, and ductular reaction. Periodic acid-Schiff-diastase staining was used to identify macrophages containing engulfed cellular material in portal areas. For immunofluorescence analysis, YAP1 was detected using anti-YAP1 antibody [EP1674Y] (Abcam, ab52771; recombinant rabbit monoclonal), and macrophages were labeled using anti-CD68 antibody [KP1] (Agilent/Dako, M0718; mouse monoclonal). After primary antibody incubation, sections were incubated with goat anti-rabbit IgG conjugated with Cy3 for YAP1 and goat anti-mouse IgG conjugated with FITC for CD68. Nuclei were counterstained with DAPI.

For each biopsy, the number of evaluable portal tracts and the number of macrophage-associated YAP1-positive structures were counted across all evaluable portal tracts. These structures were operationally defined as YAP1-positive signals located within CD68-positive macrophages or immediately adjacent to them in portal or periportal areas on merged images. The definition was intended to capture spatial association consistent with possible engulfment or macrophage-mediated handling of YAP1-positive cellular material; it was not intended to infer molecular co-expression within a single cell or endogenous YAP1 expression by macrophages. A YAP1/CD68-positive portal-tract index was calculated as the number of macrophage-associated YAP1-positive structures divided by the number of portal tracts examined, multiplied by 100.

Statistical analysis

Continuous variables are presented as medians and ranges. Pairwise relationships among the YAP1/CD68-positive portal-tract index, peak MELD score, and days to ALT normalization were evaluated using Pearson correlation coefficients. The 95% confidence intervals for Pearson correlation coefficients were calculated using Fisher's z transformation. Spearman correlation was performed as a sensitivity analysis. Given the small sample size, all analyses were considered exploratory and hypothesis-generating. Two-sided p values < 0.05 were considered statistically significant. Analyses were performed using GraphPad Prism version 9.0 (GraphPad Software, San Diego, CA, USA).

Results

Clinical characteristics

The clinical characteristics are summarized in Table 1. The median age was 52 years (range, 41–61 years), and three patients were male. Etiologies included autoimmune hepatitis in two patients, primary biliary cholangitis-autoimmune hepatitis overlap in two patients, and drug-induced liver injury, acute hepatitis B, and idiopathic acute liver injury in one patient each. All patients recovered after etiology-directed management or observation. The median peak MELD score was 20 (range, 13–23). ALT normalized after a median of 26 days (range, 11–78 days).

Table 1
Clinical characteristics and portal-tract YAP1/CD68 positivity in seven patients with acute liver injury.

Case	Age/Sex	Etiology	Peak MELD	Portal tracts, n	YAP1 + structures, n	YAP1/CD68 index, %	Days to ALT normalization; management/outcome
1	61/M	DILI	14	8	8	100.0	11; medication withdrawal; recovered
2	55/F	AIH	22	12	7	58.3	20; prednisolone; recovered
3	52/F	AIH	20	11	7	63.6	26; prednisolone; recovered
4	48/F	PBC-AIH overlap	13	8	5	62.5	22; ursodeoxycholic acid; recovered
5	50/F	PBC-AIH overlap	15	7	3	42.9	60; ursodeoxycholic acid; recovered
6	52/M	Acute hepatitis B	23	10	4	40.0	78; nucleos(t)ide analogue; recovered
7	41/M	Idiopathic acute liver injury	23	9	5	55.6	31; observation; recovered

Abbreviations: AIH, autoimmune hepatitis; DILI, drug-induced liver injury; F, female; M, male; MELD, Model for End-Stage Liver Disease; PBC, primary biliary cholangitis; YAP1, Yes-associated protein 1.

Histological and immunopathological findings

A median of nine portal tracts per biopsy (range, 7–12) and five macrophage-associated YAP1-positive structures (range, 3–8) were evaluated, yielding a median YAP1/CD68-positive portal-tract index of 58.3% (range, 40.0-100.0%). Biopsy specimens obtained during the acute phase showed periportal hepatocellular injury with inflammatory infiltration and ductular reaction. YAP1 immunohistochemistry demonstrated YAP1 expression in ductular reaction and periportal hepatocytes. Double immunofluorescence showed CD68-positive macrophages in portal/periportal areas and YAP1-positive material within or closely associated with these macrophages (Fig. 1A-F).

Exploratory correlation with biochemical recovery

Correlation analyses are summarized in Table 2. The YAP1/CD68-positive portal-tract index showed an inverse correlation with days to ALT normalization (Pearson r = -0.79, 95% CI -0.97 to -0.09, p = 0.034). This association was directionally consistent in Spearman sensitivity analysis (rho = -0.86, p = 0.014). In contrast, peak MELD score was not significantly associated with the YAP1/CD68-positive portal-tract index (r = -0.47, p = 0.29) or days to ALT normalization (r = 0.31, p = 0.50) (Fig. 1G).

Table 2
Exploratory correlation analysis among disease severity, portal-tract YAP1/CD68 positivity, and ALT normalization.

Variable 1	Variable 2	Pearson r	95% CI for r	p value	Interpretation
MELD score	YAP1/CD68-positive portal-tract index (%)	-0.47	-0.90 to 0.44	0.29	Not significant
MELD score	Days to ALT normalization	0.31	-0.58 to 0.86	0.50	Not significant
YAP1/CD68-positive portal-tract index (%)	Days to ALT normalization	-0.79	-0.97 to -0.09	0.034	Significant inverse correlation

Abbreviations: ALT, alanine aminotransferase; CI, confidence interval; MELD, Model for End-Stage Liver Disease; YAP1, Yes-associated protein 1. P values are two-sided. Spearman sensitivity analysis for the YAP1/CD68-positive portal-tract index and days to ALT normalization: rho = -0.86, p = 0.014.

Discussion

This exploratory human biopsy series suggests that macrophage-associated YAP1-positive material can be detected in portal/periportal areas during early acute liver injury. The principal observation is not YAP1 expression itself, which has already been linked to hepatocellular stress, cell fate regulation, and ductular reaction, but the spatial association of YAP1-positive material with CD68-positive macrophages. This feature may represent a tissue-based immunopathological snapshot of macrophage-associated handling of injured YAP1-positive cellular material during the transition from injury to repair.

The observation is supported by experimental evidence. Yimlamai et al. showed that Hippo pathway activity influences liver cell fate, including hepatocyte and biliary/progenitor-like phenotypes [3]. Miyamura et al. subsequently demonstrated that YAP1 activation in injured mouse hepatocytes promotes selective elimination of these cells, which migrate into sinusoids, undergo apoptosis, and are engulfed by Kupffer cells [4]. These findings provide a mechanistic framework for interpreting YAP1-positive material in association with CD68-positive macrophages in human biopsy tissue. Importantly, acetaminophen-induced liver injury models also suggest that YAP1-related signaling is context dependent: hepatocyte-specific YAP deletion improved recovery in one model, whereas an incremental-dose model identified coordinated pro-regenerative signaling during recovery [9, 10]. Thus, YAP1-positive signals in acute liver injury may mark a dynamic stress-repair compartment rather than uniformly beneficial proliferation.

Ductular reaction and macrophage-epithelial crosstalk provide an additional interpretive framework. The ductular reaction has long been recognized as a structured histological response involving the finer branches of the biliary tree and adjacent parenchymal compartments [5]. Subsequent work has emphasized that ductular reaction may support epithelial repair but also contribute to inflammation, fibrosis, and progression when persistent [6, 7]. Terada et al. reported that Kupffer cells can induce Notch-mediated hepatocyte conversion in an experimental liver disease model [11], and Yang et al. showed that targeting the macrophage Notch1-YAP circuit reprograms macrophage polarization and alleviates acute liver injury in mice [8]. Together,

these studies support a model in which portal macrophages, ductular reaction, and YAP1-positive cellular material are spatially linked in early tissue repair.

From a diagnostic pathology perspective, the present data suggest that macrophage-associated YAP1-positive material may be a candidate tissue-based feature that complements conventional systemic severity indices. MELD score reflects systemic dysfunction, whereas a biopsy-based YAP1/CD68-positive portal-tract index may capture a local clearance or repair process within the injured portal/periportal microenvironment. The finding should not be used for clinical decision-making at present, but it may help formulate testable hypotheses for larger digital pathology studies of acute liver injury.

The study has several limitations. First, the sample size was small and etiologies and treatments were heterogeneous. Second, liver biopsy was performed for clinical indications, and no serial biopsy material was available to assess temporal changes. Third, conventional immunofluorescence without confocal z-stack imaging cannot definitively distinguish true intracellular engulfment from close membrane apposition. Fourth, nuclear versus cytoplasmic YAP1 was not quantified by cell type, and macrophage polarization markers were not included. Finally, interobserver reproducibility and automated digital quantification were not assessed. Therefore, the finding should be interpreted as spatial association consistent with possible macrophage-mediated handling, not as proof of intracellular phagocytosis or macrophage YAP1 expression.

Future studies should validate this observation in larger, etiology-specific cohorts with standardized biopsy timing. Multiplex immunofluorescence incorporating epithelial markers such as cytokeratin 19 and SOX9, apoptosis markers such as cleaved caspase-3 or CK18-M30, and macrophage markers such as CD163, CD206, and inflammatory macrophage markers would clarify the cellular origin and biological meaning of macrophage-associated YAP1-positive material. Digital pathology and spatial transcriptomic approaches may further define the cellular neighborhoods surrounding YAP1-positive cells and CD68-positive macrophages.

Conclusions

Macrophage-associated YAP1-positive material was detectable in portal/periportal areas of early human acute liver injury and was associated with faster ALT normalization in this small exploratory biopsy series. This feature, expressed as a YAP1/CD68-positive portal-tract index, may represent a candidate tissue-based marker of local macrophage-associated clearance or repair activity. Validation in larger and methodologically standardized studies is required before diagnostic or prognostic application.

Abbreviations

AIH
autoimmune hepatitis
ALT
alanine aminotransferase
CD68
cluster of differentiation 68

DAPI
4',6-diamidino-2-phenylindole
DILI
drug-induced liver injury
DR
ductular reaction
FITC
fluorescein isothiocyanate
MELD
Model for End-Stage Liver Disease
PBC
primary biliary cholangitis
YAP1
Yes-associated protein 1.

Declarations

Ethics approval and consent to participate

This study was approved by the Ethics Committee of Niigata University (approval number: 2020 – 0415) and was conducted in accordance with the Declaration of Helsinki. The requirement for written informed consent was waived by the Ethics Committee of Niigata University, and information regarding the study was disclosed through an opt-out procedure.

Consent for publication

Not applicable. No individually identifiable information or images are presented.

Competing interests

The authors declare that they have no competing interests.

Funding

This work was supported by the Japan Society for the Promotion of Science (JSPS) KAKENHI Grant-in-Aid for Research Activity Start-up (Grant Number JP17H06691) to Hiroteru Kamimura.

Author Contribution

HK conceived and designed the study, collected and analyzed the data, interpreted the findings, and drafted the manuscript. KK contributed to interpretation of the histological and immunopathological findings and

critically revised the manuscript. ST supervised the study and critically revised the manuscript. All authors read and approved the final manuscript.

Acknowledgement

The authors thank the technical staff who assisted with tissue processing and immunofluorescence staining.

Availability of data and materials

The datasets used and analyzed during the current study are available from the corresponding author upon reasonable request, subject to institutional and ethical restrictions.

References

1. Johnson R, Halder G. The two faces of Hippo: targeting the Hippo pathway for regenerative medicine and cancer treatment. Nat Rev Drug Discov. 2014;13:63–79.
2. Ye B, Yue M, Chen H, Sun C, Shao Y, Jin Q, et al. YAP/TAZ as master regulators in liver regeneration and disease: insights into mechanisms and therapeutic targets. Mol Biol Rep. 2024;52:78.
3. Yimlamai D, Christodoulou C, Galli GG, Yanger K, Pepe-Mooney B, Gurung B, et al. Hippo pathway activity influences liver cell fate. Cell. 2014;157:1324–38.
4. Miyamura N, Hata S, Itoh T, Tanaka M, Nishio M, Itoh M, et al. YAP determines the cell fate of injured mouse hepatocytes in vivo. Nat Commun. 2017;8:16017.
5. Roskams TA, Theise ND, Balabaud C, Bhagat G, Bhathal PS, Bioulac-Sage P, et al. Nomenclature of the finer branches of the biliary tree: canals, ductules, and ductular reactions in human livers. Hepatology. 2004;39:1739–45.
6. Sato K, Marzioni M, Meng F, Francis H, Glaser S, Alpini G. Ductular reaction in liver diseases: pathological mechanisms and translational significances. Hepatology. 2019;69:420–30.
7. Mavila N, Siraganahalli Eshwaraiah M, Kennedy J. Ductular reactions in liver injury, regeneration, and disease progression-an overview. Cells. 2024;13:579.
8. Yang Y, Ni M, Zong R, Yu M, Sun Y, Li J, et al. Targeting Notch1-YAP circuit reprograms macrophage polarization and alleviates acute liver injury in mice. Cell Mol Gastroenterol Hepatol. 2023;15:1085–104.
9. Poudel S, Cabrera DP, Bhushan B, Manley MW Jr, Gunewardena S, Jaeschke H, Apte U. Hepatocyte-specific deletion of yes-associated protein improves recovery from acetaminophen-induced acute liver injury. Toxicol Sci. 2021;184:276–85.
10. Bhushan B, Walesky C, Manley M, Gallagher T, Borude P, Edwards G, et al. Pro-regenerative signaling after acetaminophen-induced acute liver injury in mice identified using a novel incremental dose model. Am J Pathol. 2014;184:3013–25.
11. Terada M, Horisawa K, Miura S, Takashima Y, Ohkawa Y, Sekiya S, et al. Kupffer cells induce Notch-mediated hepatocyte conversion in a common mouse model of intrahepatic cholangiocarcinoma. Sci Rep. 2016;6:34691.

12. Sorrentino G. Microenvironmental control of the ductular reaction: balancing repair and disease progression. Cell Death Dis. 2025;16:246.

Figures

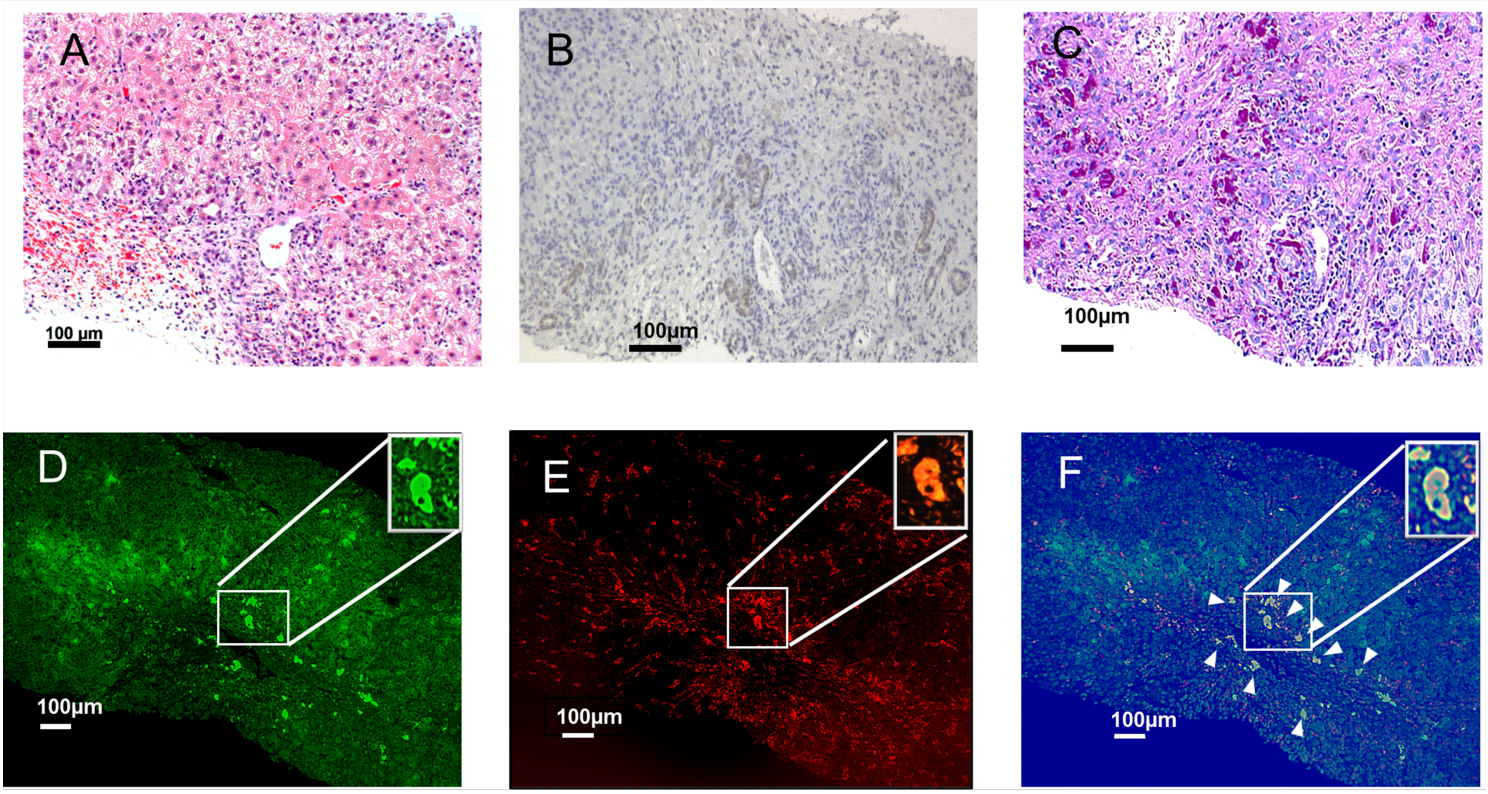

Figure 1

Histological and immunofluorescence findings in acute liver injury.

(A) Hematoxylin and eosin staining showing periportal hepatocellular injury with inflammatory cell infiltration. (B) YAP1 immunohistochemistry showing YAP1 expression in ductular reaction and periportal hepatocytes. (C) Periodic acid-Schiff-diastase staining showing macrophages containing engulfed cellular material in the portal area. (D–F) Double immunofluorescence staining for CD68 and YAP1. CD68-positive macrophages are shown in green (D), YAP1-positive signals in red (E), and the merged image with DAPI nuclear counterstaining in blue (F). YAP1-positive material was observed within or in close association with CD68-positive macrophages. Arrowheads indicate representative macrophage-associated YAP1-positive structures, and the inset shows a high-magnification view of the boxed area. Scale bars, 100 μm.

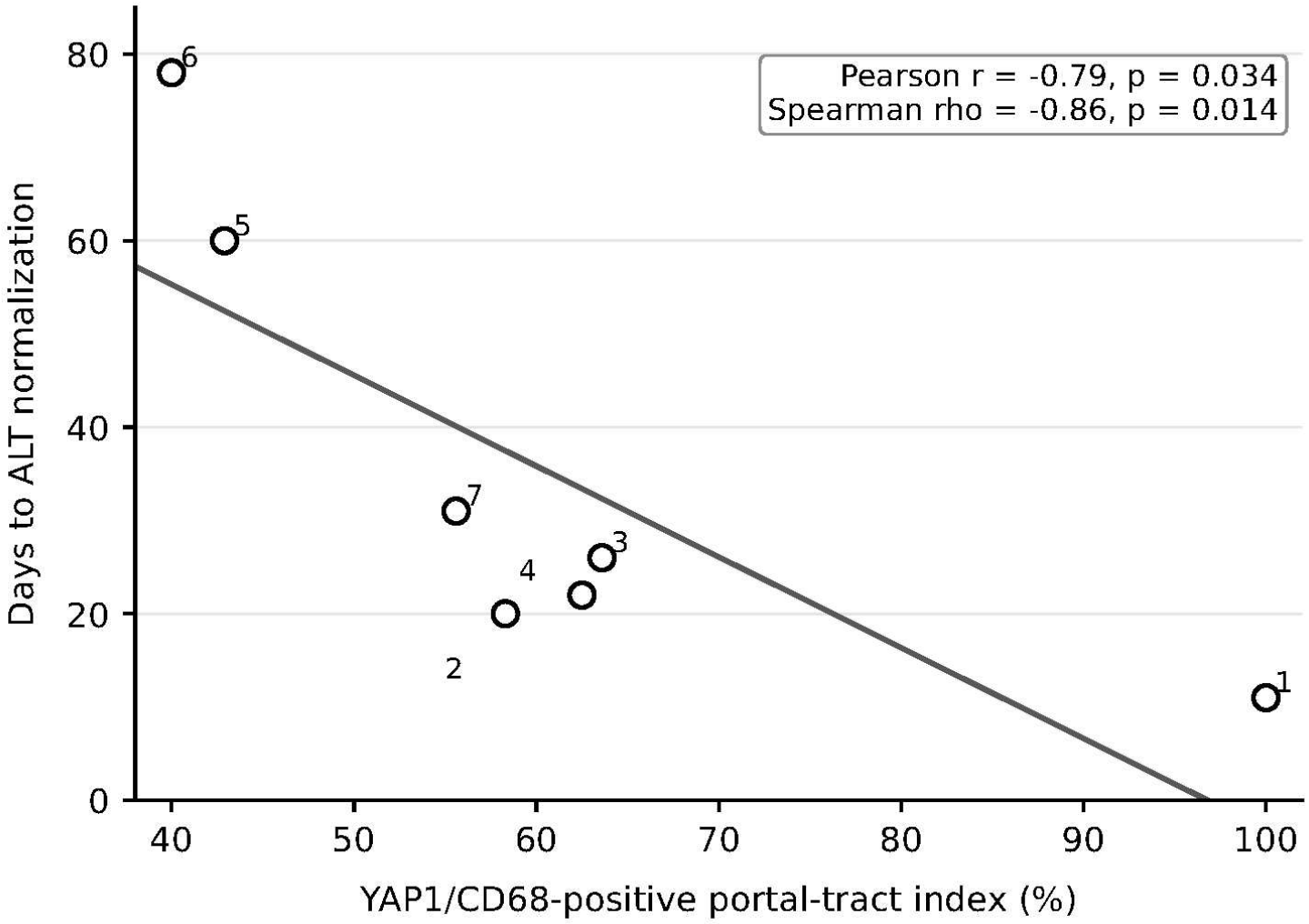

Figure 2

Relationship between the YAP1/CD68-positive portal-tract index and biochemical recovery.

Scatter plot showing the relationship between the YAP1/CD68-positive portal-tract index and days to alanine aminotransferase normalization. The index showed an inverse correlation with days to alanine aminotransferase normalization.