Research Square

Preprints are preliminary reports that have not undergone peer review.
They should not be considered conclusive, used to inform clinical practice,
or referenced by the media as validated information.

Developmental regression, optic neuropathy, retinal dysfunction, and cerebellar structural abnormalities associated with a homozygous FDXR missense variant of uncertain significance: a case report from a consanguineous family

Zaid Ahmad Sami Shbita
Arab American University
Mohammed Jehad Mohammed Dwikat
Arab American University
Issa belal issa salahaldin
Arab American University
Mais Husam Hussain Inirat
Ibn Sina Hospital
Abdallah S. Alem
abdallah.alem@aaup.edu
Arab American University
Ali Shakhshir
Arab American University

Case Report

Keywords: FDXR, ferredoxin reductase, developmental regression, hypotonia, optic atrophy, retinal dysfunction, cerebellar vermis hypoplasia, ataxia, mitochondrial disease, consanguinity

Posted Date: November 26th, 2026

DOI: https://doi.org/10.21203/rs.3.rs-9727801/v1

License: This work is licensed under a Creative Commons Attribution 4.0 International License.
Read Full License

Additional Declarations: No competing interests reported.

Developmental regression, optic neuropathy, retinal dysfunction, and cerebellar structural abnormalities associated with a homozygous FDXR missense variant of uncertain significance: a case report from a consanguineous family

Zaid Ahmad Sami Shbita [1], Mohammed Jehad Mohammed Dwikat [1], Issa belal issa salahaldin [1], Mais Husam Hussain Inirat [2,3], Abdallah S. Alem [4], Ali Shakhshir [4]

[1] Faculty of Medicine, Arab American University, Jenin, Palestine

[2] Department of Pediatrics, Ibn Sina Hospital, Jenin, Palestine.

[3] Department of Pediatrics, Faculty of Medicine, Arab American University, Jenin, Palestine.

[4] Department of Clinical Medicine, Faculty of Medicine, Arab American University, Jenin, Palestine.

Corresponding author: Abdallah S. Alem, MD. Research and Teaching Assistant, Department of Clinical Medicine, Faculty of Medicine, Arab American University, Jenin, Palestine. Email: abdallah.alem@aaup.edu

Abstract

Background: FDXR-related disease is a rare mitochondrial disorder with a broad and evolving neuro-ophthalmic phenotype. Early manifestations can be nonspecific and may precede the later recognition of optic, auditory, cerebellar, and multisystem neurologic involvement.

Case presentation: We report a Palestinian Arab male child born to consanguineous parents who developed febrile neurologic deterioration at 7 months, followed by hypotonia, developmental regression, and persistent motor disability. Initial metabolic, neuroimaging, and electrophysiological investigations were unrevealing; formal audiology at age 15 months showed bilateral normal hearing. Ophthalmic evaluation at approximately 20 months demonstrated optic disc pallor, rod-cone dysfunction, and abnormal visual electrophysiology, with subsequent progression to bilateral optic disc atrophy. Whole-exome sequencing identified a homozygous missense variant in FDXR at Chr17(GRCh37):g.72862311C>T (NM_024417.4:c.449G>A; p.Gly150Asp), with carrier segregation in available relatives. Subsequent whole-genome sequencing did not identify an alternative disease-causing variant; however, the FDXR variant remained formally classified as a variant of uncertain significance pending functional validation. At approximately 8 years of age, he had severe infection-associated decompensation requiring pediatric intensive care; brain MRI showed cerebellar vermis hypoplasia. He remained non-ambulatory with ataxia, limited expressive language, photophobia, and intermittent nystagmus.

Conclusion: This case illustrates the diagnostic odyssey of a probable FDXR-related disorder and highlights the value of longitudinal phenotyping, exome reanalysis, segregation studies, and careful clinicogenetic correlation. FDXR-associated disease should be considered in children with regression or developmental plateau, optic pathway dysfunction, hypotonia, and evolving cerebellar features, even when early hearing studies and early neuroimaging are unrevealing.

Keywords: FDXR, ferredoxin reductase, developmental regression, hypotonia, optic atrophy, retinal dysfunction, cerebellar vermis hypoplasia, ataxia, mitochondrial disease, consanguinity

Introduction

FDXR encodes ferredoxin reductase, a mitochondrial flavoprotein that transfers electrons from NADPH to mitochondrial ferredoxins and is required for iron-sulfur cluster biogenesis, steroidogenic electron transfer, and mitochondrial redox homeostasis [1-4]. Since the first descriptions of biallelic FDXR variants in 2017, the known clinical spectrum has expanded from optic atrophy and auditory neuropathy to a broader multisystem neurodegenerative phenotype that can include developmental delay or regression, hypotonia, ataxia, dystonia, peripheral neuropathy, retinal dystrophy, severe early-onset disease, and stress-related deterioration [1-8].

Recent literature has also emphasized two issues that are highly relevant to case interpretation: first, phenotypic heterogeneity is substantial, and second, acute deterioration after intercurrent infection or other physiologic stress may occur in severe disease [6,9]. Ocular disease extends beyond isolated optic nerve pallor and may include retinal vessel attenuation, retinal dystrophy, abnormal visual electrophysiology, nystagmus, and profound early visual impairment [7].

We report a Palestinian Arab child from a consanguineous family with early febrile neurologic deterioration, persistent hypotonia and ataxia, optic neuropathy with retinal dysfunction, prolonged molecular uncertainty, and later cerebellar structural abnormalities. This case report was prepared in accordance with the CARE (CAse REport) guidelines [10]. It is strengthened by contemporaneous outpatient genetics and ophthalmology records, formal early audiology, source-based hospital notes from a later intensive care admission, and a focused comparison with representative published FDXR-related reports.

Case presentation

The patient is a Palestinian Arab male child born in early 2018 at 37 weeks of gestation by cesarean section for macrosomia (birth weight 4.8 kg). Pregnancy follow-up was routine; the mother had no gestational diabetes or major antenatal complications. The parents are first cousins. He has one older healthy sister and no known family history of a similar neurologic disorder. Early growth in weight and height was described as normal. Developmentally, he achieved head control and cooing at approximately 2 months, rolling and object holding at 4 months, and rolling in both directions by 6 months, but he could not sit unsupported at that age.

According to caregiver history and later genetics summaries, the first major deterioration occurred at about 7 months of age, when he developed fever to 38°C that initially responded to antipyretics and then became less responsive. After an antipyretic injection, he developed upward eye deviation and was admitted locally. Approximately one week later, he became markedly floppy and lost neck control. The family also described repeated admissions around that period for sudden abdominal pain, vomiting, fever, dehydration, and respiratory distress. Ultrasound reportedly showed only a full bladder, urine testing suggested urinary tract infection despite negative urine culture, lumbar puncture and computed tomography were reported as normal, and he was eventually transferred for further evaluation.

A genetics evaluation at 17 months of age documented global developmental delay, hypotonia, and dystonic movements without obvious dysmorphic features. Head circumference was 48 cm. The same report summarized previously unrevealing investigations, including serum amino acids, urine organic acids, cerebrospinal fluid amino acids, lactate, ammonia, prior brain MRI, prior EEG, and vitamin E; the vitamin E value was normal at 29.79 (reference range 11.5-34.5). Chromosomal microarray subsequently showed no pathogenic deletion or duplication.

Formal audiology performed at age 15 months showed bilateral type A tympanograms, normal otoacoustic emissions, and auditory brainstem response wave V detectable at 25 dB bilaterally, with an overall impression of bilateral normal hearing. In contrast, ophthalmic evaluation at approximately 20 months of age documented bilateral temporal pallor of the optic discs, thin retinal vessels, prolonged pattern visual evoked potential implicit time, decreased flash visual evoked responses, and rod-cone dysfunction on electroretinography. Best corrected visual behavior was recorded as central-steady-maintained in both eyes, ocular movements were full, and there were no pigmentary retinal changes reported in that letter.

Whole-exome sequencing and subsequent reanalysis identified a homozygous missense variant in FDXR, later annotated as Chr17(GRCh37):g.72862311C>T; NM_024417.4:c.449G>A; p.Gly150Asp. Segregation was consistent with autosomal recessive inheritance: both parents and the unaffected sister were heterozygous carriers. Additional tested relatives were later reported as either heterozygous carriers or as carrying the wild-type allele, and no additional homozygous individual was reported among tested relatives. Historical records used different variant descriptions, including p.G98D in the initial whole-exome report and c.578G>A; p.Gly193Asp in a subsequent reanalysis note. The later NM_024417.4:c.449G>A; p.Gly150Asp nomenclature is used as the primary annotation in this report because it is the most complete source-record annotation linked to formal variant interpretation. Formal HGVS harmonization confirming equivalence across all historical designations was not available from the source records.

The variant was classified as a variant of uncertain significance under ACMG criteria, supported by absence from gnomAD (PM2) and in-silico pathogenicity prediction by multiple algorithms (PP3), but limited by inconclusive protein modelling, incomplete functional-domain characterization, and absence of functional validation data. Whole-genome sequencing did not

identify another disease-causing single-nucleotide or copy-number variant. The most recent genetics assessment stated that the variant remained classified as VUS, could not be moved to likely pathogenic, and that no definitive diagnosis had been established pending functional studies. The variant is therefore described as a probable but formally unconfirmed cause of the clinical phenotype.

Motor disability remained the dominant long-term problem. Hypotonia reportedly began in the neck and gradually became generalized. Physiotherapy started at 11 months of age and continued longitudinally. He gained the ability to crawl and later creep but never achieved independent walking; balance remained impaired with clear ataxic features. Family history indicated that he could climb onto a chair and open a door independently, hold objects, and attend kindergarten with a dedicated assistant. Expressive language remained limited to short two-word phrases understood mainly by family members. Additional symptoms included intermittent nystagmus, photophobia, hypersensitivity to loud sounds, poor sound orientation, and episodic abnormal events involving left-leg posturing with rightward eye and head deviation.

The hospital notes from a later school-age admission add important objective detail to the phenotype. At age 8 years, he presented after approximately 1 week of vomiting, fever, and progressive hypoactivity, with decreased oral intake, reduced consciousness, abnormal staring episodes, and severe respiratory distress. Examination documented Glasgow Coma Scale 5/15, not alert, eye staring, hypoactivity, decreased bilateral air entry, severe tachypnea with subcostal retractions, and tachycardia around 180 beats per minute. He required pediatric intensive care, intubation, repeated ventilatory escalation, multiple extubation attempts followed by reintubation, and bronchoscopy during a prolonged respiratory course.

The infectious and neurocritical work-up during this admission was complex. The hospital notes documented pneumonia and partially treated meningoencephalitis/meningitis, with cerebrospinal fluid polymerase chain reaction reported as positive for Streptococcus pneumoniae in one progress summary. Blood and urine cultures were repeatedly negative. Broad-spectrum treatment included ceftriaxone, vancomycin, meropenem, acyclovir early in the course, and later piperacillin-tazobactam based on evolving pulmonary findings. Bronchoscopy yielded mucus and neutrophilic exudate, with gram-positive cocci reported from a bronchoscopic culture summary. Neurologic review raised concern for possible focal seizures or acute metabolic decompensation triggered by fever, and levetiracetam loading plus maintenance therapy was used.

Inpatient neurologic testing during this admission refined but did not fully resolve the central nervous system picture. One neurology note described diffuse background slowing with episodic left-sided spikes and concern for focal ictal activity, whereas repeat EEG was later summarized as showing slow background activity with abundant beta activity likely related to sedative drugs and no definitive epileptic activity. A CT head was reported as normal. The official inpatient brain MRI report described no acute intracranial abnormality but noted mega cisterna magna and cerebellar vermis hypoplasia; enlarged adenoids narrowing the postnasal space were also mentioned. Separate review of the supplied T2-weighted images, which were selected for publication, demonstrated a diffuse symmetric cerebellar structural abnormality with vermian involvement and no focal posterior fossa mass. The discrepancy between the formal report terminology and the image-based impression is acknowledged and likely reflects differences in study timing, interpretation, or emphasis.

Additional inpatient consultations further strengthened the multisystem phenotype. Ophthalmology described a case of mitochondrial disorder with bilateral optic disc total atrophy,

absent papilledema, retinal changes, sluggish pupillary responses to light, and need for exposure-keratopathy prevention using artificial tears and lubricant gel. Cardiology evaluated episodes of hypertension and arrhythmia; echocardiography was reported as showing mild left ventricular hypertrophy, and propranolol was used transiently. A mitochondrial-disease consultation recommended supportive mitochondrial therapy including L-carnitine, coenzyme Q10, B-complex, vitamin C, and vitamin E, as well as further audiometry and ophthalmic follow-up. The clinical timeline is summarized in Table 1.

Table 1. Clinical timeline

Date / age	Clinical stage	Key findings	Importance
Birth (2018)	Birth	Male infant born at 37 weeks by cesarean section for macrosomia; birth weight 4.8 kg.	Normal perinatal course
2-6 months	Early development	Head control/cooing by 2 months; rolling and object holding by 4 months; could roll by 6 months but could not sit unsupported.	Retrospective early motor delay
~7 months	Initial deterioration	Febrile illness followed by upward gaze deviation, then marked floppiness and loss of neck control.	Initial neurological regression
Ages 0–12 months	Repeated early admissions	Abdominal pain, vomiting, fever, dehydration, and respiratory symptoms; LP and CT reportedly normal; treated empirically for infection/UTI.	Nondiagnostic early work-up
Age 15 months	Audiology	ABR wave V at 25 dB bilaterally; bilateral type A tympanograms; normal OAE.	Objective hearing study initially normal
Age 17 months	Genetics clinic	Hypotonia, global developmental delay, dystonic movements; metabolic studies, prior MRI/EEG summarized as unrevealing; vitamin E normal.	Established neurodevelopmental phenotype
Age ~19 months	Genetic reanalysis	CMA negative; reanalysis identified candidate FDXR variant.	Shift toward inherited mitochondrial disorder

Date / age	Clinical stage	Key findings	Importance
Age ~20 months	Ophthalmology	Temporal optic disc pallor, thin vessels, prolonged pattern VEP, reduced flash VEP, rod-cone dysfunction on ERG.	Objective neuro-ophthalmic involvement
Ages 20 months–5 years	Molecular follow-up	Segregation supported autosomal recessive inheritance; WGS negative for another clear cause; variant remained classified as VUS ("hot VUS") pending functional validation.	Persistent diagnostic uncertainty
Age ~8 years (later admission MRI)	Brain MRI / image review	Selected T2-weighted images showed symmetric cerebellar structural abnormality with vermian involvement.	Later structural correlate of ataxia
Age 8 years, later admission	PICU decompensation	Vomiting, fever, hypoactivity, decreased consciousness, eye-staring, severe respiratory distress; GCS 5/15; intubation and prolonged PICU course.	Documented severe stress-related decompensation
Same admission	Neuro-ophthalmic update	MRI report: mega cisterna magna and cerebellar vermis hypoplasia; repeat EEG with slowing; ophthalmology documented optic disc total atrophy/retinal changes.	Objective school-age phenotype refinement
Current status (most recent assessment)	Current status	Persistent generalized hypotonia, non-ambulatory ataxia, limited expressive language, photophobia, intermittent nystagmus, school assistant, ongoing rehabilitation.	Chronic disability

Key investigations and inpatient management are summarized in Table 2.

Table 2. Summary of key investigations and inpatient management

Domain	Timing	Findings	Interpretation / manuscript use
Metabolic / biochemical	Before age 17 months	Serum amino acids, urine organic acids, CSF amino acids, lactate, ammonia, and vitamin E were normal; vitamin E 29.79 (11.5-34.5).	Common metabolic disorders excluded; supports primary genetic etiology

Domain	Timing	Findings	Interpretation / manuscript use
Early neuroimaging / EEG	Before age 17 months	Prior brain MRI and EEG summarized as unremarkable in genetics records.	Initial neuroimaging normal; emphasizes diagnostic challenge in early disease
Audiology	Age 15 months	ABR wave V present at 25 dB bilaterally; bilateral type A tympanograms; bilateral normal OAE.	Normal hearing on formal testing at age 15 months; hearing loss may emerge later in disease course
Ophthalmology	Age ~20 months	Temporal optic disc pallor, thin vessels, prolonged pattern VEP, reduced flash VEP, rod-cone dysfunction on ERG.	Objective evidence of early optic neuropathy and retinal dysfunction
Chromosomal microarray	Age ~19 months	No pathogenic deletions or duplications detected.	No pathogenic copy number variant identified; supports single-gene etiology
Genomics	Ages 20 months–5 years	Homozygous FDXR missense variant with segregation in parents/sister; WGS reportedly did not reveal an alternative cause; classification remained VUS (reported as VOUS in source documents).	Molecular data support probable FDXR-related disorder; functional validation pending reclassification
CT head	Age ~8 years (later admission)	No acute intracranial hemorrhage, hydrocephalus, mass effect, or skull fracture; reported normal study.	Acute hemorrhage, hydrocephalus, and mass effect excluded
Inpatient MRI report	Age ~8 years (later admission)	No acute intracranial abnormality; mega cisterna magna; cerebellar vermis hypoplasia; enlarged adenoids narrowing postnasal space.	Official report terminology preserved; both report and image-based descriptions included

Domain	Timing	Findings	Interpretation / manuscript use
MRI – author-provided images	Provided T2 images	Near-midline sagittal and axial T2 images show symmetric cerebellar structural abnormality with vermian involvement and no focal posterior fossa mass.	Symmetric cerebellar structural abnormality with vermian involvement; no focal posterior fossa mass
EEG	Age ~8 years (later admission)	One note raised concern for focal ictal activity; repeat EEG later showed slow background and drug-related beta activity without definitive epileptiform activity.	Inconclusive for definitive epileptic activity; background slowing and drug-related findings predominated
Inpatient ophthalmology	Age ~8 years (later admission)	Bilateral optic disc total atrophy, retinal changes, sluggish pupillary reaction, no papilledema; corneal protection advised.	Documents progressive optic involvement and management implications
Cardiology / echo	Age ~8 years (later admission)	Transient hypertension/arrhythmia; echocardiography reported mild LVH.	Transient systemic involvement during acute decompensation; resolved
PICU management	Age ~8 years (later admission)	Intubation, repeated extubation/reintubation, bronchoscopy, broad-spectrum antimicrobials, levetiracetam, mitochondrial cocktail, rehabilitation planning.	Documents severe stress-related decompensation and multidisciplinary management

Representative T2-weighted MRI images are shown in Figure 1.

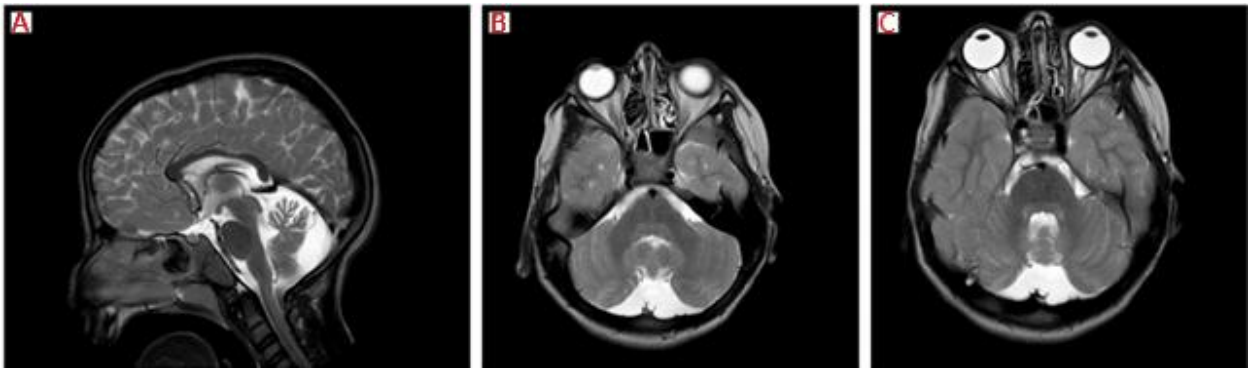

Figure 1. Selected T2-weighted brain MRI images illustrating the cerebellar phenotype. (A) Near-midline sagittal T2-weighted image showing cerebellar structural abnormality with vermian involvement. (B, C) Axial T2-weighted images showing bilateral cerebellar hemispheric involvement without a focal posterior fossa mass or acute intracranial abnormality. The official inpatient radiology report described mega cisterna magna and cerebellar vermis hypoplasia; both the formal report terminology and image-based observations are preserved.

Representative published FDXR-related reports are compared with the present case in Table 3.

Table 3. Focused comparison with representative published FDXR-related reports

Study	Setting / scope	Key phenotype emphasized	How it compares with this case	Why cited
Paul et al., 2017 [1]	Foundational series	Sensorial neuropathies and expansion of FDXR disease beyond isolated optic involvement.	Our patient shares optic involvement and neurologic disability, but had normal early audiology and later cerebellar structural abnormalities.	Foundational description of FDXR disease spectrum.
Peng et al., 2017 [2]	Initial molecular description	Novel mitochondriopathy with optic atrophy.	Our case is concordant in optic phenotype but more clinically complex and longitudinally documented.	Seminal molecular/clinical reference.
Slone et al., 2018 [3]	Case series	Neurodegeneration associated with inflammation; developmental delay, hypotonia, ataxia, stress-related worsening.	Our patient closely resembles this broader inflammatory/neurodevelopmental phenotype, including severe deterioration during intercurrent illness.	Most relevant early spectrum-expanding paper.
Yang et al., 2021 [5]	Single pediatric case	Chinese boy with hearing loss, visual impairment, and motor retardation.	Our case overlaps in motor and visual impairment but differed by normal early formal hearing studies.	Useful pediatric comparator.

Study	Setting / scope	Key phenotype emphasized	How it compares with this case	Why cited
Campbell et al., 2024 [6]	Natural history cohort	Genotype-phenotype correlation; developmental delay, movement disorder, optic atrophy frequent; severe events after infections reported.	Our case fits the severe early-onset/stress-sensitive end of the spectrum.	Best current cohort-level clinical summary.
Kaler and Couser, 2025 [7]	Ocular/neurologic review with case	Retinal dystrophy and wider ocular phenotype emphasized; total reported cases expanded.	Our case strongly aligns because electrophysiology showed rod-cone dysfunction in addition to optic neuropathy.	Best current ocular reference.
Tafakhori et al., 2026 [9]	Twin case report	Post-infectious acute flaccid deterioration broadening phenotype beyond classic optic-auditory pattern.	The patient's school-age PICU decompensation similarly supports infection-triggered worsening in FDXR-related disease.	Most recent acute-decompensation comparator.

Study	Setting / scope	Key phenotype emphasized	How it compares with this case	Why cited
Current case	Single pediatric case from a consanguineous family (this report)	Developmental regression and plateau, hypotonia, ataxia, optic neuropathy with retinal dysfunction, VUS-level FDXR segregation, later severe PICU decompensation, and cerebellar structural abnormality.	Adds a source-rich longitudinal pediatric case with discordance between early normal hearing studies and later severe neuro-ophthalmic disease.	Provides source-rich longitudinal documentation with early normal hearing, severe neuro-ophthalmic involvement, documented cerebellar imaging abnormalities, and infection-associated PICU-level decompensation.

Discussion

This report is strengthened by the convergence of four separate evidence streams: longitudinal caregiver history, formal outpatient genetics and ophthalmology records, early objective audiology, and later hospital-source documentation from an intensive care admission. Taken together, these data support a probable FDXR-related disorder with early regression or developmental plateau, optic neuropathy with retinal dysfunction, persistent motor impairment, and later cerebellar structural abnormalities. The phenotype is highly concordant with the expanded FDXR literature, particularly the broader neurodevelopmental and stress-sensitive spectrum described after the earliest 2017 reports [1-3,6-9].

One of the most instructive aspects of this case is the diagnostic delay. Early lumbar puncture, computed tomography, EEG, and MRI were reported as unremarkable, and the first exome readout did not yield a definitive diagnosis. Published FDXR cohorts show that early studies may be nondiagnostic and that phenotypic evolution over time is common [3,6]. This is clinically

important because children with FDXR-related disease may initially resemble more common infectious, metabolic, or nonspecific developmental disorders.

The ophthalmic phenotype is a particular strength of this report. The outpatient letter documented bilateral temporal optic disc pallor, prolonged pattern VEP, decreased flash VEP, and rod-cone dysfunction on ERG. Later inpatient ophthalmology review described bilateral optic disc total atrophy and retinal changes. This aligns closely with recent work emphasizing that FDXR-related ocular disease is broader than isolated optic atrophy and may include retinal dystrophy, retinal vessel attenuation, nystagmus, and severe early visual dysfunction [7]. The coexistence of optic neuropathy and retinal dysfunction makes this case especially valuable for the neuro-ophthalmic literature.

The auditory phenotype is more nuanced. Formal ABR, tympanometry, and otoacoustic emissions were normal at age 15 months, and consultant correspondence later still noted normal hearing tests despite strong molecular suspicion. This is important because many clinicians still associate FDXR mainly with auditory neuropathy and optic atrophy. Our case supports the more contemporary view that organ-system involvement may evolve asynchronously and that a normal early hearing assessment does not exclude FDXR-related disease [1,6].

The school-age hospital admission is clinically informative and documents the severity of disease progression. The child developed encephalopathy, abnormal staring episodes, severe respiratory distress, and prolonged PICU dependence with repeated ventilatory failure. Similar stress-sensitive deterioration after infection has been emphasized in recent cohort and case literature [6,9]. However, the admission should not be interpreted as proof that every acute manifestation was directly genetic in origin. The hospital course is better understood as severe intercurrent infectious

illness and meningoencephalitic/pneumonic decompensation occurring on the background of a vulnerable FDXR-related neurodevelopmental disorder.

The imaging section requires careful wording. The official inpatient MRI report described mega cisterna magna and cerebellar vermis hypoplasia without acute intracranial abnormality, whereas the selected T2-weighted images visually suggest a symmetric cerebellar structural abnormality with vermian involvement. Because the official report and image-based impression are not phrased identically, we preserve both observations rather than collapsing them into a single label, acknowledging that terminology such as hypoplasia, atrophy, or volume loss may vary across study timing and interpreters.

The molecular interpretation warrants careful framing. The homozygous FDXR missense variant at Chr17(GRCh37):g.72862311C>T is supported by a strongly concordant clinical phenotype, consistent autosomal recessive segregation in available family members, absence from population variant databases, in-silico pathogenicity prediction, and negative whole-genome sequencing for an alternative cause. Despite this convergent evidence, consultant correspondence repeatedly and explicitly maintained a VUS classification, and the January 2023 assessment stated that the variant could not be moved to likely pathogenic and that there was no definitive diagnosis pending functional studies. This distinction matters: the phenotypic and segregation data make FDXR the most plausible explanation, but the absence of functional validation means that a pathogenic or likely pathogenic classification is not scientifically justified at the time of this report. Published work has demonstrated that functional studies are critical for reclassifying FDXR missense variants, and that in-vitro evidence can successfully move a variant from VUS to likely pathogenic or pathogenic status [4]. The variant is therefore described throughout this report as a probable but

formally unconfirmed cause, and the case is presented as a probable FDXR-related disorder rather than a genetically confirmed diagnosis.

This report has several limitations. Some of the early infantile events were reconstructed from caregiver history and secondary summaries rather than complete contemporaneous charts. The later hospital note set was rich but partly duplicative and image-based, and not every microbiologic or neurophysiologic detail could be independently source-verified across all pages. Adrenal function was not systematically assessed, which is relevant because adrenal insufficiency has recently been reported within the broader FDXR-related spectrum [8]. The primary molecular limitation is that the FDXR variant remained formally classified as a variant of uncertain significance at the most recent assessment, despite supportive phenotype, segregation, absence from population databases, in-silico support, and negative whole-genome sequencing for an alternative cause. Functional validation studies had not been completed within the period covered by this report, and no definitive molecular diagnosis was established. A further technical limitation is that historical source documents used different protein-level designations for the candidate variant; formal HGVS harmonization confirming equivalence across all designations was not available, and final confirmation from the reporting laboratory would strengthen the molecular interpretation. These limitations are balanced by the unusual depth of longitudinal phenotyping, objective neuro-ophthalmic testing, segregating molecular data, and documented later critical illness.

Conclusion

Children with regression or developmental plateau, hypotonia, optic pathway dysfunction, and evolving cerebellar features should prompt consideration of FDXR-associated disease even when early metabolic studies, early MRI, or early formal hearing tests are unrevealing. This case contributes additional evidence that FDXR-related disease may remain molecularly unresolved for

years, may exhibit strong ocular but initially limited auditory findings, and may deteriorate severely during intercurrent infection or physiologic stress.

Abbreviations

ABR, auditory brainstem response
CMA, chromosomal microarray
CSF, cerebrospinal fluid
CT, computed tomography
EEG, electroencephalography
ERG, electroretinography
FDXR, ferredoxin reductase
Fe-S, iron-sulfur
LP, lumbar puncture
LVH, left ventricular hypertrophy
MRI, magnetic resonance imaging
NADPH, nicotinamide adenine dinucleotide phosphate
OAE, otoacoustic emissions
PCR, polymerase chain reaction
PICU, pediatric intensive care unit
VEP, visual evoked potential
VUS, variant of uncertain significance (reported in some source documents as VOUS)

WES, whole-exome sequencing
WGS, whole-genome sequencing

Declarations

Ethics approval and consent to participate

Ethical approval was not required for this single case report as no experimental interventions were performed. Applicable institutional or national guidelines were followed.

Consent for publication

Written informed consent for publication of the patient's clinical details and radiological images was obtained from the patient's parent/legal guardian. A copy of the consent form is available for review by the Editor-in-Chief on request.

Availability of data and materials

All data summarized in this report are contained within the manuscript. Additional source records are available from the corresponding author on reasonable request, subject to privacy restrictions.

Competing interests

The authors declare that they have no competing interests.

Funding

No specific funding was received for preparation of this case report.

Authors' contributions

ZASS: literature review, data collection, manuscript drafting. MJMD: literature review, data collection, manuscript drafting. IBIS: literature review, data collection, manuscript drafting. MHHI: clinical data acquisition, clinical interpretation, and critical revision of the manuscript. ASA: conceptualization, case supervision, genetic/clinical interpretation, manuscript drafting, and critical revision. AS: conceptualization, supervision, manuscript editing, and critical revision. All authors read and approved the final manuscript and agree to be accountable for its content.

Acknowledgements: The authors thank the patient and his family for their consent to the publication of this case.

References

1. Paul A, Drecourt A, Petit F, Deguine DD, Vasnier C, Oufadem M, et al. FDXR mutations cause sensorial neuropathies and expand the spectrum of mitochondrial Fe-S-synthesis diseases. Am J Hum Genet. 2017;101(4):630-637. doi:10.1016/j.ajhg.2017.09.007.
2. Peng Y, Shinde DN, Valencia CA, Mo JS, Rosenfeld J, Truitt Cho M, et al. Biallelic mutations in the ferredoxin reductase gene cause novel mitochondriopathy with optic atrophy. Hum Mol Genet. 2017;26(24):4937-4950. doi:10.1093/hmg/ddx377.
3. Slone J, Peng Y, Yang L, Valle D, Queme L, Zurakowski D, et al. Biallelic mutations in FDXR cause neurodegeneration associated with inflammation. J Hum Genet. 2018;63(12):1211-1222. doi:10.1038/s10038-018-0515-y.

4. Stenton SL, Piekutowska-Abramczuk D, Kulterer L, Kopajtich R, Claeys KG, Ciara E, et al. Expanding the clinical and genetic spectrum of FDXR deficiency by functional validation of variants of uncertain significance. Hum Mutat. 2021;42(3):310-319. doi:10.1002/humu.24160.

5. Yang C, Zhao X, Zhang Y, et al. Report of a case with ferredoxin reductase (FDXR) gene variants in a Chinese boy exhibiting hearing loss, visual impairment, and motor retardation. Int J Dev Neurosci. 2021;81(4):364-369. doi:10.1002/jdn.10104.

6. Campbell T, Slone J, Metzger H, Liu W, Sacharow S, Yang A, et al. Clinical study of ferredoxin-reductase-related mitochondriopathy: genotype-phenotype correlation and proposal of ancestry-based carrier screening in the Mexican population. Genet Med Open. 2024;2:100841. doi:10.1016/j.gimo.2023.100841.

7. Kaler A, Couser NL. Ocular and neurological manifestations of the FDXR-related disorder. J AAPOS. 2025;29(1):104102. doi:10.1016/j.jaapos.2024.104102.

8. Pignatti E, Fluck CE, Miller WL, et al. FDXR variants cause adrenal insufficiency and atypical sexual development. JCI Insight. 2024;9(14):e179071. doi:10.1172/jci.insight.179071.

9. Tafakhori A, Sarvestani Z, Kariminejad A, Tajsharghi H, Seo GH, Ryu SW, et al. Homozygous FDXR variant in twin sisters with spastic paraparesis followed by acute progressive flaccid quadriparesis. BMC Neurol. 2026;26:202. doi:10.1186/s12883-026-04752-5.

10. Gagnier JJ, Kienle G, Altman DG, Moher D, Sox H, Riley D; CARE Group. The CARE guidelines: consensus-based clinical case reporting guideline development. BMJ Case Rep. 2013;2013:bcr2013201554. doi:10.1136/bcr-2013-201554.