Research Square

Preprints are preliminary reports that have not undergone peer review. They should not be considered conclusive, used to inform clinical practice, or referenced by the media as validated information.

Aconitine accidental poisoning: two case reports and literature review

Qian Zhao
The First Affiliated Hospital (Southwest Hospital) of Army Medical University, Third Military Medical University)

Lei Wang
The First Affiliated Hospital (Southwest Hospital) of Army Medical University, Third Military Medical University)

Feng Zeng
The First Affiliated Hospital (Southwest Hospital) of Army Medical University, Third Military Medical University)

Xue-bo Jiang
The First Affiliated Hospital (Southwest Hospital) of Army Medical University, Third Military Medical University)

Yan-xia Shao
shaoyanxia@tmmu.edu.cn

The First Affiliated Hospital (Southwest Hospital) of Army Medical University, Third Military Medical University)

Case Report

Keywords: Chinese Herbal Medicine, Aconitine Poisoning, Arrhythmia, Hemoperfusion, Treatment

Posted Date: July 3rd, 2026

DOI: https://doi.org/10.21203/rs.3.rs-9714955/v1

License: This work is licensed under a Creative Commons Attribution 4.0 International License. Read Full License

Additional Declarations: No competing interests reported.

Abstract

Chinese Herbal Medicine (CHM) is widely integrated into clinical practice across Asia and other regions for disease treatment and health maintenance. Aconitine, a potent diterpenoid alkaloid derived from plants of the Aconitum genus (e.g., *Aconitum carmichaelii* and *Aconitum kusnezoffii*), exhibits significant pharmacological activity but also considerable toxicity. While properly processed Aconitum herbs are prescribed for their analgesic and anti-rheumatic properties, inadequate detoxification during processing or improper clinical use can lead to accidental aconitine poisoning. This condition characterized by severe cardiotoxicity and neurotoxicity, which may progress to fatal outcomes. Recently, with the expanding clinical application of traditional medicines globally, the incidence of aconitine poisoning has risen, particularly in Asian populations.

Case presentation:

We present two cases of aconitine poisoning in middle-aged patients following ingestion of herbal preparations containing aconitine. Both patients developed significant cardiac arrhythmias of varying severity. Clinical management included gastric lavage, catharsis induced by mannitol, gastric mucosal protection, intravenous fluid resuscitation, and hemoperfusion. One patient experienced cardiac arrest and subsequently died after family members elected to withdraw life-sustaining therapy. The second patient was successfully weaned from mechanical ventilation and was eventually discharged following a short-term hospitalization.

Conclusion:

These cases underscore the critical need to enhance awareness among healthcare professionals and the public regarding the risks associated with certain Chinese herbal medicines, particularly those containing aconitine. Strengthened vigilance and the promotion of their rational use are essential for improving public health literacy and preventing similar adverse events.

Background

Chinese Herbal Medicine (CHM), with a history of thousands of years in China and many Asian countries, serves as an integral component of traditional medical practice and is widely employed in disease prevention and treatment [1]. Despite its conventional perception as being “natural and safe”, accumulating clinical evidence indicates that inappropriate use may result in toxic exposure, leading to severe hepatic, renal, and neurological damage, sometimes with fatal outcomes [2–3]. Among CHM-related toxicities, aconitine poisoning stands as one of the most prevalent in Asia However, its diagnosis remains challenging due to the complexity and nonspecificity of clinical presentations, which may encompass life-threatening cardiac arrhythmias, gastrointestinal disturbances, and diverse neurological symptoms [3]. In recent years, alongside the global expansion of traditional medicine, the incidence of aconitine poisoning has shown an increasing trend, underscoring the need for enhanced clinical awareness and diagnostic competence [4–5]. This article reports two cases of aconitine poisoning and

provides a systematic analysis of CHM-related toxicity cases, aiming to offer a comprehensive clinical reference for diagnosis and management, as well as improving public awareness regarding the safe use of CHM.

Case presentation

Case 1

A 61-year-old female ingested an herbal preparation containing *Aconitum carmichaelii* and *Aconitum kusnezoffii* on two occasions (at 13:00 and 19:00; exact doses unknown) on September 9, 2023. Approximately two hours after the second ingestion, at 21:00,, she developed dizziness, vomiting, palpitations, perioral and limb numbness, and generalized weakness. She was initially evaluated at a local traditional Chinese medicine hospital, where an electrocardiogram (ECG) showed atrial fibrillation with third-degree atrioventricular block. She was then transferred via emergency medical services to our department for further management, arriving at 04:37 the next day.

Physical examination on admission noted: body temperature, 36.5°C; heart rate, 21 bpm; respiratory rate, 13 breaths/min; blood pressure, 76/36 mmHg, the patient was conscious but in apparent distress, with cold, clammy skin. Peripheral pulses were irregular and thready. Cardiac auscultation revealed an irregular rhythm with variable intensity of the first heart sound. A repeat ECG confirmed atrial fibrillation with ST-T segment changes and left axis deviation (Fig. 1A). Arterial blood gas analysis showed hyperkalemia and elevated lactate levels. Complete blood count, myocardial enzyme profiles, coagulation studies, and hepatic and renal function tests were within normal limits (Table 1).

Following a diagnosis of aconitine poisoning, the patient underwent continuous ECG monitoring and received a series of detoxification measures, including gastric lavage, activated charcoal adsorption, and catharsis with mannitol. Supportive management included oxygen inhalation, intravenous fluid resuscitation, and anti-shock therapy, as well as potassium-lowering and diuretic agents. Atropine was administered for bradyarrhythmia. Hemoperfusion was initiated at 06:40. At 09:28, the patient developed recurrent bradycardia (HR 48 bpm), which was managed with additional atropine and isoproterenol infusion. By 13:04, the ECG showed atrial fibrillation (Fig. 1B), which was further confirmed with an 18-lead ECG at 13:15, demonstrating concomitant ST-T changes (Fig. 1A); fFollow-up laboratory evaluations were performed.

At 14:02, the patient reported palpitations with a heart rate of 181 bpm and blood pressure of 154/86 mmHg. ECG revealed ventricular tachycardia (Fig. 1C), prompting immediate intravenous administration of lidocaine. At 14:04, she experienced a sudden loss of consciousness with absence of palpable central pulses. Cardiopulmonary resuscitation was commenced, including intravenous epinephrine and continuous chest compressions. Concurrent arterial blood gas analysis and other laboratory assessments were performed, and veno-arterial extracorporeal membrane oxygenation (VA-ECMO) was proposed as a rescue intervention. However, the family declined ECMO support for personal reasons. By

15:00, there was no return of spontaneous circulation, central pulses remained absent, and pupils were fixed and dilated with no light reflex. ECG demonstrated asystole, and the patient was declared clinically deceased.

Case 2

A 56-year-old male presented to the emergency department of our hospital at 21:00 on October 26, 2024, approximately two hours after ingesting wine prepared from unprocessed *Aconitum kusnezoffii*. Shortly after consumption, he developed neuropsychiatric symptoms, which progressed to gradual impairment of consciousness. An admission ECG revealed sinus tachycardia, frequent premature ventricular contractions, first-degree atrioventricular block, and ST-T segment abnormalities (Fig. 2A). Arterial blood gas analysis demonstrated hypercapnia and elevated lactate levels. While complete blood count, myocardial enzyme profiles, and coagulation parameters were within normal limits, hepatic and renal function tests showed mild abnormalities (Table 2).

A preliminary diagnosis of aconitine poisoning was established. The patient underwent emergent gastric lavage and endotracheal intubation for airway protection before being transferred to the emergency intensive care unit (EICU). His medical history was significant for hypertension, with previously recorded blood pressures up to 180/110 mmHg.

In the EICU, his course was complicated by recurrent ventricular arrhythmias. At 00:25 on October 27, continuous monitoring showed frequent PVCs with brief runs of ventricular tachycardia, managed with esmolol. At 00:50, he developed torsades de pointes (TdP) triggered by a PVC, which required immediate electrical defibrillation and intravenous magnesium sulfate, resulting in the restoration of sinus rhythm.. Potassium and magnesium were supplemented for membrane stabilization.. By 01:45, his heart rate increased to 150–180 bpm, with ECG confirming paroxysmal ventricular tachycardia (Fig. 2B). A cardiology consultation recommended aggressive detoxification, correction of ischemia and hypoxia, continued membrane stabilization, and consideration of electrical cardioversion or lidocaine infusion if warranted.

The patient's treatment regimen included continued catharsis, activated charcoal, intravenous fluids, electrolyte repletion, and hemoperfusion. His vital signs, fluid balance, serial ECGs, and laboratory parameters were closely monitored (Fig. 2C). By hospital day 3, the patient’s condition markedly improved with stabilization of vital signs. Successful extubation was performed. On day 4, repeat complete blood count, hepatic and renal function, and coagulation profiles returned to normal ranges. The patient was discharged on day 5. Subsequent follow-up indicated complete recovery and return to normal activities.

Discussion

CHM constitutes a major component of traditional medical systems, valued for its natural origins and role in low-cost primary care, particularly in China and across Asia [1, 6–7]. Aconitine, a highly toxic diterpenoid alkaloid present in botanicals such as *Aconitum carmichaelii*, *Aconitum kusnezoffii*, and *Aconitum carmichaelii* var. *edwardsii*, is utilized in traditional practice for therapeutic and preventive purposes following appropriate detoxification processing [3–5]. However, its narrow therapeutic index means that improper preparation, such as ingesting raw materials or inadequate decoction, readily leads to accidental poisoning. After gastrointestinal absorption and hepatic/renal metabolism, initial symptoms of intoxication typically include dizziness, perioral and extremity numbness, nausea, vomiting, and palpitations [7–8]. Severe poisoning can progress to impaired consciousness, life-threatening arrhythmias (including ventricular tachycardia, atrial fibrillation, and torsades de pointes), and multiorgan failure [9–10], with fatalities reported following ingestion of as little as 1 mg of pure aconitine [11–12]. This report illustrates these challenges through two cases of aconitine poisoning resulting from inappropriate use of CHM preparations, underscoring both the clinical manifestations and therapeutic strategies in managing such intoxications.

In our report, both patients developed refractory arrhythmias after ingesting Chuanwu, an herbal medicine containing aconitine. The first patient presented with severe shock and significant arrhythmias upon admission to our hospital. Management included continuous electrocardiographic monitoring, gastric lavage, anti-shock therapy, intravenous fluid resuscitation, diuresis, and therapeutic plasma exchange. Despite these interventions, the patient's condition deteriorated progressively, culminating in cardiac arrest. Cardiopulmonary resuscitation was initiated per protocol, and veno-arterial extracorporeal membrane oxygenation (VA-ECMO) was discussed as a rescue therapy. However, the family declined ECMO support for personal reasons. The patient ultimately succumbed to the poisoning. In contrast, the second patient initially exhibited prominent neurological symptoms. Following emergency gastric lavage and endotracheal intubation for airway protection, the patient was transferred to the intensive care unit, where recurrent arrhythmias were observed and managed with intravenous fluid support, hemoperfusion, antiarrhythmic drugs, and myocardial membrane stabilization. This patient was successfully weaned from mechanical ventilation and was eventually discharged in recovered condition.

Clinical case analyses indicate that the half-life of aconitine in humans is approximately 3 hours, making the first few hours post-exposure the critical window for clinical intervention [13]. Aconitine-induced cardiotoxicity has been widely documented. Pharmacokinetic studies demonstrate significantly higher concentrations of aconitine in cardiac tissue compared to peripheral blood, which is considered a primary factor in its high mortality rate [3–5, 9–12, 14]. The molecular mechanisms underlying this cardiotoxicity remain incompletely understood but are thought to involve interactions with myocardial ion channels (especially sodium channels), induction of cytotoxic injury, and alterations in epigenetic and transcriptional regulation [5, 7, 9–10]. To date, no specific antidote for aconitine poisoning is available worldwide. Traditional detoxification methods rely on physical and chemical processing of herbal material (e.g., soaking, boiling, drying, steaming) to reduce toxicity, while contemporary clinical management focuses on gastrointestinal decontamination (catharsis, activated charcoal),

extracorporeal elimination (hemoperfusion), antiarrhythmic agents (e.g., amiodarone, procainamide, mexiletine), and advanced life support, including ECMO.

Conclusion

Aconitine poisoning represents a potentially life-threatening clinical emergency. When the etiology of intoxication is unclear, diagnosis can be challenging, a detailed medication and exposure history is therefore essential. Early initiation of gastrointestinal decontamination, arrhythmia management, and extracorporeal detoxification—guided by swift clinical recognition—can significantly improve outcomes. Equally important are public health initiatives aimed at raising awareness about the risks of improperly prepared herbal medicines to prevent such poisoning incidents.

Declarations

Ethics approval and consent to participate

The study has been approved by the Committee of Research Ethics of Southwest Hospital.

Author 1-Conceptualization, Writing-original draft

Author 2-Data curation,Methodology

Author 3-Formal analysis

Author 4-Supervision and Project administration

Author 5-Funding acquisition,Writing-review & editing

Consent for publication

Written informed consent for publication of the clinical details were obtained from the relative of the patient

Competing interests

The authors declare that they have no competing interests.

Availability of data and materials

The datasets used and/or analyzed during the current study are available from the corresponding author on reasonable request.

Funding

No.

Authors' contributions

All authors made a significant contribution to the work reported, whether that is in the conception, study design, execution, acquisition of data, analysis and interpretation, or in all these areas; took part in drafting, revising or critically reviewing the article; gave final approval of the version to be published; have agreed on the journal to which the article has been submitted; and agree to be accountable for all aspects of the work.

References

1. Rolf T, Dominique L, Dieter M et al. Traditional Chinese Medicine (TCM) and Herbal Hepatotoxicity: RUCAM and the Role of Novel Diagnostic Biomarkers Such as MicroRNAs[J].Medicines, 2016, (3):18.10.3390/medicines3030018
2. Yang X-X, Duan Z-PHW, Zhu Y-Z. Shu-Feng Zhou.Drug-herb interactions: eliminating toxicity with hard drug design.[J]. Curr Pharm Design. 2006;12(35):–. 10.2174/138161206779010440.
3. Chan TY. K.Incidence of herb-induced aconitine poisoning in Hong Kong: impact of publicity measures to promote awareness among the herbalists and the public.[J].Drug Safety, 2002, 25(11):823–8.10.2165/00002018-200225110-00006
4. Daniel E. Rusyniak.Goldfrank's toxicologic emergencies /[J].Jama the. JAMA. 2007;297(8):893. 10.1001/jama.297.8.894.
5. Chan TY. K.Aconitine poisoning: a global perspective[J]. Vet Hum Toxicol. 1994;36(4):326–8.
6. Huang Z, Shi X, Nicholas S et al. Use of Traditional Chinese Medicine and Its Impact on Medical Cost among Urban Ischemic Stroke Inpatients in China: A National Cross-Sectional Study.[J].Hindawi Limited, 2021.10.1155/2021/8554829
7. Liao YP, Shen LH, Cai LH, et al. Acute myocardial necrosis caused by aconitine poisoning:A case report[J]. World J Clin cases. 2022;10(33):6. 10.12998/wjcc.v10.i33.12416.
8. Nicoleta Anca, Paunescu A, Topala C et al. Aconitine in Synergistic, Additive and Antagonistic Approaches[J].toxins, 2024, 16(11).10.3390/toxins16110460
9. Xueyan,Chen. Huicai,Protective effect of berberine on aconite?induced myocardial injury and the associated mechanisms.[J].Molecular Medicine Reports, 2018.10.3892/mmr.2018.9476
10. Cheng F, Hao LI, Liu MW. Clinical effect of a temporary pacemaker on an electrical storm induced by severe acute aconitine poisoning[J]. World Acad Sci J. 2022;4(1). 10.3892/wasj.2022.142.
11. A F V, B M G. A A N, et al.Intentional ingestion of aconite: Two cases of suicide - ScienceDirect[J]. Forensic Sci International: Rep. 2020. 10.1016/j.fsir.2020.100158.
12. Lin CC, Chan TY, Deng JF. Clinical features and management of herb-induced aconitine poisoning. Ann Emerg Med. 2004;43(5):574–9. 10.1016/j.annemergmed.2003.10.046.
13. Moritz F, Compagnon P, Kaliszczak IG et al. Severe Acute Poisoning with Homemade Aconitum napellus Capsules: Toxicokinetic and Clinical Data[J].Clinical Toxicology, 2009, 43(7):873–6.10.1080/15563650500357594

14. Bicker W, Monticelli F, Bauer A, et al. Quantification of aconitine in post-mortem specimens by validated liquid chromatography-tandem mass spectrometry method: Three case reports on fatal 'monkshood' poisoning[J]. Drug Test Anal. 2013;5:9–10. 10.1002/dta.1501.

Tables

Tables are available in the Supplementary Files section.

Figures

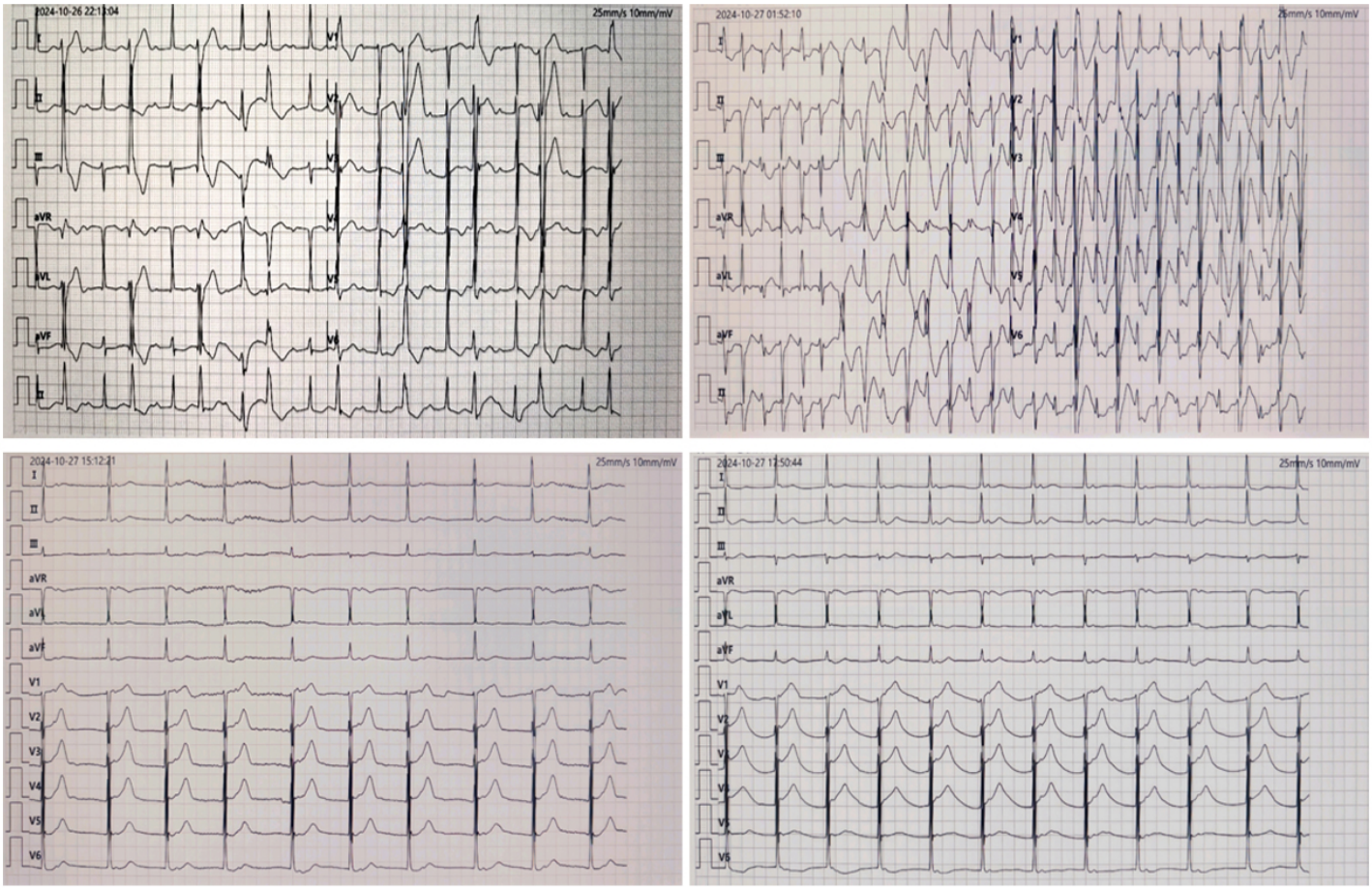

Figure 1

The changes in the electrocardiogram of patient

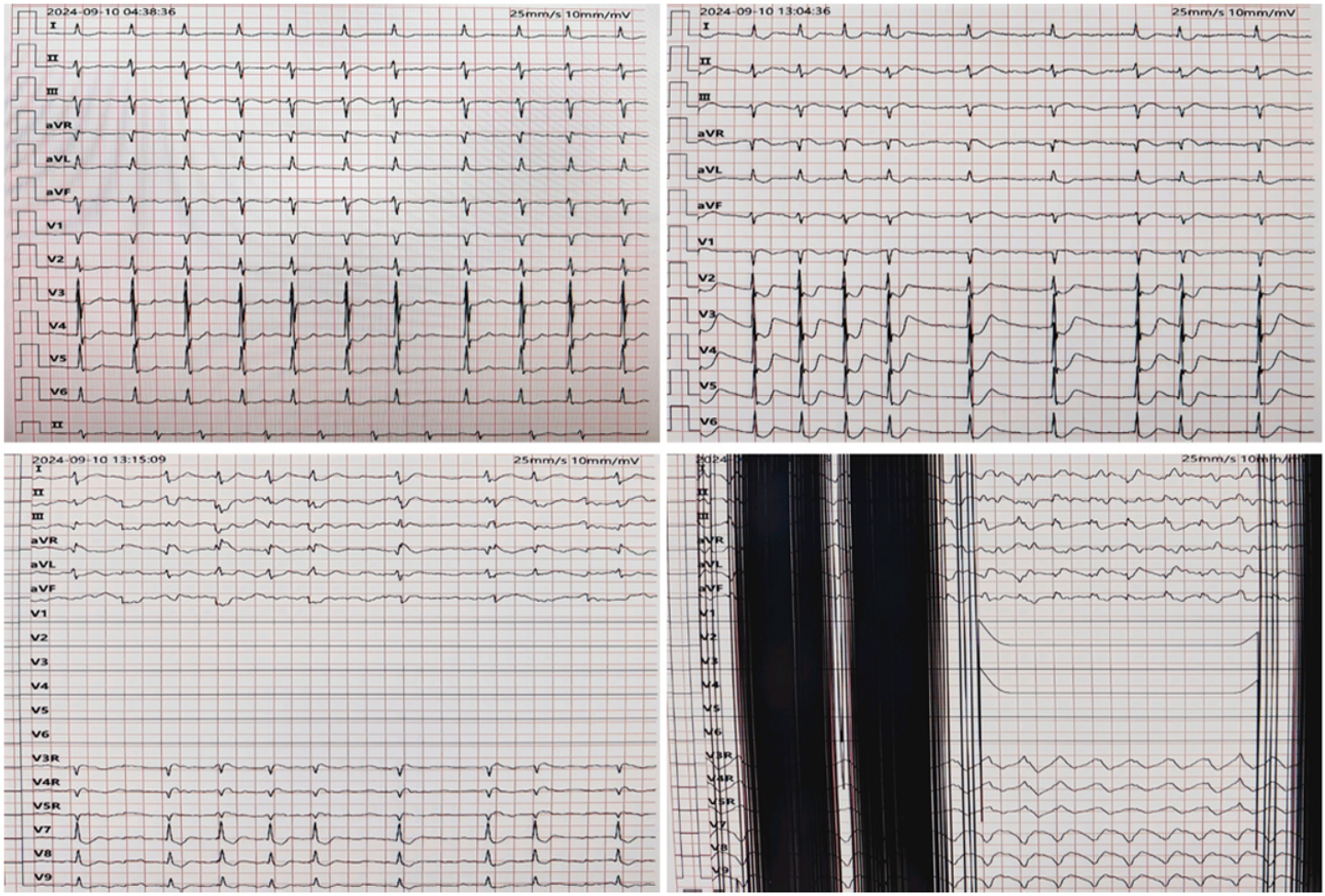

Figure 2

The changes in the electrocardiogram of patient 2

Supplementary Files

This is a list of supplementary files associated with this preprint. Click to download.

- Table1.docx
- Table2.docx