Research Square

Preprints are preliminary reports that have not undergone peer review.
They should not be considered conclusive, used to inform clinical practice,
or referenced by the media as validated information.

Immediate preoperative veno-venous extracorporeal membrane oxygenation for anaesthesia-induced aspiration pneumonitis in an abdominal trauma patient: a case report

Simon Dolenc
University Medical Centre Ljubljana
Primož Kastelic
University Medical Centre Ljubljana
Anja Kramarič Lozar
University Medical Centre Ljubljana
Primož Gradišek
primoz.gradisek@mf.uni-lj.si

University of Ljubljana

Case Report

Keywords: VV-ECMO, Mendelson's syndrome, chemical pneumonitis, aspiration pneumonia, ARDS, trauma-related small-bowel ischaemia, perioperative anticoagulation, CytoSorb® haemoadsorption

Posted Date: June 16th, 2026

DOI: https://doi.org/10.21203/rs.3.rs-9694168/v1

License: This work is licensed under a Creative Commons Attribution 4.0 International License. Read Full License

Additional Declarations: No competing interests reported.

Abstract

Background

Aspiration pneumonitis is a serious and potentially fatal complication that may occur during the induction of general anaesthesia. This report describes a clinical case involving the immediate preoperative use of veno-venous extracorporeal membrane oxygenation (VV-ECMO) as a life-saving intervention for severe respiratory failure caused by aspiration pneumonitis in a patient requiring urgent abdominal surgery for trauma-induced small-bowel ischaemia.

Case presentation

A 33-year-old male patient developed severe refractory hypoxemia following massive gastric content aspiration during rapid sequence induction for an emergency relaparotomy. Despite maximal conventional respiratory support measures, including inhalational recruitment manoeuvres and optimised mechanical ventilation strategies, adequate oxygenation could not be achieved. VV-ECMO support was initiated immediately before the urgent surgical intervention. The VV-ECMO was successfully maintained throughout the intraoperative period and continued postoperatively. Adjunctive in-line CytoSorb® hemoadsorption was subsequently used in the intensive care unit to manage marked hyperinflammation. No major bleeding, thrombotic events, or VV-ECMO-related organ dysfunction occurred postoperatively. VV-ECMO was discontinued after 7 days. The patient was successfully extubated on ICU day 21 and discharged home without functional impairment.

Conclusions

Immediate preoperative use of VV-ECMO for aspiration-induced refractory hypoxemia in patients requiring urgent major abdominal surgery has rarely been documented in the medical literature. This case demonstrates that, in carefully selected patients with life-threatening hypoxemia, rapid implementation of VV-ECMO may serve as an effective bridge to facilitate essential surgical procedures while providing adequate tissue oxygenation and allowing time for pulmonary recovery. To our knowledge, this is also the first reported use of CytoSorb® hemoadsorption specifically in aspiration-induced acute respiratory distress syndrome.

Background

Perioperative pulmonary aspiration is a major airway-related complication associated with significant morbidity and mortality. The reported incidence is approximately 1 in 8,000 cases during elective anaesthetic procedures, with rates increasing up to eight-fold in emergency surgical situations [1, 2]. When severe, aspiration pneumonitis may progress to acute respiratory distress syndrome (ARDS) [3–5]. In selected cases of severe ARDS characterised by refractory hypoxemia, veno-venous extracorporeal membrane oxygenation (VV-ECMO) may be required as a rescue therapy [6].

While perioperative VV-ECMO has been documented in specific clinical scenarios such as orthotopic liver transplantation and complex airway surgical procedures, evidence supporting its immediate preoperative use following massive aspiration events, particularly prior to emergency surgery, remains limited [7, 8]. This clinical scenario presents a substantial management challenge, as the implementation of extracorporeal support necessitates systemic anticoagulation, which may increase the risk of perioperative haemorrhage [9,10 The present report describes a case in which VV-ECMO was instituted before and maintained throughout an emergency abdominal surgical procedure for trauma-related small-bowel ischaemia following massive aspiration during the induction of anaesthesia.

Case presentation

A 33-year-old male patient presented to the emergency department with abdominal pain following a head-on motor vehicle collision. His medical history included recreational cocaine use and a bicuspid aortic valve with moderate stenosis. Abdominal computed tomography (CT) revealed 500 ml of free intraperitoneal fluid and a suspected small-bowel contusion without radiographic evidence of active haemorrhage. Emergency exploratory laparotomy identified two sites of venous bleeding and a serosal defect of the small intestine. After surgical haemostasis and serosal repair, the patient was transferred to the surgical ward. His initial postoperative course was stable, with unremarkable chest radiographic findings, although he repeatedly ingested large volumes of fluid despite strict intake restrictions (Figure 1A).

On postoperative day 3, the patient developed severe new-onset abdominal pain. Repeated CT imaging demonstrated ileus and extensive small-bowel ischaemia secondary to mesenteric venous thrombosis. Emergency relaparotomy was therefore indicated. At that time, the patient was hemodynamically stable, with peripheral oxygen saturation (SpO_2) of 97% on room air, and he denied nausea or retching. The patient declined nasogastric tube placement prior to the induction of anaesthesia.

Following preoxygenation in the head-up tilt position and rapid sequence induction using fentanyl, propofol, and rocuronium, the patient experienced regurgitation and aspiration of gastric contents. Despite maximal pulmonary support measures, including a fraction of inspired oxygen (FiO_2) of 1.0, positive end-expiratory pressure (PEEP) of 10 cmH_2O, and extensive bronchial lavage, arterial blood gas analysis revealed hypoxemic hypercapnic respiratory acidosis (Table 1). Despite repeated therapeutic bronchoscopic interventions and the addition of inhaled nitric oxide (iNO), the patient developed refractory hypoxemia, with SpO_2 decreasing to a nadir of 68%, while maintaining hemodynamic stability. Transoesophageal echocardiography (TEE) demonstrated the absence of right-sided pressure overload and revealed hyperdynamic biventricular function, effectively excluding acute pulmonary embolism. The clinical team proceeded to initiate veno-venous extracorporeal membrane oxygenation (VV-ECMO) in femoro-jugular configuration (drainage cannula: 25 French/50 cm positioned in the right femoral vein; return cannula: 23 French/20 cm positioned in the right internal jugular vein; Maquet Cardiohelp, Getinge, Sweden). A bolus dose of 5,000 IU of unfractionated heparin was administered during the cannulation procedure. Extracorporeal circulation was commenced 105 minutes after the aspiration event, following progressive refractory hypoxemia despite repeated bronchoscopic procedures and inhaled nitric oxide therapy. The initial blood flow rate, sweep gas flow rate, and oxygen fraction (FdO_2) were set at 4 L/min, 3.5 L/min, and 1.0, respectively (Table 1). Given the extensive small-bowel ischaemia, a joint decision was made to proceed with urgent exploratory laparotomy, during which ileocaecal resection, segmental ileal resection with terminal ileostomy creation, sigmoid resection, and terminal descendostomy were performed.

Table 1. Clinical timeline, ventilatory/ECMO settings, and arterial blood gases after aspiration.

Events	Following aspiration and first bronchoscopy	Following several bronchoscopies and addition of iNO before ECMO initiation	Immediately following ECMO initiation	Following adjustment of ECMO cannulae in ICU	18 hours post-ICU admission	Reference range
Time	18:30	19:30	20:00	00:15	18:15 next day	—
Time elapsed from aspiration (T0)	T0 + 15 min	T0 + 75 min	T0 + 105 min	T0 + 6 hours	T0 + 24 hours	—
Mechanical ventilation settings	FiO_2 1.0 PEEP 10 cm H_2O	FiO_2 1.0 PEEP 10 cm H_2O iNO 20 ppm	FiO_2 1.0 PEEP 10 cm H_2O iNO 20 ppm	FiO_2 0.4 PEEP 10 cm H_2O iNO 5 ppm	FiO_2 0.4 PEEP 10 cm H_2O iNO 0 ppm	—
ECMO settings	N/A	N/A	ECMO flow 4 L/min Sweep gas 3.5 L/min FdO_2 1.0	ECMO flow 3.3 L/min Sweep gas 3 L/min FdO_2 1.0	ECMO flow 4 L/min Sweep gas 3 L/min FdO_2 1.0	—
SpO_2 (%)	91	68	95	95	98	95–99
pH	7.295	7.329	7.341	7.364	7.401	7.37–7.45
pCO_2 (kPa)	8.51	6.66	4.53	4.42	5.27	4.7–6.1
pO_2 (kPa)	9.1	5.1	10.2	9.9	12.3	9.5–13.9
HCO_3^- (mmol/L)	30.1	25.5	17.9	18.4	24.0	21.0–26.0
Base excess (mmol/L)	2.8	−0.9	−6.7	−5.6	−0.2	−2.0 to +3.0
Lactate (mmol/L)	1.0	2.7	6.3	5.7	3.6	0.50–2.20

Abbreviations: ICU, intensive care unit; SpO_2, peripheral oxygen saturation; pCO_2, partial pressure of carbon dioxide; pO_2, partial pressure of oxygen; FiO_2, fraction of inspired oxygen; PEEP, positive end-expiratory pressure; ECMO, extracorporeal membrane oxygenation; FdO_2, fraction of delivered oxygen via ECMO; iNO, inhaled nitric oxide; ppm, parts per million; N/A, not applicable.

Following surgery, the patient was admitted to the intensive care unit (ICU). Admission chest radiography showed bilateral pulmonary infiltrates consistent with severe ARDS (Murray Lung Injury Score 2.25) and suboptimal positioning of the ECMO cannulae, which was confirmed by TEE (Figure 1B and 1C). Adjustment of the cannulae to the correct depth resulted in further improvement in oxygenation, as evidenced by discontinuation of iNO and reduction of FiO_2 to 0.4, while maintaining lung-protective ventilation (Table 1). During the early ICU course, while gas exchange parameters improved, the patient developed vasoplegic septic shock accompanied by a marked hyperinflammatory response at ICU admission (lactate 5.7 mmol/L, C-reactive protein 280 mg/L, procalcitonin 47.3 µg/L, and interleukin-6 [IL-6] 137,935 ng/L). Despite ultrasound-guided fluid optimisation, vasopressor support with norepinephrine and vasopressin was required to maintain adequate tissue perfusion, and a hydrocortisone infusion was started. Hemoperfusion blood purification with a CytoSorb® cartridge (CytoSorbents Corporation, New Jersey, USA), incorporated into the ECMO circuit, was commenced 6 hours after ICU admission. After 12 hours of hemoadsorption therapy, the IL-6 concentration

decreased from 23,892 ng/L to 1,112 ng/L, while the norepinephrine-equivalent vasopressor requirement decreased from 0.5 to 0.135 μg/kg/min. Broad-spectrum antimicrobial therapy consisting of imipenem, vancomycin, and anidulafungin was initiated for presumed sepsis in the context of acute lung injury and distributive shock. Klebsiella pneumoniae and Enterococcus faecium were subsequently isolated from blood cultures and lower airway specimens and were sensitive to the antibiotics used, while follow-up blood cultures remained sterile and repeated echocardiographic examinations showed no evidence of infective endocarditis. Hemodynamic status improved progressively, permitting discontinuation of vasopressor support on postoperative day 2.

Upon ICU admission, continuous intravenous unfractionated heparin was started at 1,000 IU/h and adjusted to maintain a target activated partial thromboplastin time (aPTT) of 55–65 seconds. Within the first 18 hours, the platelet count fell to a nadir of 45×10⁹/L, representing a 70% reduction from the admission value. After heparin-induced thrombocytopenia was excluded, the aPTT target was lowered to 45–55 seconds. The patient's platelet count recovered spontaneously without specific intervention. No major haemorrhagic complications requiring transfusion, thrombotic events, ECMO-related organ dysfunction, or ECMO circuit failure occurred during the postoperative period. VV-ECMO support was discontinued on postoperative day 7. Weaning from mechanical ventilation was prolonged due to severe hyperactive delirium. Haloperidol, quetiapine, and lorazepam were administered sequentially; however, symptoms remained refractory until enteral valproate was added to the regimen. The patient was successfully extubated on ICU day 21 and transferred the following day to a lower-acuity surgical ward. A chest X-ray demonstrated complete resolution of pulmonary infiltrates (Figure 1D). He was discharged home 18 days later without cognitive, pulmonary, or intestinal impairment.

Discussion

Pulmonary aspiration of gastric contents during anaesthesia induction resulted in fulminant hypoxemic respiratory failure, consistent with severe chemical pneumonitis and early ARDS. As hypoxemia persisted despite repeated bronchoscopic lavage procedures, optimised mechanical ventilation strategies, and iNO therapy, VV-ECMO was implemented as a bridge to pulmonary recovery while limiting further ventilator-induced lung injury and facilitating urgent abdominal surgery. In this patient, this indication arose immediately prior to urgent relaparotomy for extensive small-bowel ischaemia, creating a challenging balance between life-saving respiratory rescue intervention and the haemorrhagic risk associated with major abdominal surgery under systemic anticoagulation.

In this case, blunt abdominal trauma was followed by delayed small-bowel ischaemia. Although hollow viscus and mesenteric injuries occur in only approximately 1% of blunt trauma patients, they are frequently missed initially, and vascular injury may manifest later as intestinal ischaemia or necrosis. Prompt recognition is therefore crucial, as diagnostic delay increases morbidity and likely mortality [11]. Small-bowel ileus, combined with non-adherence to the fluid restriction protocol, likely contributed to the aspiration event.

Extracorporeal support has previously been incorporated into perioperative management in selected clinical settings, particularly in liver transplantation and planned complex airway or thoracic surgical procedures, where conventional ventilation may be unsafe or technically impossible [7,8]. The broader surgical and trauma ECMO literature indicates that extracorporeal support can be feasible in selected patients requiring operative management; however, haemorrhage, thrombosis, infection, and anticoagulation management remain major concerns [12,13]. Evidence directly addressing VV-ECMO for aspiration-induced respiratory failure in the immediate preoperative setting is limited to case reports and small case series. As summarised in Table 2, in previously reported peri-induction or procedural aspiration cases managed with ECMO, either the planned surgery was abandoned [14,15] or ECMO was initiated only postoperatively as rescue therapy [16,17]. In contrast, the present case appears to represent a rare example of VV-ECMO established immediately before and maintained throughout urgent major abdominal surgery for aspiration-

induced refractory hypoxaemic respiratory failure and early ARDS.

Table 2. Previously reported cases of ECMO for aspiration-related respiratory failure in the perioperative or peri-procedural setting.

Study	Patient age	Aspiration context	ECMO timing	Surgery decision	Anticoagulation	Complications
Wetsch 2012 [14]	39	Induction for urgent hand surgery	VA-ECMO 3 h after aspiration; VV-ECMO later on day 7	Cancelled	Not reported	Cardiac arrest before ECMO; VA-ECMO oxygenation limitation attributed to high cardiac output requiring later VV-ECMO
Kim 2015 [15]	64	Induction for diagnostic laparoscopy/possible gastrectomy	60 min post-aspiration	Cancelled	Not reported	No major ECMO complication reported
Felinski 2021 [16]	Two patients, both 56	Induction for reoperation after gastric bypass surgery	Postoperative; within several hours in both cases	Completed before ECMO	Not reported	Incidental subsegmental pulmonary embolism
Gamberini 2021 [17]	69	Sedation for ERCP on postoperative day 9 after abdominal surgery	6 h post-aspiration	N/A (ERCP)	UFH bolus + infusion; aPTT ratio target 1.5	Renal failure requiring haemodialysis
Present case	33	Induction before urgent relaparotomy	105 min post-aspiration	Proceeded on ECMO	UFH bolus + infusion; aPTT target 55–65 s, later 45–55 s	Platelet drop; cannula malposition; no major bleeding, thrombosis, or circuit failure

Legend: Cases were selected because aspiration was temporally related to induction of anaesthesia or procedural sedation. All patients survived.

Abbreviations: ECMO, extracorporeal membrane oxygenation; VV, veno-venous; VA, veno-arterial; UFH, unfractionated heparin; aPTT, activated partial thromboplastin time; ERCP, endoscopic retrograde cholangiopancreatography; N/A, not applicable.

Aspiration-related lung injury includes large-airway obstruction, chemical aspiration pneumonitis caused by sterile gastric contents, and aspiration pneumonia due to inoculation of pathogenic oropharyngeal or enteric flora [3,18]. In our patient, bronchoscopy promptly relieved the obstructive component, whereas bacterial superinfection became evident only later during the ICU stay. Fulminant respiratory failure was therefore most consistent with severe chemical aspiration pneumonitis, first described by Mendelson [19]. This results from macroaspiration of sterile gastric contents, causing immediate caustic epithelial injury (within an hour), followed by a secondary neutrophil-mediated inflammatory response (within 4–6 hours), as was markedly observed in our case [3,19]. Radiographically, it is typically characterised by bilateral patchy or confluent air-space opacities in dependent lung regions, as observed in our patient (Figure 1B).

Treatment is mainly supportive and, when aspiration pneumonitis progresses to ARDS, should follow evidence-based ARDS management, including lung-protective ventilation, appropriate PEEP, prone positioning, and VV-ECMO in selected patients with severe refractory hypoxaemia [6]. Inhaled nitric oxide may be considered as a temporary rescue adjunct in selected cases, as in our patient. Although prophylactic antibiotics are not recommended for uncomplicated aspiration pneumonitis [20], close clinical reassessment is warranted because secondary bacterial infection may follow macroaspiration, and early differentiation from aspiration pneumonia is often difficult [5,18]. Given the small-bowel ileus/ischaemia, subsequent positive blood and lower-airway cultures, and evolution to distributive shock, empiric antibiotics in our case were justified as treatment for evolving infection rather than as prophylaxis. ARDS remains associated with substantial mortality and long-term morbidity. Contemporary data indicate a 28-day mortality rate of approximately 35%, rising to more than 40% in patients with severe ARDS, and survivors frequently experience persistent physical impairment, cognitive dysfunction, and psychological sequelae [21].

A technical challenge in this case was the suboptimal positioning of the ECMO cannulas, identified on chest radiograph and confirmed by transoesophageal echocardiography at ICU admission (Figure 1B). Cannula positions were assessed intraoperatively; however, repositioning was deferred due to several competing priorities: the urgency of completing bowel resection, adequate intraoperative oxygenation not warranting immediate intervention, limited access to cannulation sites within the operative field, and the high cognitive load of simultaneous ECMO management and major abdominal surgery. There was evidence of recirculation, manifesting as inadequate improvement in oxygenation despite ECMO support, with persistently elevated FiO_2 requirements and continued iNO dependency on ICU admission. Prompt adjustment after ICU admission improved oxygenation, as evidenced by iNO discontinuation and a reduction in FiO_2 to 0.4. This experience highlights the value of predefined intraoperative repositioning thresholds and structured postoperative imaging protocols when ECMO is deployed in the operating theatre.

A notable aspect of this case was the approximately 90-minute interval between the onset of hypoxemia and ECMO initiation. During this period, repeated therapeutic bronchoscopies and the addition of inhaled nitric oxide were attempted as conventional rescue strategies, while ECMO preparation (team mobilisation, equipment setup) proceeded in parallel. Although earlier ECMO initiation might have reduced the duration of hypoxaemic exposure, attempting conventional rescue strategies while preparing ECMO in parallel was clinically reasonable given the invasiveness and inherent risks of perioperative extracorporeal support. Nonetheless, this case highlights the importance of early ECMO consultation and parallel preparation – simultaneous conventional rescue and ECMO readiness – to minimise the time to cannulation once ECMO is deemed necessary [22].

In addition to VV-ECMO, our patient received adjunctive in-line CytoSorb® hemoadsorption for vasoplegic septic shock with marked hyperinflammation. IL-6 concentrations decreased during treatment and hemodynamics progressively stabilised, although these changes cannot be attributed solely to hemoadsorption, as source control, antimicrobials, corticosteroids, and ECMO support were administered concurrently. To our knowledge, no previous report has described CytoSorb® hemoadsorption specifically in aspiration-induced ARDS, making this a second novel aspect of the case beyond the immediate preoperative VV-ECMO sequence. Existing evidence for CytoSorb® in septic shock and ARDS remains mixed: Scharf et al. reported no significant difference in IL-6 reduction, hemodynamic stabilisation, or mortality after propensity matching, whereas the international CytoSorb registry reported biomarker reductions and cardiovascular/pulmonary Sequential Organ Failure Assessment improvements without a clear mortality benefit [23,24]. In the most comparable ECMO series, Kogelmann et al. reported haemodynamic stabilisation, reduced catecholamine requirements, improved respiratory variables, and lower-than-predicted mortality in patients with septic shock, severe ARDS, VV-ECMO, and renal replacement therapy treated with CytoSorb® [25]. Therefore, our findings should be interpreted as hypothesis-generating rather than evidence of efficacy.

This case suggests that immediate preoperative VV-ECMO may be considered when refractory hypoxemia coexists with an urgent, non-deferrable surgical indication, provided the patient is hemodynamically stable, conventional rescue therapies have been exhausted, and institutional resources allow rapid ECMO deployment. The decision to proceed with surgery on ECMO requires careful weighing of competing risks – ongoing hypoxaemic organ injury versus surgical bleeding under systemic anticoagulation – ideally through a structured multidisciplinary discussion. Several factors contribute to this increased bleeding diathesis: consumption coagulopathy in the context of major surgery, ECMO-induced coagulopathy, and thrombocytopenia due to consumption and septic shock [9,10].

This case also illustrates the limitations of rapid sequence induction in patients with ileus, presumed gastric distension, or non-adherence to fasting restrictions. In such high-risk situations, pre-induction gastric decompression should be considered whenever feasible, and patient refusal should prompt explicit risk discussion and contingency planning. During ECMO-supported surgery, anaesthetic management requires close coordination between the anaesthesia, ECMO, and surgical teams, particularly regarding lung-protective ventilation, anticoagulation, haemostasis, cannula position, and haemodynamic targets.

Several limitations of this report merit acknowledgment. As a single case report, generalisability is inherently limited, and the favourable outcome may partly reflect patient-specific factors, including young age and the absence of major comorbidities, as well as institutional resources that enabled rapid ECMO deployment. The suboptimal initial cannula positioning may have transiently affected oxygenation during the early ICU course, and its avoidance or earlier correction represents a technical lesson for future cases. Additionally, the approximately 90-minute interval between refractory hypoxemia and ECMO initiation, while clinically justified by parallel conventional rescue attempts and logistical preparation, represents an area for potential process improvement in future cases.

Conclusions

To our knowledge, this case is one of the few documented examples of VV-ECMO initiated immediately before and maintained throughout urgent surgery to manage aspiration-induced ARDS following induction to anaesthesia, and it may also represent the first reported use of adjunctive in-line CytoSorb® haemoadsorption in this context. This case highlights that immediate preoperative VV-ECMO may be feasible in carefully selected patients requiring urgent major surgery when refractory hypoxemia cannot otherwise be managed, whereas the observed response to CytoSorb® should be interpreted as hypothesis-generating rather than evidence of efficacy.

Abbreviations

ARDS: Acute respiratory distress syndrome
aPTT: Activated partial thromboplastin time
CT: Computed tomography
ECMO: Extracorporeal membrane oxygenation
FdO_2: Fraction of delivered oxygen (ECMO oxygen delivery fraction)
FiO_2: Fraction of inspired oxygen
ICU: Intensive care unit
IL-6: Interleukin-6
iNO: Inhaled nitric oxide
PEEP: Positive end-expiratory pressure
SpO_2: Peripheral oxygen saturation
TEE: Transoesophageal echocardiography
VV-ECMO: Veno-venous extracorporeal membrane oxygenation

Declarations

Ethics approval and consent to participate

Ethics approval was not required for this case report according to institutional requirements. Consent to participate was not applicable as this is a retrospective case report.

Consent for publication

Written informed consent was obtained from the patient for publication of this case report and any accompanying images.

Availability of data and materials

All the data relevant to this case report are included in this article.

Competing interests

The authors declare that they have no competing interests.

Funding

No funding was received for this case report.

Authors' contributions

SD, PK, and AKL contributed to the acquisition and interpretation of the clinical data and were involved in the clinical management of the patient. SD and PG conceived the case report and its scientific framing. SD, PK, and PG drafted the initial manuscript. PG substantively revised the manuscript for important intellectual content, including clinical interpretation, perioperative management, extracorporeal support, and presentation of the case. All the authors approved the submitted version of the manuscript and agree to be personally accountable for their own contributions. All authors also agree to ensure that questions related to the accuracy or integrity of any part of the work are appropriately investigated, resolved, and documented.

Acknowledgements

Not applicable.

Authors' information

Not applicable.

References

1. Sun J, Wei G, Hu L, Liu C, Ding Z. Perioperative pulmonary aspiration and regurgitation without aspiration in adults: a retrospective observational study of 166,491 anesthesia records. Ann Palliat Med. 2021;10(4):4037–46. 10.21037/apm-20-2382.
2. Robinson M, Davidson A. Aspiration under anaesthesia: risk assessment and decision-making. Contin Educ Anaesth Crit Care Pain. 2014;14(4):171–5. 10.1093/bjaceaccp/mkt053.
3. Košutova P, Mikolka P. Aspiration syndromes and associated lung injury: incidence, pathophysiology and management. Physiol Res. 2021;70(Suppl4):S567–83. 10.33549/physiolres.934767.

4. Son YG, Shin J, Ryu HG. Pneumonitis and pneumonia after aspiration. J Dent Anesth Pain Med. 2017;17(1):1–12. 10.17245/jdapm.2017.17.1.1.
5. Raghavendran K, Nemzek J, Napolitano LM, Knight PR. Aspiration-induced lung injury. Crit Care Med. 2011;39(4):818–26. 10.1097/CCM.0b013e31820a856b.
6. Qadir N, Sahetya S, Munshi L, Summers C, Abrams D, Beitler J, et al. An update on management of adult patients with acute respiratory distress syndrome: An official American Thoracic Society clinical practice guideline. Am J Respir Crit Care Med. 2024;209(1):24–36. 10.1164/rccm.202311-2011ST.
7. Laici C, Bianchini A, Miglionico N, Bambagiotti N, Vitale G, Fallani G, et al. Planned extracorporeal life support employment during liver transplantation: The potential of ECMO and CRRT as preventive therapies-case reports and literature review. J Clin Med. 2023;12(3):1239. 10.3390/jcm12031239.
8. Onorati I, Radu DM, Maiolino E, Suriano I, Juvin C, Peretti M, et al. The role of extracorporeal membrane oxygenation in airway surgery: experience from a French referral centre for tracheobronchial diseases. Eur J Cardiothorac Surg. 2026;68(2):ezag076. 10.1093/ejcts/ezag076.
9. Frantzeskaki F, Konstantonis D, Rizos M, Kitsinelis V, Skyllas G, Renieris I, et al. Extracorporeal membrane oxygenation (ECMO)-associated coagulopathy in adults. Diagnostics (Basel). 2023;13(23):3496. 10.3390/diagnostics13233496.
10. Murphy DA, Hockings LE, Andrews RK, Aubron C, Gardiner EE, Pellegrino VA, et al. Extracorporeal membrane oxygenation-hemostatic complications. Transfus Med Rev. 2015;29(2):90–101. 10.1016/j.tmrv.2014.12.001.
11. Smyth L, Bendinelli C, Lee N, Reeds MG, Loh EJ, Amico F, et al. WSES guidelines on blunt and penetrating bowel injury: diagnosis, investigations, and treatment. World J Emerg Surg. 2022;17(1):13. 10.1186/s13017-022-00418-y.
12. Juthani BK, Macfarlan J, Wu J, Beman S, Misselbeck TS. Incidence of general surgical procedures in adult patients on extracorporeal membrane oxygenation. J Intensive Care Soc. 2019;20(2):155–60. 10.1177/1751143718801705.
13. Wang C, Zhang L, Qin T, Xi Z, Sun L, Wu H, et al. Extracorporeal membrane oxygenation in trauma patients: a systematic review. World J Emerg Surg. 2020;15(1):51. 10.1186/s13017-020-00331-2.
14. Wetsch WA, Spöhr FA, Hinkelbein J, Padosch SA. Emergency extracorporeal membrane oxygenation to treat massive aspiration during anaesthesia induction. A case report. Acta Anaesthesiol Scand. 2012;56(6):797–800. 10.1111/j.1399-6576.2012.02697.x.
15. Kim N, Kim KH, Kim JM, Choi SY, Na S. Early extracorporeal membrane oxygenation for massive aspiration during anesthesia induction. Acute Crit Care. 2015;30(2):109–14. 10.4266/kjccm.2015.30.2.109.
16. Felinski MM, Abbas D, Walker PA, Primomo JA, Kajese TM, Kar B, et al. Extracorporeal membrane oxygenation rescue for severe aspiration pneumonitis in two patients after roux-en-y gastric bypass procedure. J Extra Corpor Technol. 2021;53(3):199–203. 10.1182/ject-2100013.
17. Gamberini E, Poletti V, Russo E, Circelli A, Benni M, Scognamiglio G, et al. Massive aspiration syndrome: a possible indication for emergent veno-venous extracorporeal membrane oxygenation? a case report. J Med Case Rep. 2021;15(1):499. 10.1186/s13256-021-03050-7.
18. Pan D, Chung S, Nielsen E, Niederman MS. Aspiration pneumonia. Semin Respir Crit Care Med. 2024;45(2):237–45. 10.1055/s-0043-1777772.
19. Mendelson CL. The aspiration of stomach contents into the lungs during obstetric anesthesia. Am J Obstet Gynecol. 1946;52:191–205. 10.1016/s0002-9378(16)39829-5.
20. Dragan V, Wei Y, Elligsen M, Kiss A, Walker SAN, Leis JA. Prophylactic antimicrobial therapy for acute aspiration pneumonitis. Clin Infect Dis. 2018;67(4):513–8. 10.1093/cid/ciy120.
21. Gorman EA, O'Kane CM, McAuley DF. Acute respiratory distress syndrome in adults: diagnosis, outcomes, long-term sequelae, and management. Lancet. 2022;400(10358):1157–70. 10.1016/S0140-6736(22)01439-8.

22. Powell EK, Reynolds TS, Webb JK, Kundi R, Cantu J, Keville M, et al. Early veno-venous extracorporeal membrane oxygenation is an effective strategy for traumatically injured patients presenting with refractory respiratory failure. J Trauma Acute Care Surg. 2023;95(2S):S50–9. 10.1097/TA.0000000000004057.
23. Scharf C, Schroeder I, Paal M, Winkels M, Irlbeck M, Zoller M, et al. Can the cytokine adsorber CytoSorb® help to mitigate cytokine storm and reduce mortality in critically ill patients? A propensity score matching analysis. Ann Intensive Care. 2021;11(1):115. 10.1186/s13613-021-00905-6.
24. Hawchar F, Tomescu D, Träger K, Joskowiak D, Kogelmann K, Soukup J, et al. Hemoadsorption in the critically ill—Final results of the International CytoSorb Registry. PLoS ONE. 2022;17(10):e0274315. 10.1371/journal.pone.0274315.
25. Kogelmann K, Scheller M, Drüner M, Jarczak D. Use of hemoadsorption in sepsis-associated ECMO-dependent severe ARDS: a case series. J Intensive Care Soc. 2020;21(2):183–90. 10.1177/1751143718818992.

Figures

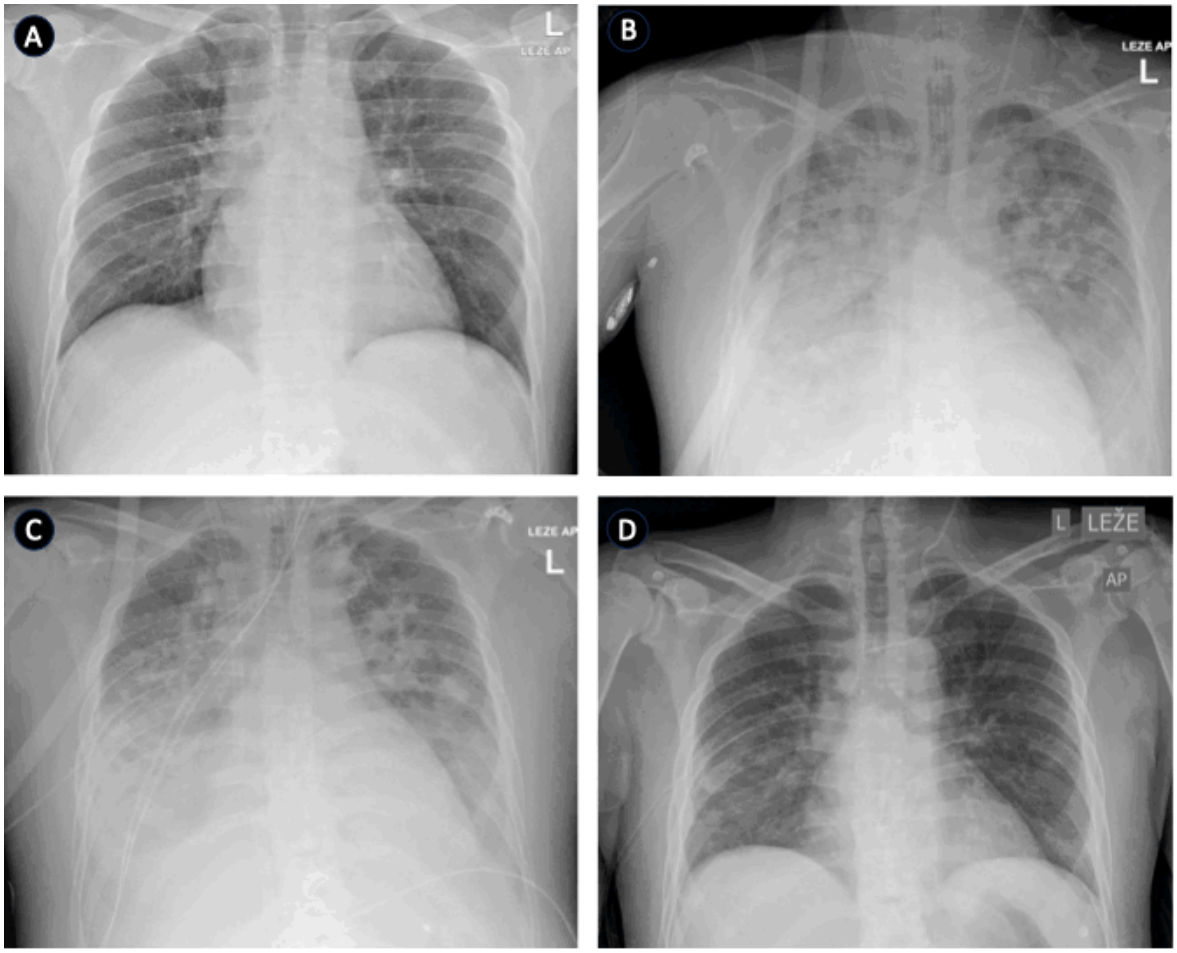

Figure 1

Serial chest radiographs during the clinical course.

Legend: Chest radiographs obtained (A) on the surgical ward before emergency exploratory laparotomy; (B) at admission to the intensive care unit; (C) suboptimal positioning of the extracorporeal membrane oxygenation (ECMO) cannula; and (D) after ECMO decannulation, demonstrating resolution of pulmonary infiltrates.