Research Square

Preprints are preliminary reports that have not undergone peer review.
They should not be considered conclusive, used to inform clinical practice,
or referenced by the media as validated information.

Diagnostic capability of perimetry and optical coherence tomography based retinal thickness measurements in diabetic patients with no or mild retinopathy

Nasrin Moghadas Sharif
Mashhad University of Medical Sciences
Faezeh Noferesti
Mashhad University of Medical Sciences
Maliheh Karimpour
Karimpour.opt@gmail.com

Mashhad University of Medical Sciences
Ata Asiaei
Birjand University of Medical Sciences

Article

Keywords: diabetes, diabetic retinopathy, retinal thickness, visual field, perimetry

Posted Date: June 8th, 2026

DOI: https://doi.org/10.21203/rs.3.rs-9676162/v1

License: This work is licensed under a Creative Commons Attribution 4.0 International License.
Read Full License

Additional Declarations: No competing interests reported.

Abstract

Purpose: To compare and evaluate the diagnostic potential of visual field parameters and different retinal layers thicknesses among diabetic patients with and without diabetic retinopathy and non-diabetic controls

Methods: A total of 174 participants were enrolled in present study, divided equally into three groups of 58 subjects: (1) healthy controls, (2) diabetic patients without diabetic retinopathy (NoDR), and (3) diabetic patients with mild non-proliferative diabetic retinopathy (NPDR). A comprehensive ophthalmologic examination including visual field parameters and retinal layers thicknesses was obtained for all the participants.

Results: Significant thinning of the Nerve Fiber Layer (NFL) (P = 0.038) and Outer Nuclear Layer (ONL) (P = 0.027) was observed in eyes of NoDR patients compared with healthy controls. In comparison between mild NPDR and NoDR patients, significant differences were detected in Ganglion Cell Layer (GCL) (P = 0.013), NFL (P **<** 0.001), Outer Plexiform Layer (OPL) (P= 0.001), Retinal Pigment Epithelium (RPE) (P= 0.017) and also the Inner Nuclear Layer (INL) (P = 0.013). Mean Deviation of visual field (MD) demonstrated good diagnostic performance with 69% sensitivity and 80% specificity for distinguishing NoDR patients from controls and also 81% sensitivity and 80% specificity for differentiating NPDR patients from controls.

Conclusion: Patients with mild or no diabetic retinopathy may exhibit substantial visual field sensitivity loss that is typically diffuse in pattern, and mean deviation may serve as an optimal index for assessing overall sensitivity.

Introduction

Diabetic retinopathy (DR) is the most common microvascular complication associated with diabetes mellitus, affecting approximately one-third of diabetic individuals [1]. It is generally classified into two major stages: Non-Proliferative Diabetic Retinopathy (NPDR) and Proliferative Diabetic Retinopathy (PDR). The diagnosis of NPDR is primarily based on fundus photography and is characterized by the microvascular abnormalities including micro aneurysms and retinal hemorrhages, in the absence of neovascularization [2]. Macular edema accompanying NPDR may lead to visual impairment. Progression to PDR, which is marked by the development of pathological retinal neovascularization, can result in severe or complete vision loss due to complications such as vitreous hemorrhage and/or tractional retinal detachment [2].

Since the advent of optical coherence tomography (OCT) in 1991 [3], this imaging modality has become an important biomarker in the diagnosis and monitoring of DR. OCT employs low-coherence interferometry to produce high-resolution, cross-sectional, three-dimensional images of the retina. When combined with advanced image segmentation techniques, OCT enables precise quantification of the thickness of individual retinal layers [4].

Consequently, numerous investigators have sought to elucidate the relationship between retinal layer thickness and the progression of DR. Previous studies [2, 4–6] have reported alterations in the thickness of various retinal layers as well as in different macular regions among diabetic and DR patients. Furthermore, OCT has demonstrated ability to detect early neurodegenerative changes in diabetic individuals even in the absence of clinically detectable DR on fundus examination [7].

In addition to structural changes, DR has been shown to affect functional visual outcomes, particularly visual field parameters such as mean sensitivity (MS) and mean defect (MD), also referred to as mean deviation (MD). These parameters are essential for evaluating visual function and identifying abnormalities in visual perception. MS reflects the average luminance level at which visual stimuli are detected 50% of the time during perimetric testing, with higher MS values indicating greater visual sensitivity. In contrast, MD quantifies the average deviation of an individual's visual sensitivity from that of an age-matched normative population [8].

Although several studies have evaluated structural and functional retinal changes in diabetes, the majority have focused either on isolated OCT parameters or visual field indices, often without clear stratification of early disease stages. Furthermore, the relationship between subtle retinal thinning and corresponding functional impairment in patients without clinically evident diabetic retinopathy or with mild NPDR remains incompletely understood and somewhat inconsistent across studies. Therefore, there is a need for well-powered studies that simultaneously assess both structural and functional parameters across early stages of diabetic retinal disease.

Therefore, the present study aimed to compare visual field parameters and different retinal layers thicknesses among patients with DR. Additionally, we sought to evaluate the diagnostic potential of perimetry and OCT-derived retinal parameters in distinguishing individuals with diabetes and DR from those without DR and from non-diabetic controls.

Materials and Methods

Study population

A total of 174 participants were enrolled, equally divided into three groups of 58 subjects: (1) healthy controls, (2) diabetic patients without diabetic retinopathy (NoDR), and (3) diabetic patients with mild non-proliferative diabetic retinopathy (NPDR). The study was conducted at Razi Hospital, Birjand, Iran.

A comprehensive ophthalmologic examination was performed for all the participants, including slit-lamp biomicroscopy, funduscopy, tonometry, and both objective and subjective refraction. The exclusion of other ocular conditions was determined based on participants' ophthalmic history and the findings of this examination.

For control group, inclusion criteria required participants to be aged 18 years or older with no history of diabetes. For the diabetic groups (NoDR and NPDR), participants aged 18 years or older with a confirmed

diagnosis of diabetes mellitus were recruited. Exclusion criteria for all groups included: presence of any neurological or systemic disease other than diabetes; other ocular disorders potentially affecting vision (e.g., glaucoma or cataract of grade > + 1); use of medications known to influence visual performance; best corrected visual acuity (BCVA) worse than 20/40; spherical equivalent ≥ ± 3.00 diopters; astigmatism ≥ 2.00 diopters; macular edema; and pregnancy.

Diabetic retinopathy severity was classified according to the International Clinical Diabetic Retinopathy Disease Severity Scale. Grading was performed by an experienced ophthalmologist based on fundus examination and/or retinal imaging.

Visual field assessment

Visual field testing was performed using the 30° SITA Standard strategy with a Humphrey Field Analyzer (Swedish Interactive Threshold Algorithm, standard protocol; Carl Zeiss Meditec Inc., Dublin, California, USA). All examinations were carried out by the same optometrist. Participants were instructed on the procedures in detail prior to testing, and any medications affecting pupil size were prohibited. Corrective lenses were worn during testing. Before testing, participants adapted to a dark environment for 3–5 minutes. The Goldmann III stimulus was used with a duration of 100 ms and a background luminance of 4 cd/m². Visual field reliability was ensured by maintaining both false-positive and false-negative rates below 20%. Finally, the mean defect (MD) value of each participant was recorded.

Participants were seated comfortably, instructed to fixate on a central target, and asked to press a response button whenever a flash of light was detected. The varying intensity of stimuli allowed assessment of regional sensitivity thresholds and identification of potential visual field defects.

Retinal layers thicknesses measurement

Retinal imaging was performed using spectral-domain optical coherence tomography (SD-OCT; Spectralis HR + OCT, Heidelberg Engineering, Heidelberg, Germany) following pharmacological mydriasis (pupil diameter 6–8 mm). A standardized macular scan centered on the fovea was obtained for all participants. The device operates at a scanning speed of up to 40,000 A-scans per second with axial and transverse resolutions of approximately 7 µm and 14 µm, respectively. Automatic Real-Time (ART) averaging was applied to enhance the signal-to-noise ratio and improve overall image quality. Images with poor signal strength, motion artifacts, poor centration, or segmentation errors were excluded from the analysis. Automated retinal layer segmentation was performed using the device's built-in software, and all segmentation outputs were reviewed for accuracy by a trained examiner.

All imaging procedures were performed by a single trained operator to minimize inter-operator variability. Only one eye per participant was included in the analysis to avoid inter-eye correlation. When both eyes met the eligibility criteria, the eye with more severe diabetic retinopathy was selected; if both eyes had the same severity, the eye with better best-corrected visual acuity (BCVA) was included.

Data Analysis

Retinal layers thicknesses and the visual field MD were compared across groups to identify potential early indicators of DR progression. Data analysis was performed using SPSS software (version 22.0; IBM Corp., Armonk, NY, USA). Normality of data distribution was assessed prior to analysis. Participant characteristics were compared across groups, and variables representing full retinal thickness and perimetry results were analyzed using one-way analysis of variance (ANOVA) and Tukey's test were applied for post hoc pairwise comparisons

Diagnostic performance was evaluated using the area under the receiver operating characteristic curve (AUC) with the corresponding 95% confidence intervals (CI). Sensitivities were determined at 80% and 95% specificity levels. The optimal diagnostic threshold for parameters with the highest AUC values was identified using the Youden index.

Results

A total of 174 participants were included in the study, comprising 58 individuals with NPDR, 58 with NoDR, and 58 healthy controls. The demographic and clinical characteristics of the study participants are summarized in Table 1.

Table 1
Clinical characteristics of participants in the groups

Variables	**NoDR** ***n* = 58**	**NPDR** ***n* = 58**	**Control** ***n* = 58**	**P- value**
Age (years)	52.76 ± 11.07	56.72 ± 8.66	51.76 ± 9.31	0.075
Males, n (%)	27 (46.5%)	22 (37.9%)	25 (43.1%)	0.069
HbA_{1c} (%)	7.8 ± 1.52	8.4 ± 1.31	5.3 ± 0.24	< 0.001
Duration of diabetes (years)	10 ± 11	18 ± 14	n/a	0.002

Data are expressed as Mean ± SD.

The retinal thickness maps of the full retina and seven individual retinal layers_ including the Nerve Fiber Layer (NFL), Ganglion Cell Layer (GCL), Inner Plexiform Layer (IPL), Inner Nuclear Layer (INL), Outer Plexiform Layer (OPL), Outer Nuclear Layer (ONL) and Retinal Pigment Epithelium (RPE) _ were generated from the OCT scans. Table 2 presents the comparative analysis of the thicknesses of the various retinal layers, along with mean deviation (MD) of visual field, among the three groups.

Table 2
Comparison of retinal layers thicknesses and visual field parameters among the three groups. Data are expressed as Mean ± SD.

Layers		NoDR	NPDR	Control	P	Post hoc results between groups		
						P^1	P^2	P^3
Retina	Center	261.05 ± 25.83	263.67 ± 27.15	258.41 ± 20.29	0.488			
	Superior	318.35 ± 19.63	322.28 ± 15.75	323.28 ± 14.00	0.434			
	Inferior	14.10 ± 1.85	16.81 ± 2.21	13.67 ± 1.80	0.621			
	Nasal	316.27 ± 19.34	323.93 ± 17.86	324.63 ± 17.03	**0.024**	> 0.99	**0.041**	0.072
	Temporal	313.73 ± 19.20	307.68 ± 19.58	307.60 ± 12.54	0.078			
GCL	Center	13.45 ± 5.01	13.72 ± 4.47	13.56 ± 4.15	0.914			
	Superior	46.50 ± 5.59	44.35 ± 4.92	46.66 ± 4.47	**0.022**	0.235	**0.007**	0.095
	Inferior	45.92 ± 4.07	44.36 ± 4.94	46.14 ± 3.87	**0.020**	0.394	**0.007**	0.056
	Nasal	45.47 ± 5.35	43.00 ± 5.19	45.15 ± 4.64	**0.007**	0.730	**0.004**	**0.013**
	Temporal	43.15 ± 4.38	42.55 ± 5.32	43.38 ± 4.22	0.617			
NFL	Center	11.41 ± 2.70	11.57 ± 2.56	11.38 ± 2.25	0.979			
	Superior	30.38 ± 4.52	30.70 ± 4.32	29.21 ± 4.04	0.144			
	Inferior	31.10 ± 3.98	32.03 ± 4.91	30.59 ± 3.31	0.264			
	Nasal	32.81 ± 5.32	28.45 ± 8.56	31.65 ± 6.84	**0.035**	0.806	0.057	**0.012**
	Temporal	19.43 ± 4.17	25.14 ± 8.62	19.35 ± 5.16	**< 0.001**	**0.038**	**< 0.001**	**< 0.001**
OPL	Center	25.43 ± 6.91	26.93 ± 7.26	23.57 ± 5.20	0.027			

Layers		NoDR	NPDR	Control	P	Post hoc results between groups		
						P^1	P^2	P^3
	Superior	30.72 ± 4.81	33.10 ± 6.48	31.38 ± 5.21	0.147			
	Inferior	30.61 ± 5.97	30.66 ± 4.17	29.74 ± 4.04	0.232			
	Nasal	32.09 ± 6.21	31.89 ± 4.78	31.48 ± 6.02	0.456			
	Temporal	28.23 ± 4.36	29.90 ± 3.69	27.60 ± 2.35	**< 0.001**	0.652	**< 0.001**	**0.001**
ONL	Center	87.00 ± 14.66	85.79 ± 15.52	88.07 ± 14.09	0.761			
	Superior	59.88 ± 10.00	57.97 ± 9.50	62.40 ± 8.75	**0.016**	0.125	**0.004**	0.180
	Inferior	57.79 ± 9.45	58.54 ± 9.68	61.36 ± 8.53	0.078			
	Nasal	60.18 ± 10.37	60.32 ± 9.75	63.31 ± 9.14	0.151			
	Temporal	62.84 ± 7.96	63.06 ± 7.33	65.70 ± 6.78	**0.026**	**0.027**	**0.015**	0.759
RPE	Center	16.40 ± 1.49	16.57 ± 2.21	16.48 ± 1.71	0.971			
	Superior	13.98 ± 1.40	14.41 ± 1.27	13.97 ± 1.27	0.129			
	Inferior	13.63 ± 1.27	13.94 ± 1.38	13.59 ± 1.33	0.276			
	Nasal	13.70 ± 1.25	14.05 ± 1.34	13.85 ± 1.39	0.280			
	Temporal	13.62 ± 1.08	14.34 ± 1.69	13.53 ± 1.11	**0.015**	0.810	**0.009**	**0.017**
IPL	Center	18.28 ± 4.39	19.12 ± 3.98	18.67 ± 3.18	0.616			
	Superior	36.30 ± 4.06	35.09 ± 3.70	36.41 ± 3.05	0.065			
	Inferior	35.94 ± 2.73	35.31 ± 3.23	35.84 ± 3.10	0.336			

Layers		NoDR	NPDR	Control	P	Post hoc results between groups		
						P^1	P^2	P^3
	Nasal	35.99 ± 3.28	35.43 ± 3.15	36.25 ± 3.09	0.274			
	Temporal	36.86 ± 3.13	36.41 ± 3.73	36.52 ± 2.98	0.745			
INL	Center	18.55 ± 6.72	21.24 ± 6.86	16.62 ± 5.69	**0.001**	0.192	**< 0.001**	**0.013**
	Superior	38.12 ± 3.12	38.09 ± 3.61	37.96 ± 2.56	0.957			
	Inferior	34.10 ± 2.67	33.57 ± 4.05	34.35 ± 2.54	0.574			
	Nasal	38.41 ± 4.69	40.54 ± 5.07	37.21 ± 3.65	**< 0.001**	0.454	**< 0.001**	**0.037**
	Temporal	36.27 ± 3.26	37.22 ± 4.15	35.77 ± 2.28	**0.017**	0.432	**0.004**	0.073
MD		-2.37 ± 1.75	-3.04 ± 1.27	-0.86 ± 1.50	**< 0.001**	**< 0.001**	**< 0.001**	**0.002**

P: p-value between NoDR, NPDR and control measurements using ANOVA.

P^1: p-value of NoDR versus control, P^2: p-value of NPDR versus control, P^3: p-value of NoDR versus NPDR.

Table 3 summarizes the diagnostic performance of retinal and visual field parameters in distinguishing individuals with diabetes from non-diabetic controls.

Table 3
Predictive performance of retinal layers and visual field parameters for pairwise comparisons among controls, NoDR and NPDR participants.

Groups	Layers	AUC ± SE	CI for AUC	Sensitivity at 80% specificity	Sensitivity at 95% specificity
Control and NoDR	Retina	0.495 ± 0.054	0.388–0.601	13.8%	7.6%
	NFL	0.514 ± 0.054	0.408–0.619	16.1%	0.0%
	GCL	0.519 ± 0.054	0.413–0.624	27.6%	6.9%
	OPL	0.441 ± 0.053	0.336–0.545	15.5%	0.0%
	ONL	0.511 ± 0.053	0.405–0.617	19.0%	6.9%
	RPE	0.512 ± 0.054	0.407–0.618	20.7%	7.0%
	IPL	0.538 ± 0.054	0.432–0.643	24.1%	6.9%
	INL	0.430 ± 0.054	0.326–0.534	12.1%	1.9%
	MD	**0.766 ± 0.044**	**0.680–0.853**	69.0%	29.3%
Control and NPDR	Retina	0.438 ± 0.054	0.332–0.545	10.3%	3.4%
	NFL	0.500 ± 0.054	0.394–0.607	15.5%	0.0%
	GCL	0.521 ± 0.054	0.415–0.626	22.5%	3.4%
	OPL	0.353 ± 0.051	0.253–0.454	8.6%	0.0%
	ONL	0.542 ± 0.055	0.435–0.649	19.0%	8.6%
	RPE	0.509 ± 0.055	0.402–0.616	20.7%	5.2%
	IPL	0.488 ± 0.054	0.383–0.594	13.8%	5.2%
	INL	0.302 ± 0.048	0.207–0.396	8.6%	1.7%

Groups	Layers	AUC ± SE	CI for AUC	Sensitivity at 80% specificity	Sensitivity at 95% specificity
	MD	**0.876 ± 0.033**	**0.811–0.941**	81%	65.5%
NoDR and NPDR	Retina	0.451 ± 0.054	0.346–0.556	12.1%	5.2%
	NFL	0.495 ± 0.054	0.389–0.602	19.0%	5.2%
	GCL	0.498 ± 0.054	0.392–0.604	22.4%	1.7%
	OPL	0.421 ± 0.053	0.316–0.526	13.8%	5.2%
	ONL	0.523 ± 0.054	0.416–0.629	17.2%	10.3%
	RPE	0.505 ± 0.054	0.399–0.612	19%	1.7%
	IPL	0.449 ± 0.054	0.344–0.554	12.1%	1.7%
	INL	0.376 ± 0.052	0.266–0.468	10.3%	3.4%
	MD	**0.665 ± 0.051**	**0.565–0.764**	43.1%	19%

AUC: Area under curve, CI: Confidence interval.

In the comparison between NoDR and NPDR, the MD emerged as the most effective discriminator, with an AUC of 0.665 with a 95% CI as 0.565–0.764. Similarly, MD was identified as a statistically significant discriminator for distinguishing controls from NPDR, with an AUC of 0.876 (95% CI: 0.811–0.941). Furthermore, MD demonstrated good diagnostic utility in differentiating controls from NoDR, with an AUC of 0.766 (95% CI: 0.680–0.853). These comparisons are illustrated in Fig. 1.

Discussion

We evaluated the diagnostic performance of visual field parameters and seven individual retinal layers, as well as total retinal thickness, in pairwise comparisons across different stages of diabetic retinopathy severity. Additionally, we investigated whether OCT-derived retinal thickness measurements and perimetric MD could differentiate individuals with diabetic retinopathy from those without retinopathy and from non-diabetic controls.

Our findings demonstrate that SD-OCT can detect significant thinning of the temporal NFL and ONL in eyes of diabetic patients without clinically detectable diabetic retinopathy compared with healthy

controls, potentially indicating early structural loss of involving ganglion cell bodies and their dendritic processes. Furthermore, when comparing patients with mild NPDR to those without DR (NoDR), significant differences were observed in the nasal GCL, nasal and temporal NFL, temporal OPL, RPE and INL.

Numerous previous studies have investigated total retinal thickness or the thickness of specific retinal layers in individuals with diabetes. Van Dijk et al, reported significant thinning of the pericentral ganglion cell layer and the peripheral retinal nerve fiber layer in patients with mild diabetic retinopathy, whereas no comparable changes were observed in diabetic patients without retinopathy; however, these findings were derived from relatively small sample size [9, 10]. Similarly, studies by Chen Y et al and Demir et al, indicated reduced RNFL and GCL thicknesses in patients with type 2 diabetes compared with healthy controls, although these differences did not reach statistical significance [11, 12] Jay Chhablani et al, identified early thinning of the ganglion cell complex [13] and Vujosevic et al, reported reduced RNFL thickness in patients with type 2 diabetes without clinically detectable microvascular signs of diabetic retinopathy [14]. Additionally, Tavares Ferreira J et al, observed a generalized reduction in retinal thickness—predominantly affecting the inner retinal layers—in diabetic patients without retinopathy after one year of follow-up [15].

In comparison with these earlier investigations, the present study also identified significant differences in outer retinal layer thickness among the three study groups. These discrepancies may be attributable to methodological differences across studies, including variation in SD-OCT scanning protocols, definitions of outer retinal boundaries, and segmentation algorithms used for retinal thickness measurement [16].

The observed thinning of the INL further supports the increasingly accepted concept that alterations in the retinal neurovascular unit play a critical role in the pathogenesis of diabetes. Neural apoptosis and retinal neurodegeneration are believed to occur at the very early stages of diabetic retinopathy, even before the appearance of clinically detectable microvascular changes [17].

We also investigated whether OCT-derived parameters, including total retinal and inner retinal thickness, could discriminate diabetic patients with DR from and diabetic patients without DR and from non-diabetic controls. Sensitivity was evaluated at fixed specificity levels of 80% and 95% [18]. Although high sensitivity is desirable for disease detection—maximizing the identification of affected individuals—it is often accompanied by an increased false-positive rate, potentially leading to unnecessary follow-up examinations in healthy subjects. Our results indicate that retinal thickness measurements exhibit limited to poor diagnostic performance in distinguishing individuals with DR from those without DR and from non-diabetic controls. A plausible explanation is that majority of participants in the present study had mild DR. In contrast, OCT-derived retinal metrics appear to demonstrate greater discriminative ability in moderate to advanced stages disease, a finding that is consistent with the results reported by Srinivasan et al [18].

The mean deviation (MD) of the visual field reflected changes in retinal photosensitivity, with a reduction of 1 dB in MD corresponding to approximately a 10% decrease in visual function. The result of present study demonstrate that MD values progressively increase with advancing disease severity across all study groups, indicating a gradual decline in visual function as diabetic retinopathy worsens. Notably, alterations in visual field parameters were detected in diabetic patients prior to the appearance of clinically evident fundus lesions. All fundus abnormalities associated with diabetic retinopathy have the potential to affect visual field MD, and similar findings have been reported in previous studies [19, 20].

In present study, visual field measurements are reported only as the mean value across the entire retina.

Consequently, precise anatomical correlations between localized retinal lesions and corresponding visual field defects could not be established, limiting the ability to link structural abnormalities to focal functional loss. In this context, optical coherence tomography (OCT) may serve as a complementary modality by providing detailed structural information. Despite this limitation, MD demonstrated good diagnostic performance, with a sensitivity of 69% and specificity of 80% for distinguishing NoDR patients from controls, and a sensitivity of 81% and specificity of 80% for differentiating NPDR patients from controls. The observed increase in MD, accompanied by diffuse sensitivity loss, suggests the presence of early neural alterations in diabetic eye disease [21, 22].

One of our study limitation is that, axial length measurements were not recorded, which may have introduced minor ocular magnification–related bias in the OCT assessments. However, the exclusion of participants with significant refractive errors (spherical equivalent ≥ ± 3.00 D and astigmatism ≥ 2.00 D) likely reduced the magnitude of this potential bias and its impact on the study findings.

In summary, patients with mild or no DR may exhibit substantial and diffuse visual field sensitivity losses, for which mean deviation represents an optimal index of global sensitivity. These findings are consistent with previous studies [23, 24] and support the expansion of diabetic eye disease classification to include neural abnormalities, therefore offering a functional approach for identifying early neural dysfunction affected individuals.

Statements and Declarations

Ethical considerations

This prospective cross-sectional research was reviewed and approved by an independent ethical review board and was conducted according to the Tenets of Declaration of Helsinki for the protection of human subjects in biomedical research (ethics approval code: IR.MUMS.FHMPM.REC.1403.159). Written informed consent was provided by all participants. Patients signed informed consent regarding publishing their data.

Conflict of interest

All authors disclose no financial or non-financial interests that are directly or indirectly related to this work.

Funding

There was no funding to declared.

Data availability

The data that support the findings of this study are not openly available due to reasons of sensitivity and are available from the corresponding author upon reasonable request.

Acknowledgement

This work was supported by Mashhad University of Medical Sciences (Grant code: 4030709). The authors declare no financial disclosure and report no conflicts of interest.

References

1. Yau JW, Rogers SL, Kawasaki R, Lamoureux EL, Kowalski JW, Bek T, et al. Global prevalence and major risk factors of diabetic retinopathy. Diabetes care. 2012; https://doi.org/10.2337/dc11-1909
2. Duh EJ, Sun JK, Stitt AW. Diabetic retinopathy: current understanding, mechanisms, and treatment strategies. JCI insight. 2017; http://doi.org/10.1172/jci.insight.93751
3. Huang D, Swanson EA, Lin CP, Schuman JS, Stinson WG, Chang W, et al. Optical coherence tomography. Science. 1991; http://doi.org/10.1126/science.1957169
4. Mohammed S, Li T, Chen XD, Warner E, Shankar A, Abalem MF, et al. Density-based classification in diabetic retinopathy through thickness of retinal layers from optical coherence tomography. Scientific Reports. 2020; https://doi.org/10.1038/s41598-020-72813-x
5. Jiang J, Liu Y, Chen Y, Ma B, Qian Y, Zhang Z, et al. Analysis of changes in retinal thickness in type 2 diabetes without diabetic retinopathy. J Diabetes Res. 2018; https ://doi.org/10.1155/2018/3082893
6. Sng CCA, Cheung CY, Man RE, Wong W, Lavanya R, Mitchell P, Wong TY. Influence of diabetes on macular thickness measured using optical coherence tomography: the Singapore Indian Eye Study. Eye. 2012; https://doi.org/10.1038/eye.2012.11
7. Somfai GM, Gerding H, DeBuc DC. The use of optical coherence tomography for the detection of early diabetic retinopathy. Klinische Monatsblätter für Augenheilkunde. 2018; http://doi.org/10.1055/s0044-101827
8. Yang C, Zhou C. Observation on the changes of visual field and optic nerve fiber layer thickness in patients with early diabetic retinopathy. Photodiagnosis and Photodynamic Therapy. 2024; https://doi.org/10.1016/j.pdpdt.2024.104197

9. Van Dijk HW, Verbraak FD, Kok PH, Garvin MK, Sonka M, Lee K, et al. Decreased retinal ganglion cell layer thickness in patients with type 1 diabetes. IOVS. 2010; http://doi.org/ 10.1167/iovs.09-5041
10. Van Dijk HW, Verbraak FD, Kok PH, Stehouwer M, Garvin MK, Sonka M, et al. Early neurodegeneration in the retina of type 2 diabetic patients. IOVS. 2012; http://doi.org/10.1167/iovs.118997
11. Chen Y, Li J, Yan Y, Shen X. Diabetic macular morphology changes may occur in the early stage of diabetes. BMC ophthalmology. 2016; https://doi.org/10.1186/s12886-016-0186-4
12. Demir M, Oba E, Sensoz H, Ozdal E. Retinal nerve fiber layer and ganglion cell complex thickness in patients with type 2 diabetes mellitus. *Indian journal of ophthalmology*. 2014; http://doi.org/10.4103/0301-4738.136234
13. Chhablani J, Sharma A, Goud A, Peguda HK, Rao HL, Begum VU, Barteselli G. Neurodegeneration in type 2 diabetes: evidence from spectral-domain optical coherence tomography. IOVS. 2015; http://doi.org/ 10.1167/iovs.15-17334
14. Vujosevic S, Midena E. Retinal layers changes in human preclinical and early clinical diabetic retinopathy support early retinal neuronal and Müller cells alterations. Journal of diabetes research. 2013; http://doi.org/ 10.1155/2013/905058
15. Ferreira JT, Alves M, Dias-Santos A, Costa L, Santos BO, Cunha JP, Pinto LA. Retinal neurodegeneration in diabetic patients without diabetic retinopathy. IOVS. 2016; http://doi.org/10.1167/iovs.16-20215
16. Wolf-Schnurrbusch UE, Ceklic L, Brinkmann CK, Iliev ME, Frey M, Rothenbuehler SP, et al. Macular thickness measurements in healthy eyes using six different optical coherence tomography instruments. IOVS. 2009. http://doi.org/ 10.1167/iovs.08-2970
17. Hernández C, Bogdanov P, Corraliza L, García-Ramírez M, Solà-Adell C, Arranz JA, et al. Topical administration of GLP-1 receptor agonists prevents retinal neurodegeneration in experimental diabetes. Diabetes. 2016; https://doi.org/10.2337/db15-0443
18. Srinivasan S, Pritchard N, Sampson GP, Edwards K, Vagenas D, Russell AW, et al. Diagnostic capability of retinal thickness measures in diabetic peripheral neuropathy. Journal of optometry. 2017; https://doi.org/10.1016/j.optom.2016.05.003
19. Yang C, Zhou C. Observation on the changes of visual field and optic nerve fiber layer thickness in patients with early diabetic retinopathy. Photodiagnosis and Photodynamic Therapy. 2024; https://doi.org/10.1016/j.pdpdt.2024.104197
20. Ozates S, Simsek M, Elgin U, Keskin M, Aycan Z. Early visual field changes in patients with type 1 diabetes mellitus. European Journal of Ophthalmology. 2020; https://doi.org/10.1177/1120672119872896
21. Sabeti F, van Kleef JP, Iyer RM, Carle CF, Nolan CJ, Chia RH, Maddess T. Discriminating early-stage diabetic retinopathy with subjective and objective perimetry. Frontiers in Endocrinology. 2024; https://doi.org/10.3389/fendo.2023.1333826
22. McAnany JJ, Park JC, Lim, JI. Visual field abnormalities in early-stage diabetic retinopathy assessed by chromatic perimetry. IOVS. 2023; http://doi.org/10.1167/iovs.64.2.8

23. Abramoff MD, Fort PE, Han IC, Jayasundera KT, Sohn EH, Gardner TW. Approach for a clinically useful comprehensive classification of vascular and neural aspects of diabetic retinal disease. IOVS. 2018; https://doi.org/10.1167/iovs.17-21873
24. Sun JK, Aiello LP, Abràmoff MD, Antonetti DA, Dutta S, Pragnell M, Gardner TW. Updating the staging system for diabetic retinal disease. Ophthalmology. 2020; http://doi.org/10.1016/j.ophtha.2020.10.008

Figures

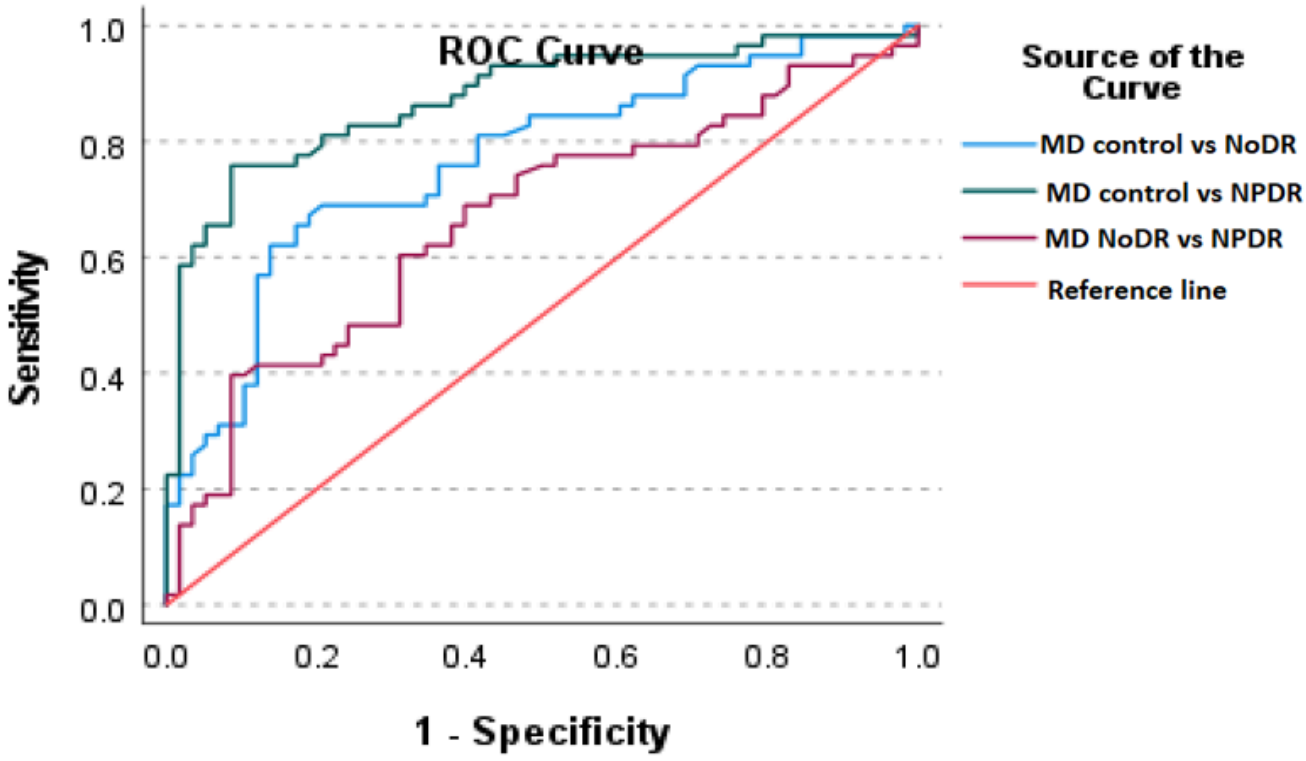

Figure 1

ROC curve for MD compared in three pairwise groups (control vs NoDR, control vs NPDR and NoDR vs NPDR).