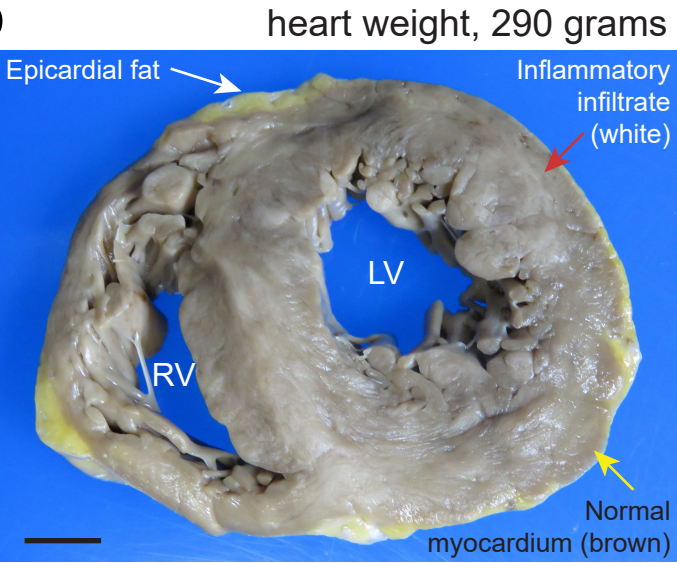


# Extended Data Figure 1

a

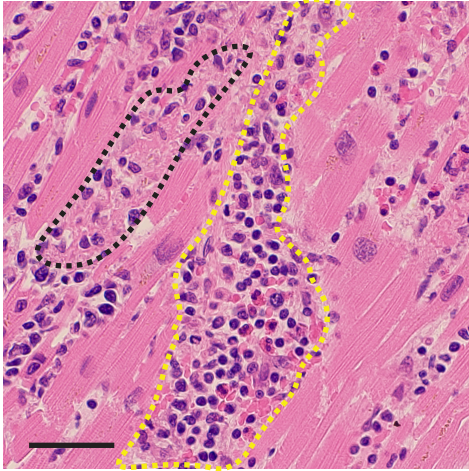
Clinical vignette:  
A 35 year-old healthy Hispanic woman, 3 months postpartum, died suddenly at home following one week of mild viral syndrome signs and symptoms that included lightheadedness. Postmortem nasal swab confirmed acute SARS-CoV-2 infection by RT-PCR and serology demonstrated anti-spike glycoprotein IgG antibodies. At autopsy, the medical examiner discovered fulminant lymphocytic myocarditis with mild congestive heart failure but no pneumonia. Cause of death: arrhythmia.

b



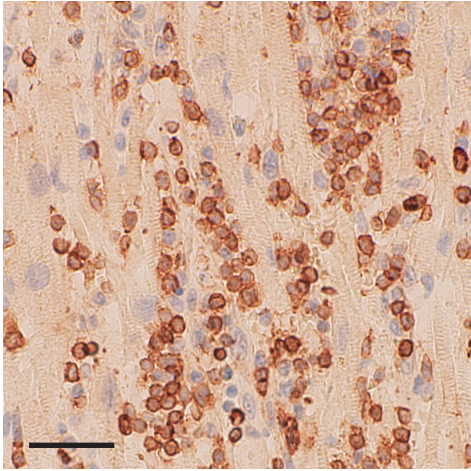
c

H&E



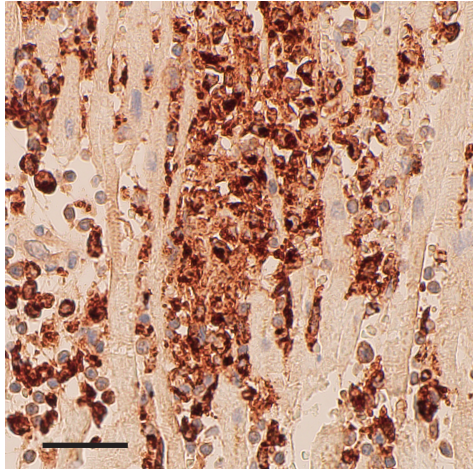
d

CD3



e

CD68



f

Nucleocapsid MYL2 DAPI

