Research Square

Preprints are preliminary reports that have not undergone peer review.
They should not be considered conclusive, used to inform clinical practice,
or referenced by the media as validated information.

Nonresponse to Intravitreal Anti-VEGF Therapy for Retinopathy of Prematurity: Clinical Characteristics and Outcomes After Retreatment

Monisha Apte
L V Prasad Eye Institute
Souvik Bhunia
L V Prasad Eye Institute
Tapas Ranjan Padhi
tapaspadhi254@gmail.com

L V Prasad Eye Institute
Suman Sahu
L V Prasad Eye Institute
Ratnabali Mishra
L V Prasad Eye Institute
Taraprasad Das
L V Prasad Eye Institute
Subhadra Jalali
L V Prasad Eye Institute

Research Article

Keywords: Retinopathy of prematurity (ROP), Intravitreal injection, No response, Anti-vascular endothelial growth factor

Posted Date: September 24th, 2026

DOI: https://doi.org/10.21203/rs.3.rs-9489907/v1

License: This work is licensed under a Creative Commons Attribution 4.0 International License. Read Full License

Additional Declarations: No competing interests reported.

Abstract

Purpose.

To describe the incidence, clinical characteristics, suspected causes, and outcomes of eyes with nonresponse to intravitreal anti-vascular endothelial growth factor (anti-VEGF) therapy for retinopathy of prematurity (ROP).

Methods.

Retrospective observational case series of infants treated with intravitreal anti-VEGF for ROP between 2014 and 2023 at a tertiary eye care center in eastern India. Nonresponse was defined as absence of improvement in plus disease and/or ridge activity within 3–5 days after injection. Demographic profile, systemic status, ROP characteristics, treatment details, retreatment, and final outcomes were analyzed.

Results.

Among 1401 eyes of 726 infants treated with intravitreal anti-VEGF, 8 eyes of 6 infants showed nonresponse (0.57%). Baseline disease included aggressive ROP in posterior zone I (6 eyes), zone I disease (1 eye), and threshold zone II ROP (1 eye). Initial agents were bevacizumab (5 eyes) and ranibizumab or biosimilar ranibizumab (3 eyes). Factors considered potentially contributory included severe posterior disease, technical limitations in drug preparation or delivery, preretinal hemorrhage, and poor systemic condition. Retreatment included laser photocoagulation (6 eyes), repeat bevacizumab (1 eye), and combined repeat bevacizumab with laser (1 eye). Following retreatment, complete regression occurred in 7 eyes and regression with residual sequelae in 1 eye.

Conclusion.

Nonresponse to anti-VEGF therapy in ROP was uncommon. It was more frequently observed in severe posterior disease and clinically challenging treatment settings. Early recognition and timely retreatment, most commonly with laser photocoagulation, were associated with favorable anatomical outcomes in most eyes.

Introduction

Intravitreal anti–vascular endothelial growth factor (anti-VEGF) therapy has become an established treatment option for retinopathy of prematurity (ROP) because of its ability to induce rapid regression of plus disease and neovascular activity [1]. By neutralizing VEGF present within the vitreous cavity, these agents often produce prompt clinical improvement. However, they do not eliminate the avascular peripheral retina, which remains a source of ongoing VEGF production; consequently, disease recurrence may occur and necessitates close follow-up and, at times, retreatment.

In contrast to recurrence after initial regression, primary nonresponse following intravitreal anti-VEGF therapy has been infrequently reported, and limited evidence is available to guide management in such cases.

Methodology

The present study aimed to analyse the incidence, clinical characteristics, possible contributing factors, and outcomes of eyes showing nonresponse to intravitreal anti-VEGF therapy for ROP at a tertiary eye care centre in Eastern India linked to multiple neonatal care facilities

over a 10-year period. The study adhered to the tenets of the Declaration of Helsinki and was approved by the institutional ethics committee (2014-29-IM-6). Informed consent for off-label intravitreal use of bevacizumab or ranibizumab biosimilars and anonymized data use had been obtained according to institutional protocol.

The institutional ROP database, which prospectively records demographic, clinical, treatment, and follow-up details of infants managed for ROP, was reviewed to identify infants who showed nonresponse to intravitreal anti-VEGF therapy and had a minimum follow-up of 6 weeks.

A favorable early response was defined as regression of tunica vasculosa lentis, improved pupillary dilatation, reduction in retinal vascular tortuosity or neovascular activity, and/or vascular progression toward the peripheral retina [2]. Nonresponse was defined as absence of improvement in plus disease and/or ridge activity within 3–5 days after injection [3].

All diagnoses and classifications of ROP were based on the third edition of the International Classification of Retinopathy of Prematurity (ICROP) [4].

Treatment Protocol and Follow-up

In this cohort, all but one infant received the first intravitreal injection at the bedside in a neonatal care facility, while one infant underwent treatment under an operating microscope in the operating room. A half-adult dose was used for both bevacizumab and ranibizumab biosimilar. When both eyes required treatment, injections were administered sequentially on the same day.

The treatment protocol was standardized. Intravitreal injections were administered by an ROP-trained retina specialist/vitreoretinal fellow or by a general ophthalmologist trained in ROP injections. On the day of treatment, the anti-VEGF agent was transported under cold-chain conditions, either in prefilled syringes or in a vial, maintaining a temperature of 4–8°C as per institutional protocol. An injection carrier box containing five ice packs (one along each wall and one at the base) maintained the required temperature for up to 8 hours (unpublished observation). The drug was removed from the cold chain and allowed to reach room temperature for at least 30 minutes before use.

The procedure was performed on the warmer bed with continuous pulse oximeter monitoring and supervision by a neonatal nurse/neonatologist. Pupillary dilatation was achieved using 2.5% phenylephrine and 0.5% tropicamide. All procedures were done under topical anaesthesia without sedation. The infant was immobilized in fresh sterile linen, with a rolled linen support forming a U-shaped gutter around the head. Topical proparacaine 0.5% was instilled, and 5% povidone-iodine eye drops were applied before and after injection. Standard aseptic precautions, including head cap, face mask, scrubbing, and no-touch gloving, were followed separately for each eye. Ocular surface preparation included cleansing with 5% povidone-iodine, drying, and sterile draping.

Each eye was prepared and injected separately using different instruments and materials. Illumination was provided by the surgeon's head-mounted indirect ophthalmoscope. The assisting nurse inserted the speculum and isolated the eyelashes from the injection field, while another assistant stabilized the infant's face and chin under the drape. Injections were delivered with a 29-gauge needle, 1 mm posterior to the limbus, parallel to the visual axis, with approximately half the needle hub entering the globe. Following injection, digital massage was applied with sterile gauze to soften the globe, and a final application of 5% povidone-iodine completed the procedure. No topical antibiotics were prescribed, and eye shields were applied for 3 hours as per institutional protocol. For infants treated in the ophthalmic facility, the same preparation was followed, and injections were given under direct microscopic visualization.

After treatment, infants were reviewed on day 1, weekly for the first month, and thereafter every 2–4 weeks until complete regression or disease reactivation. [5]

Top of Form

Bottom of Form

Data Collection and Analysis

Collected variables included gestational age, birth weight, systemic comorbidities, ROP zone and stage, postmenstrual age at treatment, anti-VEGF agent used, treatment setting, injector experience, retreatment modality, and final anatomical outcome. Clinical records, treatment notes, and available fundus images were reviewed to assess response and identify possible contributory factors for nonresponse. Data were entered into a spreadsheet and analysed using descriptive statistics.

Results

A total of 726 consecutive infants (1401 eyes) received intravitreal anti-VEGF therapy for ROP during the study period. Six infants (8 eyes) met the predefined criteria for nonresponse, corresponding to an incidence of 0.57%. The clinical characteristics, details of initial treatment, type of non-response, timing and the details of retreatment, the follow-up duration, probable causes of nonresponse, and finally, the outcome of eyes showing no response are shown in *Table 1*. There were 4 males and 2 females. The mean gestational age and birth weights were 30.24 ± 2.80 weeks and 1261.11 ± 299.11g, respectively. The mean post-menstrual age at the first injection was 34.08 ± 1.35 weeks. On average, the follow-up period was 87.68 (19.6-176) weeks.

Clinical details and outcomes are summarized in *Table 1*. The cases included unilateral nonresponse with contralateral regression (Figure 1), worsening plus disease with neovascularization requiring prompt laser treatment, and delayed regression after repeat anti-

VEGF therapy. Six of 8 eyes (75%) had aggressive ROP in posterior zone I, 1 eye had zone I disease, and 1 eye had threshold zone II disease. Initial treatment was bevacizumab in 5 eyes and ranibizumab or biosimilar ranibizumab in 3 eyes. Most injections were performed at the bedside in neonatal care facilities. The final outcome was favourable in 7 of 8 eyes *Table 1*. Retreatment was individualized according to disease severity, ocular findings, and systemic condition. This included laser photocoagulation in 6 eyes, repeat bevacizumab in 1 eye, and combined repeat bevacizumab with laser in 1 eye. At final follow-up, complete regression was achieved in 7 eyes. One eye showed regression with residual tractional sequelae. Overall, anatomical outcome was favorable in most eyes.

Chart review suggested several potential contributory factors, including severe posterior avascular retina, technical challenges related to dose preparation or intravitreal delivery, ocular hemorrhage, and persistent systemic instability. In some infants with bilateral symmetrical disease, nonresponse occurred in only one eye. The technical issues in delivering the first injection, probably related to being injected at the bedside in a neonatal care facility in a compromised situation, and also at times by an ROP trainee. There were some cases where the disease responded partially to a repeat injection and needed additional lasers. We suspected technical issues in aliquoting a smaller amount of drug or faulty delivery of drug (subconjunctival/ intrascleral) during the 1st injection.

The observed frequency of nonresponse was numerically higher among eyes treated with ranibizumab/ranibizumab biosimilar (3/20 eyes; 15.0%) than among those treated with bevacizumab (5/1380 eyes; 0.36%); however, the small sample size precluded meaningful comparative analysis.

Discussion

Anti-VEGF agents have gained rapid popularity in the management of ROP.[6] By rapidly neutralizing VEGF already present within the vitreous cavity, they often produce a prompt and dramatic response in VEGF-driven diseases such as ROP. [7,8] However, they do not directly address the continued production of VEGF from the persistent avascular retina. In some eyes, particularly those with posterior zone I disease, the extent of avascular retina may be disproportionately large relative to the vascularized retina. We hypothesize that, in such severe disease, a modest reduction in disease activity after a single anti-VEGF injection may be insufficient to produce a clinically recognizable response.

There is still no universal consensus regarding the optimal anti-VEGF dose for ROP. In an effort to minimize systemic exposure, progressively lower doses have been adopted. However, ultra-low doses may occasionally fail to achieve an intravitreal concentration sufficient to neutralize VEGF effectively, potentially resulting in an inadequate clinical response.

Infants with rapidly progressive, treatment-requiring ROP are often medically unstable and may remain admitted in the NICU, necessitating bedside intravitreal injections under suboptimal conditions and sometimes without operating microscope support. The skill and experience of the treating physician are equally important. Injections delivered in compromised settings or by less experienced clinicians may result in under-delivery or incorrect site delivery of the drug. In addition, failure to maintain the cold chain during transport of aliquoted medication to peripheral centers may reduce drug potency.

Among babies with broadly comparable disease severity and systemic profiles, we observed a higher proportion of no response after intravitreal ranibizumab/ranibizumab biosimilar than after bevacizumab (for example, Case 1). This observation may relate to the longer intravitreal half-life of bevacizumab compared with ranibizumab.[9]

ROP is an ocular manifestation of prematurity and may reflect the broader systemic fragility of these infants. Persistent poor systemic health may also contribute to lack of response following anti-VEGF therapy. In this series, three major contributors to no response were identified: technical factors, poor systemic condition, and extremely posterior/severe retinopathy. These eyes may benefit from individualized retreatment strategies, including a repeat intravitreal injection administered under optimal conditions by an experienced physician, laser photocoagulation once systemic status improves, or macula-sparing laser when appropriate. Eyes showing worsening disease or progression to retinal detachment may benefit from early vitreoretinal surgery combined with laser.

Limitations

The limitations of this study include its retrospective design and small sample size. Given the low incidence of true non-response, multicenter pooled data may be valuable to better characterize risk factors, mechanisms, and optimal management strategies.

Conclusion

The present cases in the present study showing no response to the intravitreal anti-VEGFs in ROP had several associations. These include disease in posterior zone I with a severe tempo at presentation, continued poor health, atypical ROP, detachment at the presentation, use of low dose anti-VEGF, and technical issues like sub-optimal delivery of the drug or delivery at a wrong site, which were linked to no response. All of them had a favourable outcome following retreatment, including laser in the majority.

Declarations

Funding: Hyderabad Eye Research Foundation.

Though this project did not receive any direct support, the ROP Program has been supported by various organisations from time to time, including Cognizant Foundation, Miriam Hyman Memorial Trust, Newborn Eye Health Alliance, National Health Mission, and Rashtriya Bal Swasthya Karyakram, Odisha.

Competing interests: The authors have no relevant financial or non-financial interests to disclose

Author contributions: All authors contributed to the study conception and design. Material preparation, data collection and analysis were performed by Monisha Apte, Souvik Bhunia, Ratnabali Mishra and Tapas Ranjan Padhi. The first draft of the manuscript was written by Monisha Apte and Tapas Ranjan Padhi and all authors commented on previous versions of the manuscript. All authors have read and approved the final manuscript.

References

1. Gangwe A, Agrawal D, Vinekar A, Azad RV, Parchand SM, Agrawal D (2021) Anti-vascular endothelial growth factor in the management of retinopathy of prematurity: a survey among the members of Indian Retinopathy of Prematurity Society. Indian J Ophthalmol 69:2158-2163. https://doi.org/10.4103/ijo.IJO_200_21.
2. Wallace DK, Dean TW, Hartnett ME, Kong L, Smith LE, Hubbard GB, et al (2018) A dosing study of bevacizumab for retinopathy of prematurity: late recurrences and additional treatments. Ophthalmology 125:1961-1966. https://doi.org/10.1016/j.ophtha.2018.05.001.
3. Chuluunbat T, Chan RV, Wang NK, Lien R, Chen YP, Chao AN, et al (2016) Nonresponse and recurrence of retinopathy of prematurity after intravitreal ranibizumab treatment. Ophthalmic Surg Lasers Imaging Retina 47:1095-1105. https://doi.org/10.3928/23258160-20161130-03.
4. Chiang MF, Quinn GE, Fielder AR, Ostmo SR, Chan RV, Berrocal A, et al (2021) International Classification of Retinopathy of Prematurity, Third Edition. Ophthalmology 128: e51-e68. https://doi.org/10.1016/j.ophtha.2021.05.031.
5. Padhi TR, Das T, Rath S, Pradhan L, Sutar S, Panda KG, et al (2016) Serial evaluation of retinal vascular changes in infants treated with intravitreal bevacizumab for aggressive posterior retinopathy of prematurity in zone I. Eye (Lond) 30:392-399. https://doi.org/10.1038/eye.2015.240.
6. Travassos A, Teixeira S, Ferreira P, Regadas I, Travassos AS, Esperancinha FE, et al (2007) Intravitreal bevacizumab in aggressive posterior retinopathy of prematurity. Ophthalmic Surg Lasers Imaging 38:233-237. https://doi.org/10.3928/15428877-20070501-09.
7. Mintz-Hittner HA, Kennedy KA, Chuang AZ (2011) Efficacy of intravitreal bevacizumab for stage 3+ retinopathy of prematurity. N Engl J Med 364:603-615. https://doi.org/10.1056/NEJMoa1007374.
8. Huang Q, Zhang Q, Fei P, Xu Y, Lyu J, Ji X, et al (2017) Ranibizumab injection as primary treatment in patients with retinopathy of prematurity: anatomic outcomes and influencing factors. Ophthalmology 124:1156-1164. https://doi.org/10.1016/j.ophtha.2017.03.018.

Table

Table 1: Clinical profile and outcomes of babies with no response to initial anti-VEGF therapy

Baby No.	Baseline ROP	Initial drug	PMA at injection (weeks)	Response pattern	Retreatment (timing, weeks)	Final outcome	Follow-up (weeks)	Suspected factor
1	A-ROP, posterior zone I, BE	Ranibizumab biosimilar	34.5	RE: regression then reactivation; LE: no initial response with NV	LE laser (36.5); LE ranibizumab biosimilar (39.2); RE laser (40.6)	Complete regression in BE	68.3	Posterior location/severe disease; possible reduced efficacy
2	A-ROP, zone I, BE	Bevacizumab	32.2	RE: no response with NV, TVL, FVP; LE: regression	RE bevacizumab (35.3); RE laser (36.4)	Complete regression in BE	22.1	Possible technical issue in drug delivery
3	A-ROP, posterior zone I, BE	Bevacizumab	33.4	RE: no response, worsened to threshold ROP; LE: regression	RE bevacizumab (36.0)	Regressing at last visit in BE	19.6	Possible technical issue in drug delivery
4	A-ROP, posterior zone I, BE	Bevacizumab	35.2	BE: no response with NV	Laser (36.3)	Complete regression in BE	86.5	Posterior location and severe disease
5	A-ROP, posterior zone I, BE	Ranibizumab	33.0	BE: no response with NV	Laser (35.3)	Complete regression in BE	153.3	Possible technical issue in drug dilution
6	Threshold ROP, zone II, BE	Bevacizumab	36.2	RE: regression; LE: no response with FVP and vitreous hemorrhage	LE bevacizumab (55.2)	Complete regression in RE; settling TRD in LE	176.0	Severe disease

Abbreviations: A-ROP, aggressive retinopathy of prematurity; BE, both eyes; RE, right eye; LE, left eye; NV, neovascularization; TVL, tunica vasculosa lentis; FVP, fibrovascular proliferation; TRD, tractional retinal detachment; PMA, postmenstrual age.

Figures

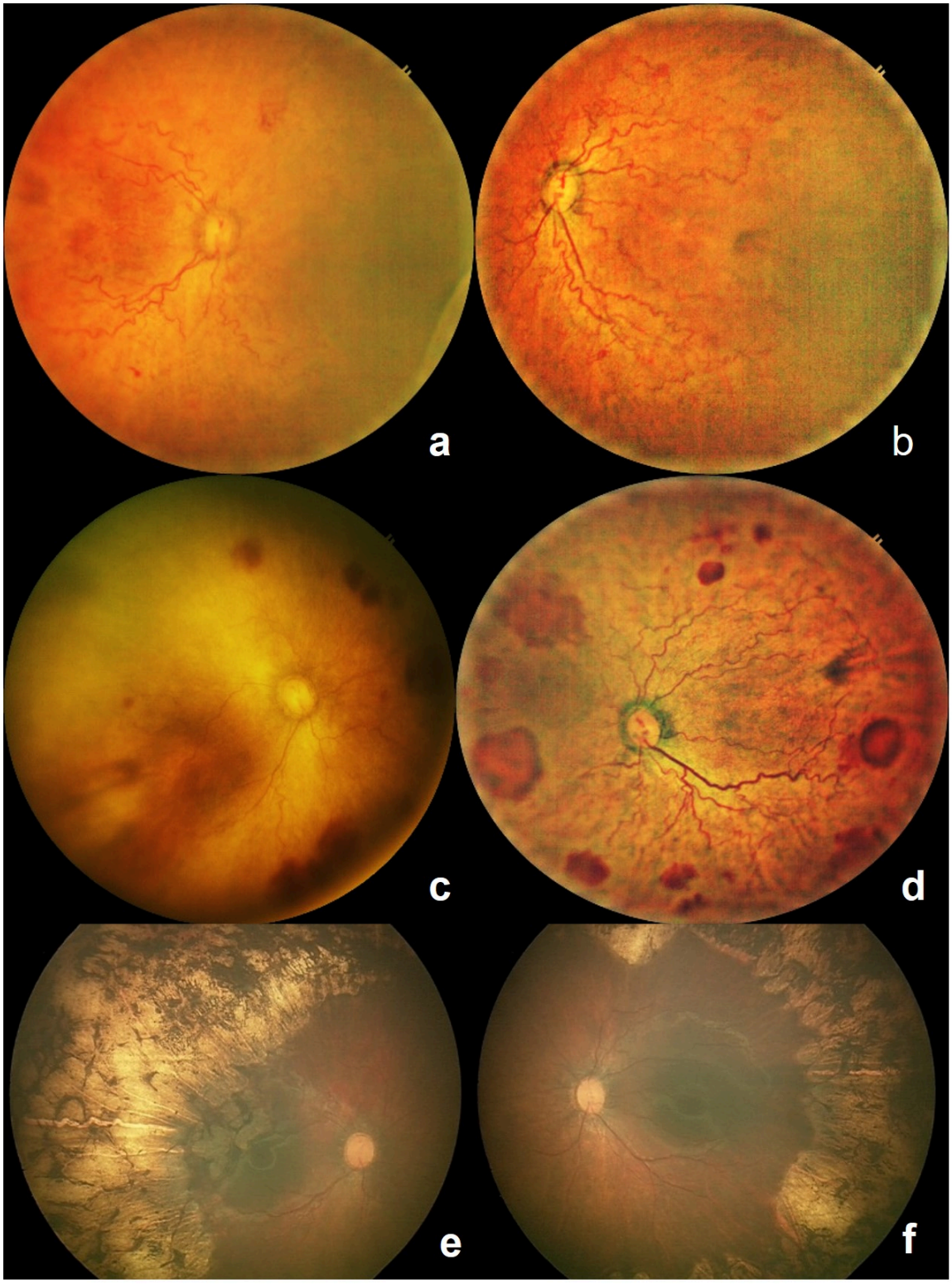

Figure 1

Composite fundus photographs of an infant with aggressive retinopathy of prematurity (A-ROP) demonstrating baseline findings, lack of response after initial anti-VEGF therapy in the left eye, and regression after retreatment. The infant was born at 30 weeks' gestation with a birth weight of 1050 g and was diagnosed with posterior zone I A-ROP at 34–35 weeks postmenstrual age (PMA). The baby required mechanical ventilation, oxygen supplementation, and multiple blood transfusions.

(a, b) Baseline fundus images of both eyes at presentation showing posterior zone I A-ROP with marked vascular dilatation and tortuosity, multiple arteriovenous shunts, and posteriorly terminating retinal vessels close to the optic disc. Both eyes were initially treated with intravitreal ranibizumab (half adult dose).

(c) Right eye at 37 weeks PMA showing marked reduction of plus disease following treatment.

(d) Left eye showing persistent and worsening plus disease despite anti-VEGF therapy, with superficial retinal hemorrhages along the vascular-avascular junction. The left eye was treated with laser photocoagulation followed by repeat intravitreal ranibizumab for neovascularization of the iris and worsening plus disease. The right eye later developed reactivation with recurrence of plus disease and underwent laser treatment

(e) Right eye at 43 weeks PMA showing regressed ROP after laser treatment.

(f) Left eye at 43 weeks PMA showing regressed ROP following retreatment with laser.