Research Square

Preprints are preliminary reports that have not undergone peer review.
They should not be considered conclusive, used to inform clinical practice,
or referenced by the media as validated information.

Clinicopathological Characteristics and Prognosis of Marginal Zone Lymphoma with Plasmacytic Differentiation

Heng Li
Central South University
Jiayi Wang
Central South University
Hongling Peng
Central South University
Wenzhe Yan
ywzwjy8890@csu.edu.cn
Central South University

Research Article

Keywords: Marginal zone lymphoma, Plasmacytic differentiation, M protein, Progression-free survival, Prognosis

Posted Date: May 11th, 2026

DOI: https://doi.org/10.21203/rs.3.rs-9370536/v1

License: This work is licensed under a Creative Commons Attribution 4.0 International License.
Read Full License

Additional Declarations: No competing interests reported.

Abstract

Objective

To investigate the clinicopathological characteristics, immunophenotype and prognostic factors of marginal zone lymphoma with plasmacytic differentiation (MZL-PD).

Methods

This was a single-center retrospective cohort study. A total of 49 patients with MZL-PD diagnosed and treated at the Second Xiangya Hospital of Central South University from January 2010 to December 2025 were enrolled. Based on serum M protein test results, patients were divided into an M protein-positive group (30 cases) and an M protein-negative group (19 cases). Clinicopathological data were collected, and survival analysis was performed using the Kaplan-Meier method.

Results

The 49 patients included 37 cases with pathological morphological plasmacytic differentiation and 12 cases with monoclonal plasma cells detected by flow cytometry. Among the 37 patients with morphological plasmacytic differentiation, 73% showed light chain restriction confirmed by immunohistochemistry, with κ light chain restriction being more common (81.5%). Among the 12 cases where monoclonal plasma cells were detected by flow cytometry, 9 cases simultaneously had monoclonal small B lymphocytes, with 8 cases showing the same type of light chain restriction in both cell populations. The immunophenotype of plasma cells in MZL-PD (CD38 + CD138+ MUM1 + CD20- CD56- CD19+) was highly similar to that of lymphoplasmacytic lymphoma (LPL). Clinically, MZL-PD had a high proportion of primary lesions in the lung (28.6%). The bone marrow infiltration rate in the M protein-positive group was significantly higher than that in the negative group (66.7% vs 10.5%, $P < 0.01$). Survival analysis showed a median follow-up of 32.8 months for the entire group; median PFS was not reached, the 2-year PFS rate was 83.6%, and the 2-year OS rate was 96.4%. The 2-year PFS of the M protein-positive group was significantly lower than that of the negative group (78.1% vs 91.7%, $P = 0.037$), but there was no significant difference in OS between the two groups.

Conclusion

MZL with plasmacytic differentiation frequently involves the lung and exhibits a plasma cell immunophenotype similar to that of lymphoplasmacytic lymphoma, necessitating differentiation via MYD88 testing. M protein positivity serves as an adverse prognostic factor, indicating a higher risk of bone marrow infiltration and early disease progression. Identification of this subgroup is therefore of great significance for precise diagnosis and the formulation of individualized treatment strategies.

Background

Marginal zone lymphoma (MZL) is a group of indolent non-Hodgkin lymphomas originating from B lymphocytes, mainly including three subtypes: extranodal mucosa-associated lymphoid tissue lymphoma (MALT lymphoma), splenic MZL (SMZL), and nodal MZL (NMZL)(1). Although the overall prognosis of MZL is favorable, its clinical course is highly heterogeneous, and some patients still face the risk of early progression.

Plasmacytic differentiation (PD) is a common biological and pathological morphological feature of MZL, referring to the morphological differentiation of B cells into plasma cells. As tumor cells derived from post-germinal center memory B cells, B lymphoma cells can differentiate into plasma cells under microenvironmental stimulation, undergoing antibody class switching and somatic hypermutation to acquire immunoglobulin secretion capability, thereby producing monoclonal immunoglobulin (M protein) (2). In addition, the detection of monoclonal plasma cells by flow cytometry in MZL is also considered a manifestation of plasmacytic differentiation(3, 4). The probability of plasmacytic differentiation varies among MZLs at different sites; the overall incidence in MALT lymphoma is about 1/3, common in ocular adnexa(5), thyroid(6), and central nervous system(7). NMZL is about 22%-38%(8, 9); and SMZL is 21%-74%(10, 11).

Clinically, MZL with plasmacytic differentiation shares many similarities with lymphoplasmacytic lymphoma (LPL), such as both being associated with IgM monoclonal gammopathy, hence being difficult to distinguish morphologically. M protein positivity is an important clinical feature of myeloma and LPL, and can also be seen in MZL-PD. Epperla et al. confirmed through a multicenter large-sample cohort study that M protein positivity at diagnosis is significantly associated with shorter PFS in MZL patients(12). However, current research on the prognostic impact of M protein on MZL-PD is insufficient.

Based on this, this study systematically summarizes the clinicopathological characteristics of MZL-PD through 15 years of single-center case data and analyzes the impact of M protein positivity on prognosis, aiming to enrich the differential points between MZL-PD, LPL, and plasmacytoma, and to provide a basis for risk-stratified therapy.

Methods

Study Design and Subjects

This is a single-center, retrospective cohort study. Consecutive patients diagnosed with and treated for marginal zone lymphoma in the Department of Hematology, Second Xiangya Hospital of Central South University from January 2010 to December 2025 were included. Data were extracted from the electronic medical record system, including demographic characteristics, tumor burden indicators, laboratory tests, M protein detection, bone marrow examination, and treatment regimens. This study was approved by the Ethics Committee of the Second Xiangya Hospital of Central South University and followed the Declaration of Helsinki. Informed consent was waived due to the retrospective nature of the study. Serum M protein was detected by serum protein electrophoresis and confirmed by immunofixation electrophoresis at the time of diagnosis, prior to any treatment. Positivity was defined as the presence of

a monoclonal spike confirmed by immunofixation. Patients were divided into M protein-positive and M protein-negative groups accordingly.

Inclusion Criteria:

1. Pathologically confirmed diagnosis of marginal zone lymphoma according to the WHO 2022 classification of hematopoietic and lymphoid tumors; 2.Complete clinical and follow-up data; 3.Pathology report explicitly describing significant "plasmacytic differentiation" or "plasma cell differentiation" confirmed by central pathology review, or detection of monoclonal plasma cells in body fluids or bone marrow fluid via flow cytometry; 4.Divided into positive and negative groups based on M protein test results.

Exclusion Criteria:

MYD88 gene mutation positivity, or suspected diagnosis of other types of B-cell lymphomas including lymphoplasmacytic lymphoma/Waldenström macroglobulinemia, chronic lymphocytic leukemia/small lymphocytic lymphoma).

Follow-up

Efficacy was evaluated according to Lugano 2014 criteria, classified as complete response (CR), partial response (PR), stable disease (SD), and progressive disease (PD). The follow-up cut-off date was January 31, 2025. Progression-free survival (PFS) was defined as the time from treatment initiation to the first recorded disease progression, relapse, or death from any cause. Overall survival (OS) was defined as the time from treatment initiation to death from any cause.

Statistical Analysis

Statistical analysis was performed using SPSS 26.0. Categorical variables were expressed as numbers (%) and compared between groups using the Chi-square test or Fisher's exact test. Survival analysis was performed using the Kaplan-Meier method to plot survival curves, and comparisons between groups were made using the Log-rank test. The significance level was set at $\alpha = 0.05$ (two-sided), with $P < 0.05$ considered statistically significant.

Results

Pathological Characteristics of MZL-PD

A total of 49 MZL-PD patients were included. Among them, 12 cases (24.5%) had monoclonal plasma cells detected by flow cytometry, and 37 cases (75.5%) were confirmed to have plasmacytic differentiation via biopsy morphology. Among the 37 cases with morphological plasmacytic differentiation, 27 cases (73%) showed light chain restriction by immunohistochemistry, with kappa light chain restriction accounting for 81.5% (22/27) and lambda light chain restriction for 18.5% (5/27); 10

cases (27%) showed no light chain restriction. Among the 12 cases where monoclonal plasma cells were detected by flow cytometry, 9 cases (75%) simultaneously had two populations of cells: monoclonal plasma cells and monoclonal small B lymphocytes. Among these 9 cases, 8 cases showed the same type of light chain restriction in both populations, suggesting a common clonal origin; 1 case showed different types of light chain restriction, suggesting bi-clonal origin or subclonal evolution (see Table 1 for details).

Table 1
Characteristics of Plasmacytic Differentiation in MZL-PD

Category		Item	Number(Percentage)
MZL-PD (n = 49)	Morphological plasmacytic differentiation cases (n = 37)	No light chain restriction	10/37 (27%)
		Light chain restriction present	27/37 (73%)
		— Kappa light chain restriction	22/27 (81.5%)
		— Lambda light chain restriction	5/27 (18.5%)
	Cases with monoclonal plasma cells (n = 12)	Monoclonal plasma cells + Monoclonal small B lymphocytes detected	9/12 (75%)
		— Both populations with same light chain restriction	8/9 (88.9%)
		— Different light chain restriction in populations	1/9 (11.1%)

Immunohistochemistry results showed high expression of MUM1 (29/31, 93.5%), CD38 (37/37, 100%), and CD138 (20/21, 95.2%) in plasma cells, with no expression of CD56 (0/10, 0%). Flow cytometry showed a CD19 positivity rate of 75% (9/12) and a CD20 positivity rate of only 10% (1/10). The lower number of cases assessed for certain markers reflects the availability of adequate tissue or flow cytometry data in the retrospective cohort. The overall immunophenotype was CD38 + CD138+MUM1 + CD20-CD56-CD19+, which is highly similar to the plasma cell phenotype of LPL (see Table 2 for details).

Table 2
Pathological Immunophenotypic Features of MZL-PD

Category	Item	n/N (%)
Plasma cell immunophenotype examed by immunohistochemistry	MUM1	29/31 (93.5%)
	CD38	37/37 (100%)
	CD138	20/21 (95.2%)
	CD56	0/10 (0%)
Plasma cell immunophenotype examed by flow cytometry	CD56	0/12 (0%)
	CD38	12/12 (100%)
	CD138	10/10 (100%)
	CD19	9/12 (75%)
	CD20	1/10 (10%)
Clinical Baseline Characteristics of MZL-PD		

Among the 49 MZL-PD patients, the MALT lymphoma subtype was the most common (83.7%), followed by NMZL (10.2%) and SMZL (6.1%). The lung was the most common primary site (28.6%). The overall M protein positivity rate was 61.2%, with the IgM type accounting for 76.6% (23/30). For IgM-type M protein, the median concentration was 18 g/L (range: 2.5–39.6 g/L). The bone marrow infiltration rate in the M protein-positive group was significantly higher than in the negative group (66.7% vs 10.5%, $P < 0.01$). Ki-67 index was mainly concentrated between 10%-20% (45.5%). Clinical staging was mostly advanced stage (63.3%). Some patients had concomitant autoimmune diseases, such as Sjögren's syndrome (6%) and autoimmune hemolytic anemia (8.2%) (see Table 3 for details).

Table 3
Comparison of Baseline Clinical Characteristics of 49 MZL-PD Patients

Clinical Characteristic	**[n/49 (%)]**
Gender [n, Male/Female]	23/26
Median age [years, M (range)]	64 (43–77)
B symptoms	8 (16.3)
MZL Subtype	41 (83.7)
MALT Lymphoma	5 (10.2)
NMZL	3 (6.1)
SMZL	
ECOG > 1	9 (18.4)
Lugano Modified Stage	18 (36.7)
Limited Stage	31 (63.3)
Advanced Stage	
Ki-67	17 (34.7)
≤10	21 (42.9)
>10 to ≤ 20	11 (22.4)
>20	
Most Common Site	14 (28.6)
Lung	7 (14.3)
Stomach	5 (10.2)
Lymph Node	4 (8.2)
Spleen	19 (38.8)
Other Sites	
MZL-IPI	
Low Risk	10 (20.4)
Intermediate Risk	28 (57.1)
High Risk	11 (22.4)
M proteinemia	30 (61.2)
Survival Analysis	

Clinical Characteristic	[n/49 (%)]
IgG type	4/30 (13.3)
IgM type	23/30 (76.6)
IgA type	3/30 (10)
Bone marrow involvement	22 (44.9)
M protein positive group	20/30 (66.6)
M protein negative group	2/19 (10.5)
ANA positive rate	6 (12.2)
Sjögren's syndrome	3 (6)
Autoimmune hemolytic anemia	4 (8.2)
Survival Analysis	

The median follow-up time was 32.8 months (range: 5-120 months). A total of 10 patients experienced disease progression or relapse, and 6 patients died. Median PFS was not reached, the 2-year PFS rate was 83.6% (95% CI, 70.08%-97.12%), and the 2-year OS rate was 96.4% (95% CI, 89.54%-100%) (Fig. 1A, B). We further analyzed the prognostic impact of M protein positivity. The PFS of the M protein-negative group was superior to that of the positive group. The 2-year PFS for the M protein-positive group was 78.1% (95% CI: 58.1%-98.0%), and for the M protein-negative group was 91.7% (95% CI: 76.0%-100%), showing a statistically significant difference (P = 0.037, Fig. 1C). There was no significant difference in OS between the two groups (P = 0.26, Fig. 1D).

Discussion

This study systematically reveals the unique biological characteristics, clinicopathological spectrum, and prognostic value of marginal zone lymphoma with plasmacytic differentiation (MZL-PD). Through the integrated analysis of morphology, immunophenotype, and clinical data, we found that MZL-PD is not merely a morphological change, but represents a subgroup of MZL with distinct clinical biological behavior.

At the level of tumor biology and immunophenotype, plasmacytic differentiation in MZL shows clear evidence of clonality in most cases. Among the morphological plasmacytic differentiation cases, 73% confirmed plasma cell light chain restriction via immunohistochemistry, establishing their monoclonal nature; the 27% of cases without light chain restriction suggest that background plasma cell infiltration may also present as a polyclonal background. Notably, flow cytometry detected two populations of small B lymphocytes and plasma cells simultaneously in 9 cases, with 8 cases (88.9%) showing the same type of light chain restriction, suggesting a common clonal origin in the majority of these cases. In 1 case, the two populations showed different types of light chain restriction, suggesting that in rare instances, MZL

may have a bi-clonal origin or subclonal evolutionary divergence. Previous case reports have also detected via IgH rearrangement that plasma cells in SMZL may originate from a different clone than the neoplastic B lymphocytes(10).

In terms of immunophenotypic differential diagnosis, the plasma cells associated with MZL-PD present an antigen expression profile with certain characteristics, holding significant clinical differential significance. These plasma cells are characterized by negative CD56, high CD19 positivity rate, and rare CD20 expression. This is distinctly different from the classic myeloma plasma cell phenotype (CD56+/CD19-/CD20-), but quite similar to the plasma cell characteristics of LPL. Based on this, misinterpretation of bone marrow involvement as plasma cell myeloma can be effectively avoided, and MYD88 gene test turns out to be necessary for MZL-PD patients. It has been reported in the literature that monoclonal plasma cells in MZL represent "precursor plasma cell neoplasms," with tumor cells at a different differentiation stage from plasma cell myeloma(3)(13). Among the 49 cases, 1 MZL-PD case with plasma cell phenotype CD20 + CD38+CD138 + MUM1- was initially misdiagnosed as myeloma, highlighting the necessity of completing CD56 and CD19 for MZL-PD. CD20-positive myeloma is very rare, necessitating vigilance for lymphocytes with plasmacytic differentiation(14).

We found that 61.2% of MZL-PD cases simultaneously were positive for serum M protein. This suggests that plasmacytic differentiation is not necessarily accompanied by M protein, which may be related to some cases having polyclonal plasma cell infiltration. M protein is most commonly of the IgM type, and the median IgM value is significantly higher than the upper limit of normal IgM; the highest IgM value in the cases was 72 g/L, further highlighting the heterogeneity of MZL and its clinical similarity to LPL. The bone marrow infiltration proportion in the M protein-positive group was significantly higher than in the M protein-negative group, also suggesting that M protein is a factor likely affecting MZL-PD staging and prognosis. MZL-PD shows significant tissue organ tropism, with primary occurrence in the lung being common, consistent with the previously reported high rate of 67% plasmacytic differentiation in pulmonary MALT lymphoma(15). In the disease spectrum, MZL-PD is mainly complicated by Sjögren's syndrome and autoimmune hemolytic anemia; previous literature reports that SMZL with plasmacytic differentiation is more likely to be complicated by autoimmune hemolytic anemia (16).

M protein positivity increases the risk of early progression in patients, but there is no significant difference in overall survival. The reason may be related to the higher rate of bone marrow involvement in M protein-positive patients, as well as the possibility that these patients more frequently harbor monoclonal plasma cells that share clonal origin with the neoplastic B cells. While current MZL treatment regimens primarily target B lymphocytes, the impact on clonally related plasma cells remains unclear. However, detailed data on first-line regimens and subsequent therapies were not systematically captured in this study. Although no significant difference in overall survival was observed within the limited follow-up period, this finding requires validation in larger studies with extended follow-up.”

In summary, MZL-PD commonly occurs in the lung, and its plasma cell immunophenotype is similar to LPL, requiring differentiation combined with MYD88 testing. M protein positivity is an adverse prognostic

factor for bone marrow infiltration and early progression in MZL-PD patients. Identifying this subgroup is of great significance for precise diagnosis and the formulation of individualized treatment strategies. Due to the limited sample size and relatively small number of events, multivariate Cox regression analysis was not performed to avoid overfitting of the statistical model. Future studies with larger sample sizes and longer follow-up are warranted to confirm whether M protein positivity represents an independent prognostic factor after adjusting for other clinical variables.

Declarations

Ethics approval:

This study was performed in accordance with the ethical standards of the Declaration of Helsinki and its later amendments. This study was also approved by the Institutional Review Board of the Second Xiangya Hospital, Xiangya School of Medicine, Central South University.

Consent to participate:

Informed consent was obtained from all individual participants involved in the study.

Consent to publish

statement

Competing interests

The authors declare that they have no competing interests

Funding

This study was supported by the National Natural Science Foundation of China (82200777,81900170) and Natural Science Foundation of Hunan Province(2020JJ5840,2022JJ40710)

Data Availability Statement

All data included in this study are available upon request by contact with the corresponding author.

Author Contribution

Heng Li: Conceptualization, Data curation, Formal analysis, Writing – original draft.Jiayi Wang: Investigation, Methodology, Resources, Validation.Hongling Peng: Supervision, Validation, Funding acquisition, Writing – review & editing.Wenzhe Yan: Project administration, Supervision, Writing – review

& editing, Funding acquisition, Conceptualization.All authors reviewed and approved the final version of the manuscript.

Data Availability

All data included in this study are available upon request by contact with the corresponding author.

References

1. Rossi D, Bertoni F, Zucca E. Marginal-Zone Lymphomas. N Engl J Med. 2022;386(6):568–81.
2. Young JH, Pozdnyakova O. How I diagnose B-cell lymphoproliferative disorders with plasmacytic differentiation. Am J Clin Pathol. 2025;163(4):501–10.
3. Meyerson HJ, Bailey J, Miedler J, Olobatuyi F. Marginal zone B cell lymphomas with extensive plasmacytic differentiation are neoplasms of precursor plasma cells. Cytometry B Clin Cytom. 2011;80(2):71–82.
4. Souto Filho JTD, de Morais RA, Oliveira Silveira AL, Lacerda AP, Fassbender IPB, Chaves Ribeiro JMM, de Sales LR. Clonal villous lymphocytes and plasma cells in splenic marginal zone lymphoma with plasmacytic differentiation. Blood Res. 2018;53(4):267.
5. Ruiz A, Reischl U, Swerdlow SH, Hartke M, Streubel B, Procop G, et al. Extranodal marginal zone B-cell lymphomas of the ocular adnexa: multiparameter analysis of 34 cases including interphase molecular cytogenetics and PCR for Chlamydia psittaci. Am J Surg Pathol. 2007;31(5):792–802.
6. Carlsen ED, Davis AR, Cook JR, Swerdlow SH. The Distinctive Nature of Thyroid MALT Lymphomas Including IRTA1 Expression. Am J Surg Pathol. 2023;47(3):370–8.
7. Flospergher E, Marino F, Calimeri T, Cangi MG, Ferreri AJM, Ponzoni M, Bongiovanni L. Primary central nervous system marginal zone lymphoma. Br J Haematol. 2024;204(1):31–44.
8. Salama ME, Lossos IS, Warnke RA, Natkunam Y. Immunoarchitectural patterns in nodal marginal zone B-cell lymphoma: a study of 51 cases. Am J Clin Pathol. 2009;132(1):39–49.
9. Traverse-Glehen A, Felman P, Callet-Bauchu E, Gazzo S, Baseggio L, Bryon PA, et al. A clinicopathological study of nodal marginal zone B-cell lymphoma. A report on 21 cases. Histopathology. 2006;48(2):162–73.
10. Dufresne SD, Felgar RE, Sargent RL, Surti U, Gollin SM, McPhail ED, et al. Defining the borders of splenic marginal zone lymphoma: a multiparameter study. Hum Pathol. 2010;41(4):540–51.
11. Molina TJ, Lin P, Swerdlow SH, Cook JR. Marginal zone lymphomas with plasmacytic differentiation and related disorders. Am J Clin Pathol. 2011;136(2):211–25.
12. Epperla N, Zhao Q, Karmali R, Torka P, Shea L, Oh TS, et al. Impact of detectable monoclonal protein at diagnosis on outcomes in marginal zone lymphoma: a multicenter cohort study. Blood Adv. 2023;7(17):5038–46.

13. Guo Z, Su J, Liu L, Zhang N, Chen X, Zhong Q, et al. CD180 as a Robust Immunophenotypic Marker for Differentiating Lymphoplasmacytic Lymphoma/Waldenstrom Macroglobulinemia From Marginal Zone Lymphoma. Mod Pathol. 2025;38(12):100919.
14. Swerdlow SH, Kuzu I, Dogan A, Dirnhofer S, Chan JK, Sander B, et al. The many faces of small B cell lymphomas with plasmacytic differentiation and the contribution of MYD88 testing. Virchows Arch. 2016;468(3):259–75.
15. Fraune C, Tazelaar HD, Butt YM, Smith ML, Larsen BT, Kelemen K. Usefulness and Limitations of Current Diagnostic Strategies for Pulmonary Mucosa-Associated Lymphoid Tissue Lymphoma: Lessons Learned From a Large Cohort. Arch Pathol Lab Med. 2024;148(4):419–29.
16. Van Duong JP, Molina T, Delmer A, Audouin J, Le Tourneau A, Zittoun R, et al. Splenic marginal zone lymphoma with or without plasmacytic differentiation. Am J Surg Pathol. 2000;24(12):1581–92.

Figures

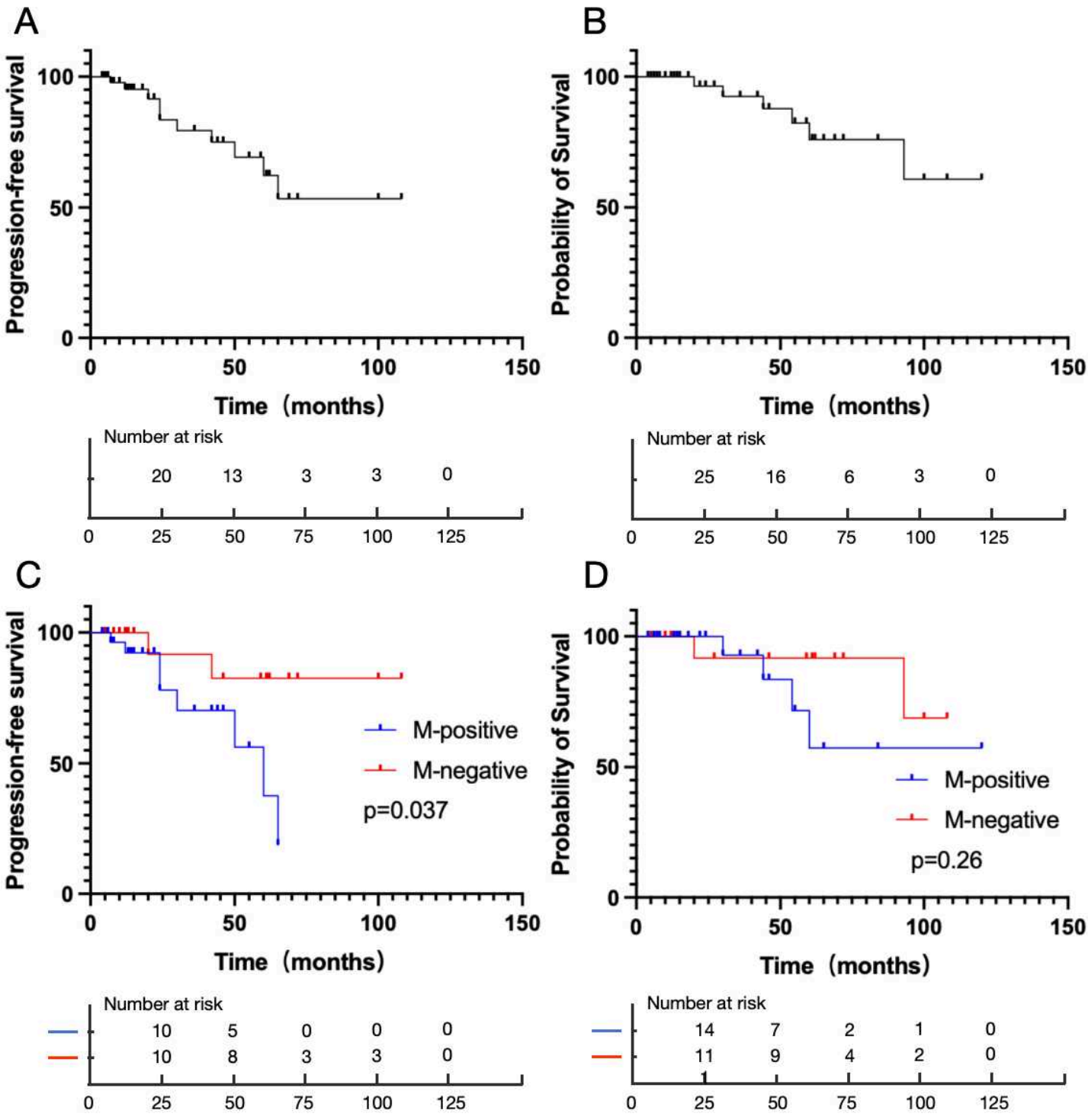

Figure 1

A: Kaplan-Meier curve for progression-free survival of MZL-PD patients. B: Kaplan-Meier curve for overall survival of MZL-PD patients. C: Kaplan-Meier curve for progression-free survival comparing M protein-positive group vs M protein-negative group; a difference in PFS exists between the two groups (p=0.037). D: Kaplan-Meier curve for overall survival comparing M protein-positive group vs M protein-negative group; no statistical difference in OS between the two groups (p=0.26). The blue line represents the M protein-positive group, and the red line represents the M protein-negative group.