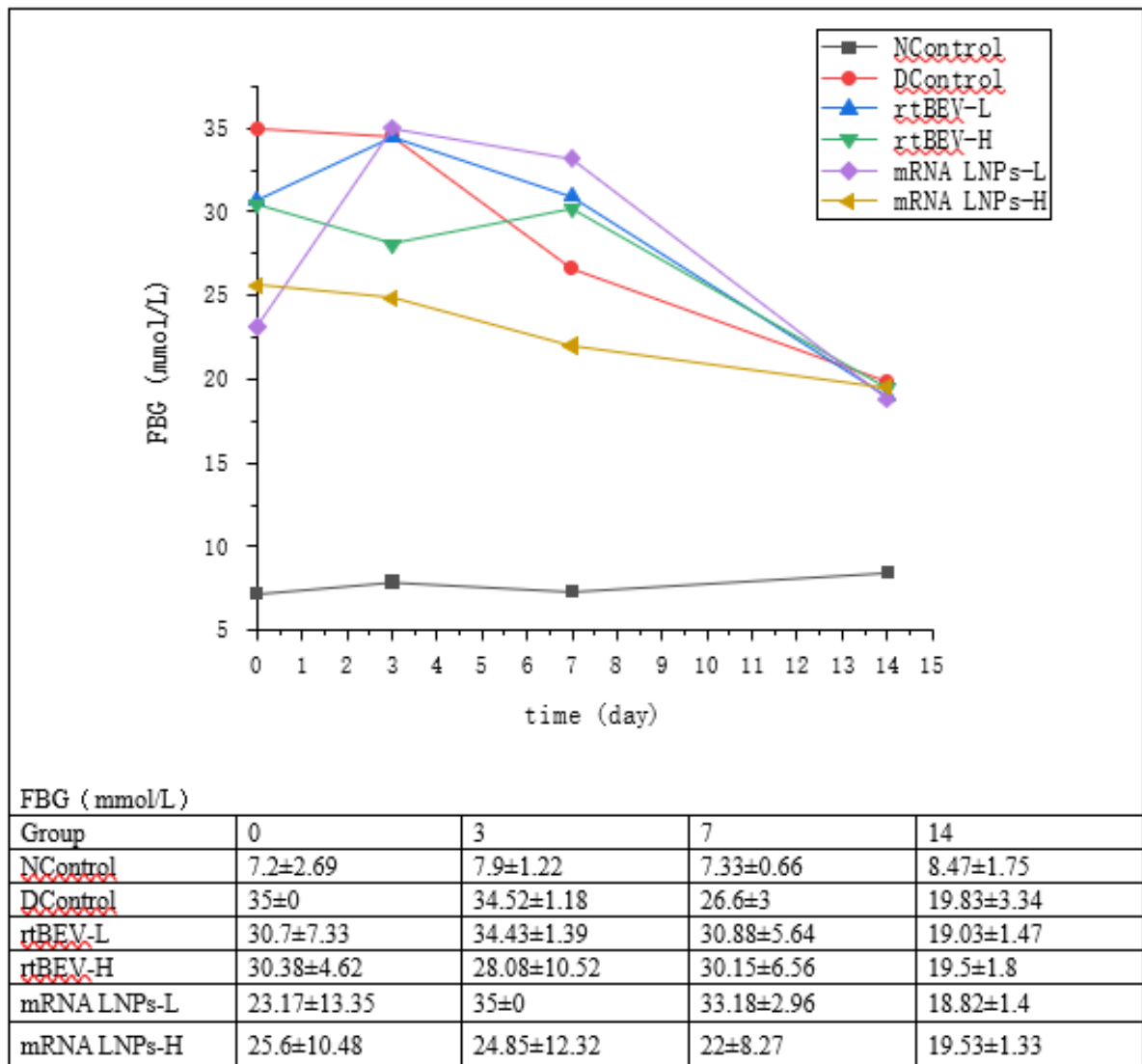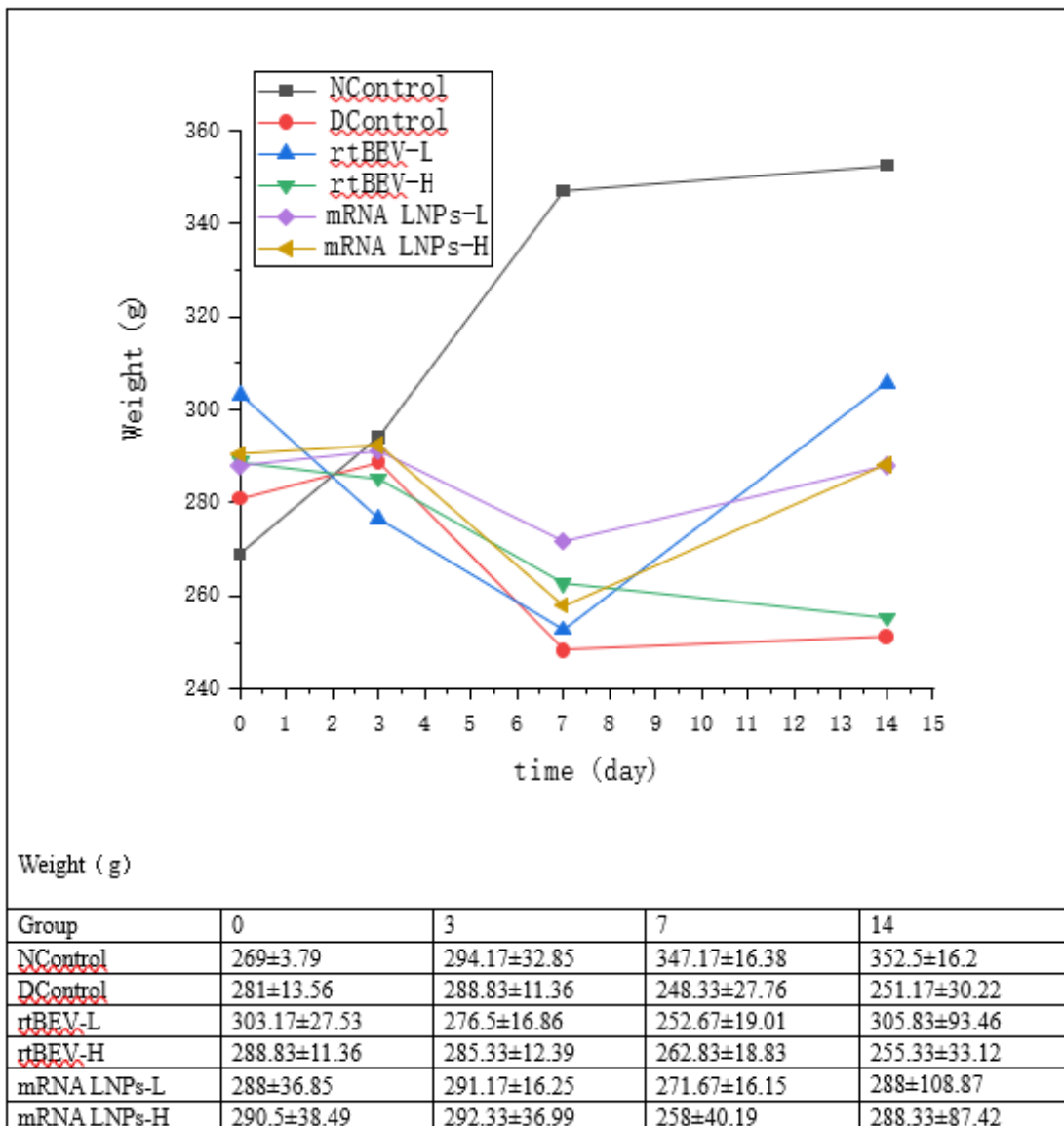


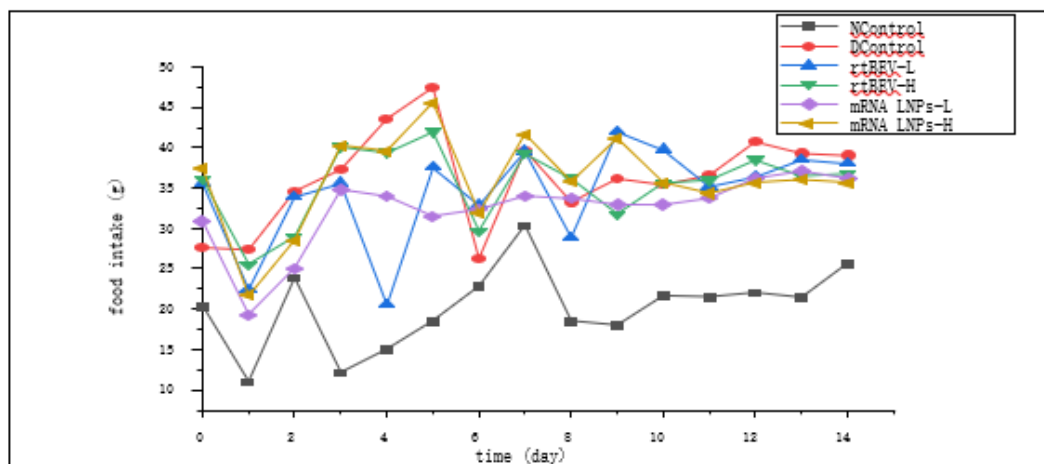
Supplementary Figure 1a | Changes in fasting blood glucose levels following treatment.

Fasting blood glucose (FBG) levels were measured at days 0, 3, 7, and 14 in normal control rat (NControl), diabetic control rat (DControl), and diabetic rat treated with low- or high-dose rtBEV (rtBEV-L and rtBEV-H) or mRNA lipid nanoparticles (mRNA LNPs-L and mRNA LNPs-H). Data are presented as mean ± s.d. (n = 6 per group). While NControl animals maintained stable normoglycaemia throughout the study (~7–8 mmol L⁻¹), diabetic groups exhibited markedly elevated glucose levels at baseline. Treatment with rtBEV or mRNA LNPs resulted in a progressive reduction in FBG over the 14-day period, with values converging to ~19 mmol L⁻¹ by day 14. Source data for the graph are provided in the accompanying table.



Supplementary Figure 1b | Changes in body weight during treatment

Body weight was monitored at days 0, 3, 7, and 14 in normal control rat (NControl), diabetic control rat (DControl), and diabetic rat treated with low- or high-dose rtBEV (rtBEV-L and rtBEV-H) or mRNA lipid nanoparticles (mRNA LNPs-L and mRNA LNPs-H). Data are presented as mean ± s.d. (n = 6 per group). NControl animals showed a progressive increase in body weight over the 14-day period. In contrast, diabetic control rat exhibited a reduction in body weight after day 3 that persisted until day 14. rat treated with rtBEV or mRNA LNPs displayed transient weight loss around day 7 followed by partial recovery by day 14. Source data corresponding to the graph are provided in the accompanying table.

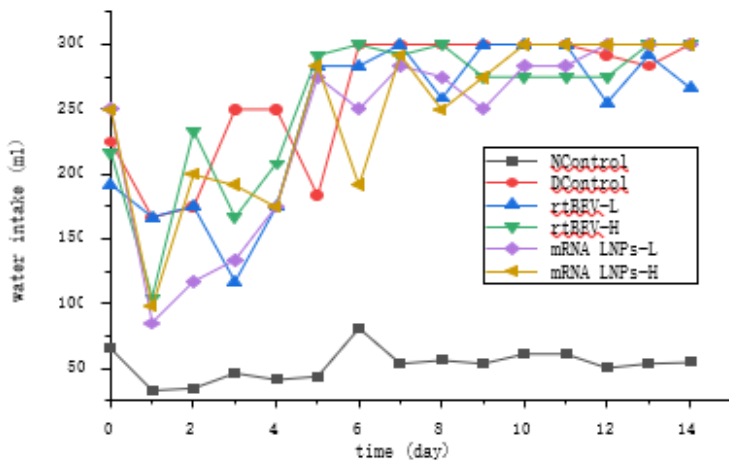


Food intake (g)

Group	0	1	2	3	4	5	6	
NControl	20.35±7.84	20.35±7.84	23.8±3.41	12.1±2.47	14.98±4.43	18.48±1.96	22.78±2.81	
DControl	27.65±8.54	27.65±8.54	34.6±4.65	37.3±3.47	43.55±3.4	47.42±4	26.32±5.29	
rtBEV-L	35.65±5.32	35.65±5.32	33.95±6.39	35.62±4.78	20.53±10.57	37.57±3.79	32.93±7.64	
rtBEV-H	36.13±14.64	36.13±14.64	28.93±7.04	40.15±6.29	39.42±5.46	42.02±7.18	29.67±9.54	
mRNA LNPs-L	30.85±7.87	30.85±7.87	25.05±10.68	34.82±11.37	33.98±8.53	31.51±3.01	32.37±6	
mRNA LNPs-H	37.37±5.37	37.37±5.37	28.55±4.4	40.23±4.66	39.55±11.45	45.53±8.61	31.88±5.3	
Group	7	8	9	10	11	12	13	14
NControl	30.32±3.01	18.47±2.91	17.95±4.69	21.6±3.7	21.45±1.75	21.97±5.04	21.37±5.19	25.62±7.67
DControl	39.68±10.17	33.28±6.11	36.18±3.43	35.4±3.97	36.58±3.05	40.72±2.48	39.28±2.48	39±42.8
rtBEV-L	39.62±10.4	28.92±4.37	42.05±5.93	39.77±2.6	35.23±3.22	36.43±3.46	38.57±3.46	38.1±3.12
rtBEV-H	39.28±5.79	36.2±3.77	31.8±6.88	35.67±4.19	36±2.98	38.5±3.92	36.5±2.03	36.83±3.85
mRNA LNPs-L	34.03±7.38	33.7±8.97	32.95±4.06	32.93±4.85	33.73±1.88	36.23±1.87	37.1±3.95	36.23±1.87
mRNA LNPs-H	41.62±6.51	35.75±5.7	41.1±6.88	35.67±0.86	34.33±0.86	35.67±0.86	36±3.91	35.67±0.86

Supplementary Figure 1c | Daily food intake during the treatment period.

Daily food intake was recorded for 14 days in normal control rat (NControl), diabetic control rat (DControl), and diabetic rat treated with low- or high-dose rtBEV (rtBEV-L and rtBEV-H) or mRNA lipid nanoparticles (mRNA LNPs-L and mRNA LNPs-H). Food consumption was measured daily and expressed in grams (g). Data are presented as mean ± s.d. (n = 6 per group). NControl animals maintained relatively stable and lower food intake throughout the study. In contrast, diabetic control rat showed increased food consumption compared with NControl animals, consistent with diabetic hyperphagia. rat treated with rtBEV or mRNA LNPs displayed food intake patterns comparable to diabetic controls with moderate fluctuations during the treatment period. Source data corresponding to the graph are provided in the accompanying table.



water intake (ml)

Group	0	1	2	3	4	5	6
NControl	65.83±18.55	33.33±5.16	35±4.47	46.67±5.16	41.67±19.15	44.17±4.92	81.67±29.94
DControl	225±27.39	166.67±40.82	175±41.83	250±0	250±0	183.33±25.82	300±0
rtBEV-L	191.67±37.64	166.67±60.55	175±27.39	116.67±68.31	175±61.24	283.33±25.82	283.33±40.82
rtBEV-H	216.67±25.82	105±59.58	233.33±25.82	166.67±40.82	208.33±20.41	291.67±20.41	300±0
mRNA LNP-L	250±0	85±40.37	116.67±51.64	133.33±51.64	175±61.24	275±27.39	250±0
mRNA LNP-H	250±0	98.33±57.42	200±77.46	191.67±58.45	175±61.24	283.33±25.82	191.67±73.6

Group	7	8	9	10	11	12	13	14
NControl	54.17±24.17	56.67±15.38	54.17±13.57	61.67±13.29	50.83±9.17	54.17±13.57	55±13.78	56.67±12.11
DControl	300±0	300±0	300±0	300±0	291.67±20.41	283.33±25.82	300±0	300±300
rtBEV-L	300±0	258.33±66.46	300±0	300±0	255±64.42	291.67±20.41	266.67±51.64	275±41.83
rtBEV-H	291.67±20.41	300±0	275±61.24	275±61.24	275±61.24	300±0	300±0	283.33±40.82
mRNA LNP-L	283.33±25.82	275±61.24	250±77.46	283.33±40.82	300±0	300±0	300±0	300±0
mRNA LNP-H	291.67±20.41	250±77.46	275±61.24	300±0	300±0	300±0	300±0	300±0

Supplementary Figure 1d | Daily water intake during the treatment period.

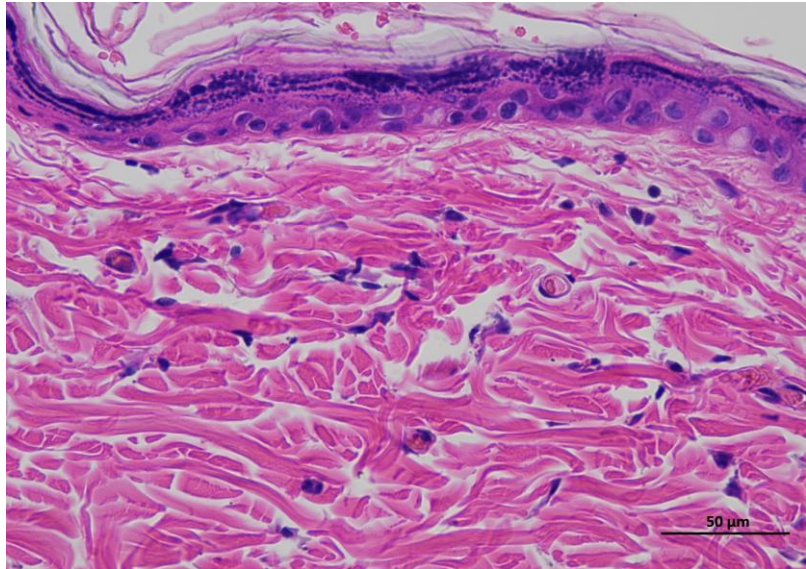
Daily water intake was recorded for 14 days in normal control rat (NControl), diabetic control rat (DControl), and diabetic rat treated with low- or high-dose rtBEV (rtBEV-L and rtBEV-H) or mRNA lipid nanoparticles (mRNA LNPs-L and mRNA LNPs-H). Water consumption was measured daily and expressed in milliliters (ml). Data are presented as mean ± s.d. (n = 6 per group). NControl animals maintained relatively stable and lower water intake throughout the study. In contrast, diabetic control rat exhibited markedly elevated water consumption compared with NControl animals, consistent with diabetic polydipsia. rat treated with rtBEV or mRNA LNPs showed water intake levels comparable to diabetic controls with moderate fluctuations during the treatment period. Source data corresponding to the graph are provided in the accompanying table.

Animal 1

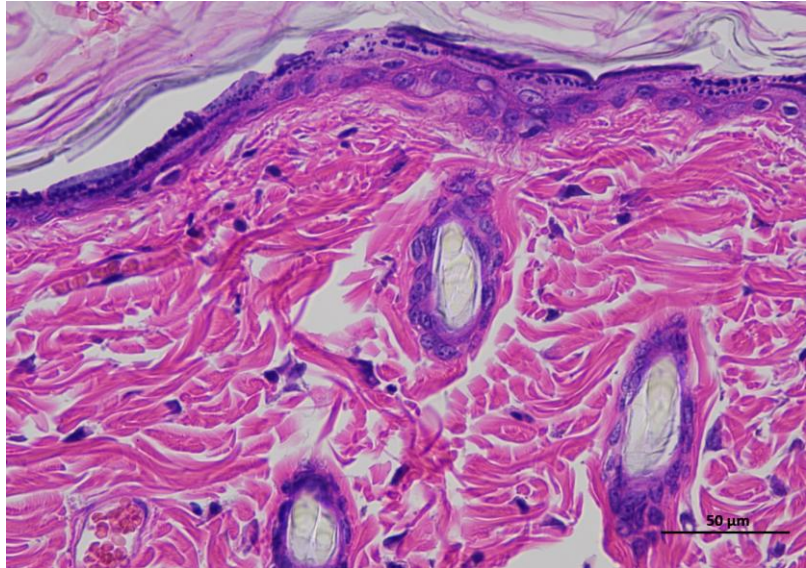
Supplementary Figure 2a | Representative H&E staining of skin tissue of control animals / Day 0.

Representative hematoxylin and eosin (H&E)-stained section of skin tissue collected from experimental rat. The image shows the typical architecture of the skin, including the epidermal layer with stratified keratinized epithelium and the underlying dermis composed of dense collagen fibers and connective tissue structures.

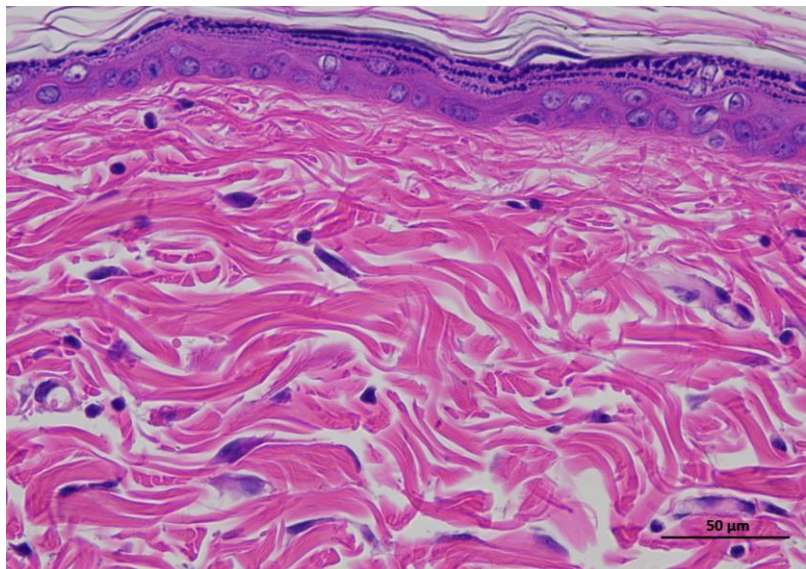
(n = 6 per group).



1 NControl 0day 400-1



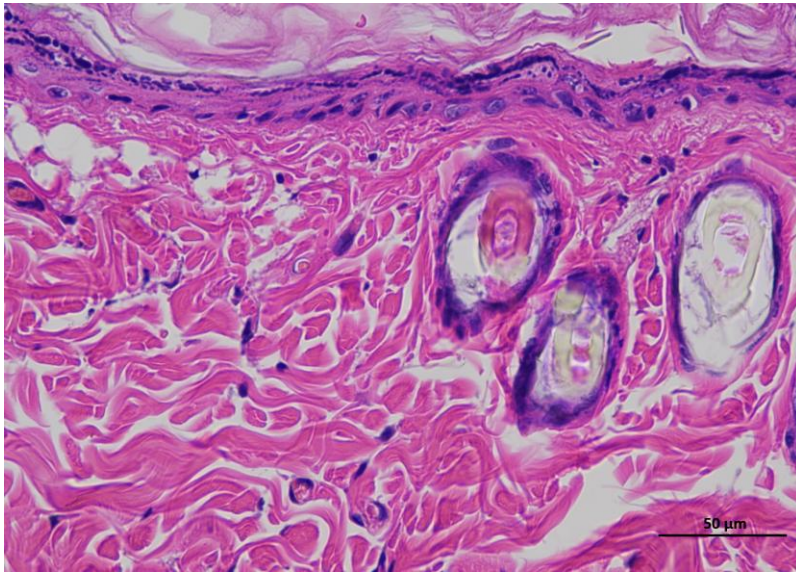
1 NControl 0day 400-2



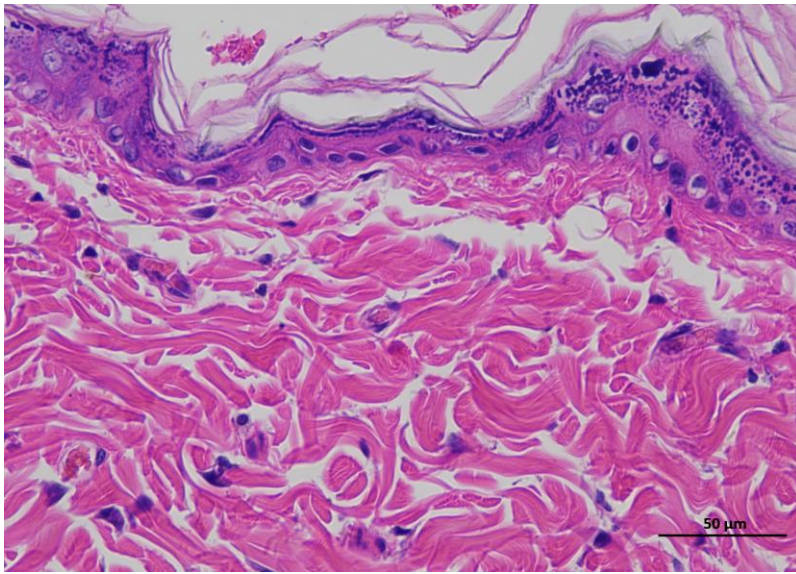
1 NControl 0day 400-3

Animal 2

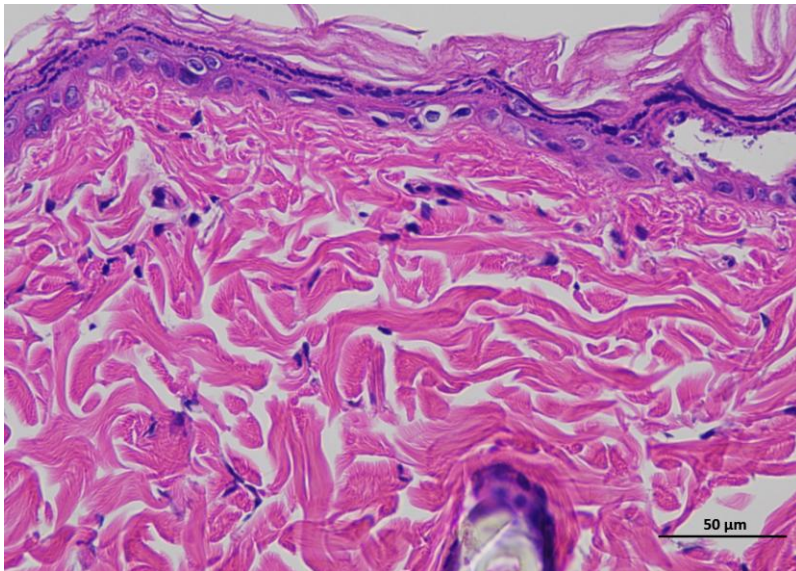
**Supplementary
Figure 2a |
Representative H&E
staining of skin
tissue of control
animals / Day 0.**



2 NControl 0day 400-1



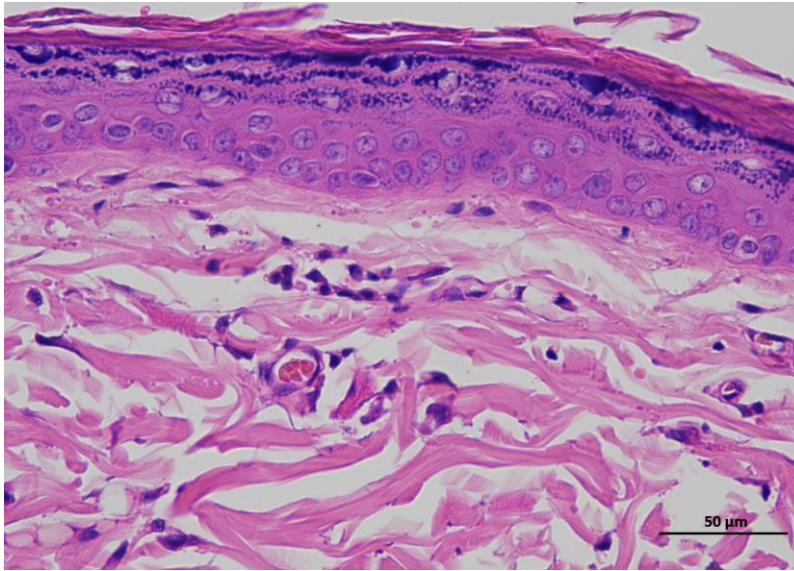
2 NControl 0day 400-2



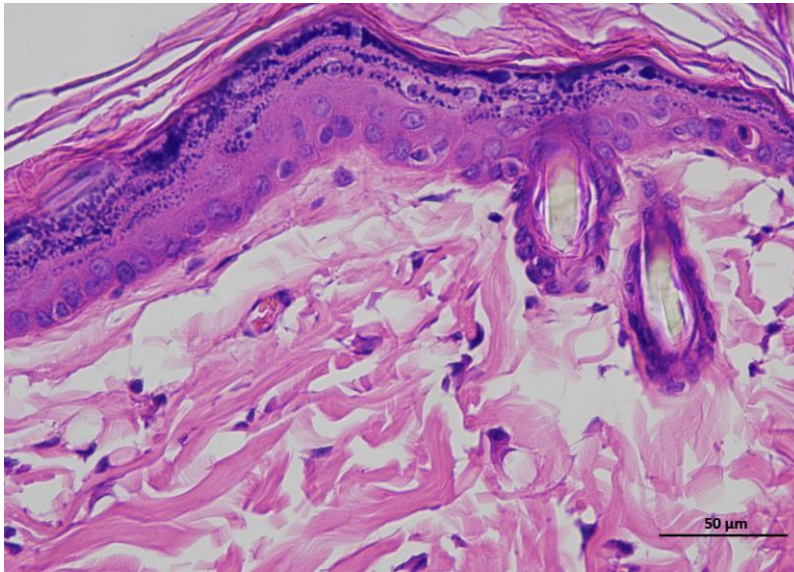
2 NControl 0day 400-3

Animal 3

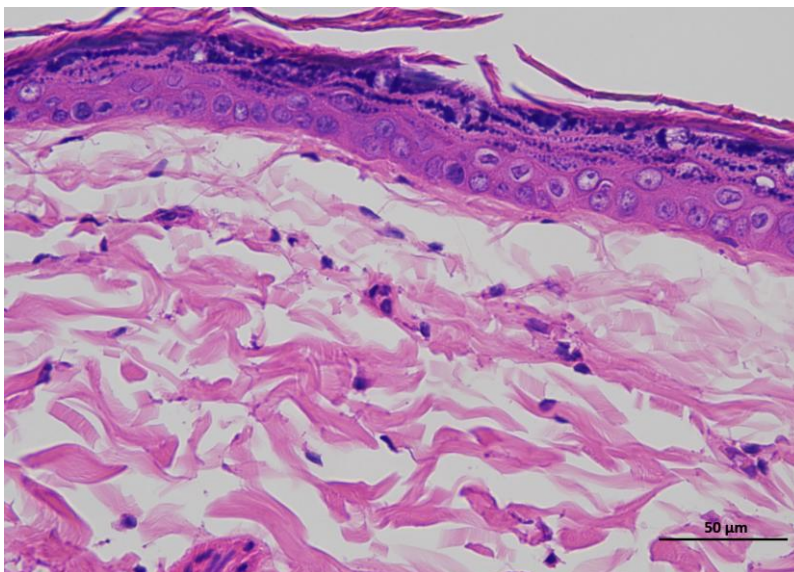
**Supplementary
Figure 2a |
Representative H&E
staining of skin
tissue of control
animals / Day 0.**



3 NControl 0day 400-1



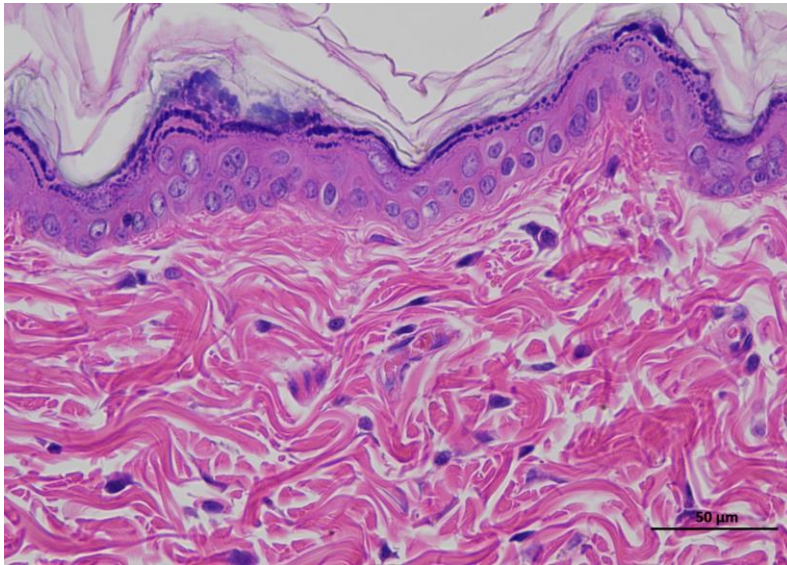
3 NControl 0day 400-2



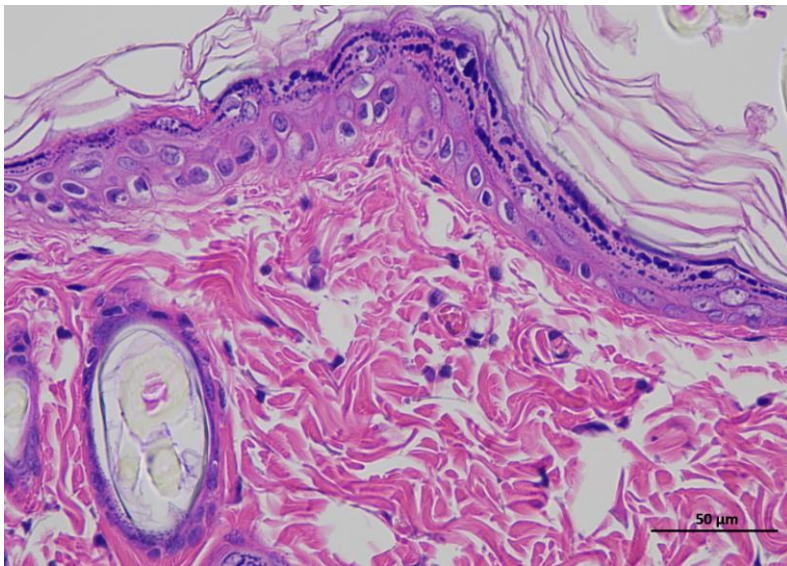
3 NControl 0day 400-3

Animal 4

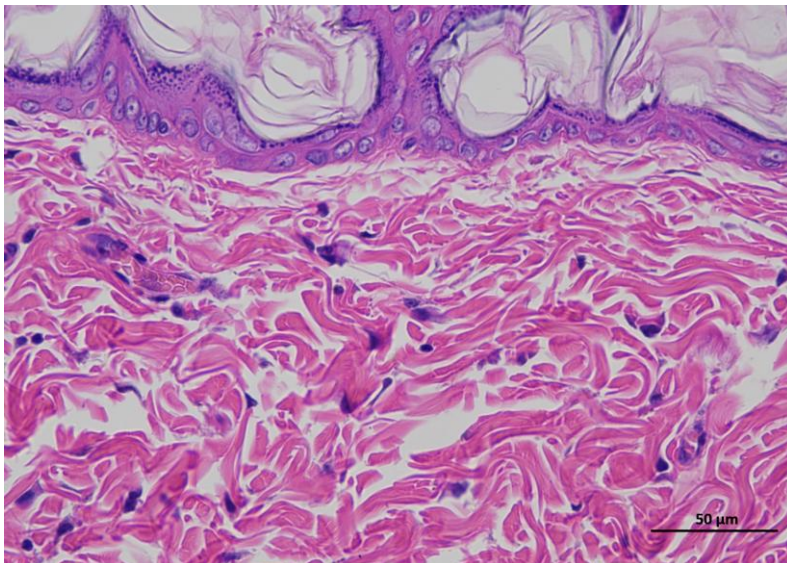
**Supplementary
Figure 2a |
Representative H&E
staining of skin
tissue of control
animals / Day 0.**



4 NControl Oday 400-1



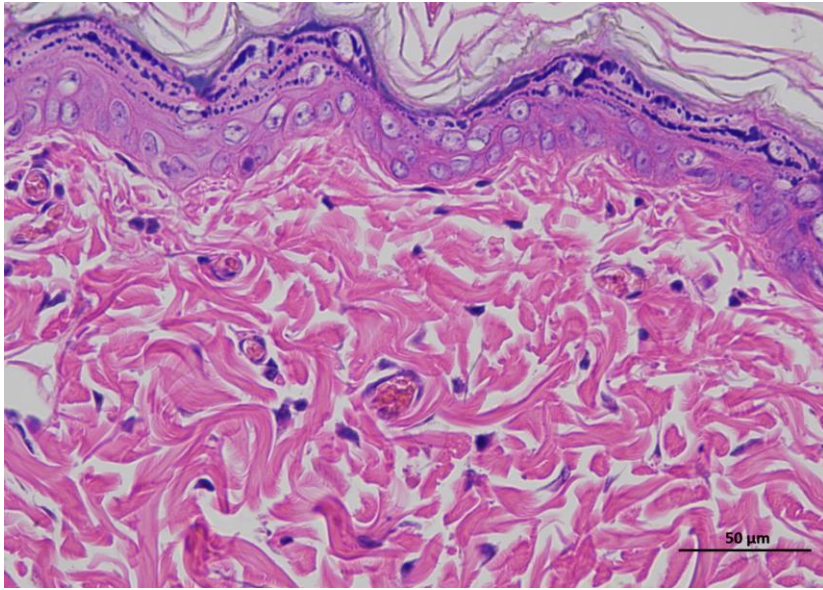
4 NControl Oday 400-2



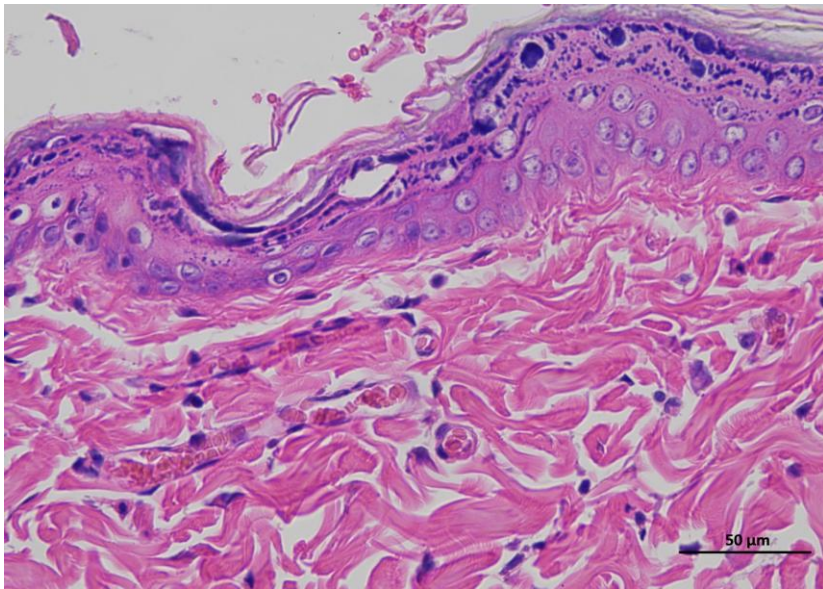
4 NControl Oday 400-3

Animal 5

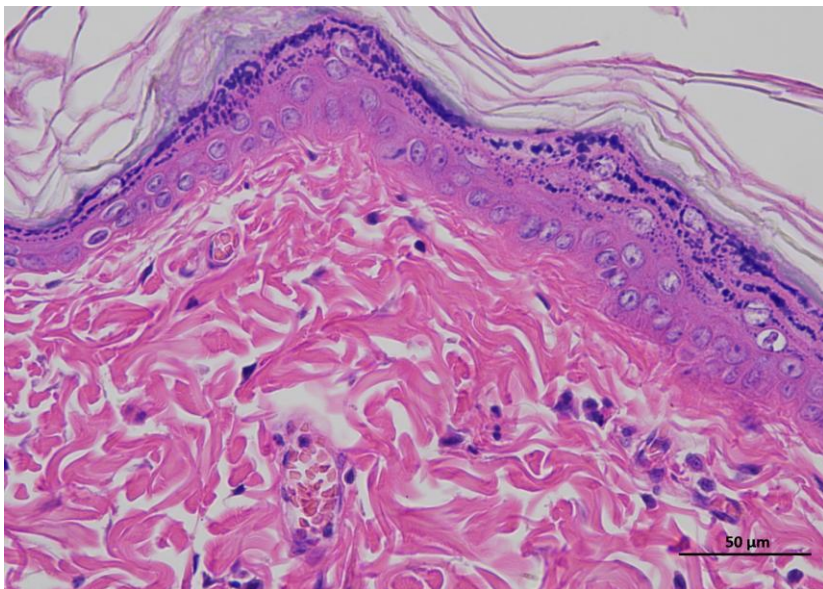
**Supplementary
Figure 2a |
Representative H&E
staining of skin
tissue of control
animals / Day 0.**



5 NControl Oday 400-1



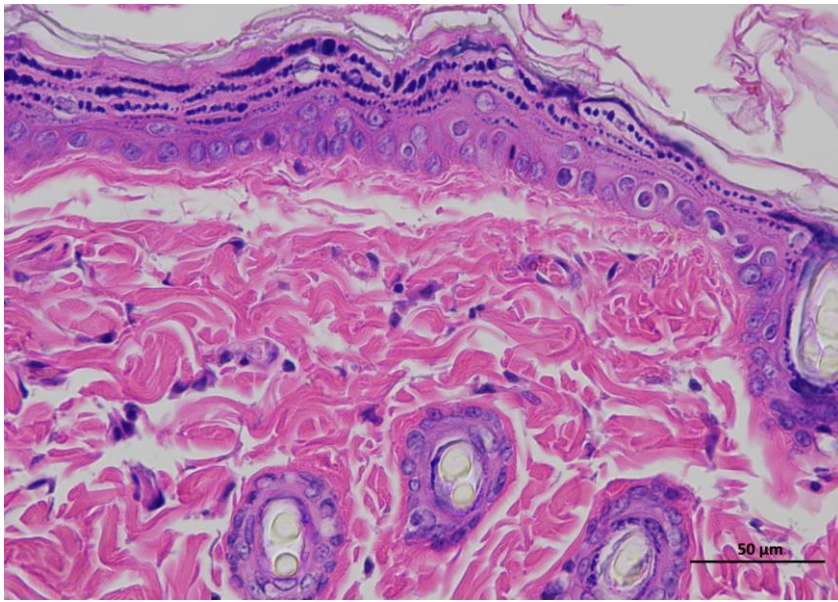
5 NControl Oday 400-2



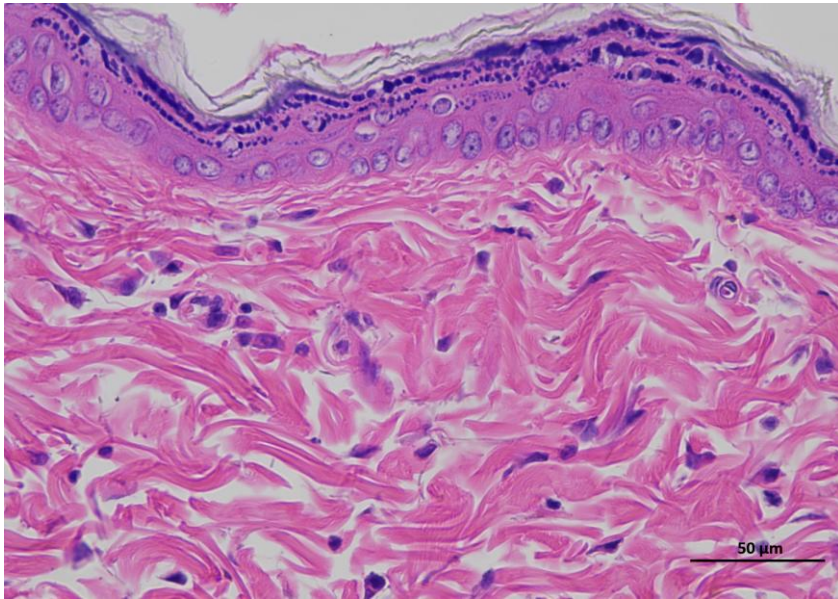
5 NControl Oday 400-3

Animal 6

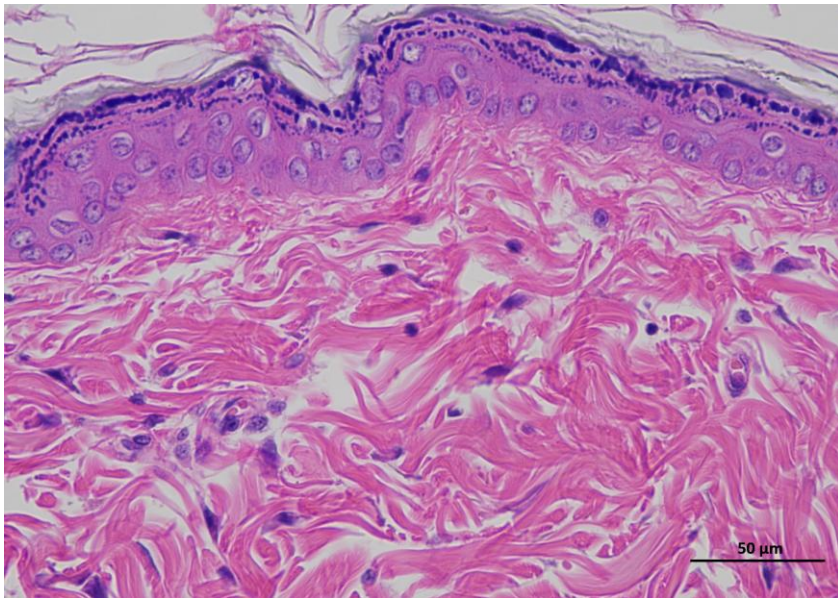
**Supplementary
Figure 2a |
Representative H&E
staining of skin
tissue of control
animals / Day 0.**



6 NControl 0day 400-1



6 NControl 0day 400-2



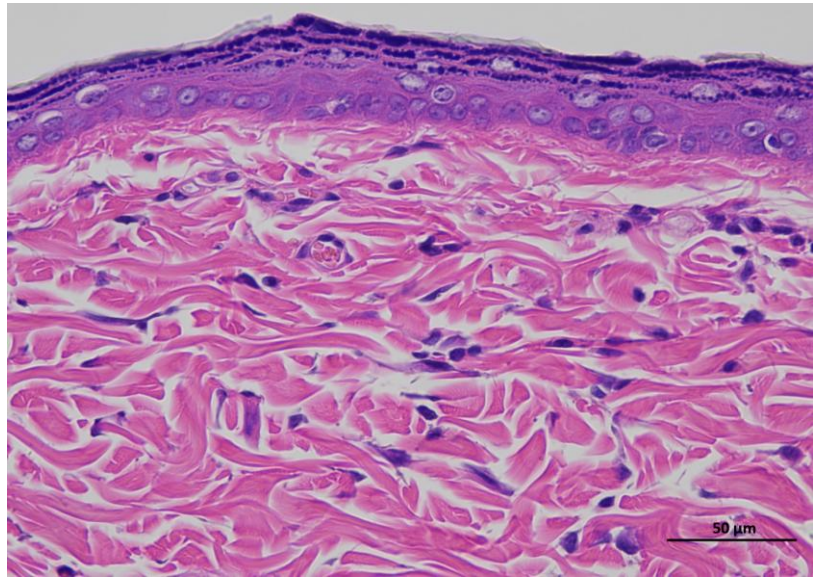
6 NControl 0day 400-3

Animal 1

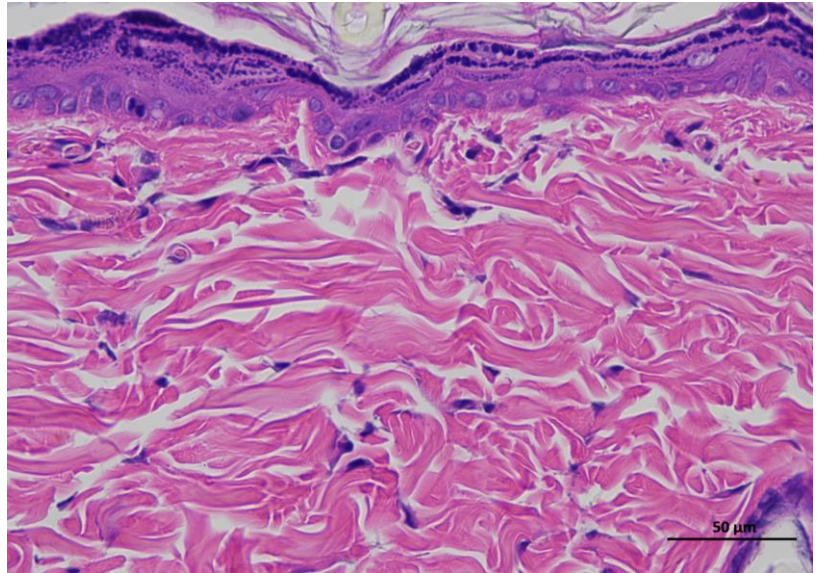
Supplementary Figure 3a | Representative H&E staining of skin tissue of control animals / Day 14.

Representative hematoxylin and eosin (H&E)-stained section of skin tissue collected from experimental rat. The image shows the typical architecture of the skin, including the epidermal layer with stratified keratinized epithelium and the underlying dermis composed of dense collagen fibers and connective tissue structures.

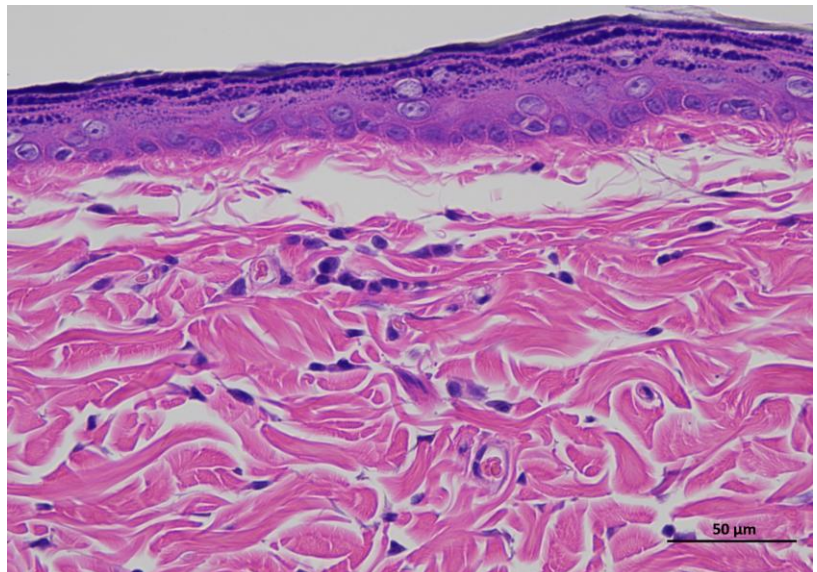
(n = 6 per group).



1 NControl 14day 400-1



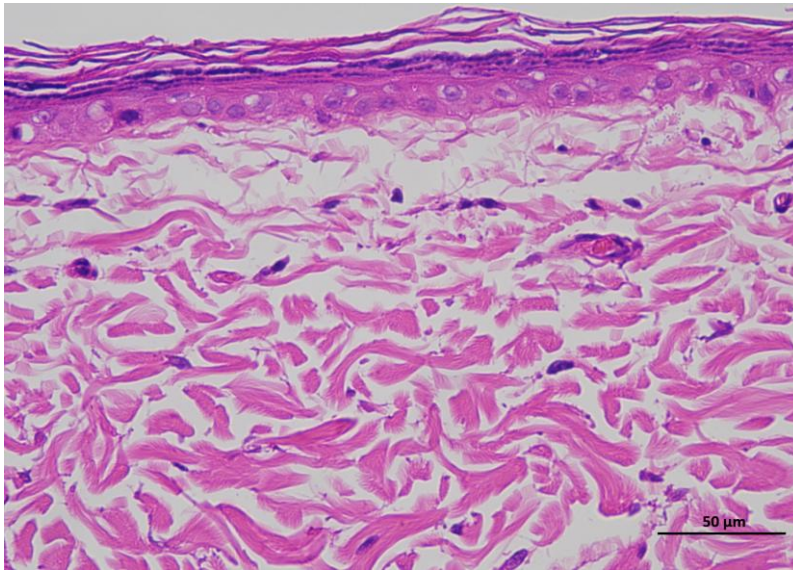
1 NControl 14day 400-2



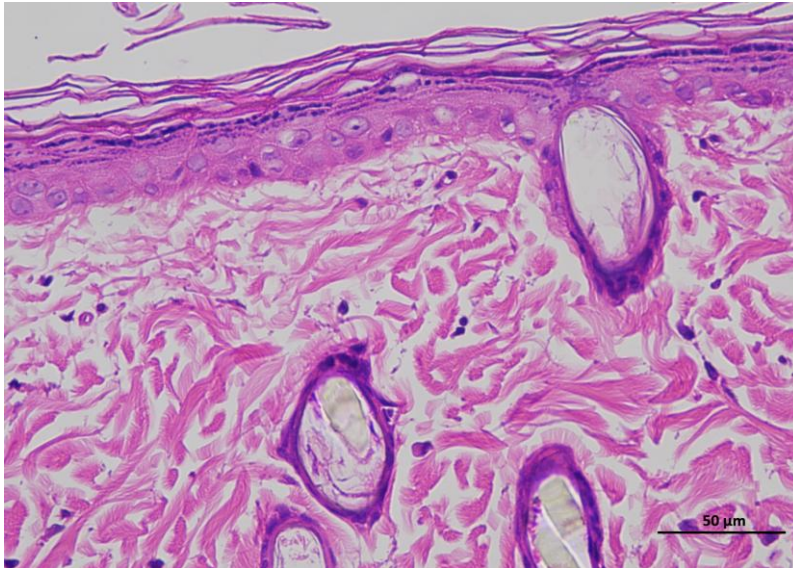
1 NControl 14day 400-3

Animal 2

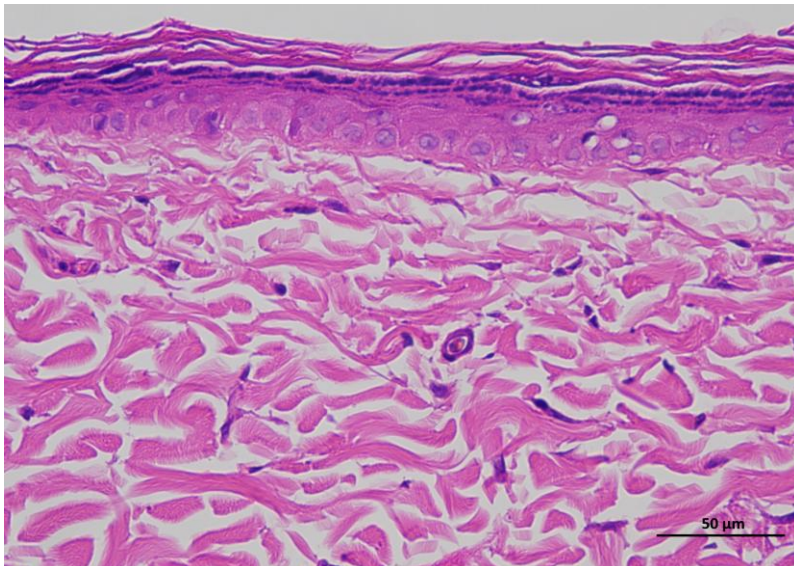
**Supplementary
Figure 3a |
Representative H&E
staining of skin
tissue of control
animals / Day 14.**



2 NControl 14day 400-1



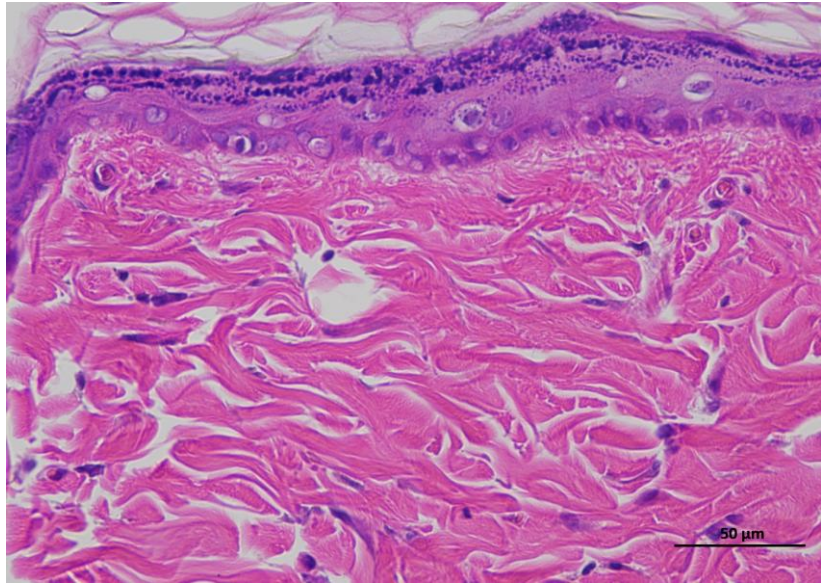
2 NControl 14day 400-2



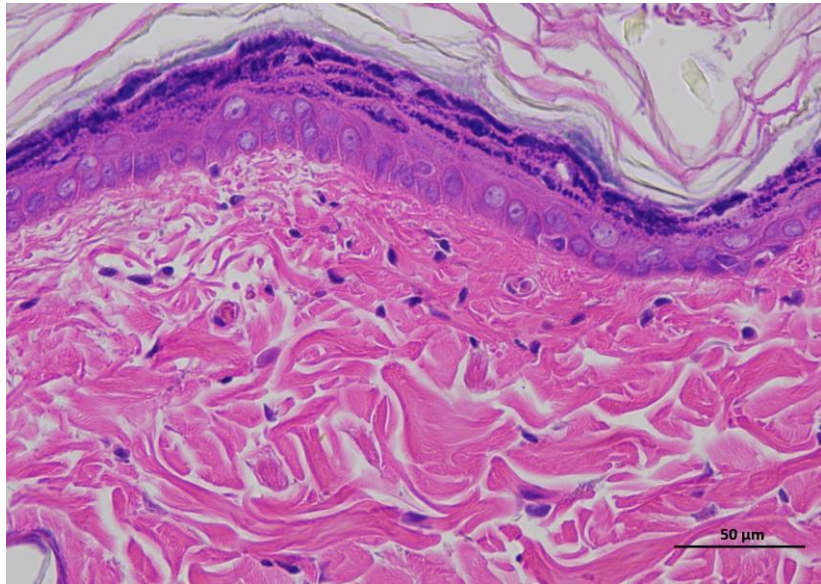
2 NControl 14day 400-3

Animal 3

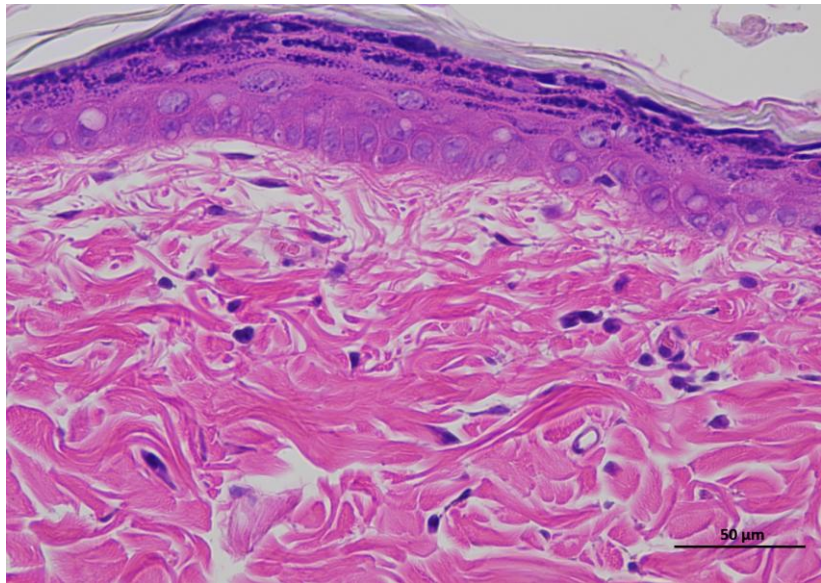
**Supplementary
Figure 3a |
Representative H&E
staining of skin
tissue of control
animals / Day 14.**



3 NControl 14day 400-1



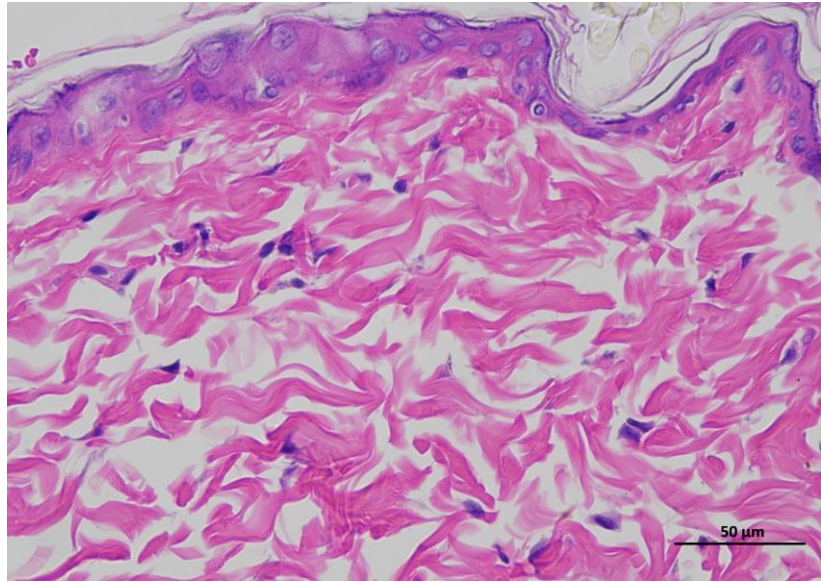
3 NControl 14day 400-2



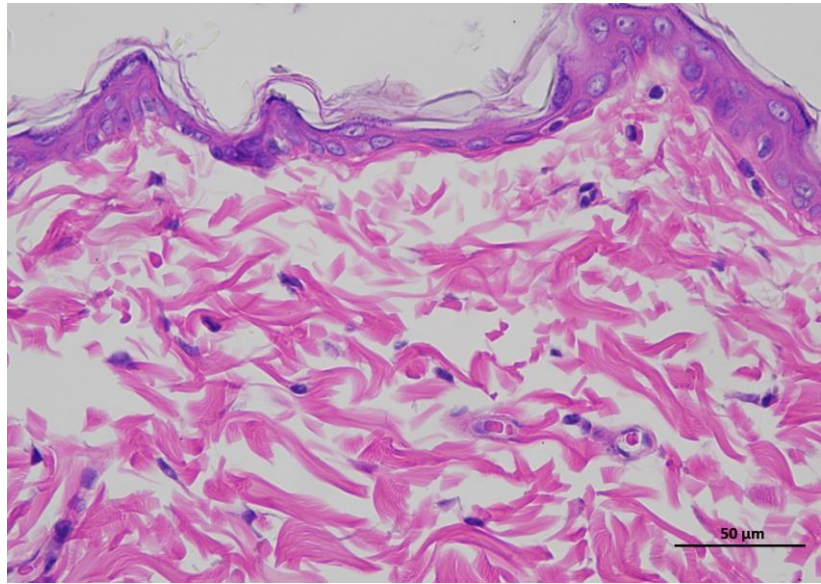
3 NControl 14day 400-3

Animal 4

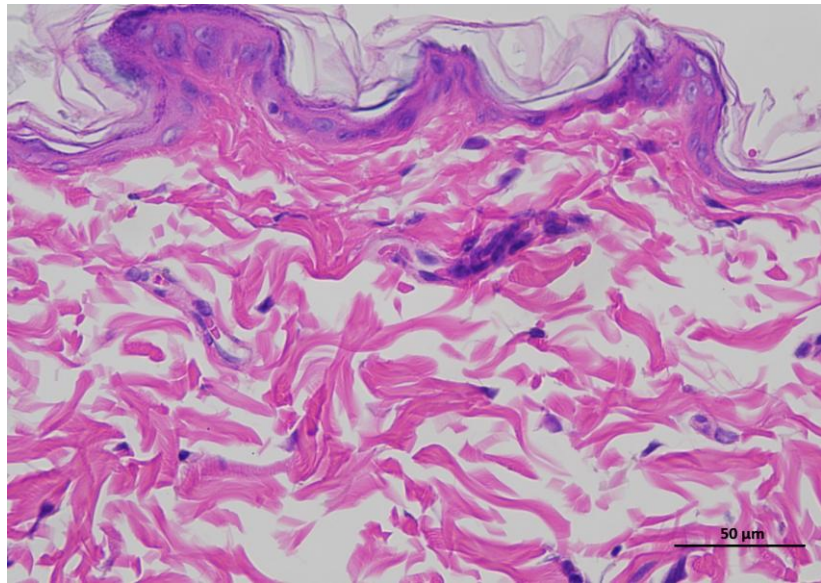
**Supplementary
Figure 3a |
Representative H&E
staining of skin
tissue of control
animals / Day 14.**



4 NControl 14day 400-1



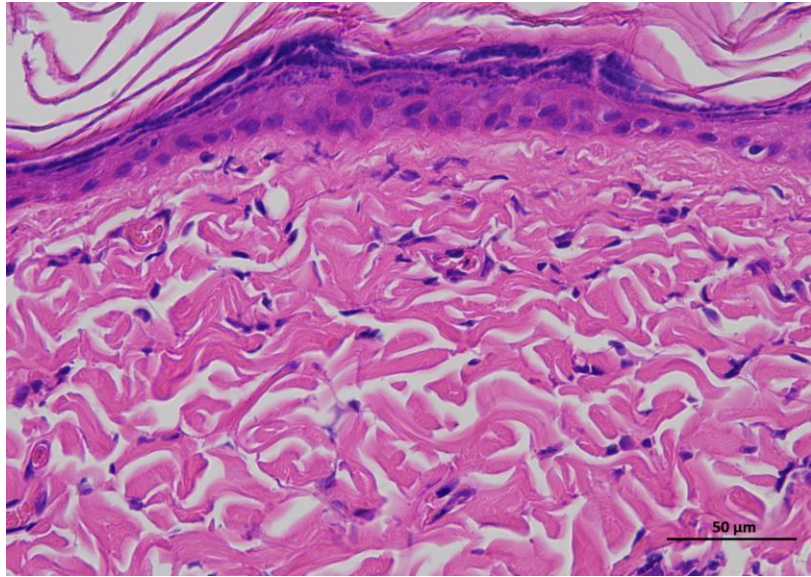
4 NControl 14day 400-2



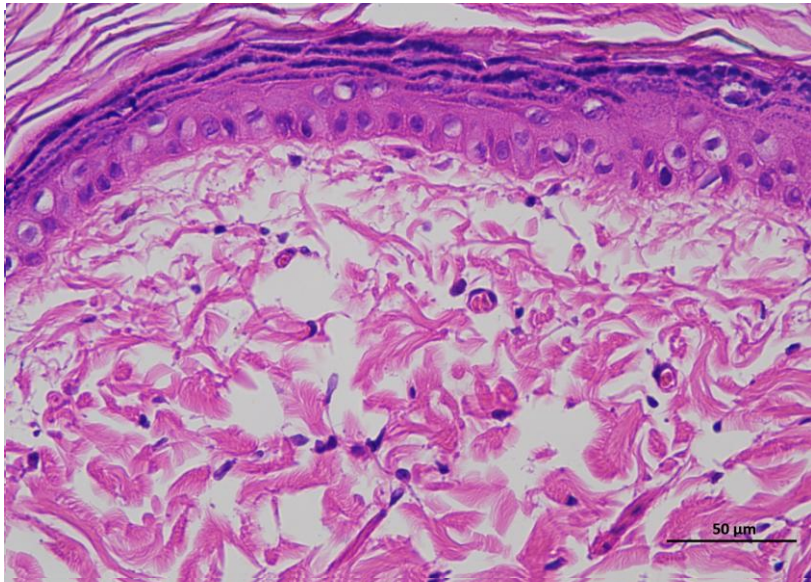
4 NControl 14day 400-3

Animal 5

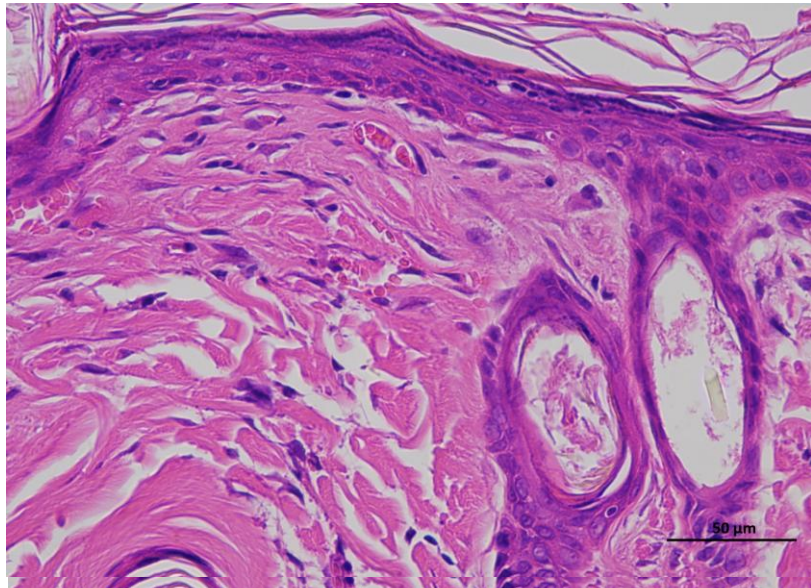
**Supplementary
Figure 3a |
Representative H&E
staining of skin
tissue of control
animals / Day 14.**



5 NControl 14day 400-1



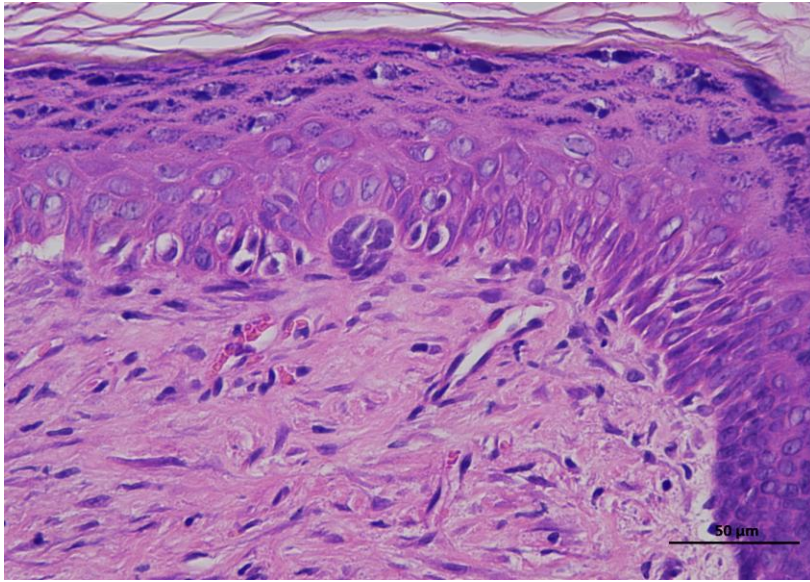
5 NControl 14day 400-2



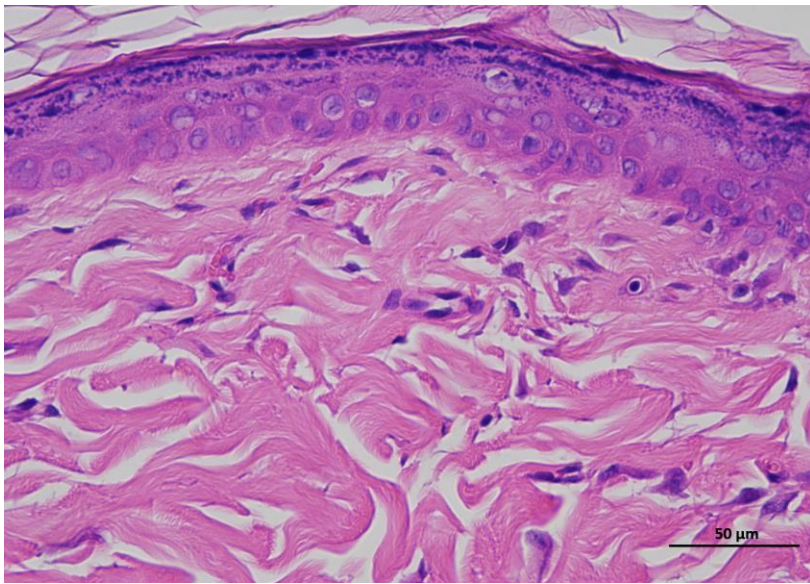
5 NControl 14day 400-3

Animal 6

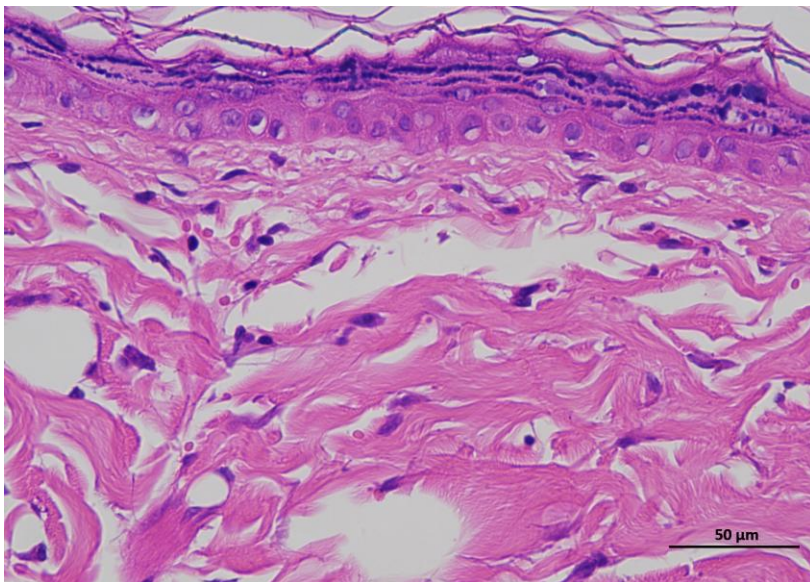
**Supplementary
Figure 3A |
Representative H&E
staining of skin
tissue of control
animals / Day 14.**



6 NControl 14day 400-1



6 NControl 14day 400-2



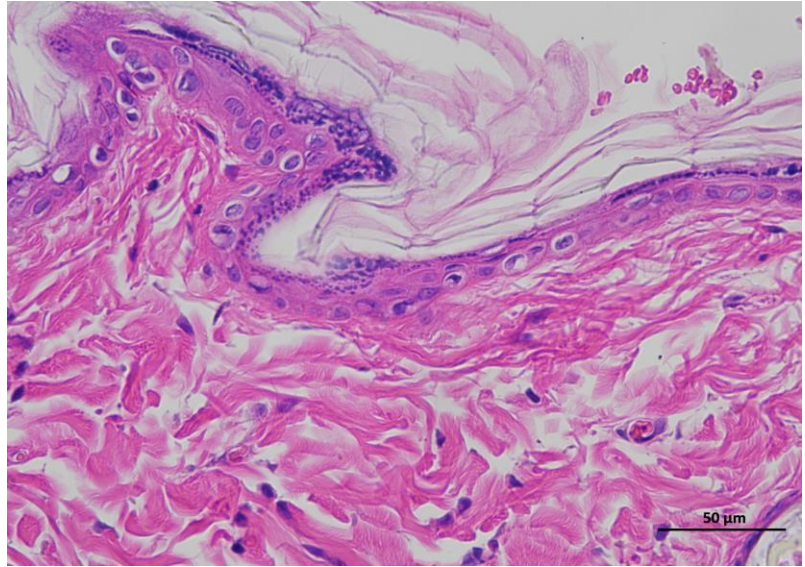
6 NControl 14day 400-3

Animal 1

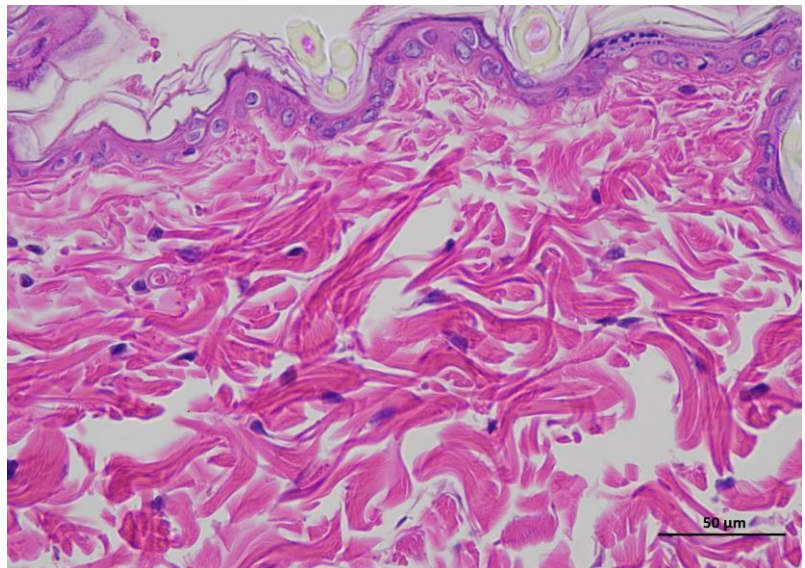
Supplementary Figure 2b | Representative H&E staining of skin tissue of diabetic control animals / Day 0.

Representative hematoxylin and eosin (H&E)-stained section of skin tissue collected from experimental rat. The image shows the typical architecture of the skin, including the epidermal layer with stratified keratinized epithelium and the underlying dermis composed of dense collagen fibers and connective tissue structures.

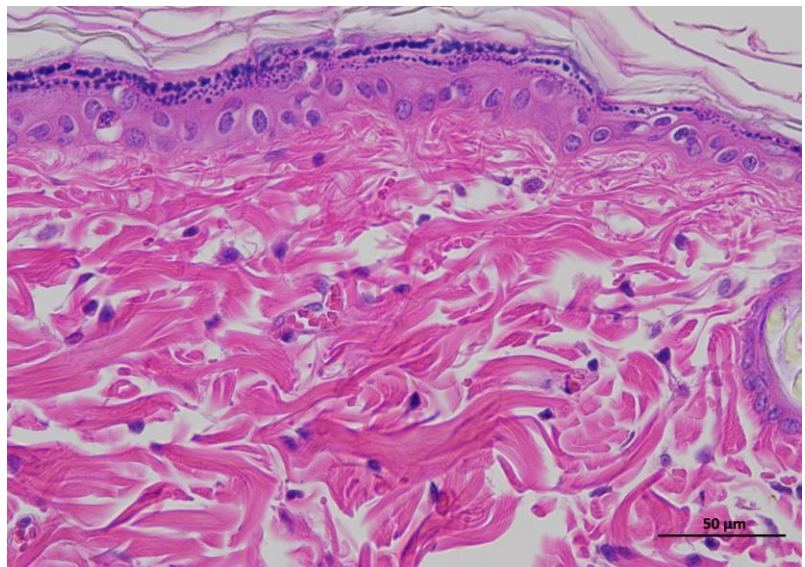
(n = 6 per group).



1 DControl 0day 400-1



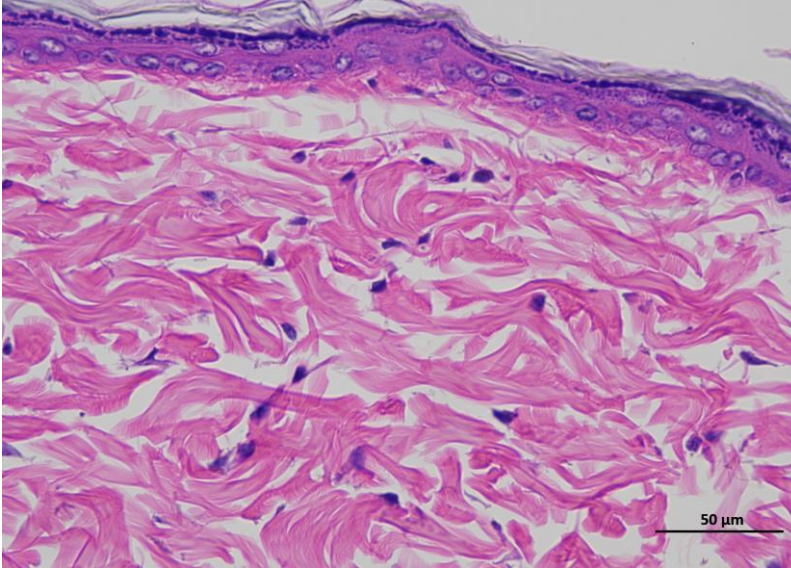
1 DControl 0day 400-2



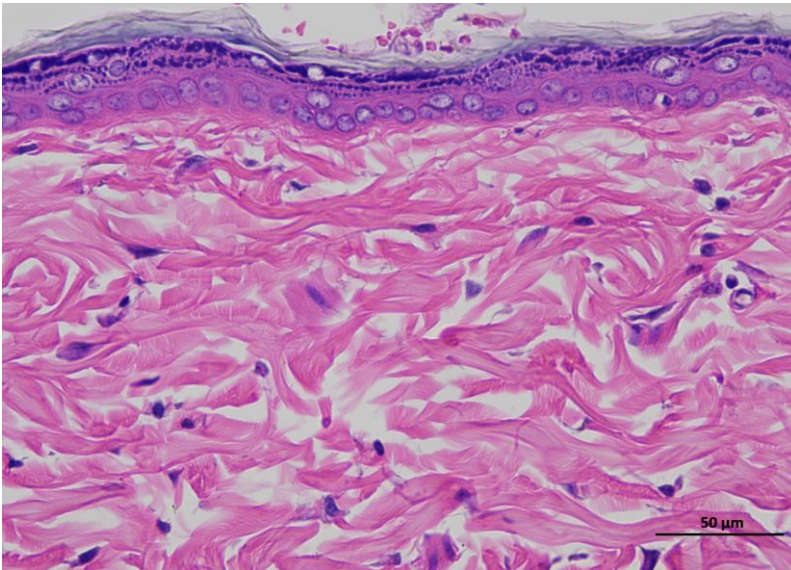
1 DControl 0day 400-3

Animal 2

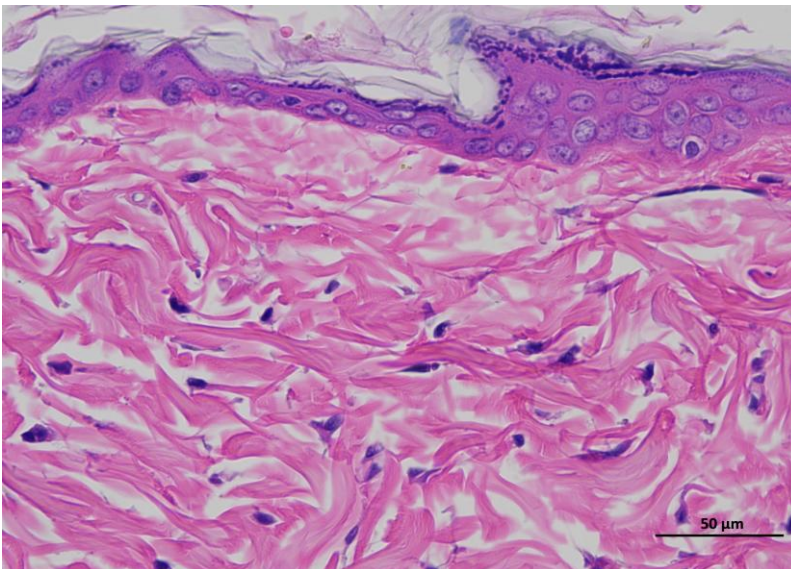
**Supplementary
Figure 2b |
Representative H&E
staining of skin
tissue of diabetic
control animals /
Day 0.**



2 DControl 0day 400-1



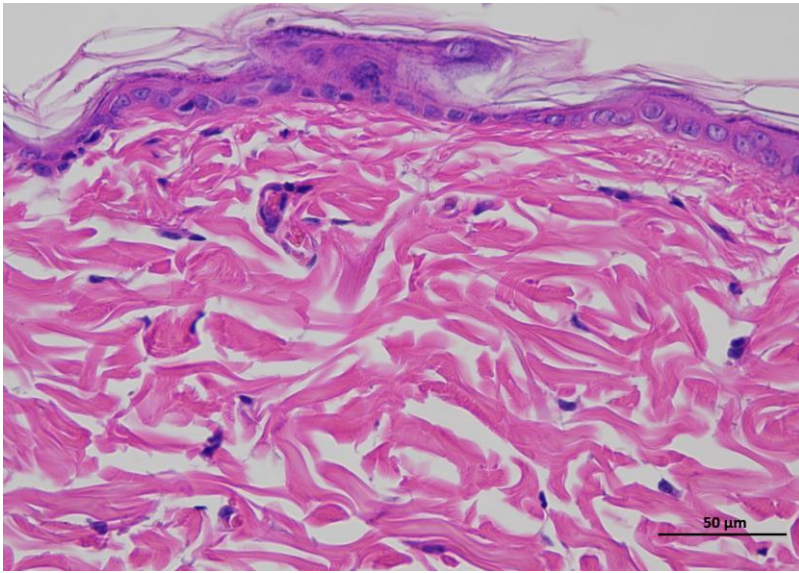
2 DControl 0day 400-2



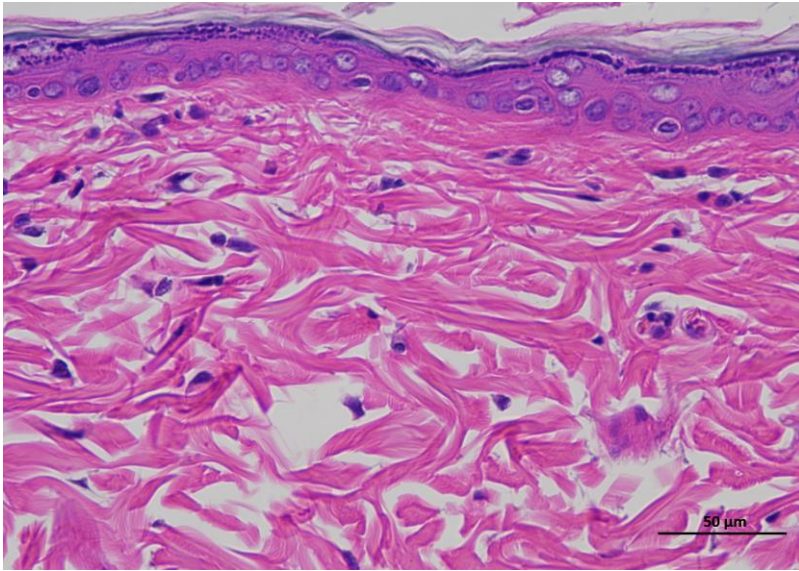
2 DControl 0day 400-3

Animal 3

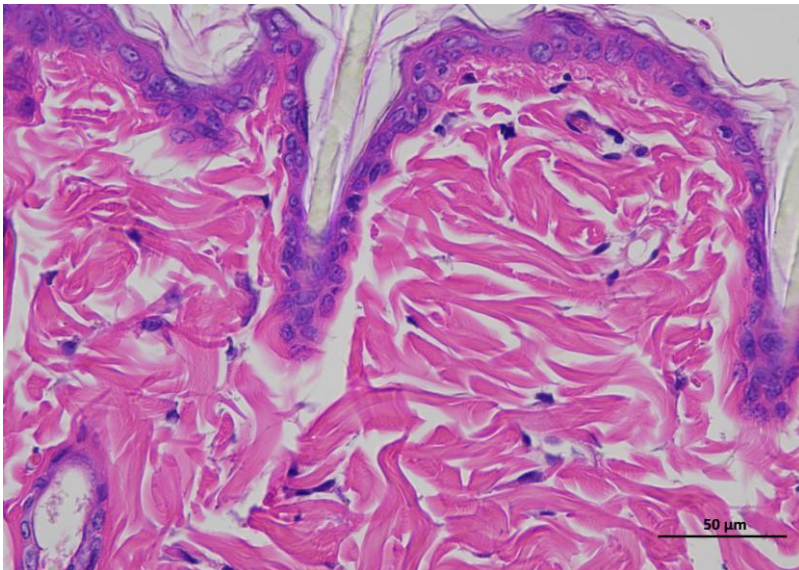
**Supplementary
Figure 2b |
Representative H&E
staining of skin
tissue of diabetic
control animals /
Day 0.**



3 DControl Oday 400-1



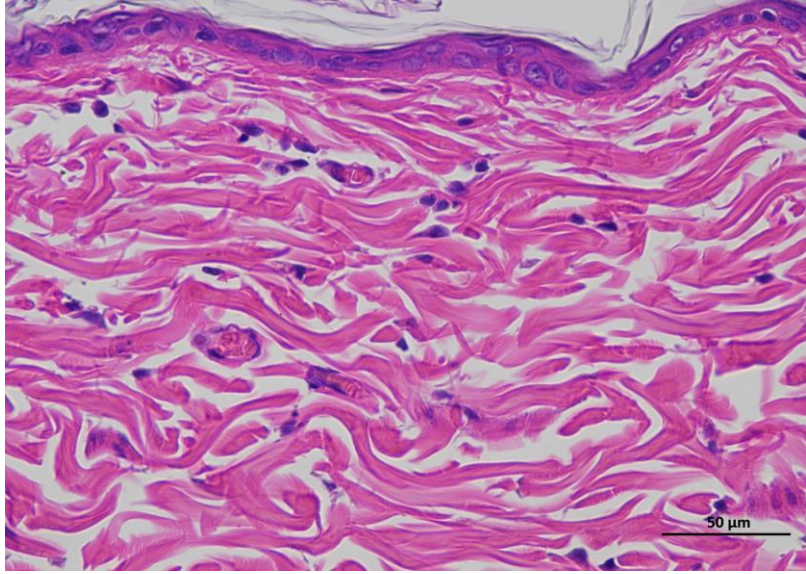
3 DControl Oday 400-2



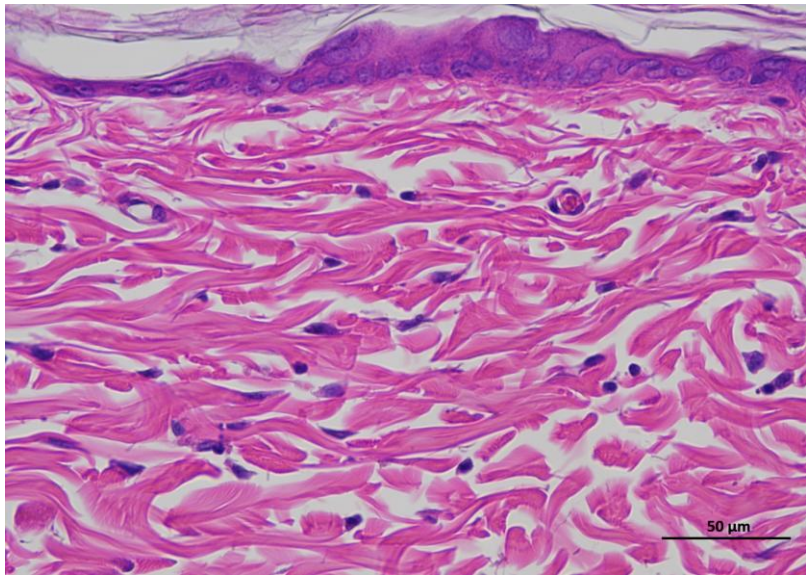
3 DControl Oday 400-3

Animal 4

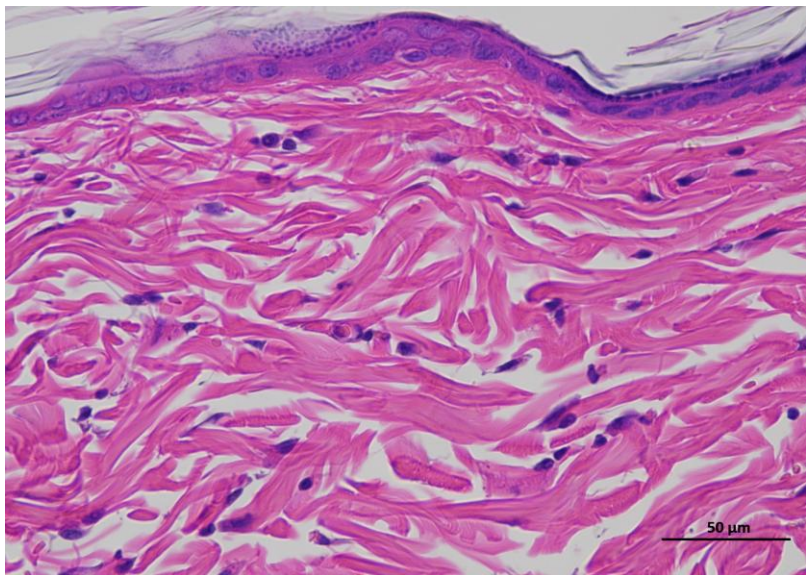
**Supplementary
Figure 2b |
Representative H&E
staining of skin
tissue of diabetic
control animals /
Day 0.**



4 DControl Oday 400-1



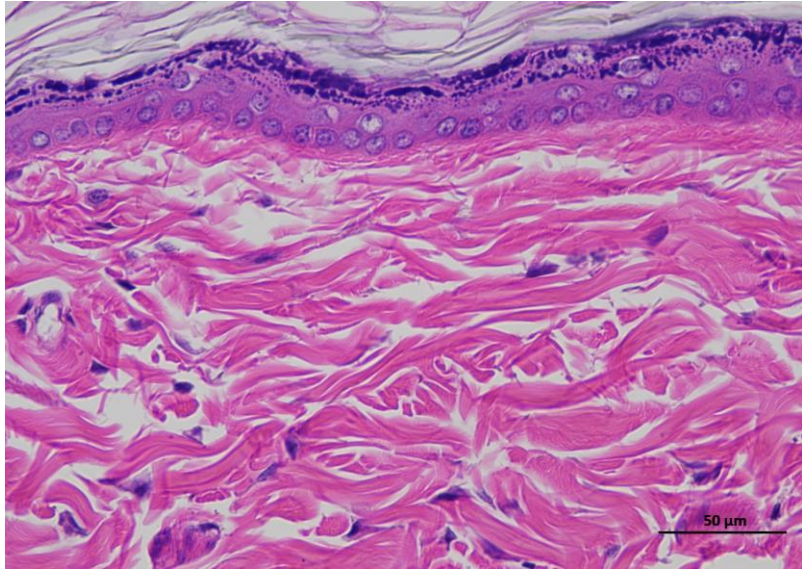
4 DControl Oday 400-2



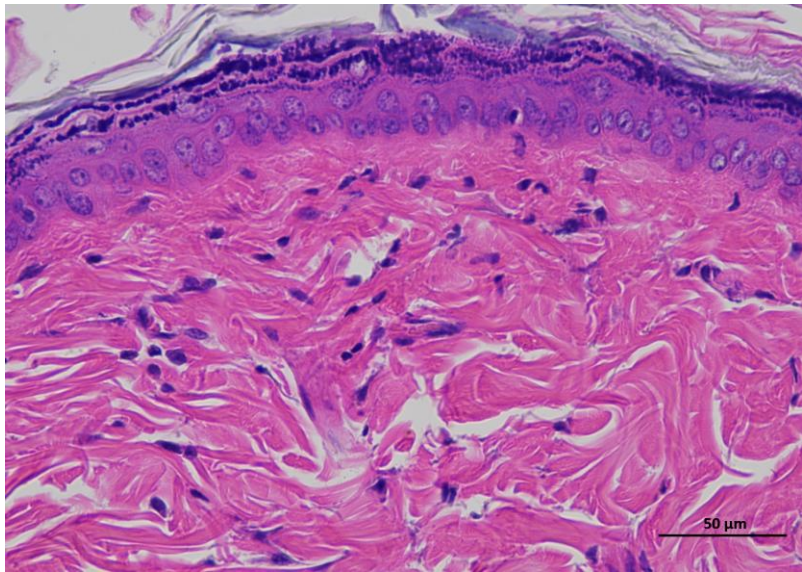
4 DControl Oday 400-3

Animal 5

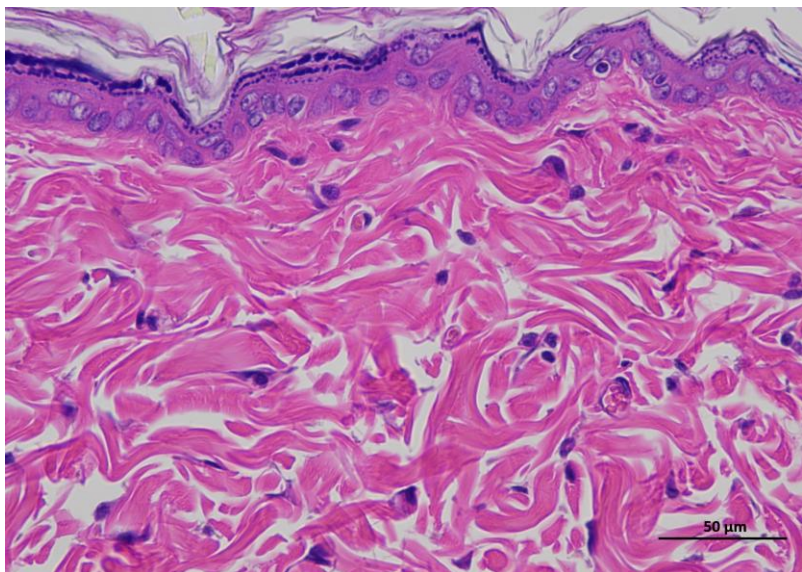
**Supplementary
Figure 2b |
Representative H&E
staining of skin
tissue of diabetic
control animals /
Day 0.**



5 DControl Oday 400-1



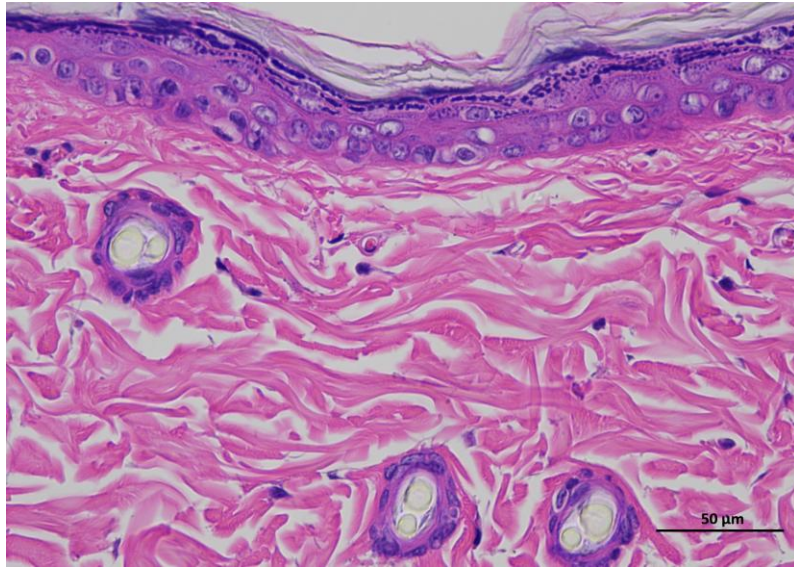
5 DControl Oday 400-2



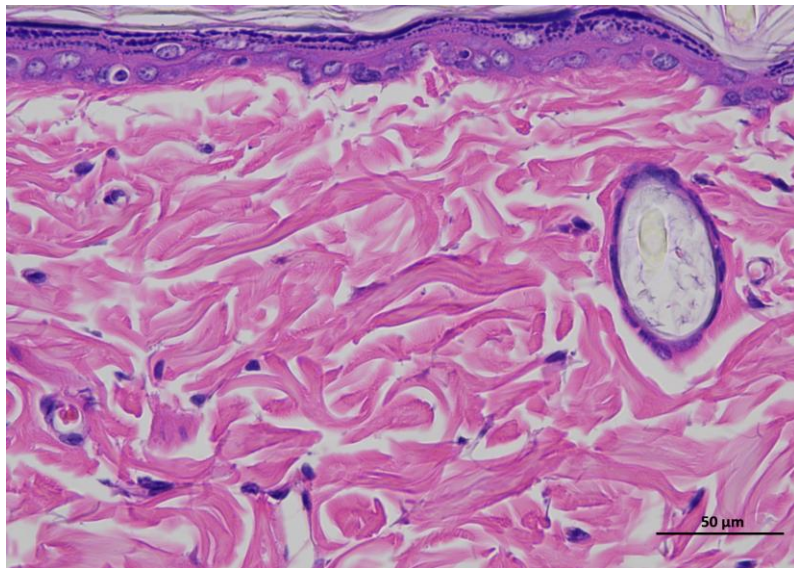
5 DControl Oday 400-3

Animal 6

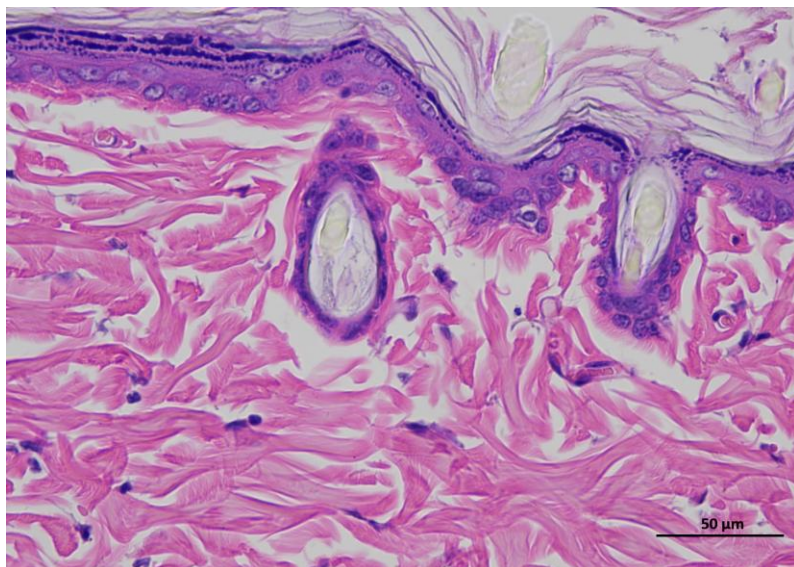
Supplementary
Figure 2b |
Representative H&E
staining of skin
tissue of diabetic
control animals /
Day 0.



6 DControl Oday 400-1



6 DControl Oday 400-2



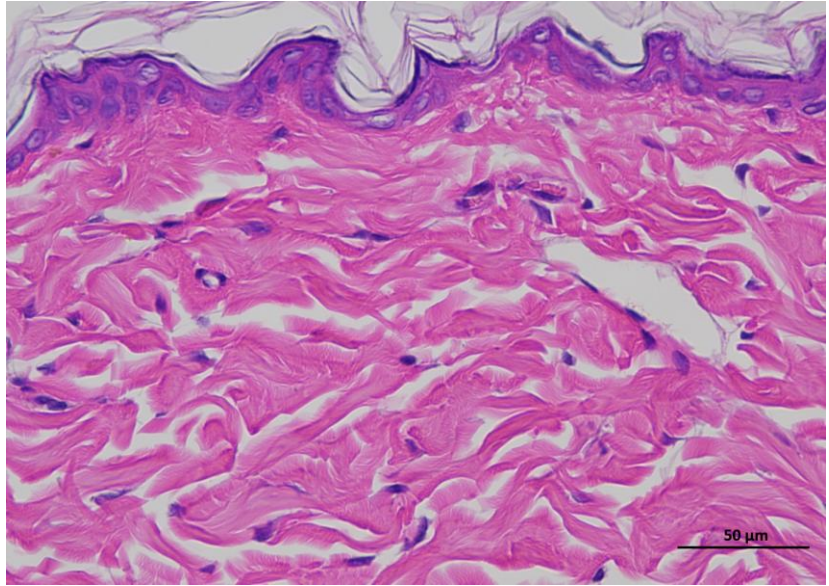
6 DControl Oday 400-3

Animal 1

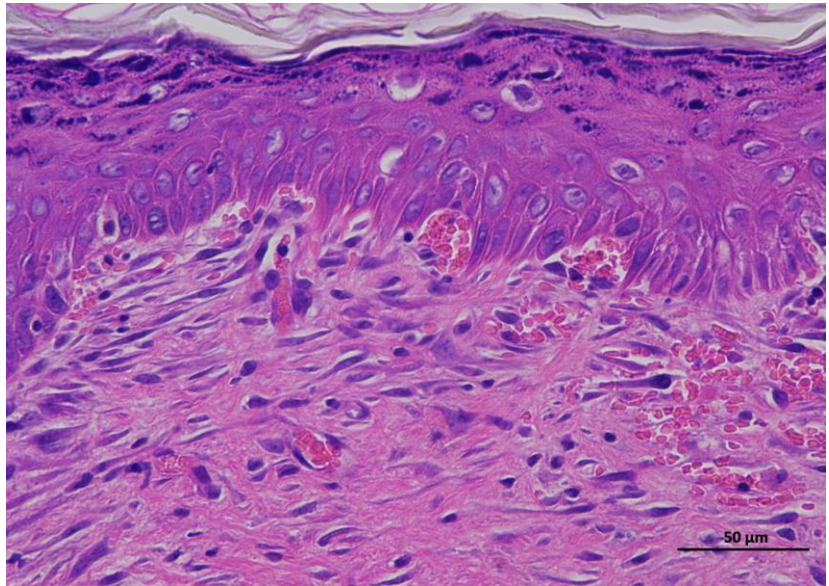
Supplementary Figure 3b | Representative H&E staining of skin tissue of diabetic control animals / Day 14.

Representative hematoxylin and eosin (H&E)-stained section of skin tissue collected from experimental rat. The image shows the typical architecture of the skin, including the epidermal layer with stratified keratinized epithelium and the underlying dermis composed of dense collagen fibers and connective tissue structures.

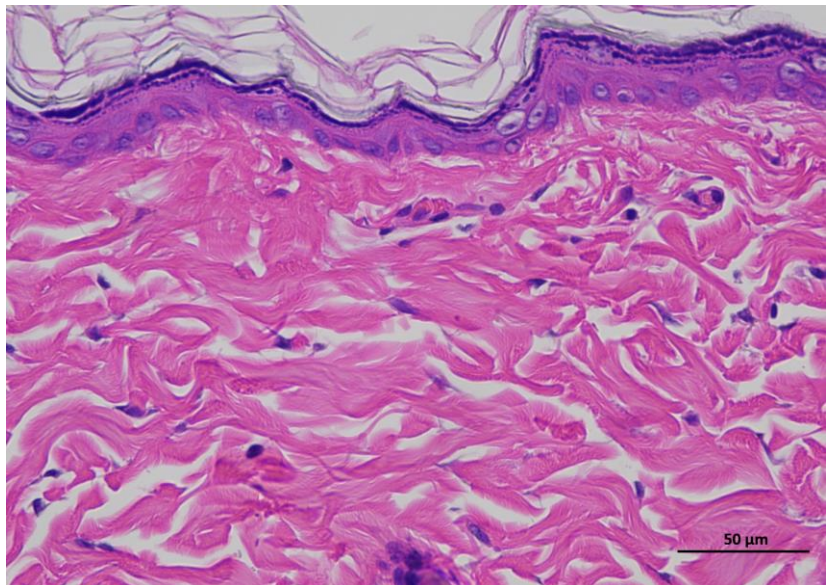
(n = 6 per group).



1 DControl 14day 400-1



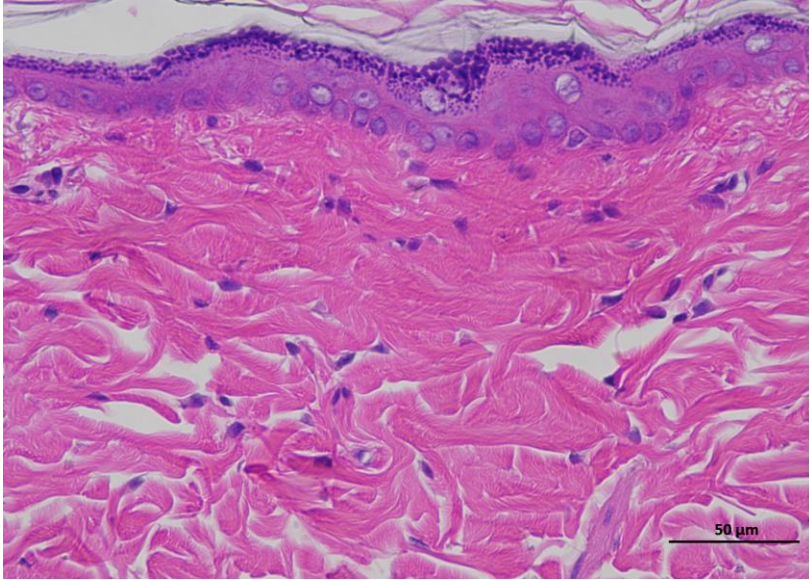
1 DControl 14day 400-2



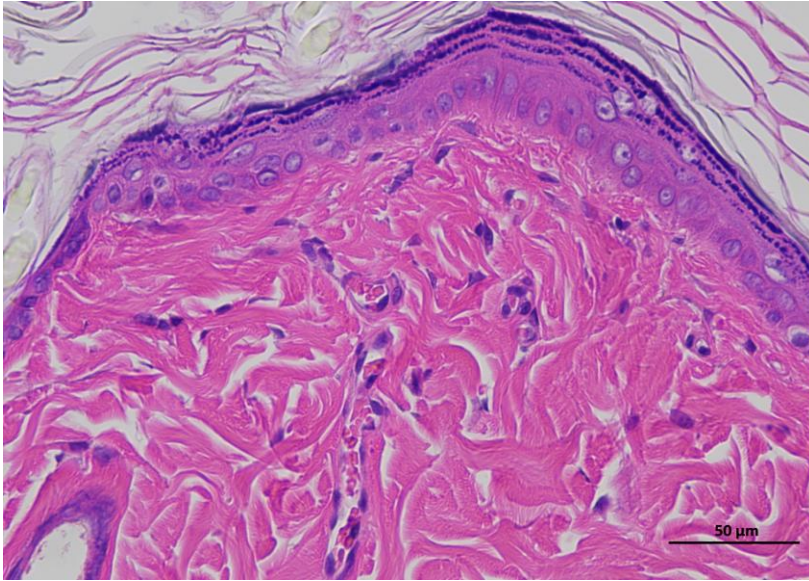
1 DControl 14day 400-3

Animal 2

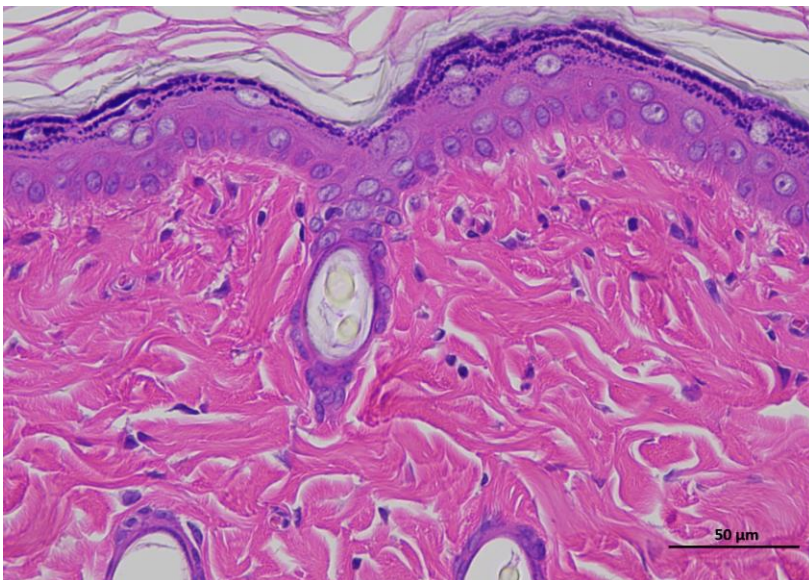
**Supplementary
Figure 3b |
Representative H&E
staining of skin
tissue of diabetic
control animals /
Day 14.**



2 DControl 14day 400-1



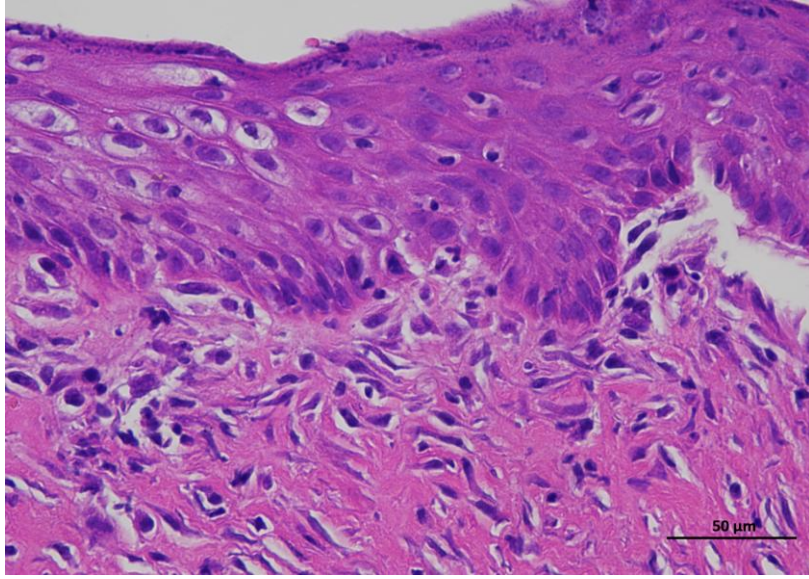
2 DControl 14day 400-2



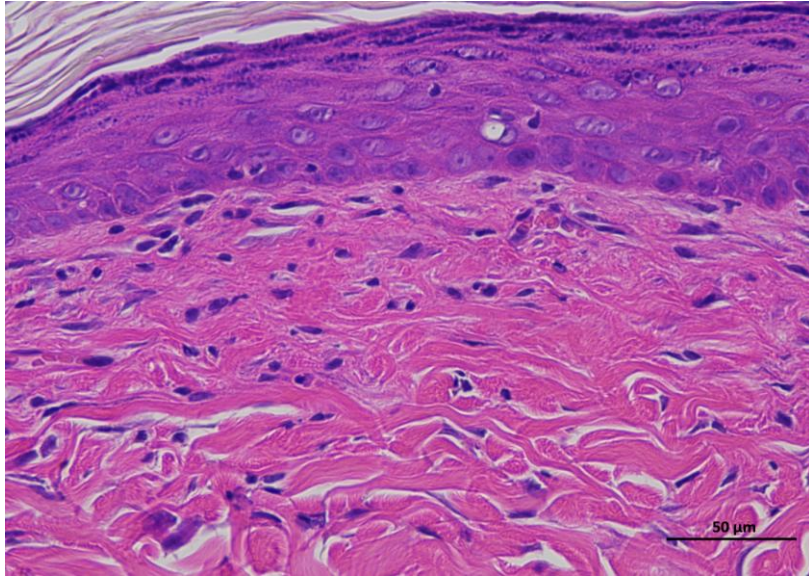
2 DControl 14day 400-3

Animal 3

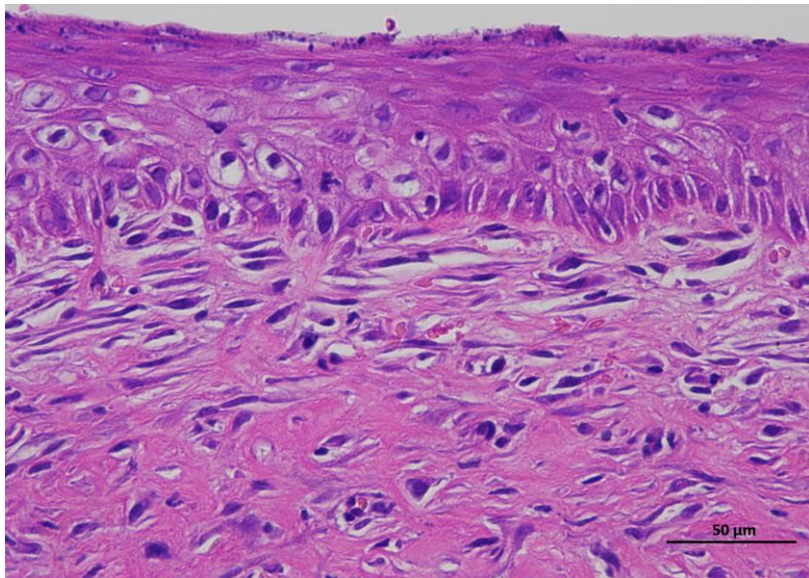
**Supplementary
Figure 3b |
Representative H&E
staining of skin
tissue of diabetic
control animals /
Day 14.**



3 DControl 14day 400-1



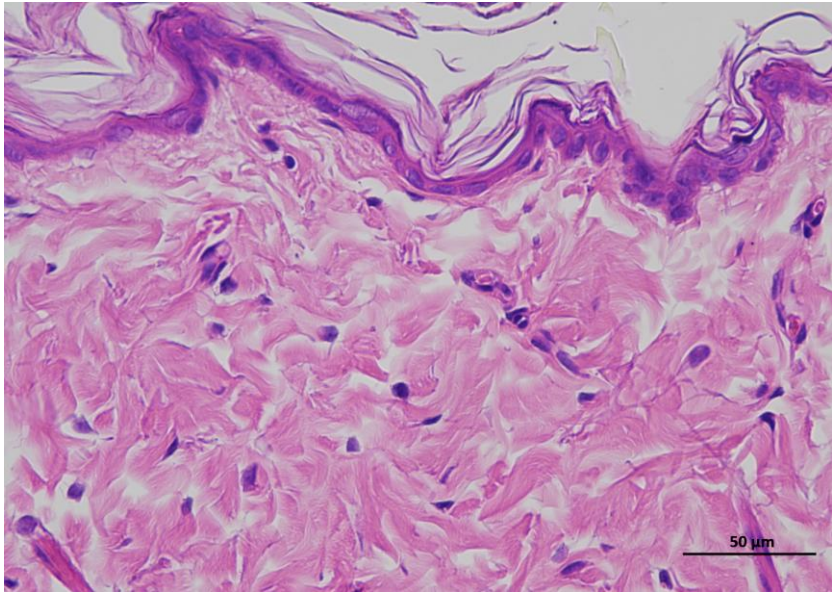
3 DControl 14day 400-2



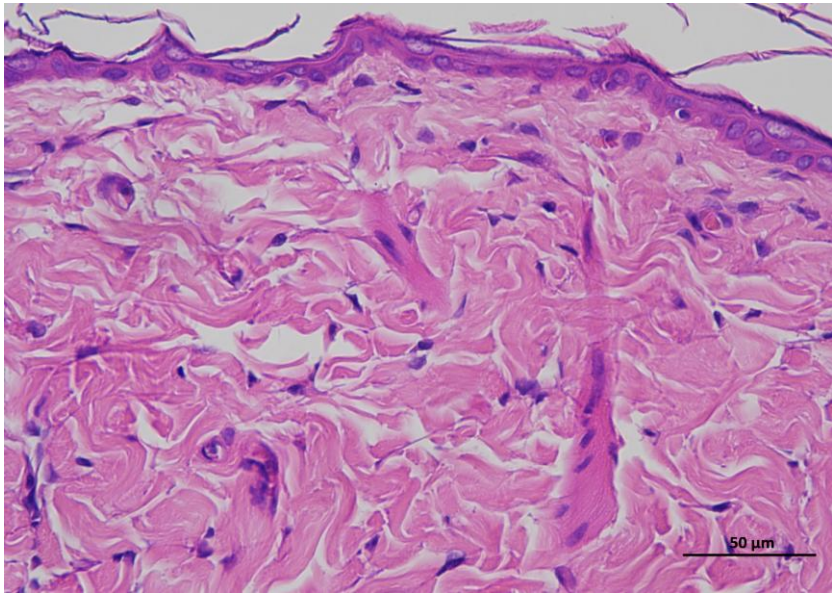
3 DControl 14day 400-3

Animal 5

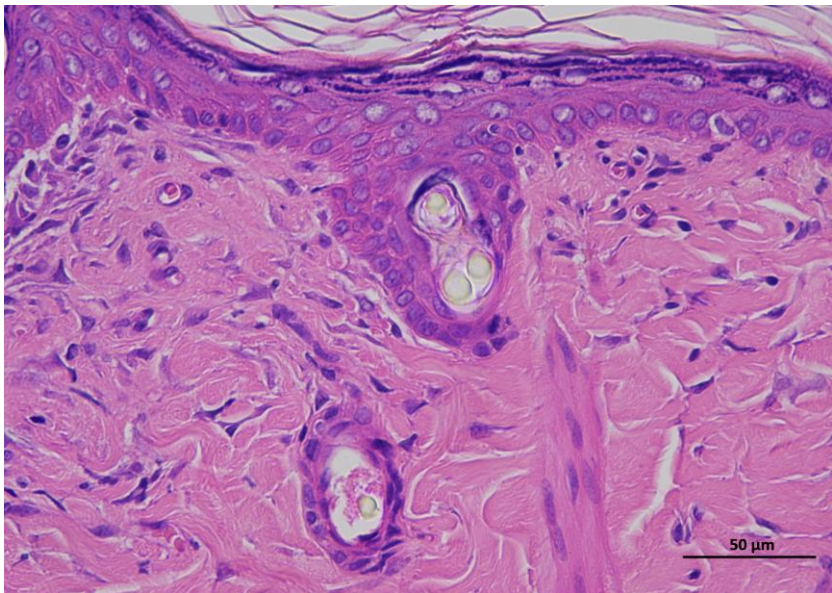
**Supplementary
Figure 3b |
Representative H&E
staining of skin
tissue of diabetic
control animals /
Day 14.**



5 DControl 14day 400-1



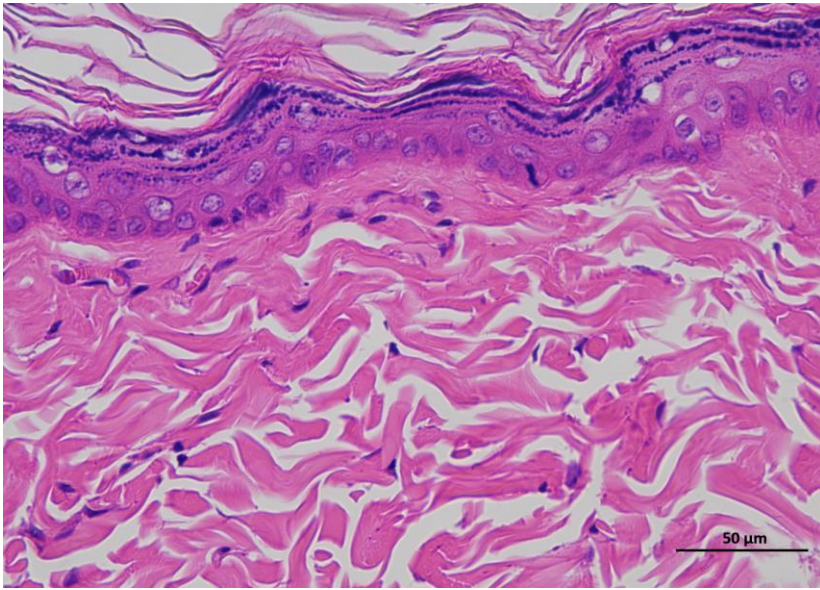
5 DControl 14day 400-2



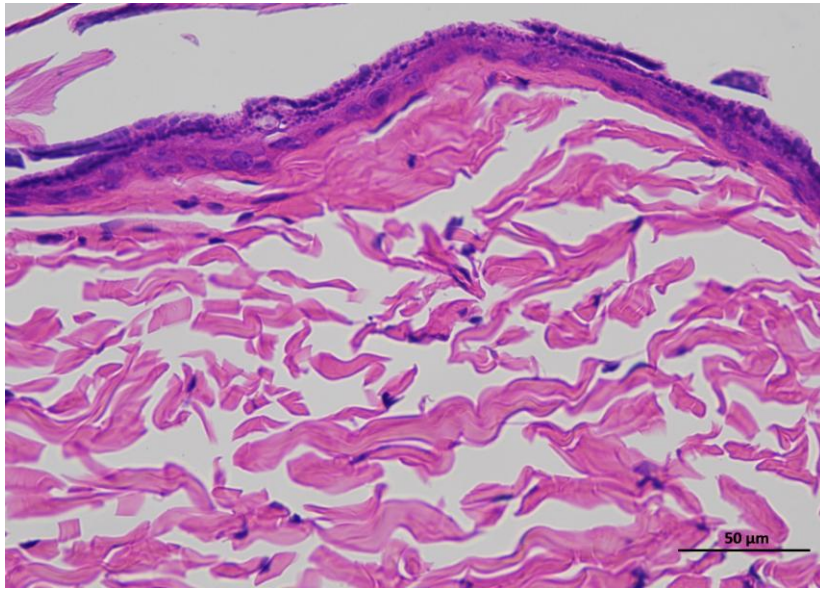
5 DControl 14day 400-3

Animal 6

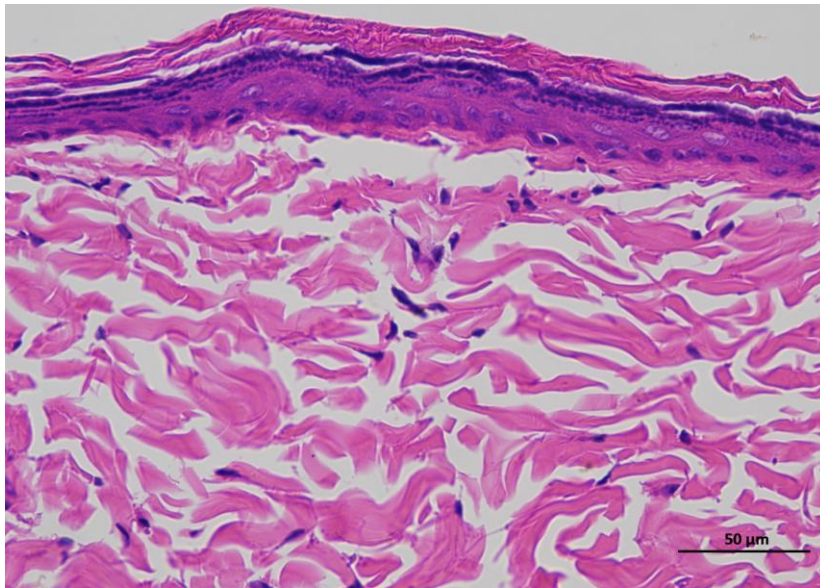
**Supplementary
Figure 3b |
Representative H&E
staining of skin
tissue of diabetic
control animals /
Day 14.**



6 DControl 14day 400-1



6 DControl 14day 400-2

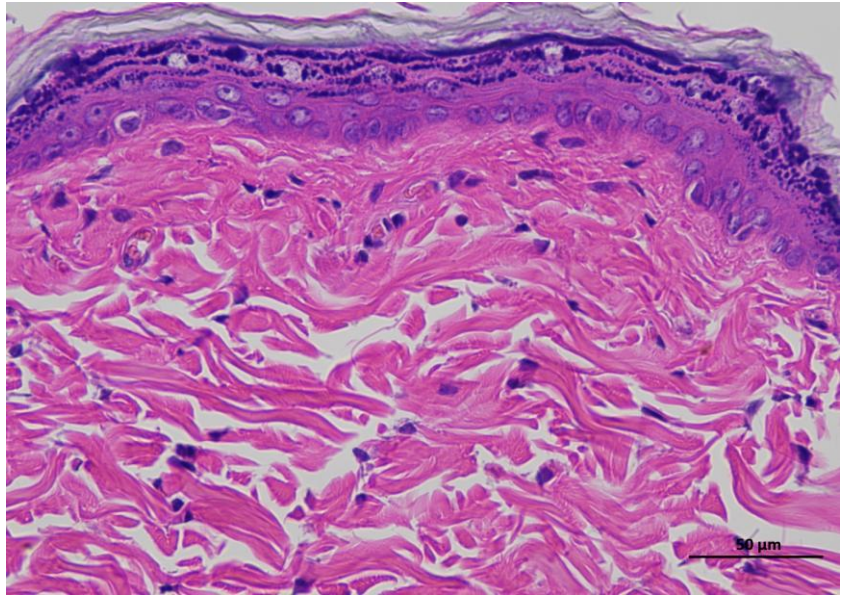


6 DControl 14day 400-3

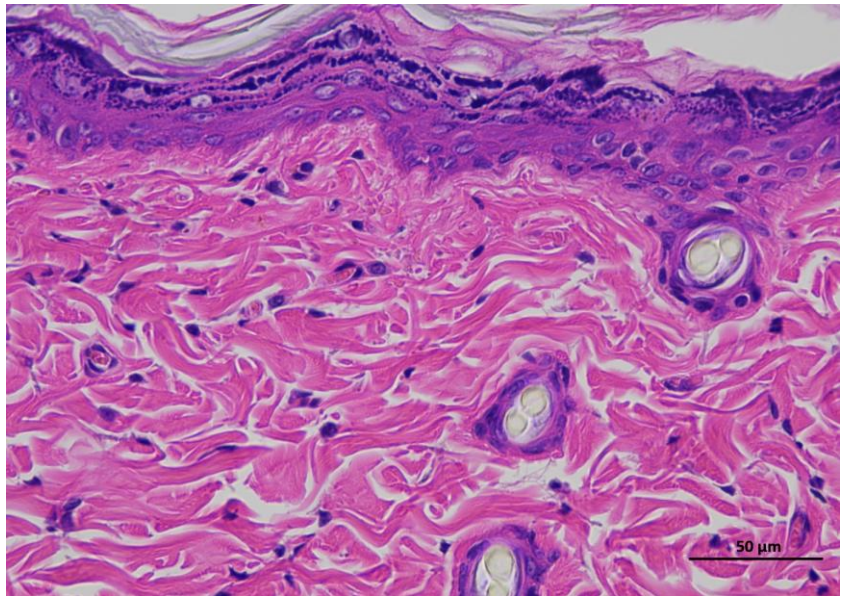
Animal 1

Supplementary Figure 2c | Representative H&E staining of skin tissue of mRNA LNPs-L animals / Day 0.

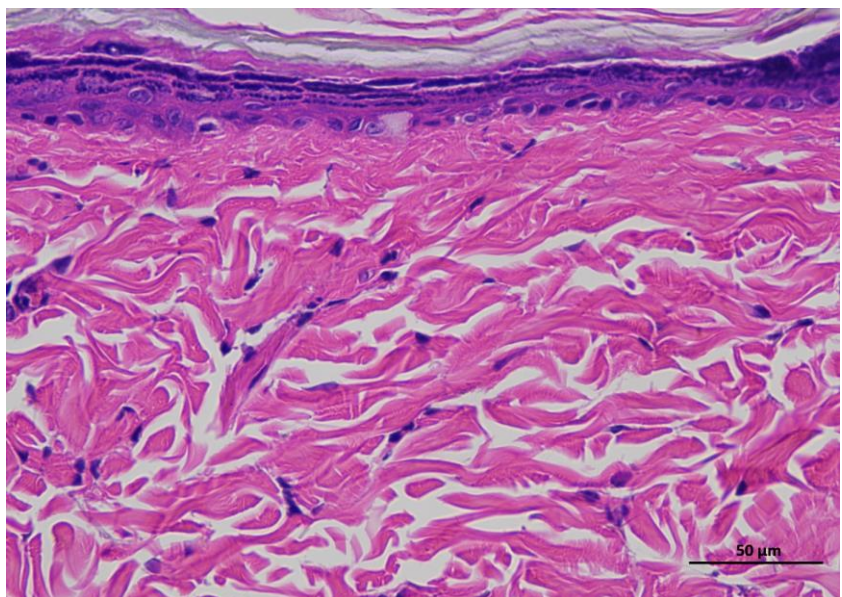
Representative hematoxylin and eosin (H&E)-stained section of skin tissue collected from experimental rat. The image shows the typical architecture of the skin, including the epidermal layer with stratified keratinized epithelium and the underlying dermis composed of dense collagen fibers and connective tissue structures. (n = 6 per group).



1 mRNA LNPs-L 0day 400-1



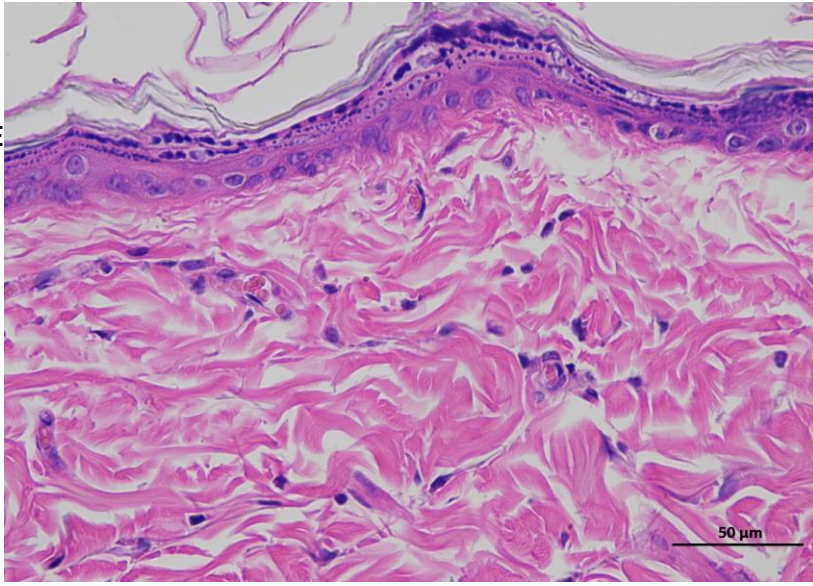
1 mRNA LNPs-L 0day 400-2



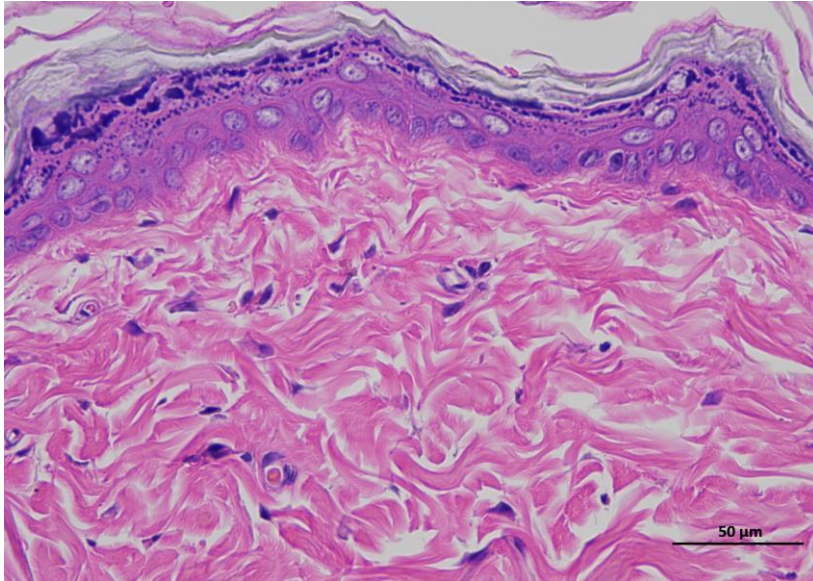
1 mRNA LNPs-L 0day 400-3

Animal 2

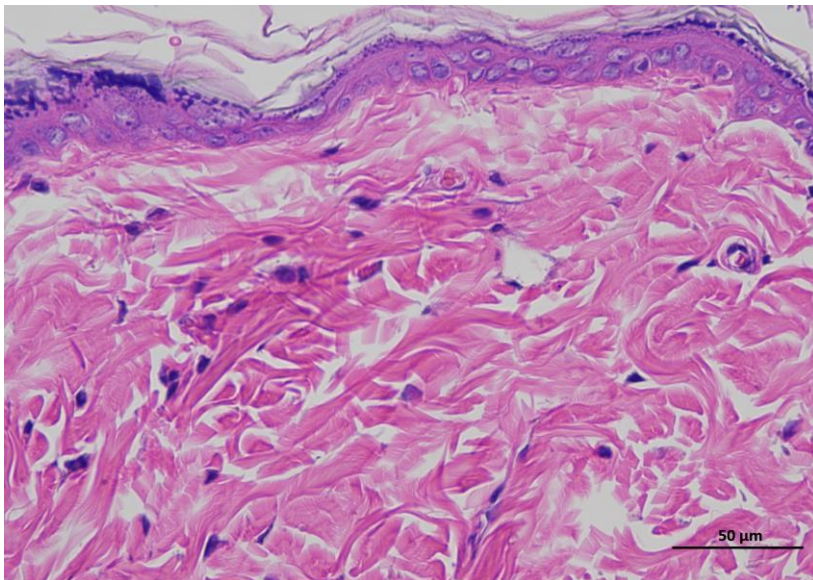
**Supplementary
Figure 2c |
Representative H&E
staining of skin
tissue of mRNA
LNPs-L animals /
Day 0.**



2 mRNA LNPs-L Oday 400-1



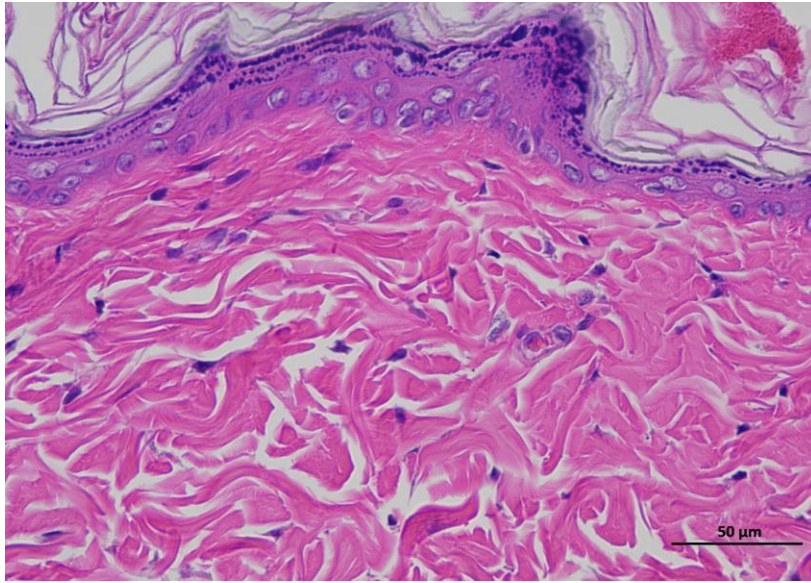
2 mRNA LNPs-L Oday 400-2



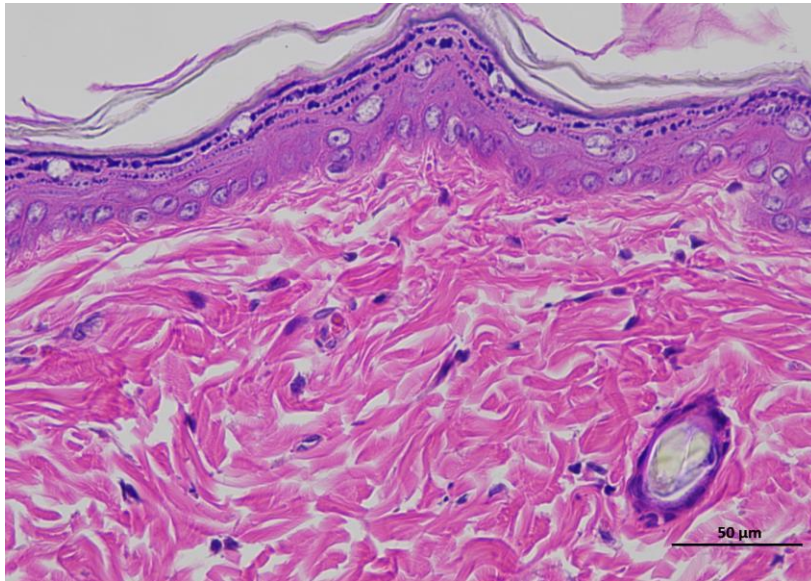
2 mRNA LNPs-L Oday 400-3

Animal 3

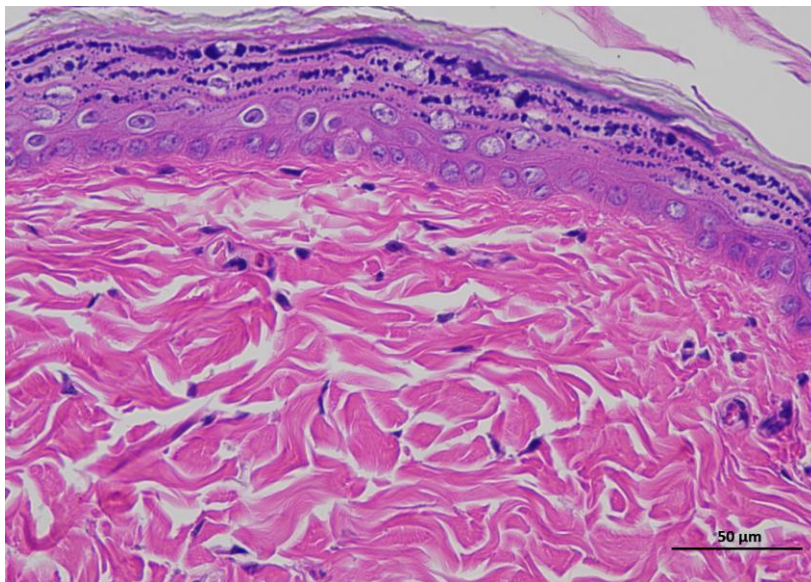
**Supplementary
Figure 2c |
Representative H&E
staining of skin
tissue of mRNA
LNPs-L animals /
Day 0.**



3 mRNA LNPs-L 0day 400-1



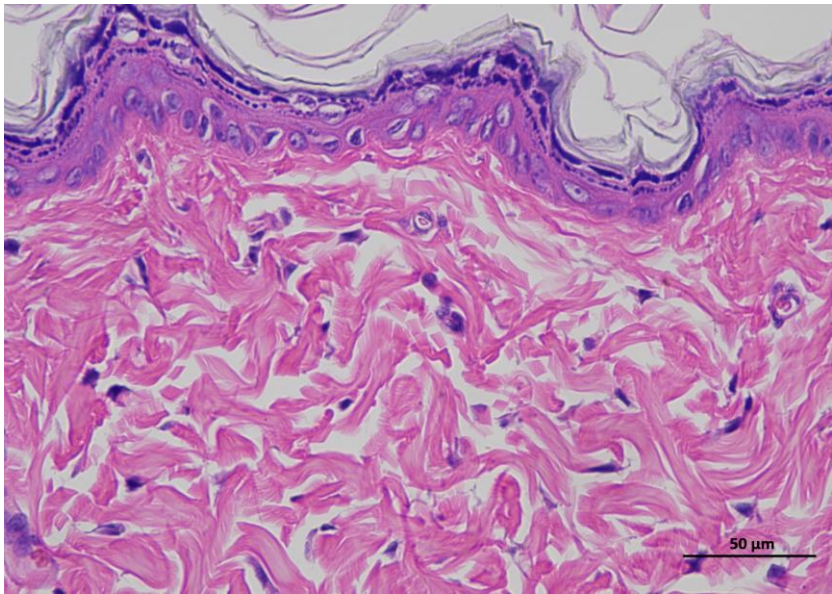
3 mRNA LNPs-L 0day 400-2



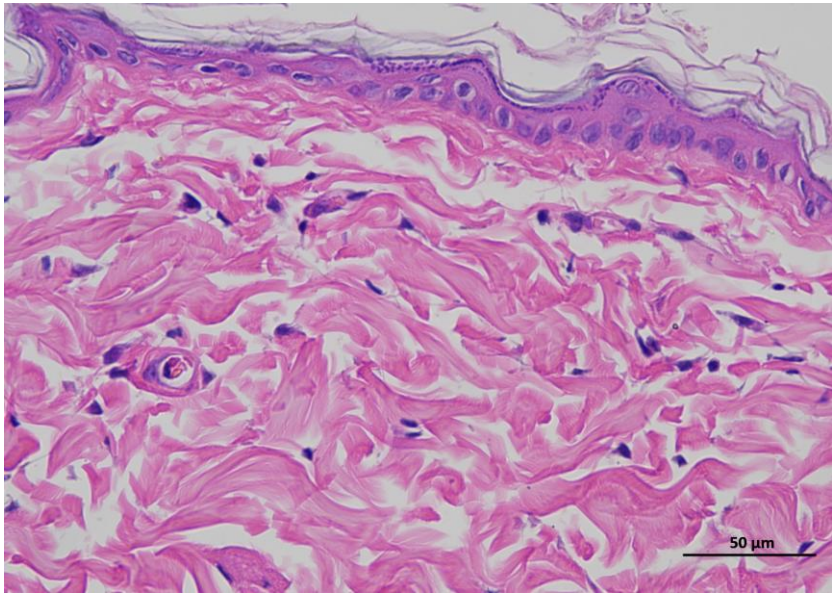
3 mRNA LNPs-L 0day 400-3

Animal 4

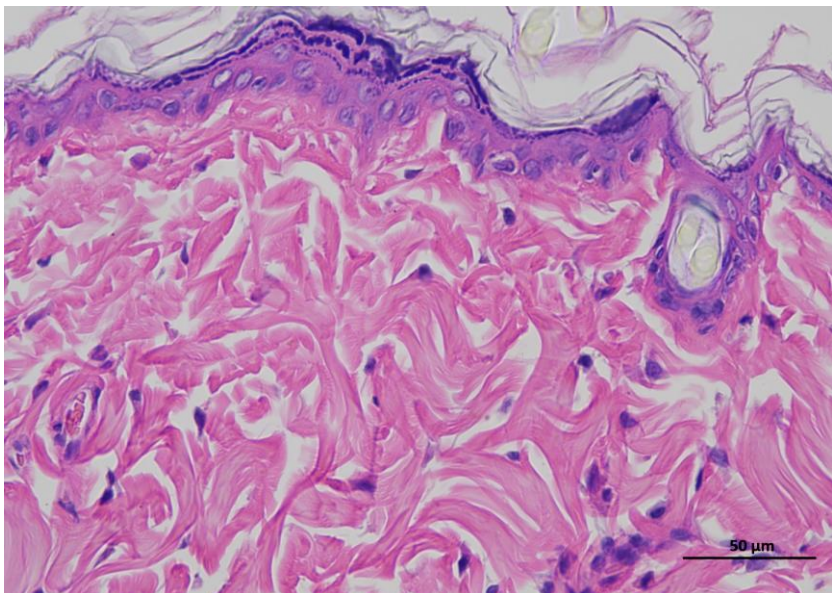
**Supplementary
Figure 2c |
Representative H&E
staining of skin
tissue of mRNA
LNPs-L animals /
Day 0.**



4 mRNA LNPs-L 0day 400-1



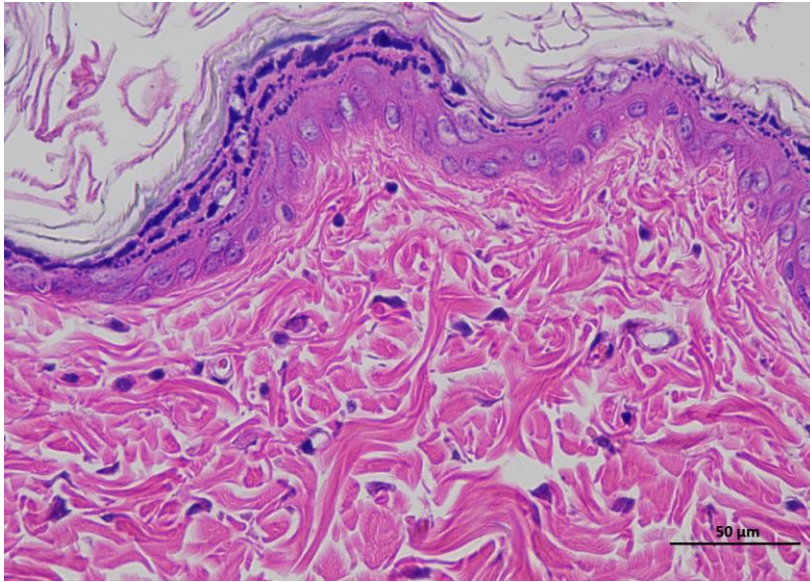
4 mRNA LNPs-L 0day 400-2



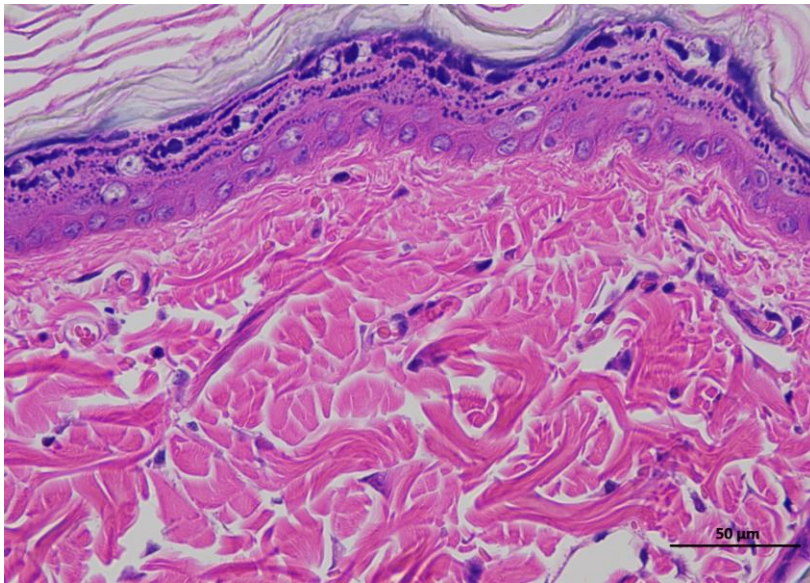
4 mRNA LNPs-L 0day 400-3

Animal 5

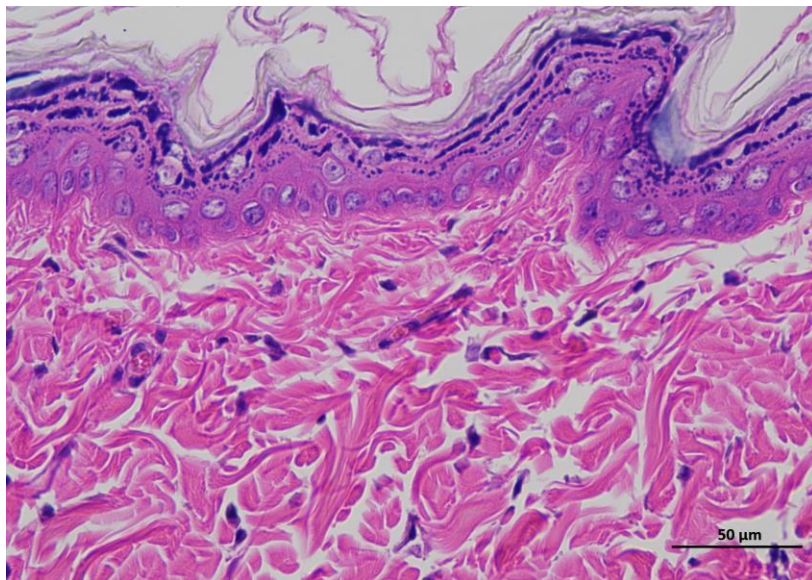
**Supplementary
Figure 2c |
Representative H&E
staining of skin
tissue of mRNA
LNPs-L animals /
Day 0.**



5 mRNA LNPs-L 0day 400-1



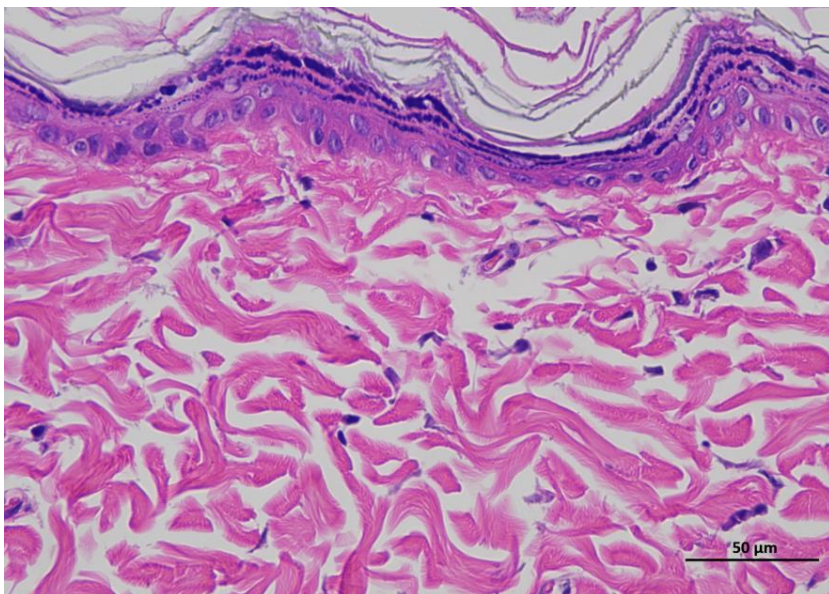
5 mRNA LNPs-L 0day 400-2



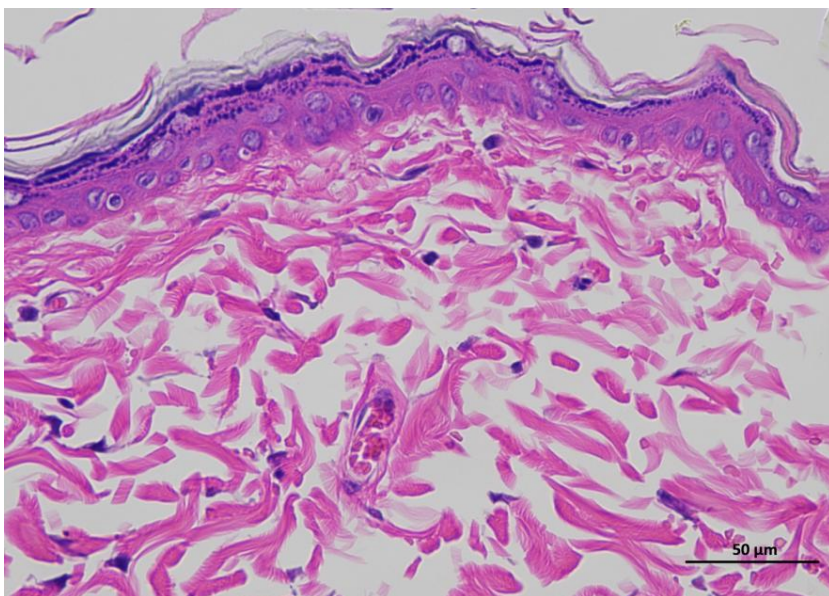
5 mRNA LNPs-L 0day 400-3

Animal 6

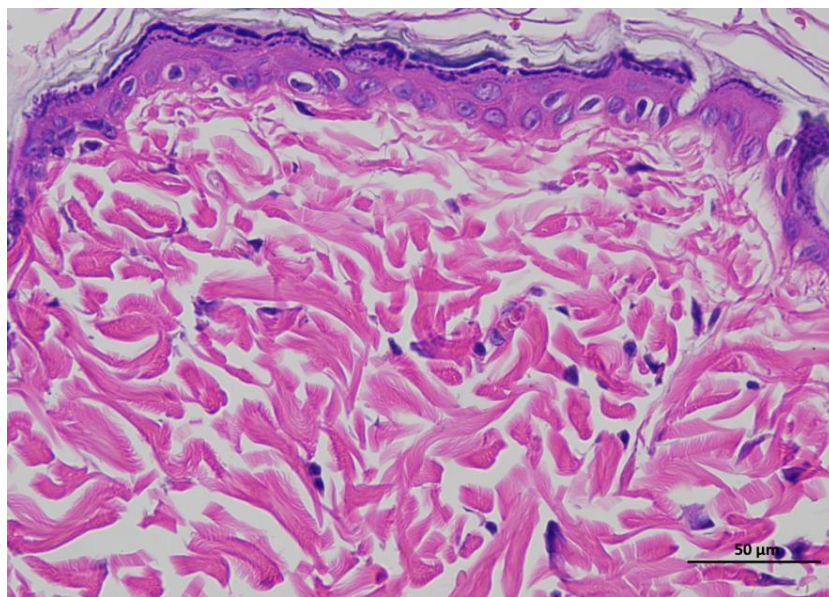
**Supplementary
Figure 2c |
Representative H&E
staining of skin
tissue of mRNA
LNPs-L animals /
Day 0.**



6 mRNA LNPs-L 0day 400-1



6 mRNA LNPs-L 0day 400-2



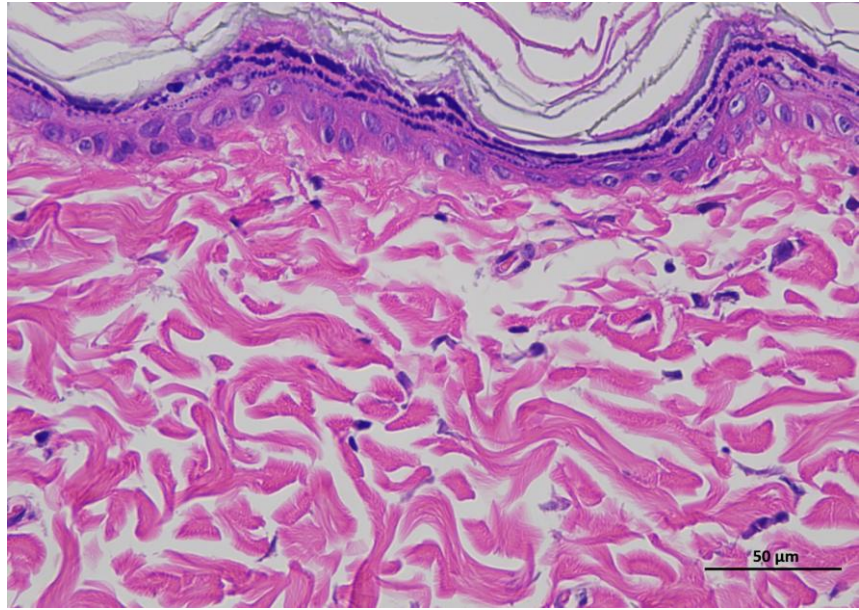
6 mRNA LNPs-L 0day 400-3

Animal 1

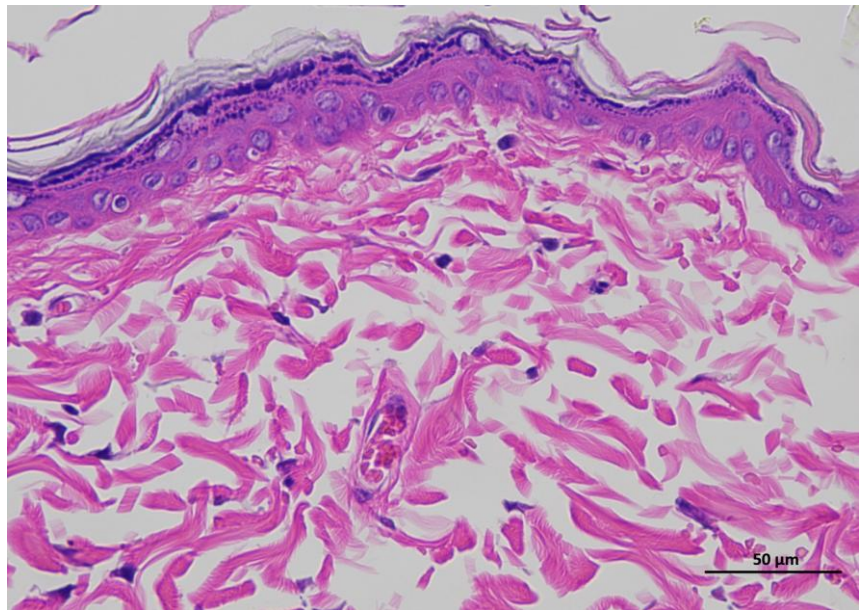
Supplementary Figure 3c | Representative H&E staining of skin tissue of mRNA LNPs-L animals / Day 14.

Representative hematoxylin and eosin (H&E)-stained section of skin tissue collected from experimental rat. The image shows the typical architecture of the skin, including the epidermal layer with stratified keratinized epithelium and the underlying dermis composed of dense collagen fibers and connective tissue structures.

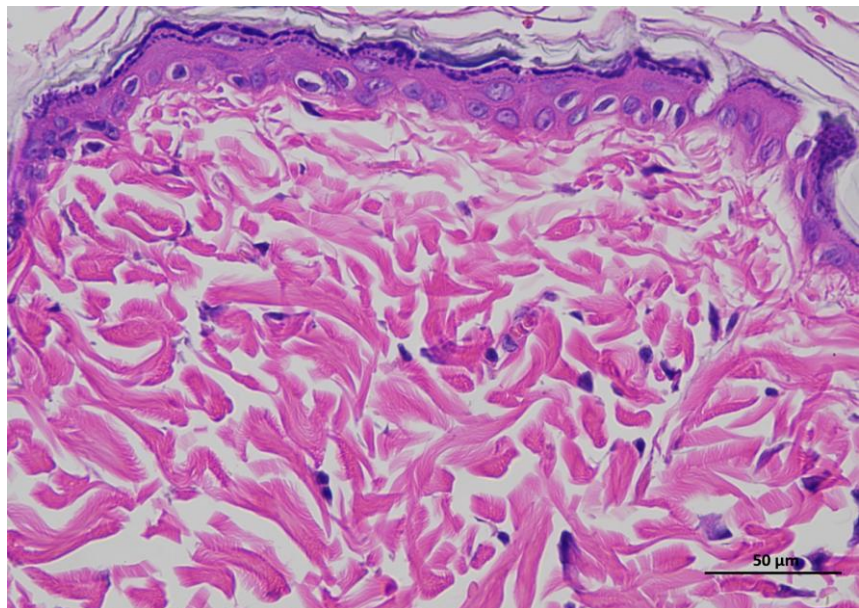
(n = 6 per group).



1 mRNA LNPs-L 14day 400-1



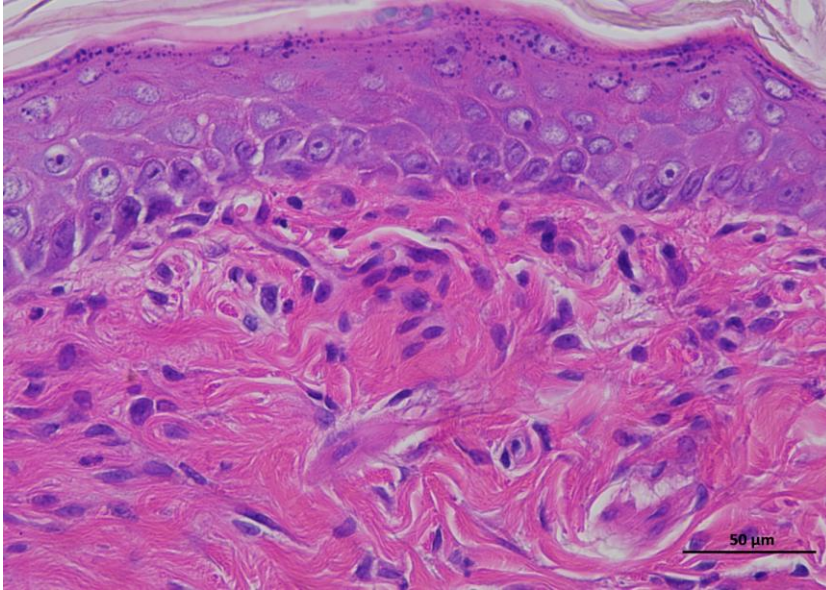
1 mRNA LNPs-L 14day 400-2



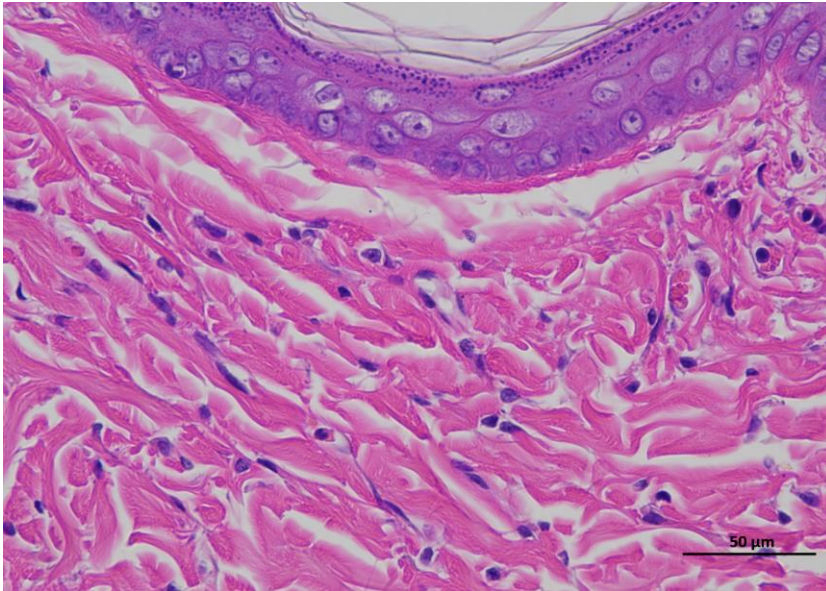
1 mRNA LNPs-L 14day 400-3

Animal 2

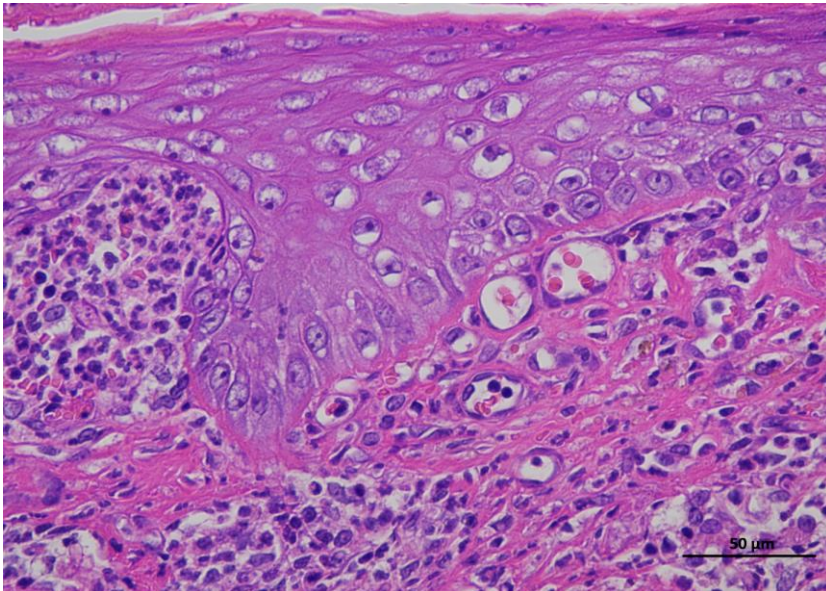
**Supplementary
Figure 3c |
Representative H&E
staining of skin
tissue of mRNA
LNPs-L animals /
Day 14.**



2 mRNA LNPs-L 14day 400-1



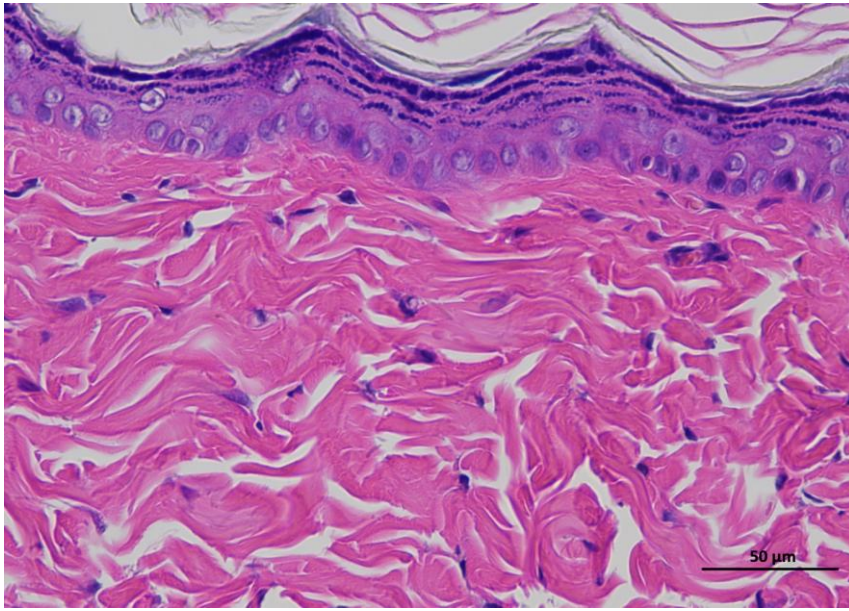
2 mRNA LNPs-L 14day 400-2



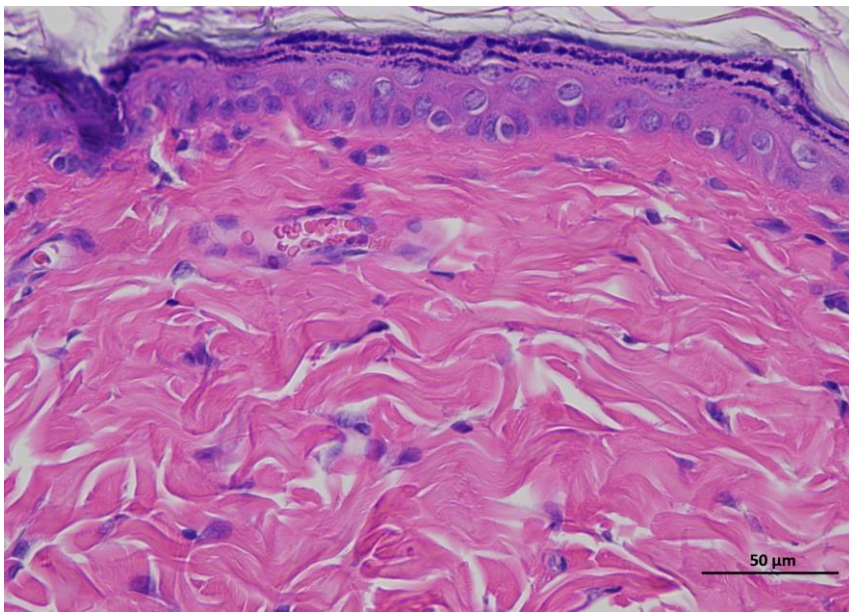
2 mRNA LNPs-L 14day 400-3

Animal 3

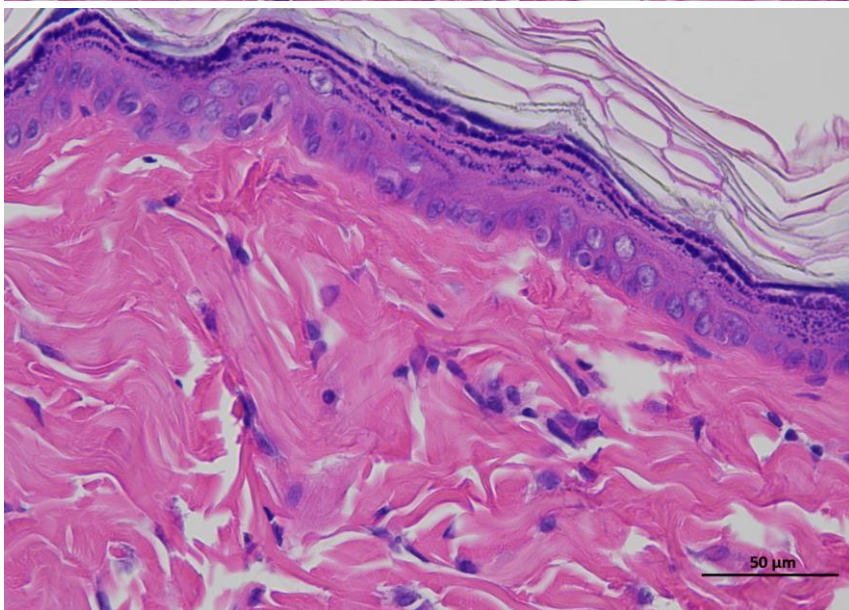
**Supplementary
Figure 3c |
Representative H&E
staining of skin
tissue of mRNA
LNPs-L animals /
Day 14.**



3 mRNA LNPs-L 14day 400-1



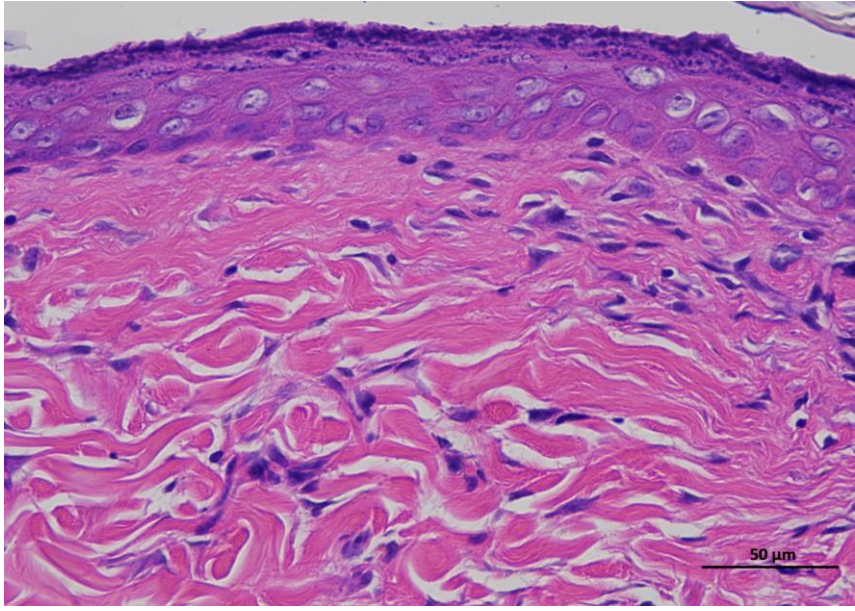
3 mRNA LNPs-L 14day 400-2



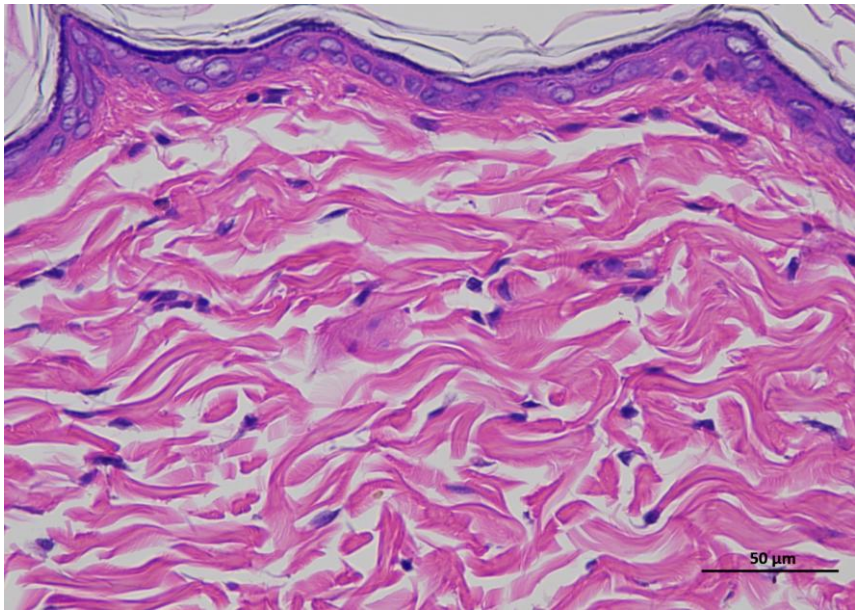
3 mRNA LNPs-L 14day 400-3

Animal 4

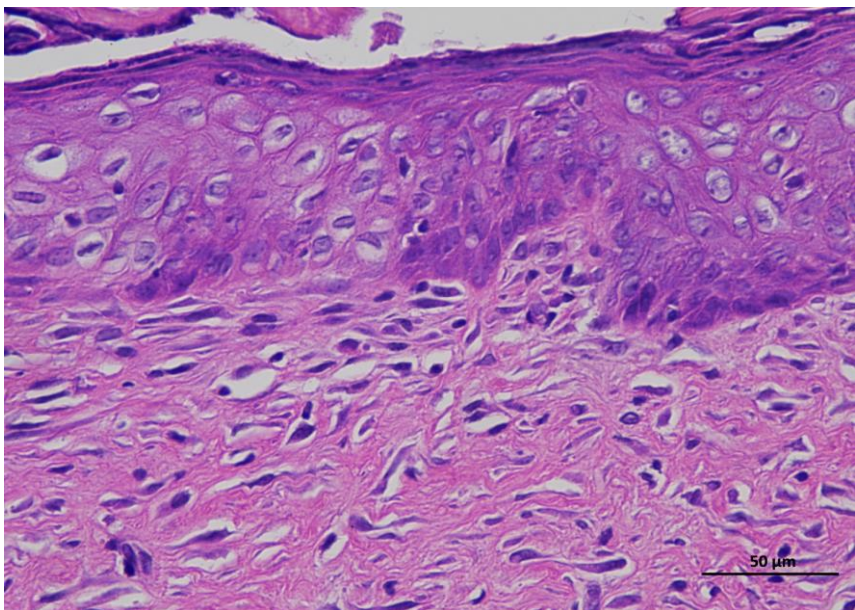
**Supplementary
Figure 3c |
Representative H&E
staining of skin
tissue of mRNA
LNPs-L animals /
Day 14.**



4 mRNA LNPs-L 14day 400-1



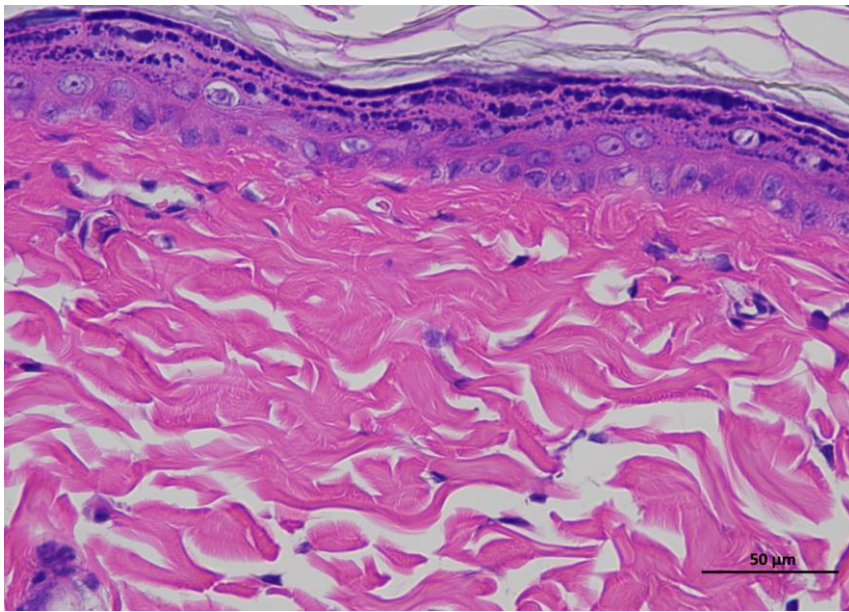
4 mRNA LNPs-L 14day 400-2



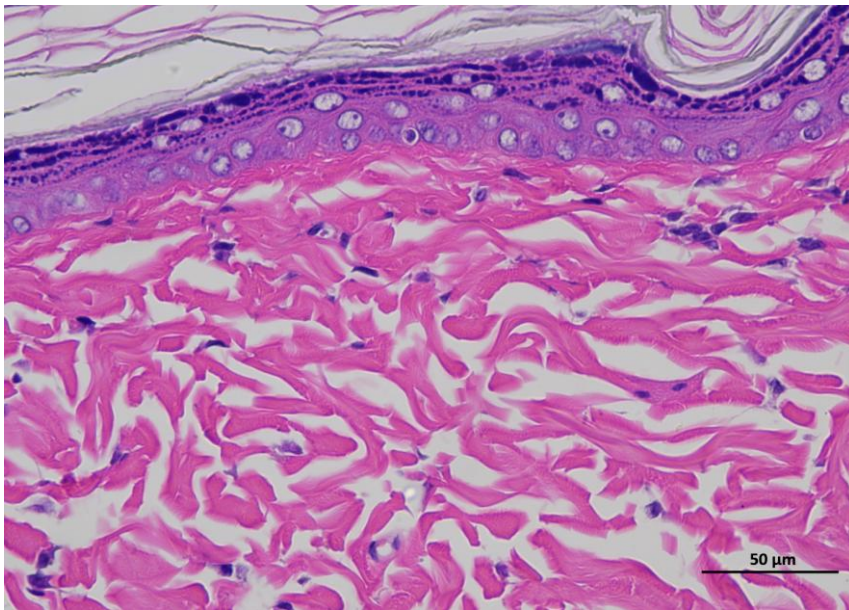
4 mRNA LNPs-L 14day 400-3

Animal 5

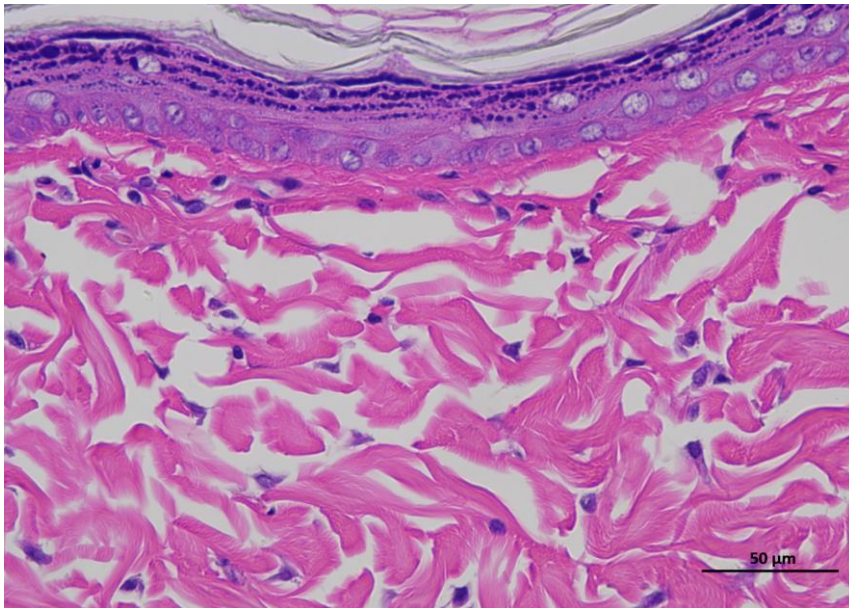
**Supplementary
Figure 3c |
Representative H&E
staining of skin
tissue of mRNA
LNPs-L animals /
Day 14.**



5 mRNA LNPs-L 14day 400-1



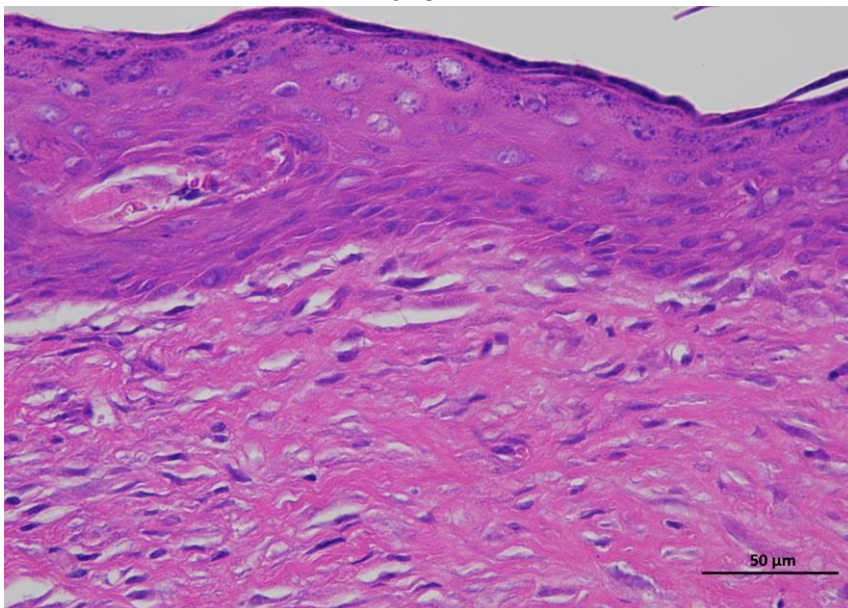
5 mRNA LNPs-L 14day 400-2



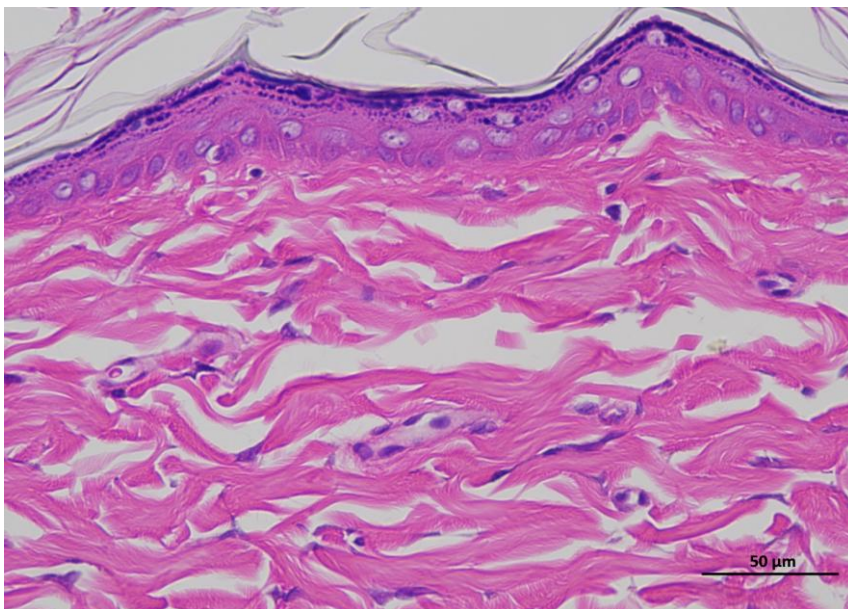
5 mRNA LNPs-L 14day 400-3

Animal 6

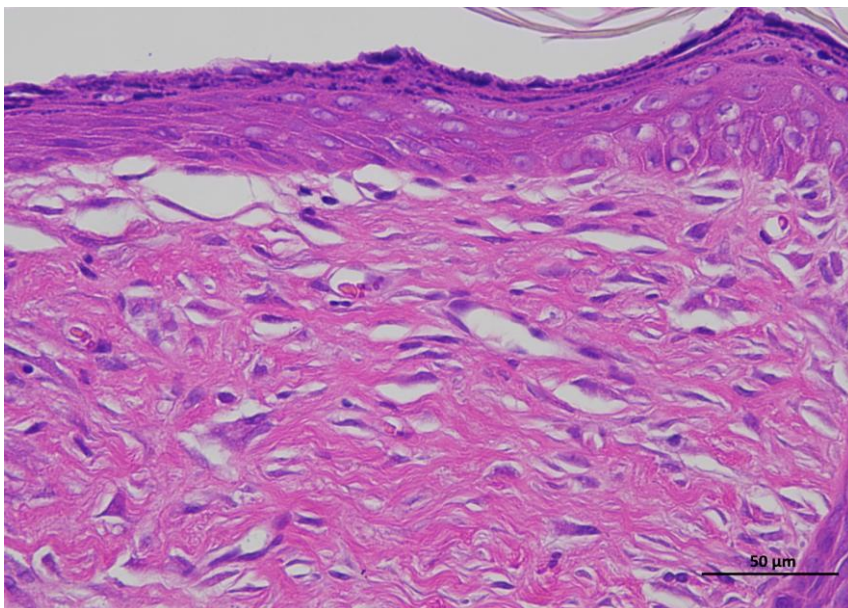
**Supplementary
Figure 3c |
Representative H&E
staining of skin
tissue of mRNA
LNPs-L animals /
Day 14.**



6 mRNA LNPs-L 14day 400-1



6 mRNA LNPs-L 14day 400-2

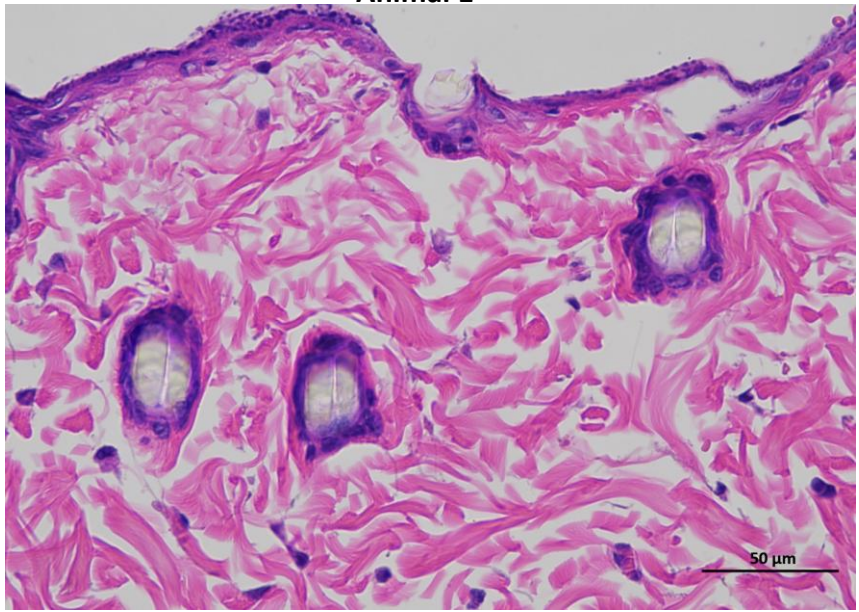


6 mRNA LNPs-L 14day 400-3

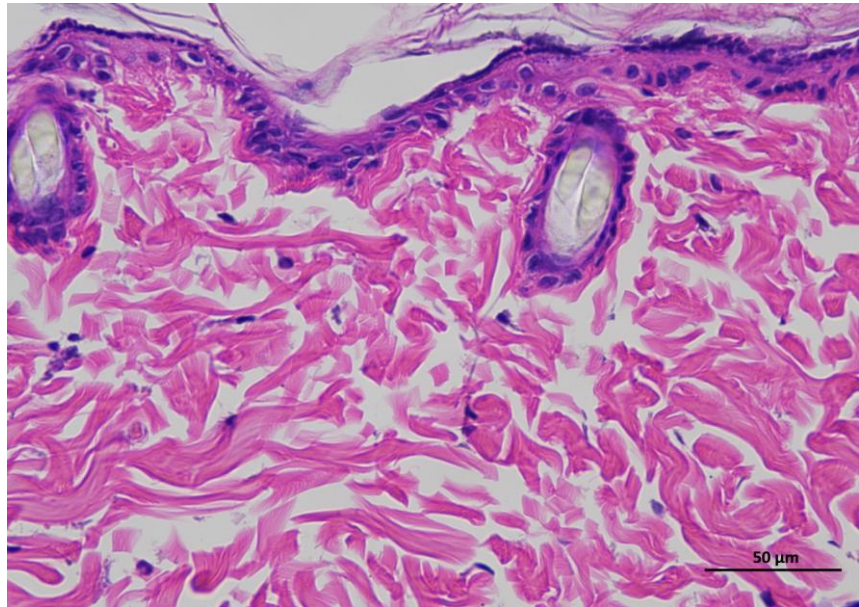
Animal 1

Supplementary Figure 2d | Representative H&E staining of skin tissue of mRNA LNPs-H animals / Day 0.

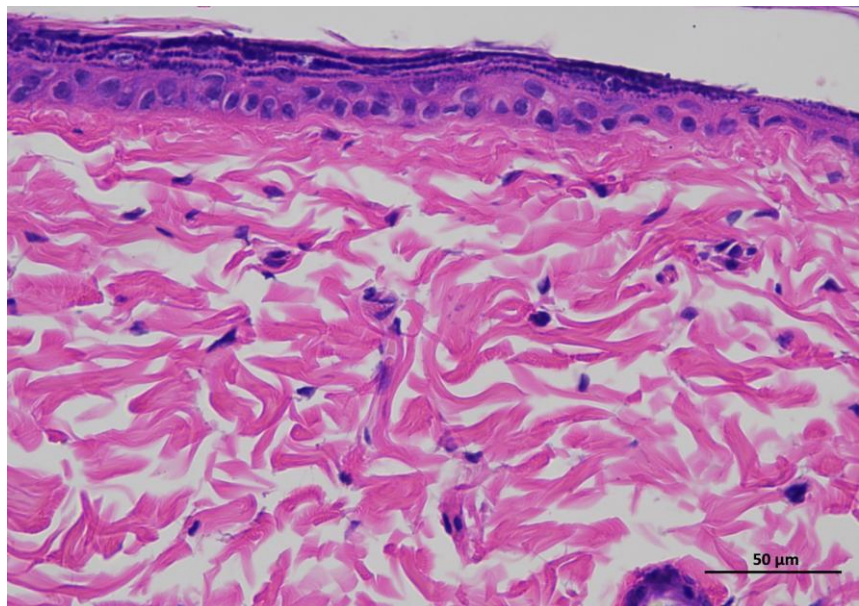
Representative hematoxylin and eosin (H&E)-stained section of skin tissue collected from experimental rat. The image shows the typical architecture of the skin, including the epidermal layer with stratified keratinized epithelium and the underlying dermis composed of dense collagen fibers and connective tissue structures. (n = 6 per group).



1 mRNA LNPs-H 0day 400-1



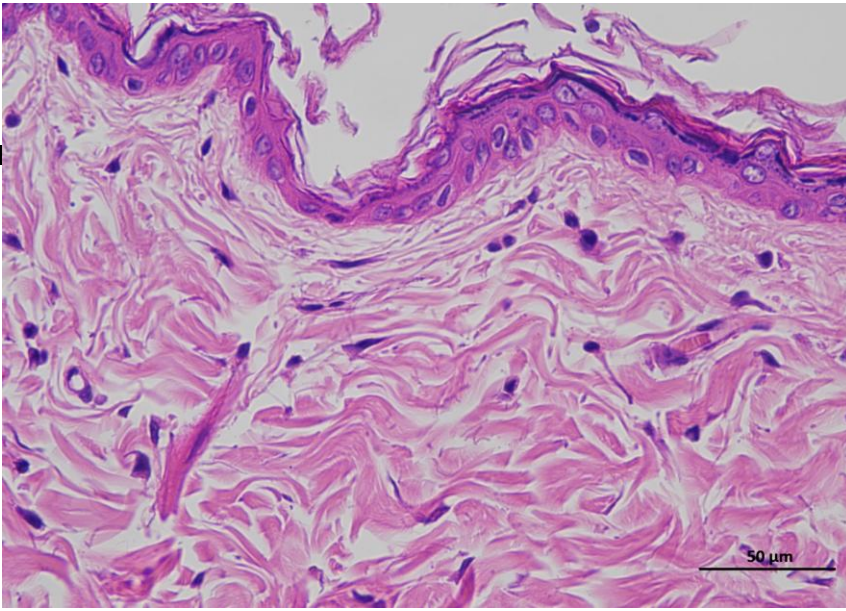
1 mRNA LNPs-H 0day 400-2



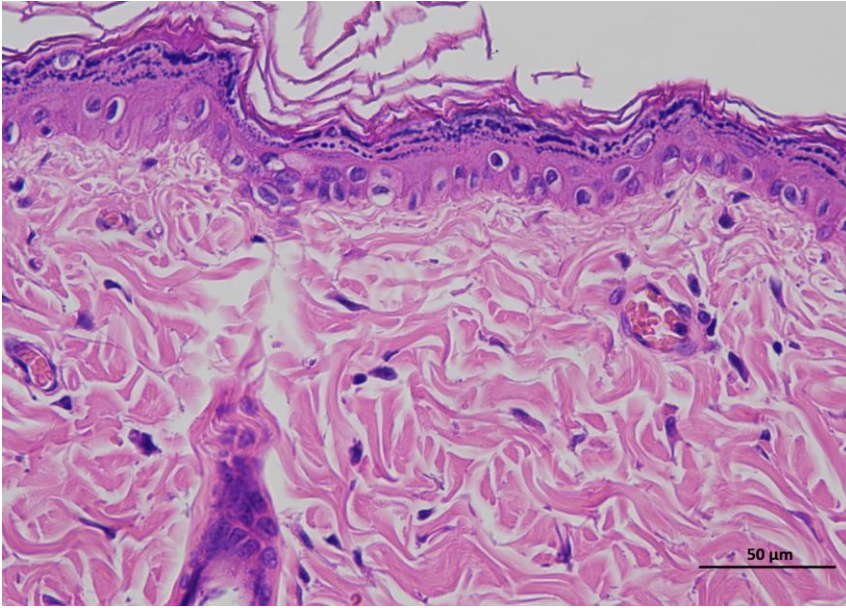
1 mRNA LNPs-H 0day 400-3

Animal 2

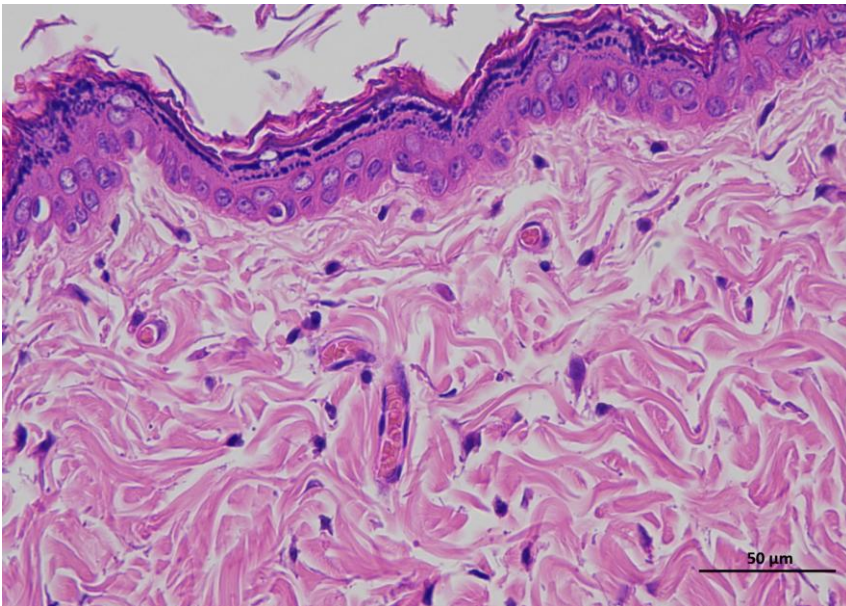
**Supplementary
Figure 2d |
Representative H&I
staining of skin
tissue of mRNA
LNPs-H animals /
Day 0.**



2 mRNA LNPs-H 0day 400-1



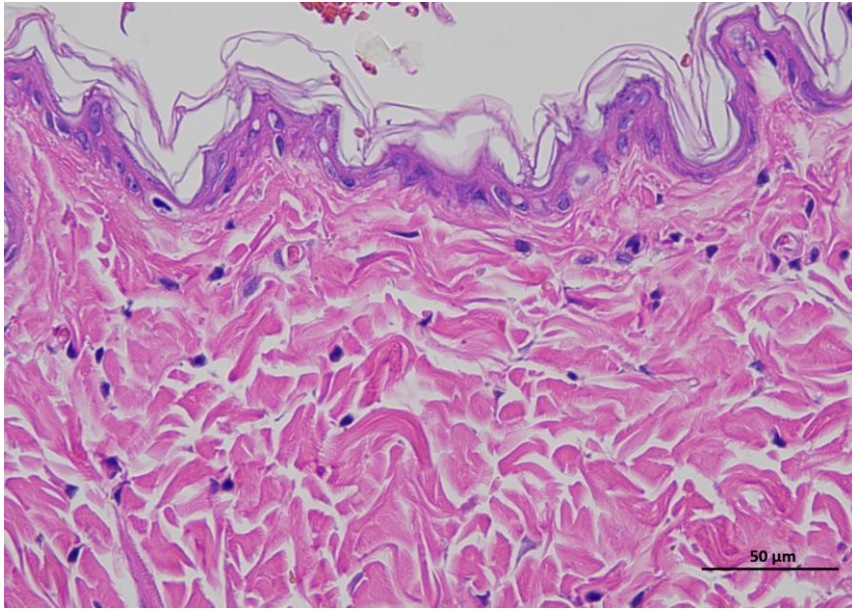
2 mRNA LNPs-H 0day 400-2



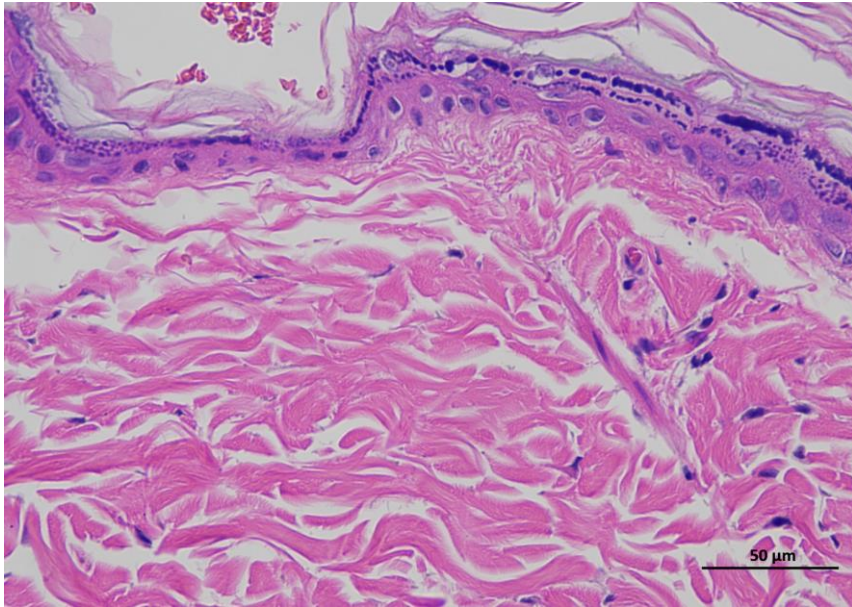
2 mRNA LNPs-H 0day 400-3

Animal 3

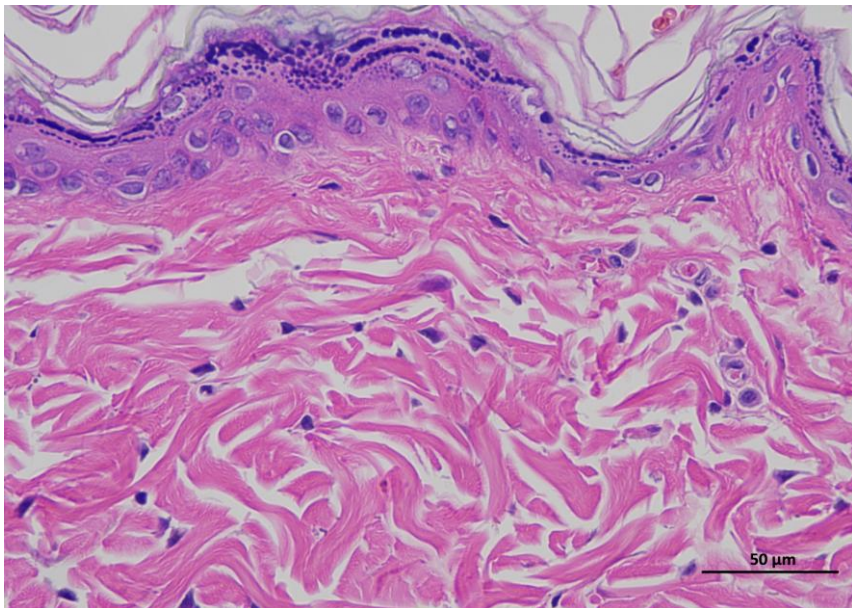
**Supplementary
Figure 2d |
Representative H&E
staining of skin
tissue of mRNA
LNPs-H animals /
Day 0.**



3 mRNA LNPs-H Oday 400-1



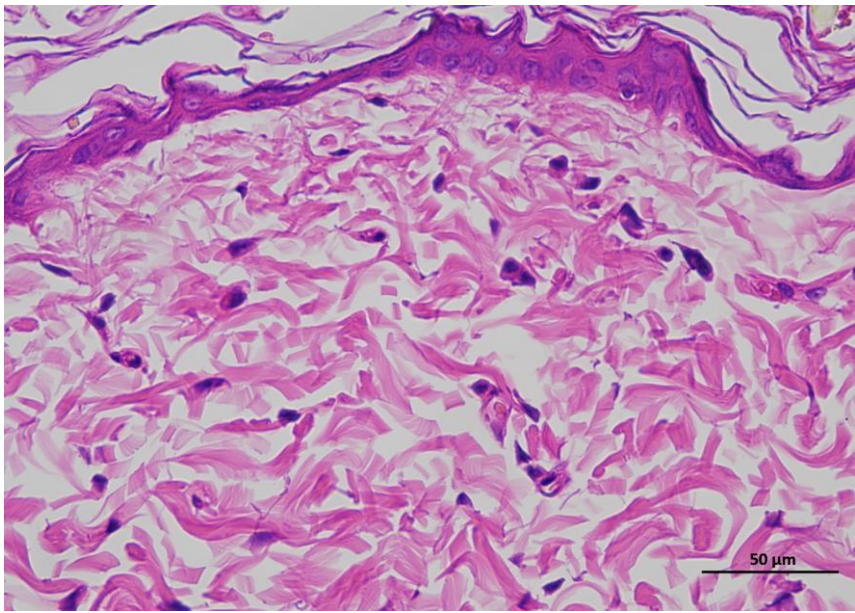
3 mRNA LNPs-H Oday 400-2



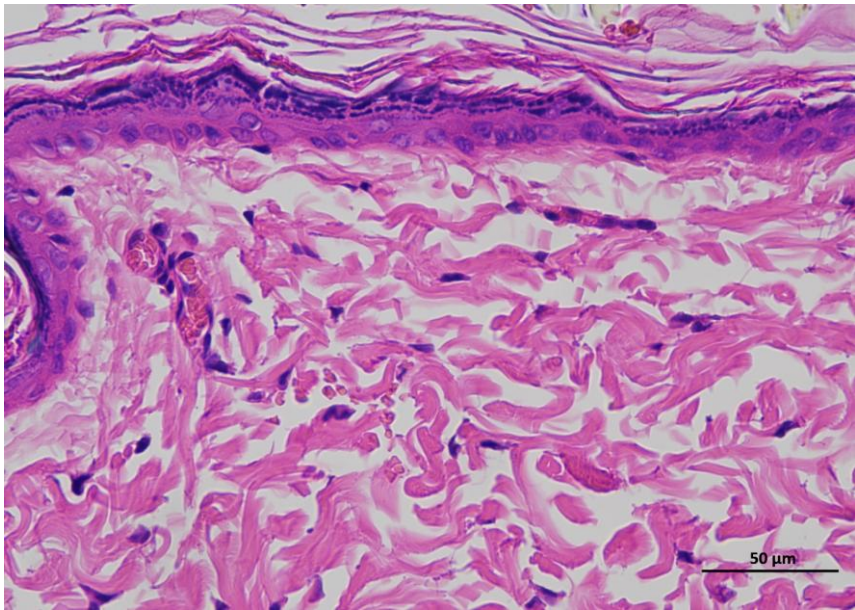
3 mRNA LNPs-H Oday 400-3

Animal 4

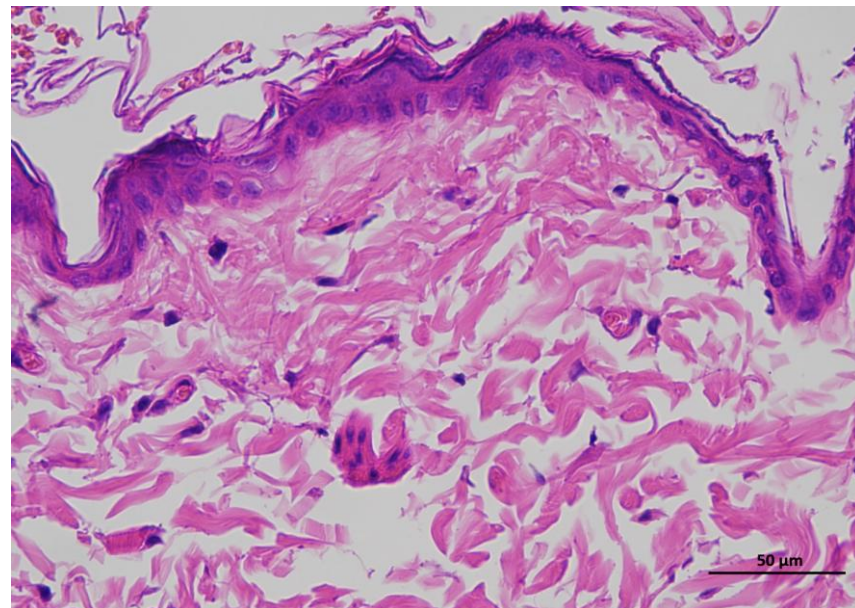
**Supplementary
Figure 2d |
Representative H&E
staining of skin
tissue of mRNA
LNPs-H animals /
Day 0.**



4 mRNA LNPs-H 0day 400-1



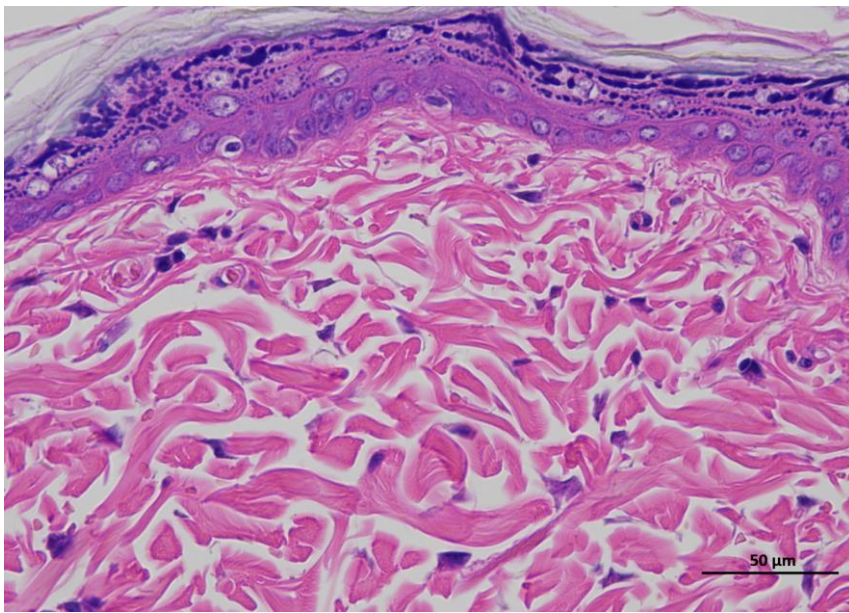
4 mRNA LNPs-H 0day 400-2



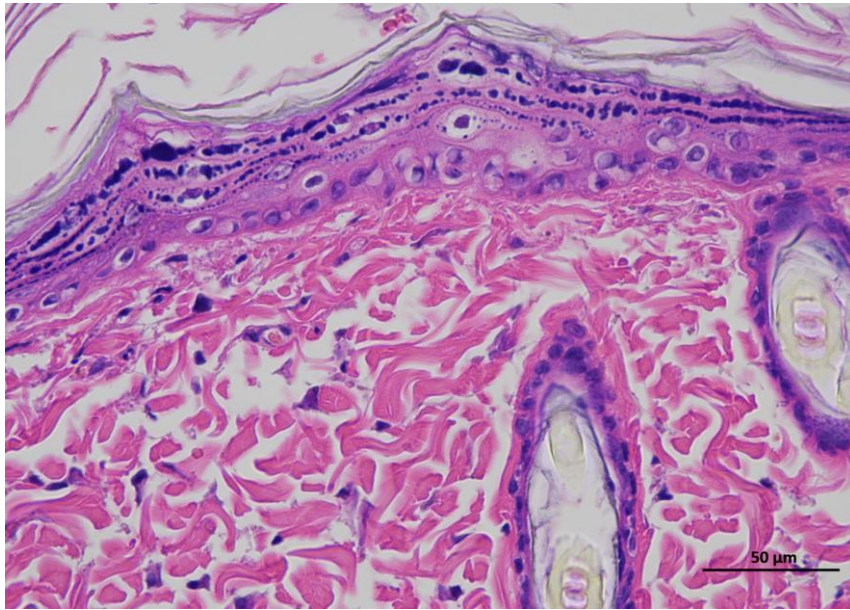
4 mRNA LNPs-H 0day 400-3

Animal 5

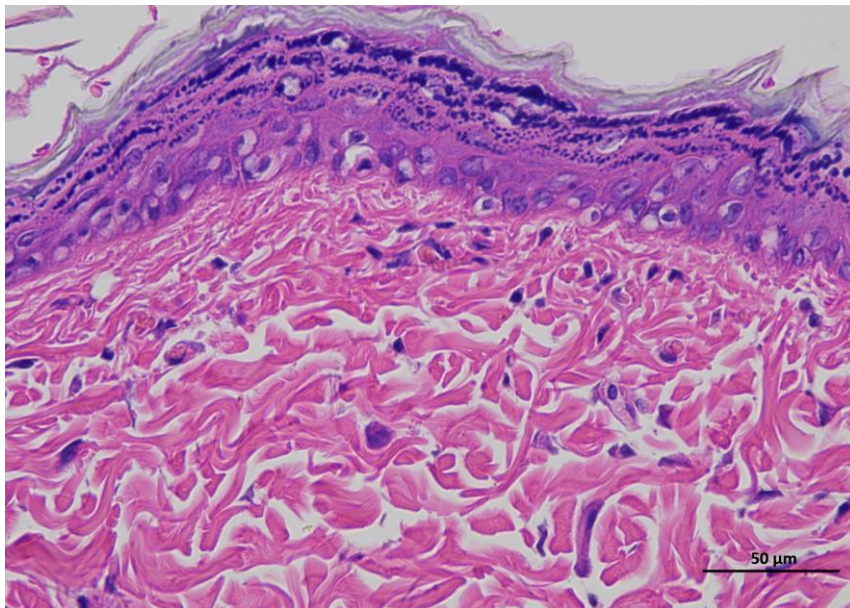
**Supplementary
Figure 2d |
Representative H&E
staining of skin
tissue of mRNA
LNPs-H animals /
Day 0.**



5 mRNA LNPs-H Oday 400-1



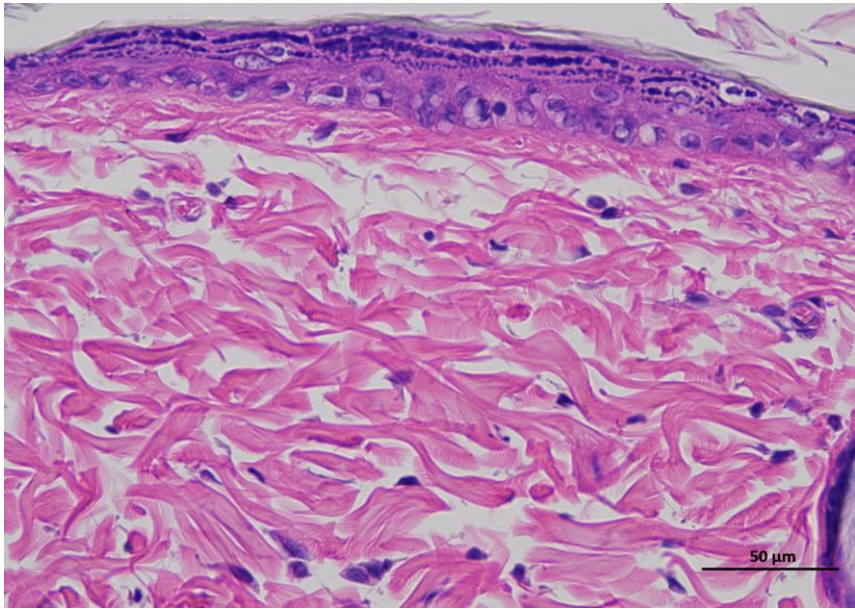
5 mRNA LNPs-H Oday 400-2



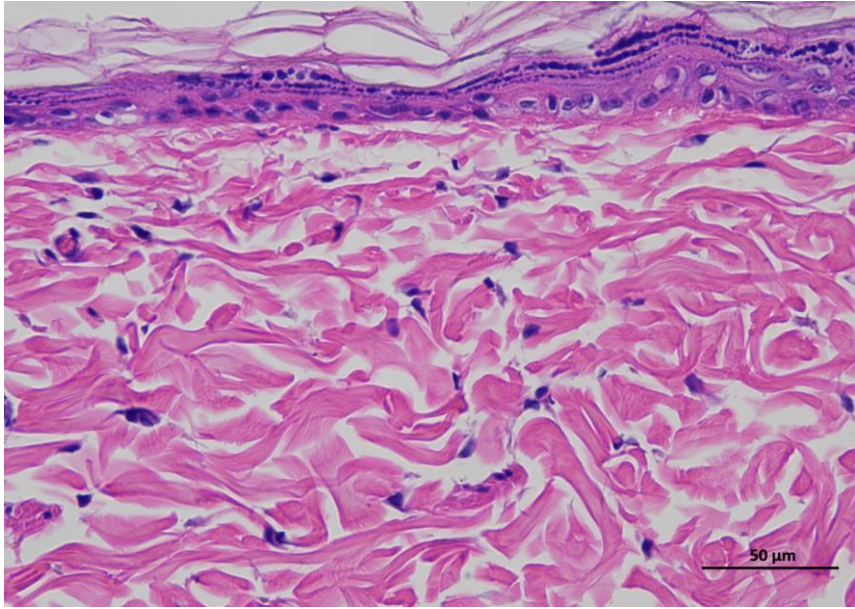
5 mRNA LNPs-H Oday 400-3

Animal 6

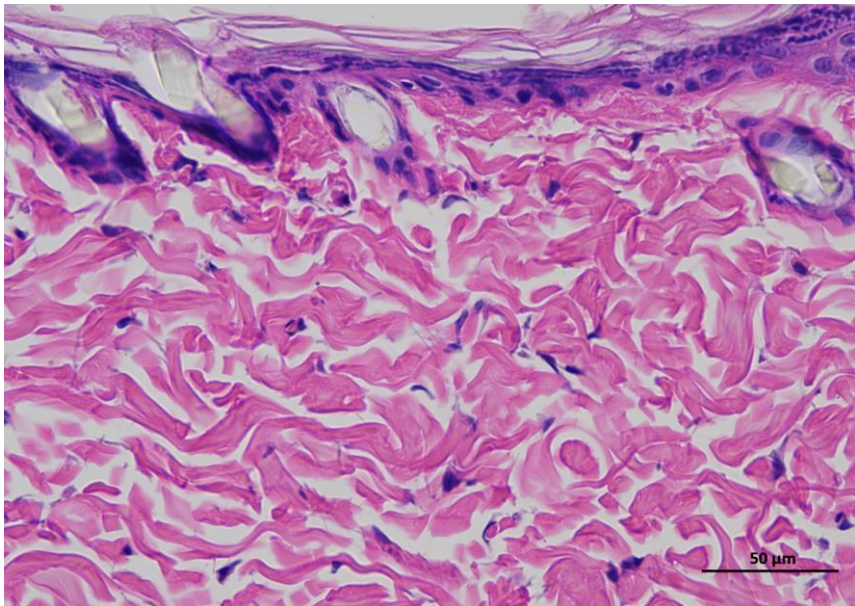
**Supplementary
Figure 2d |
Representative H&E
staining of skin
tissue of mRNA
LNPs-H animals /
Day 0.**



6 mRNA LNPs-H 0day 400-1



6 mRNA LNPs-H 0day 400-2

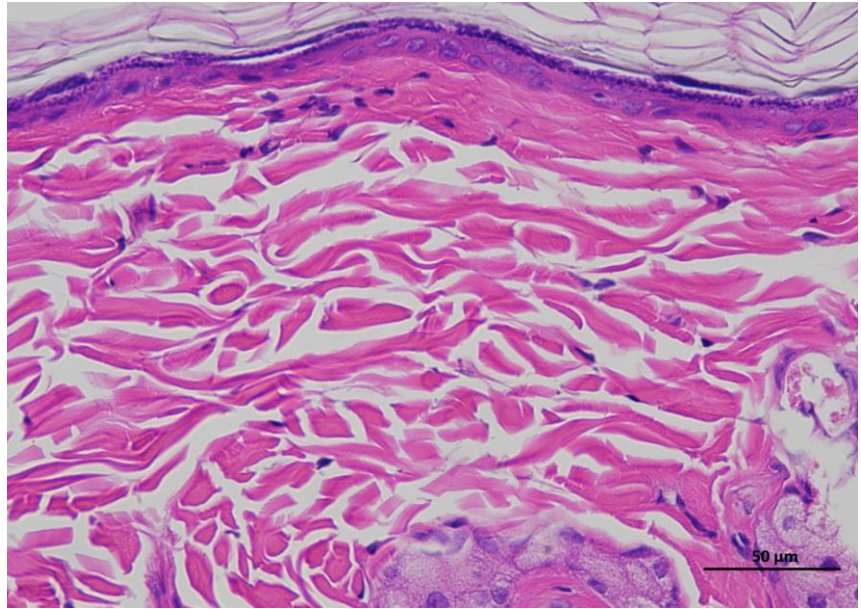


6 mRNA LNPs-H 0day 400-3

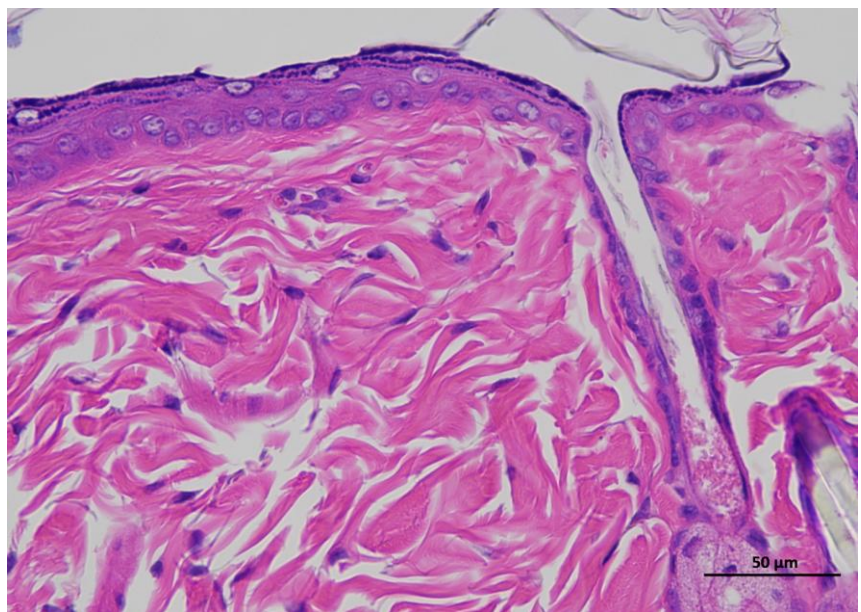
Animal 1

Supplementary Figure 3d | Representative H&E staining of skin tissue of mRNA LNPs-H animals / Day 14.

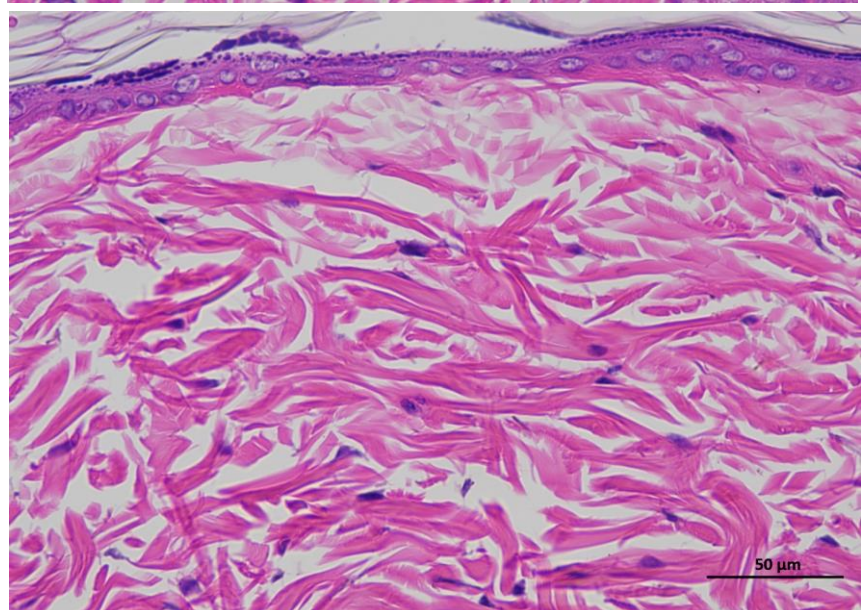
Representative hematoxylin and eosin (H&E)-stained section of skin tissue collected from experimental rat. The image shows the typical architecture of the skin, including the epidermal layer with stratified keratinized epithelium and the underlying dermis composed of dense collagen fibers and connective tissue structures. (n = 6 per group).



1 mRNA LNPs-H 14day 400-1

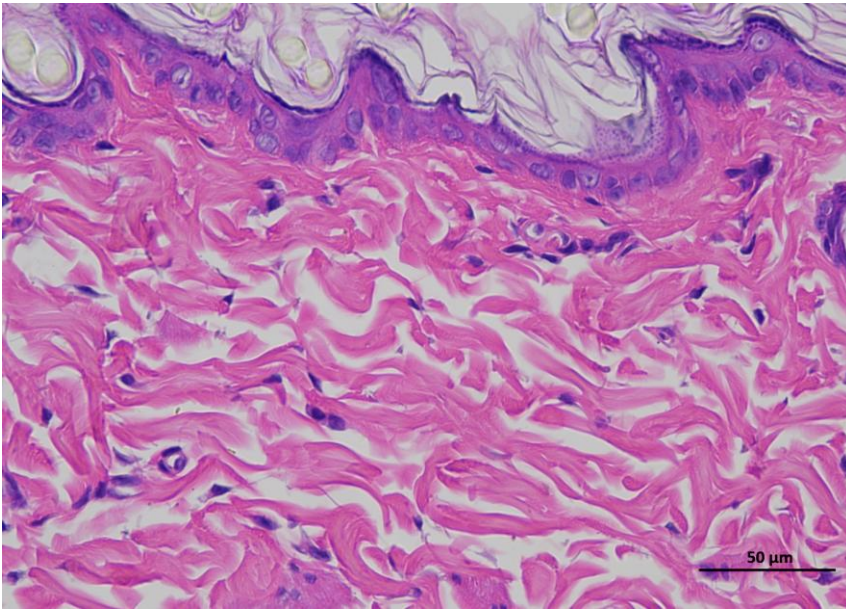


1 mRNA LNPs-H 14day 400-2

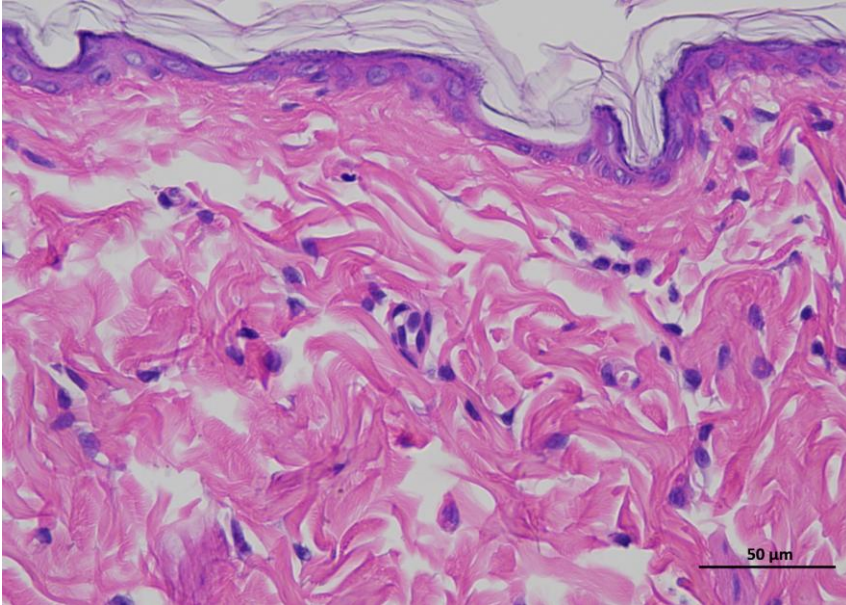


1 mRNA LNPs-H 14day 400-3

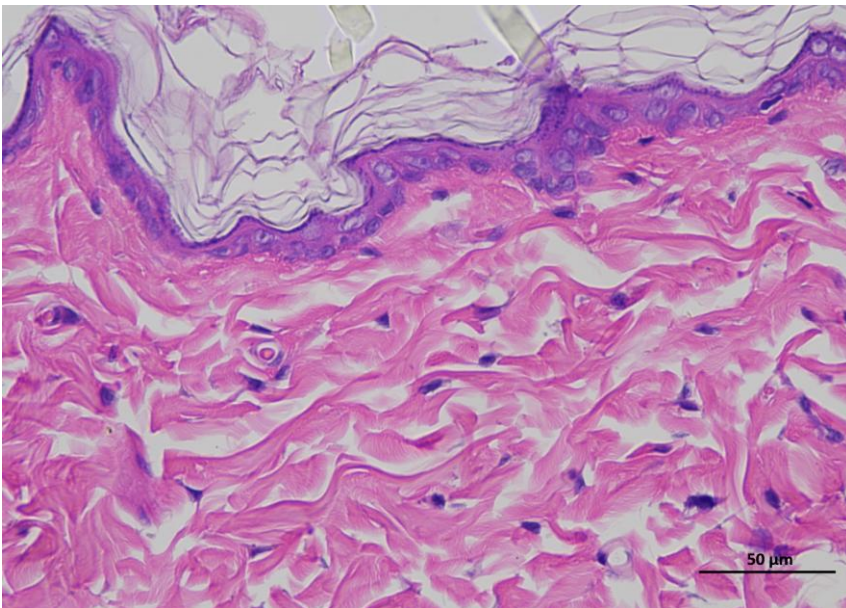
Animal 2



2 mRNA LNPs-H 14day 400-1



2 mRNA LNPs-H 14day 400-2

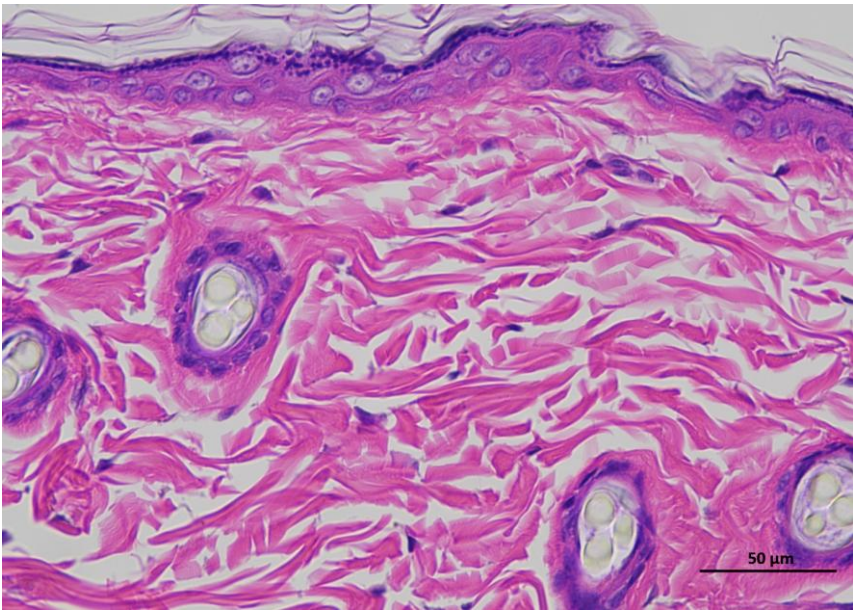


2 mRNA LNPs-H 14day 400-3

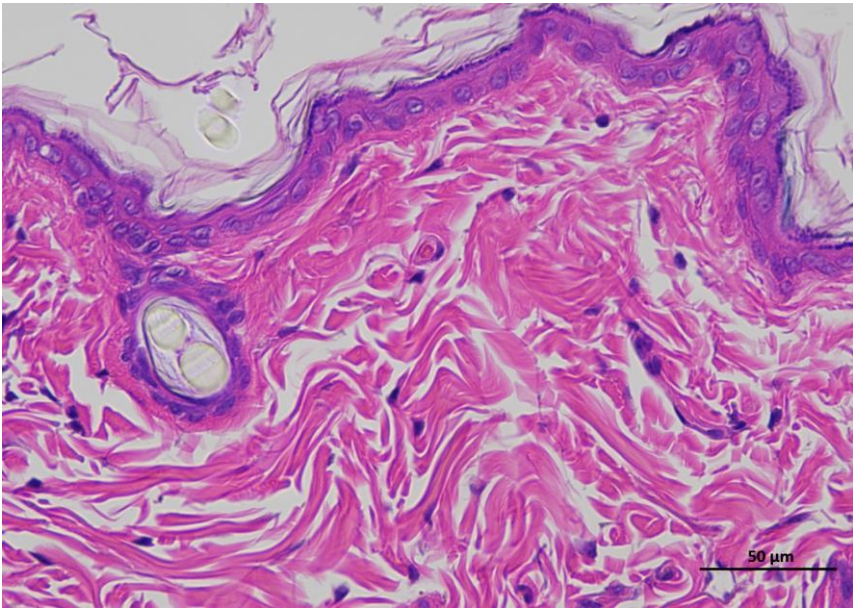
Supplementary Figure 3d | Representative H&E staining of skin tissue of mRNA LNPs-H animals / Day 14.

Animal 3

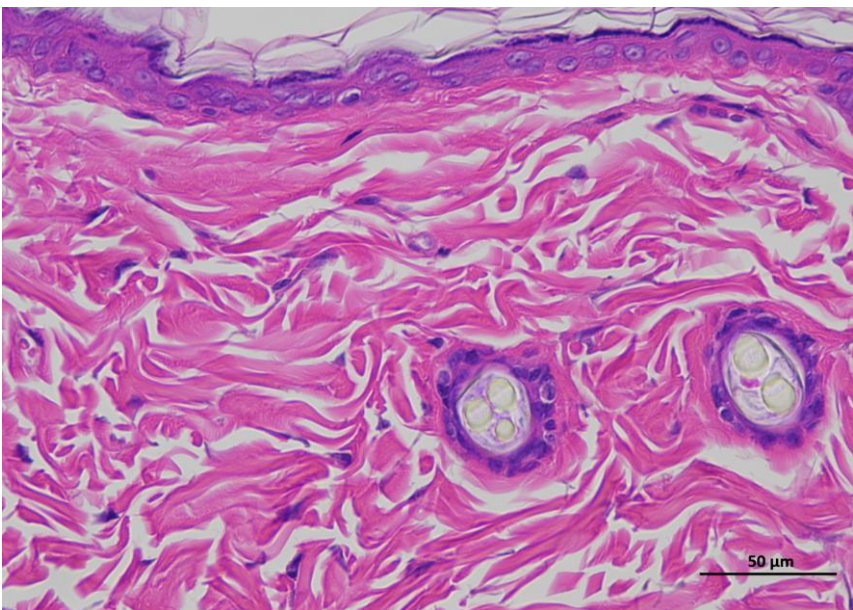
Supplementary Figure 3d | Representative H&E staining of skin tissue of mRNA LNPs-H animals / Day 14.



3 mRNA LNPs-H 14day 400-1



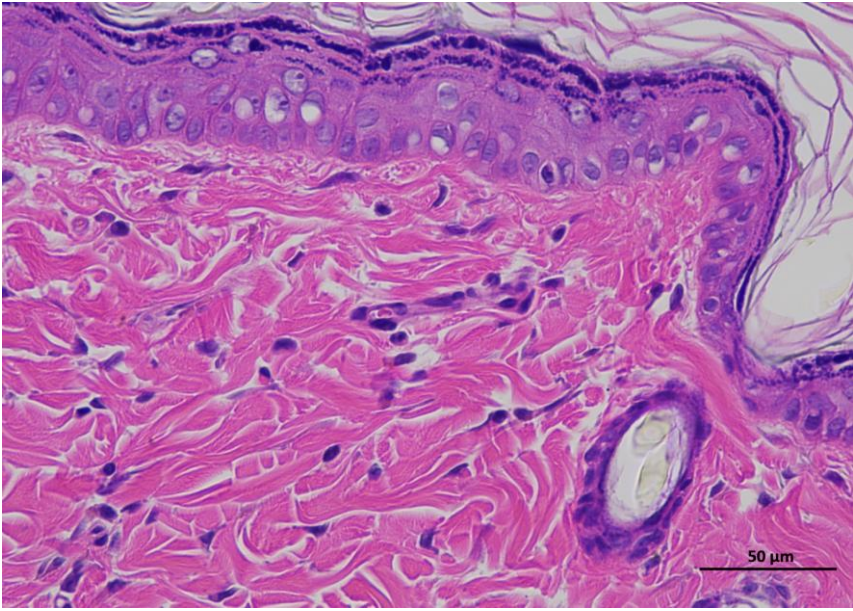
3 mRNA LNPs-H 14day 400-2



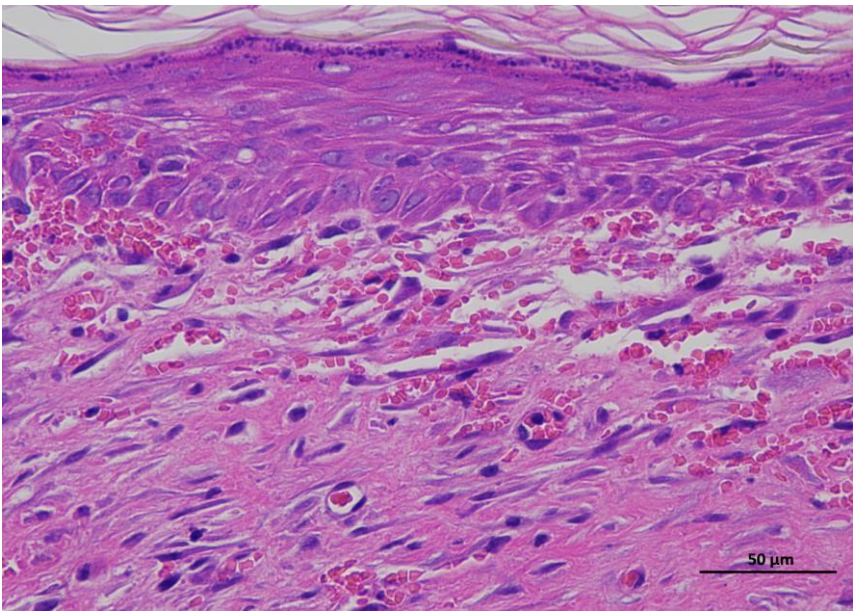
3 mRNA LNPs-H 14day 400-3

Animal 4

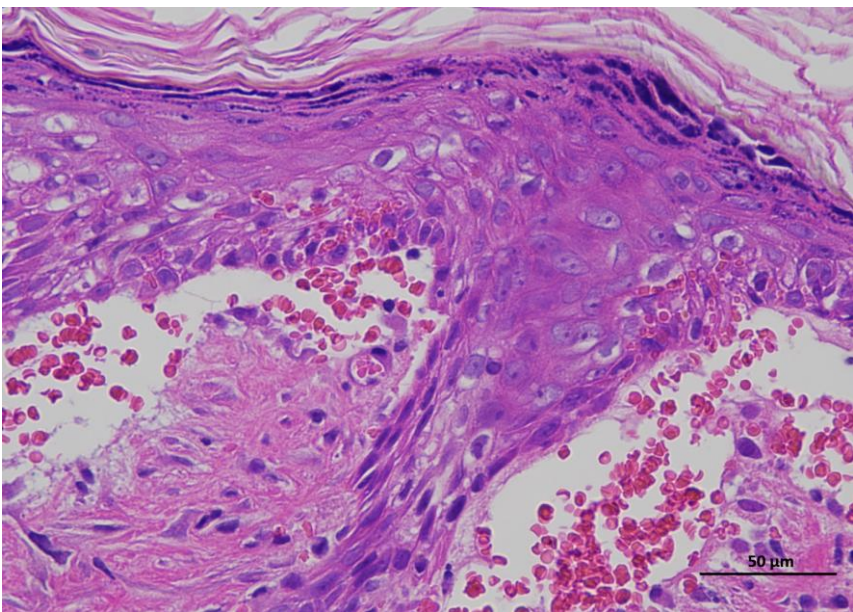
Supplementary Figure 3d | Representative H&E staining of skin tissue of mRNA LNPs-H animals / Day 14.



4 mRNA LNPs-H 14day 400-1



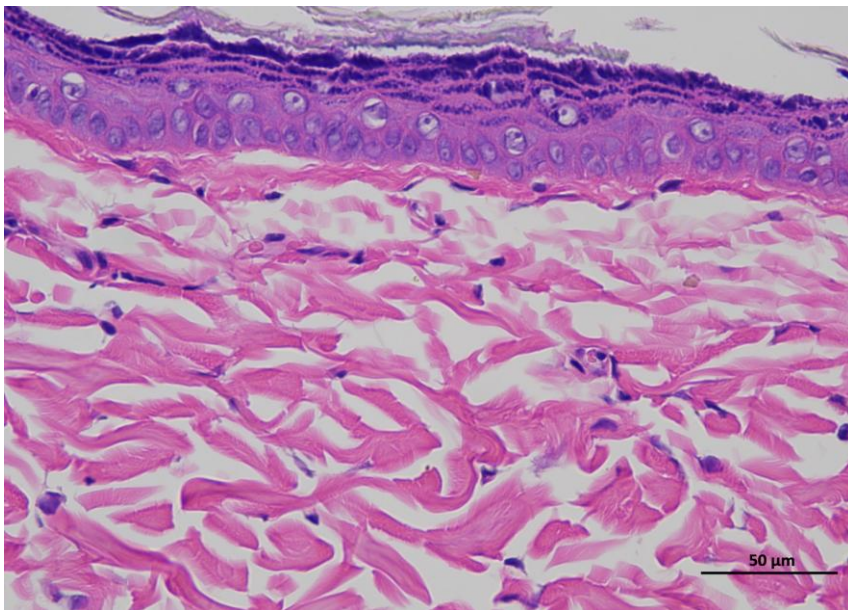
4 mRNA LNPs-H 14day 400-2



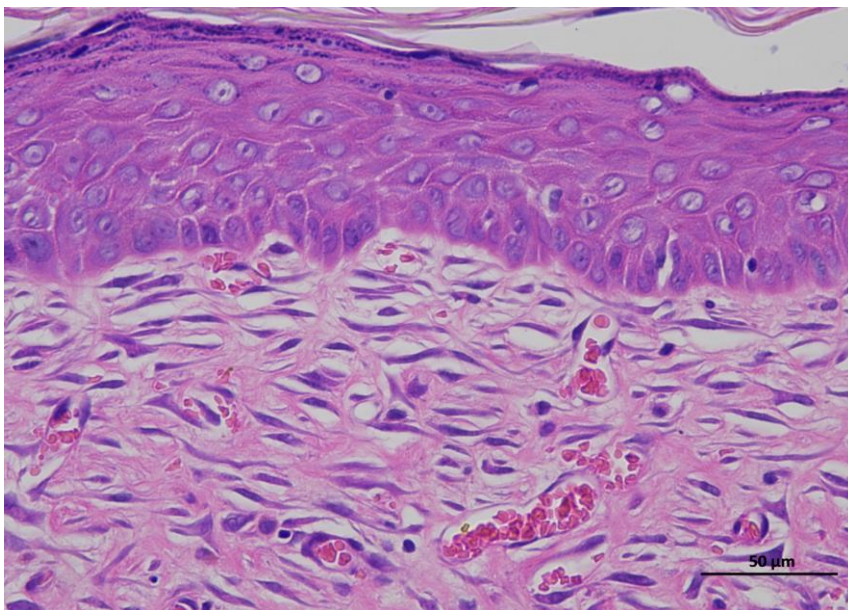
4 mRNA LNPs-H 14day 400-3

Animal 5

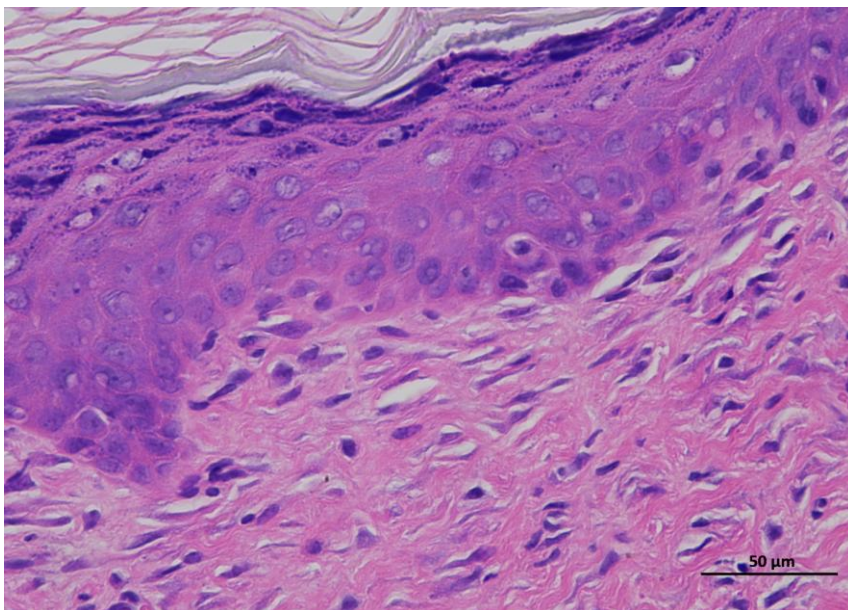
Supplementary Figure 3d | Representative H&E staining of skin tissue of mRNA LNPs-H animals / Day 14.



5 mRNA LNPs-H 14day 400-1



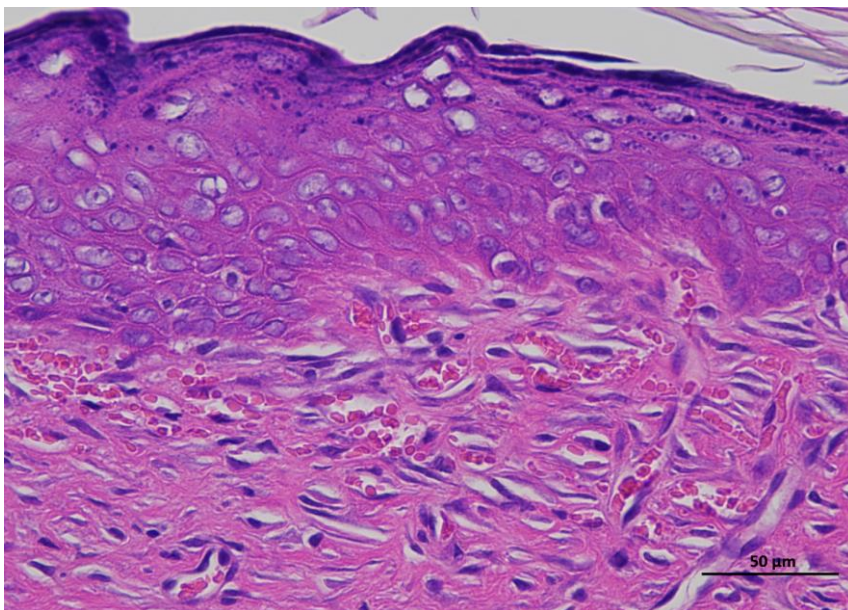
5 mRNA LNPs-H 14day 400-2



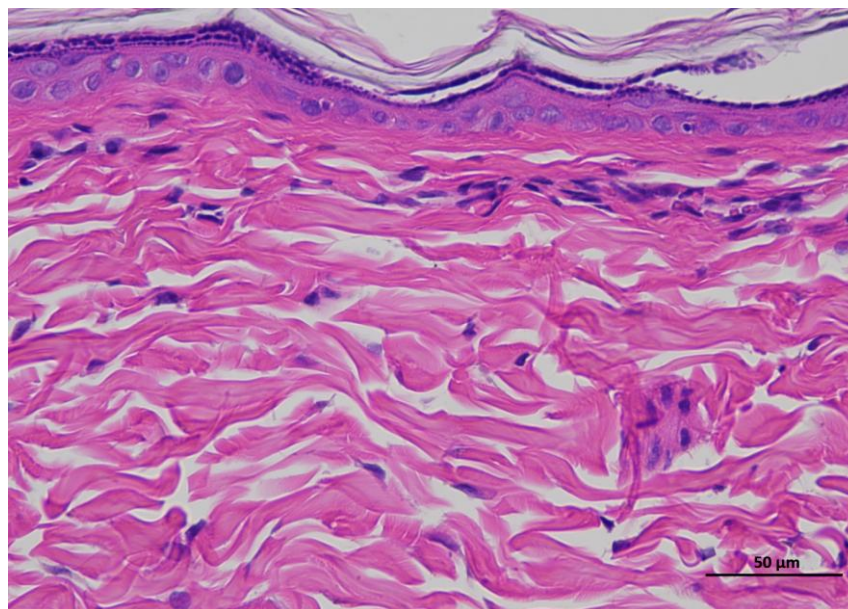
5 mRNA LNPs-H 14day 400-3

Animal 6

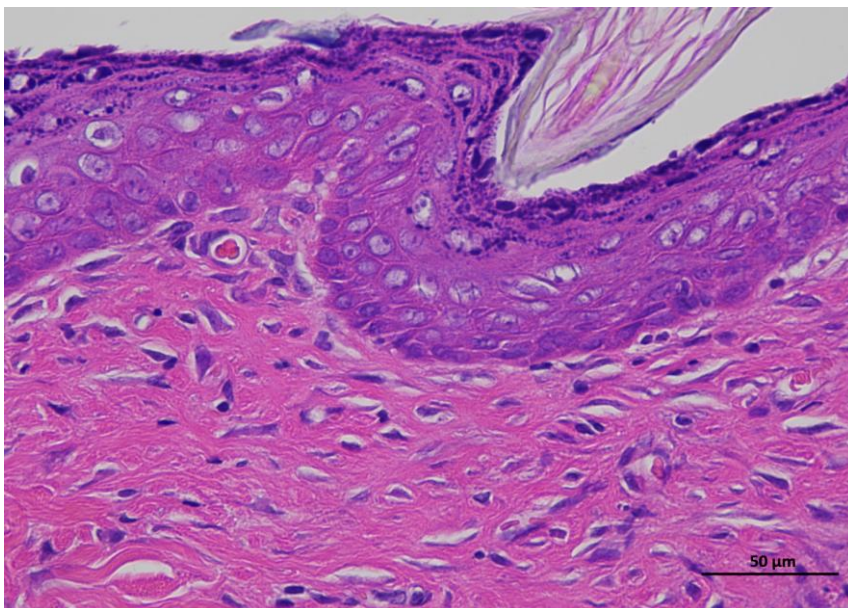
**Supplementary
Figure 3d |
Representative
H&E staining of
skin tissue of
mRNA LNPs-H
animals / Day 14.**



6 mRNA LNPs-H 14day 400-1



6 mRNA LNPs-H 14day 400-2

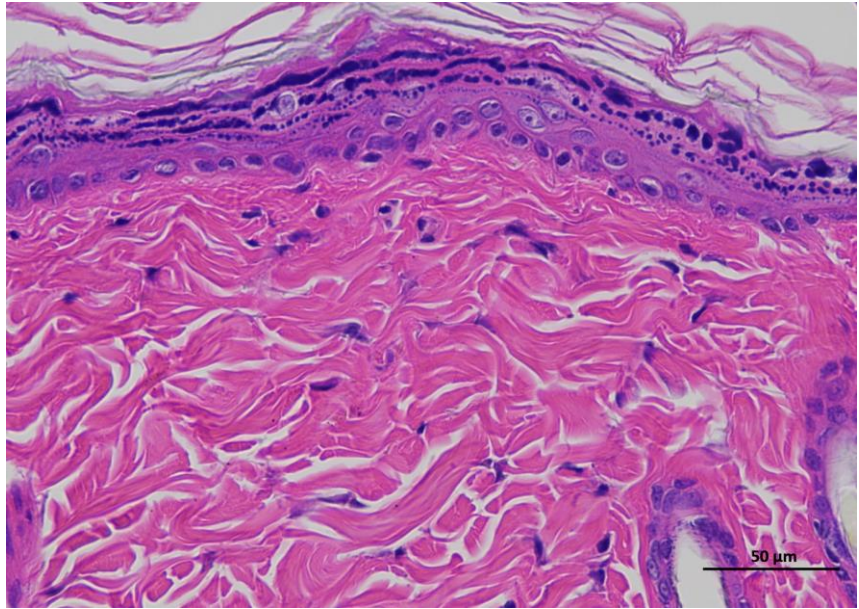


6 mRNA LNPs-H 14day 400-3

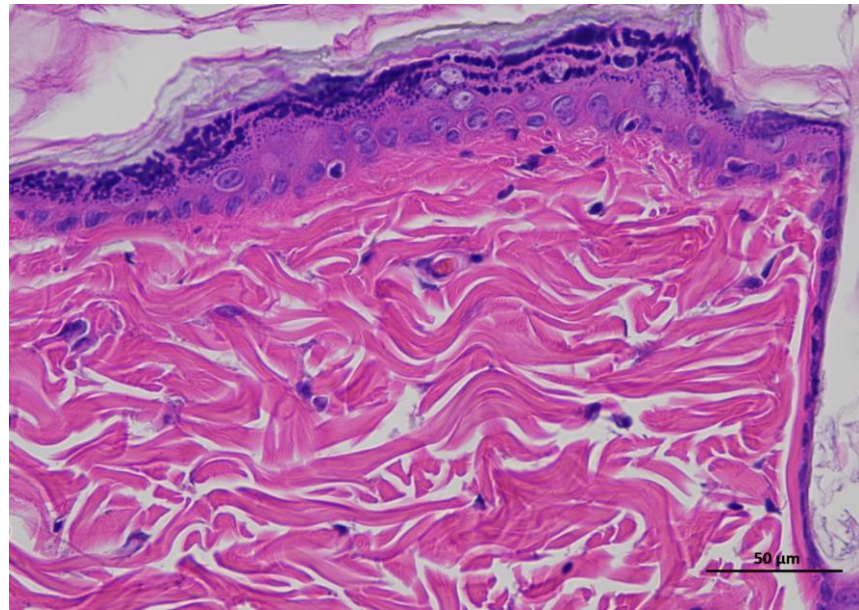
Animal 1

Supplementary Figure 2e | Representative H&E staining of skin tissue of rtBEV-L animals / Day 0.

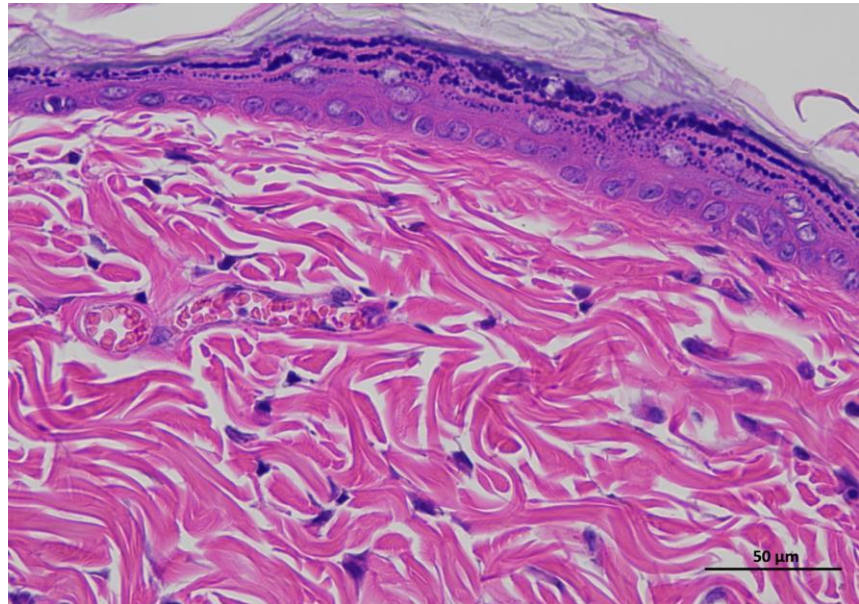
Representative hematoxylin and eosin (H&E)-stained section of skin tissue collected from experimental rat. The image shows the typical architecture of the skin, including the epidermal layer with stratified keratinized epithelium and the underlying dermis composed of dense collagen fibers and connective tissue structures. (n = 6 per group).



1 rtBEV-L 0day 400-1



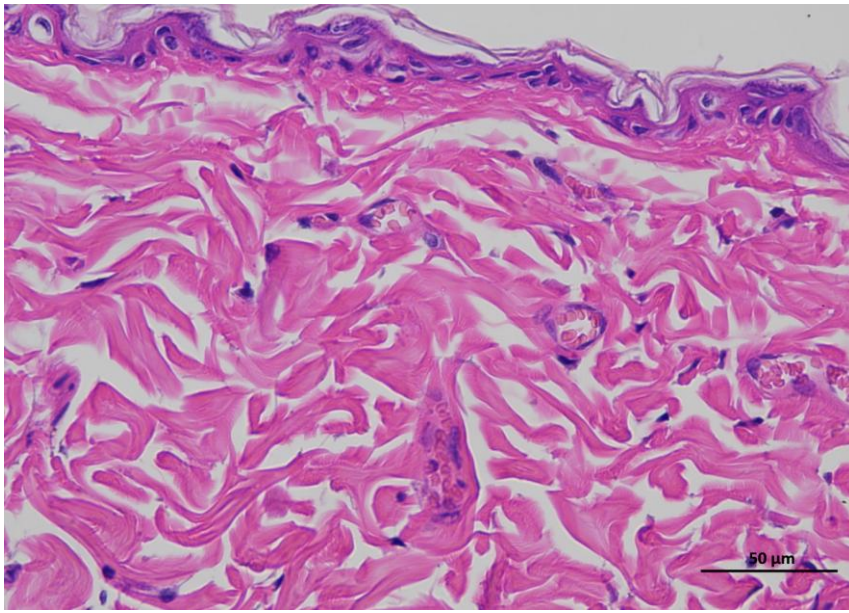
1 rtBEV-L 0day 400-2



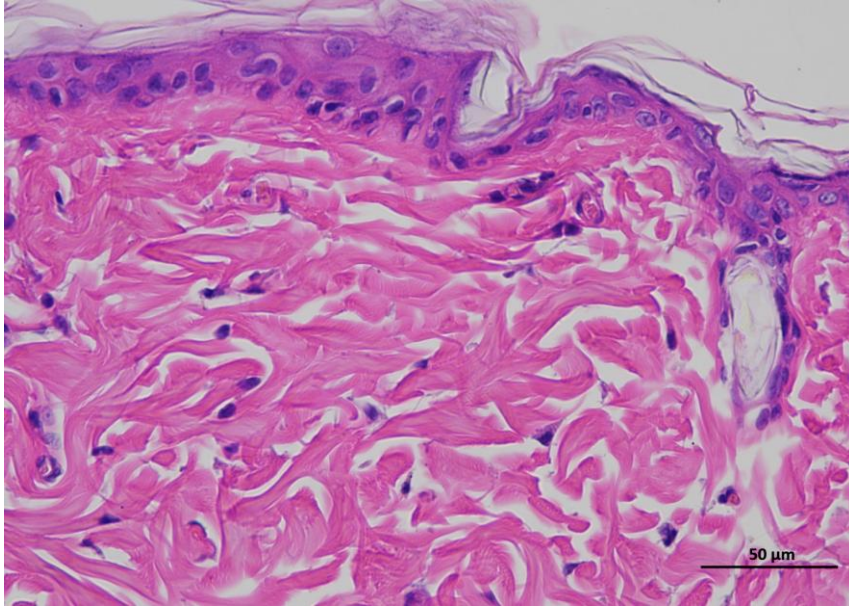
1 rtBEV-L 0day 400-3

Animal 2

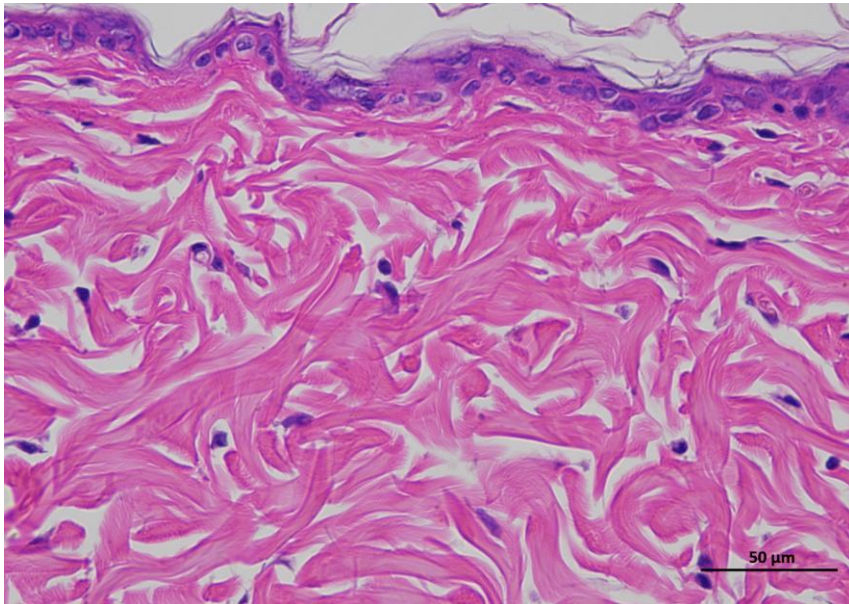
**Supplementary
Figure 2e |
Representative H&E
staining of skin
tissue of mRNA
rtBEV-L animals /
Day 0.**



2 rtBEV-L 0day 400-1



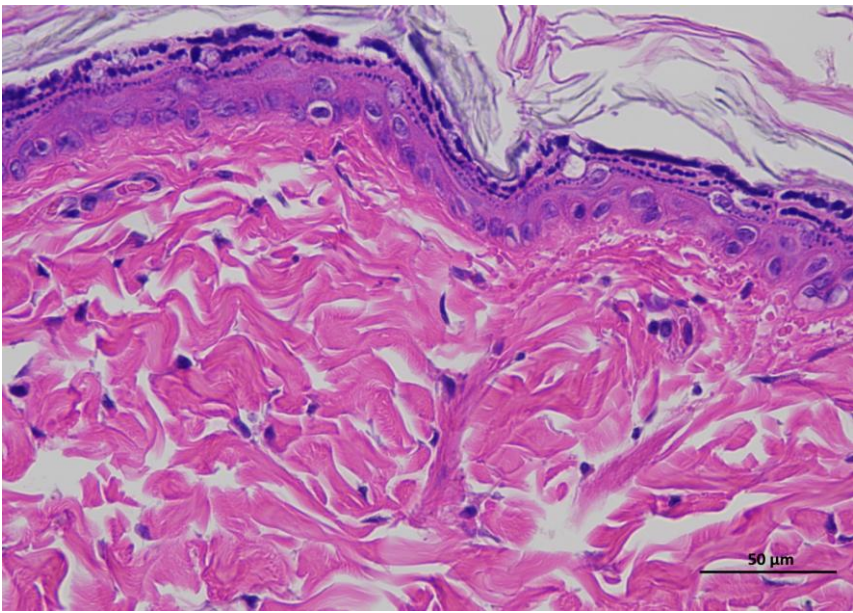
2 rtBEV-L 0day 400-2



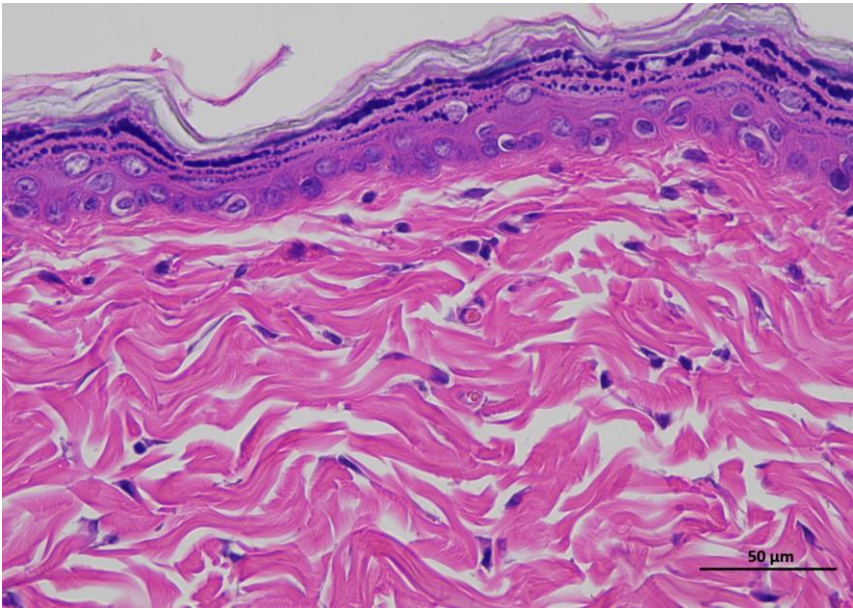
2 rtBEV-L 0day 400-3

Animal 3

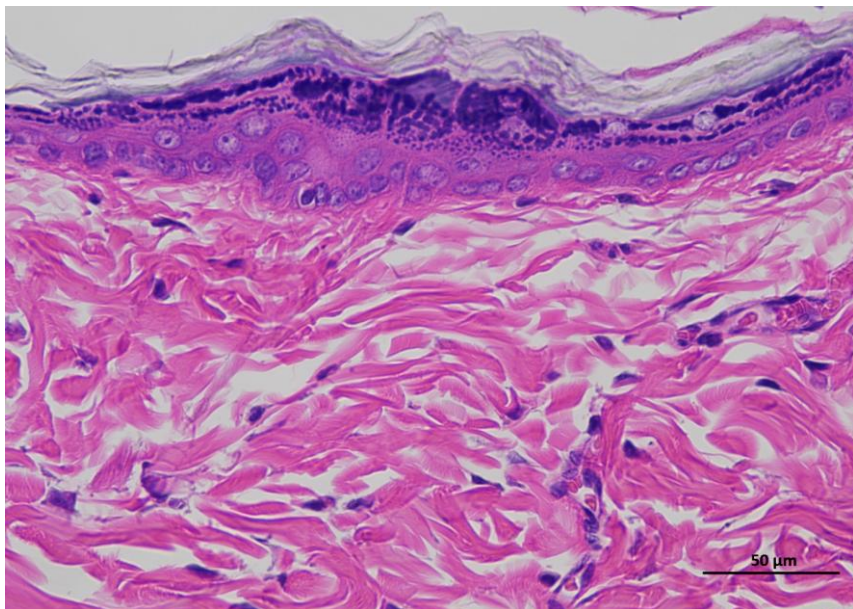
**Supplementary
Figure 2e |
Representative H&E
staining of skin
tissue of mRNA
rtBEV-L animals /
Day 0.**



3 rtBEV-L Oday 400-1



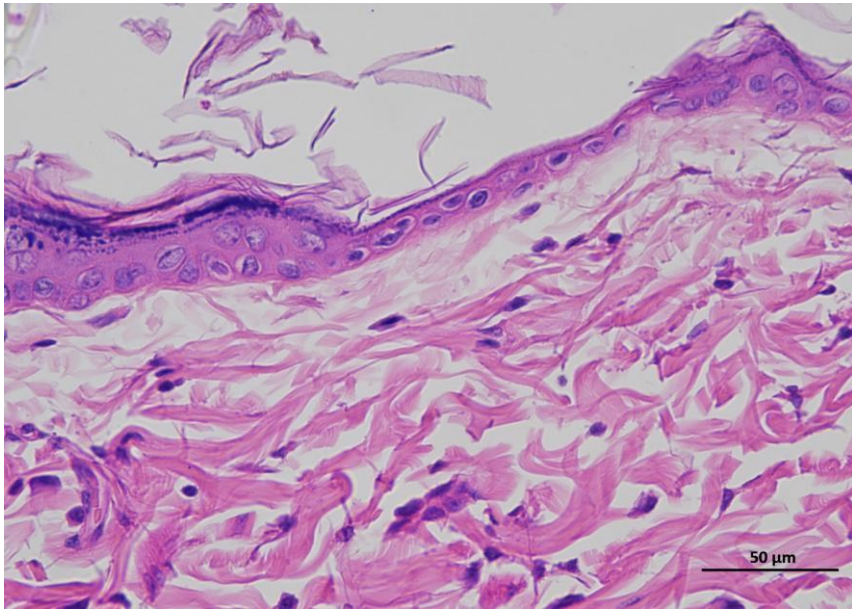
3 rtBEV-L Oday 400-2



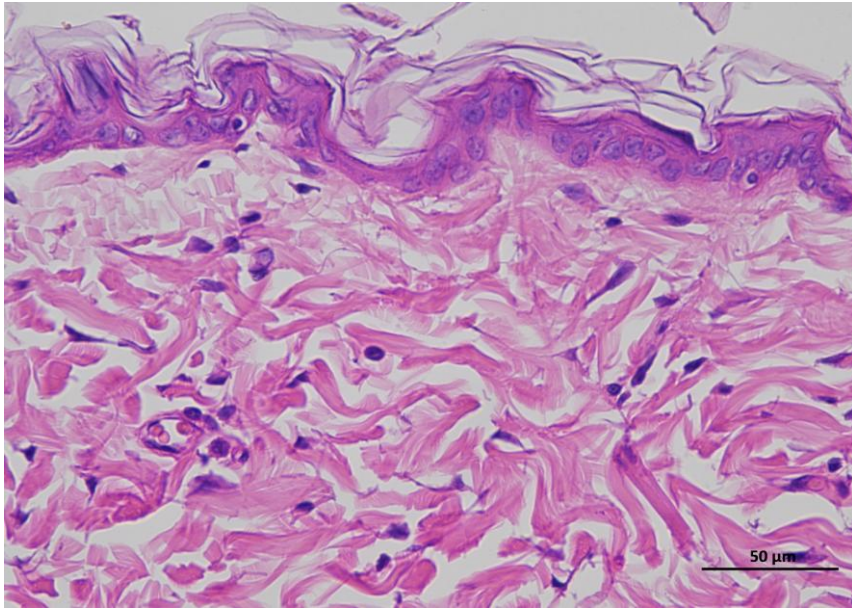
3 rtBEV-L Oday 400-3

Animal 4

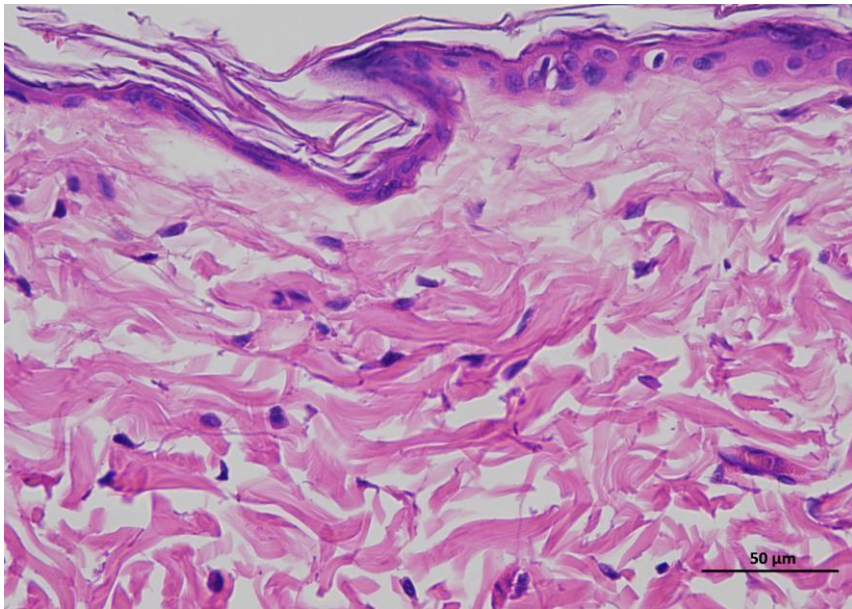
**Supplementary
Figure 2e |
Representative H&E
staining of skin
tissue of mRNA
rtBEV-L animals /
Day 0.**



4 rtBEV-L Oday 400-1



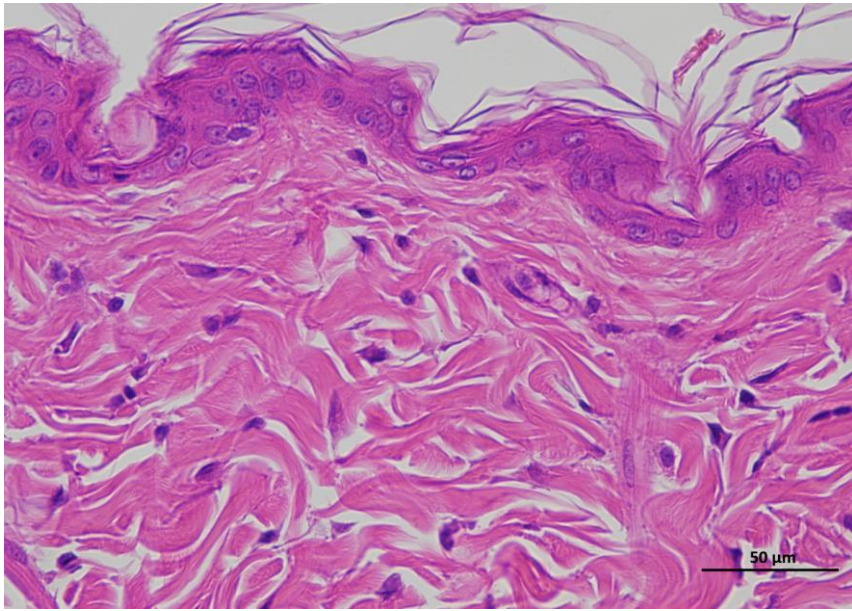
4 rtBEV-L Oday 400-2



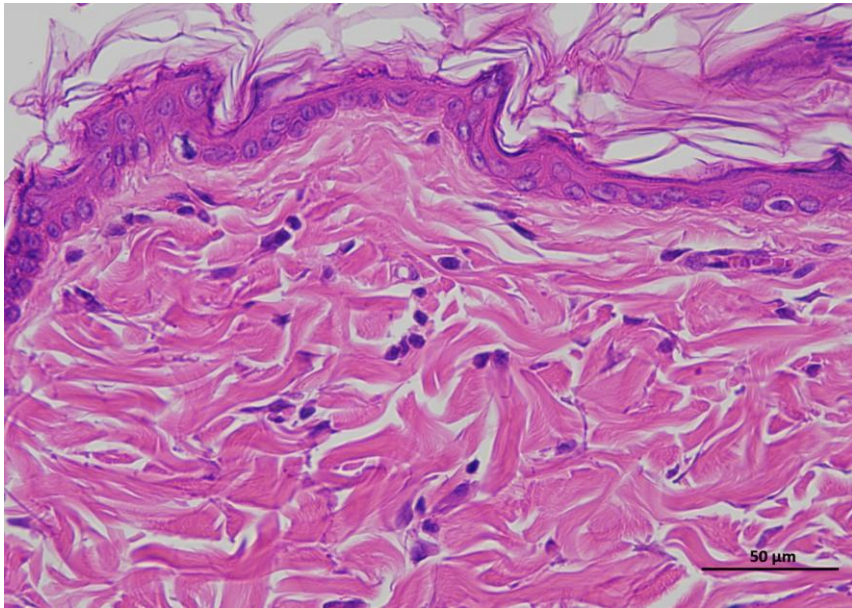
4 rtBEV-L Oday 400-3

Animal 5

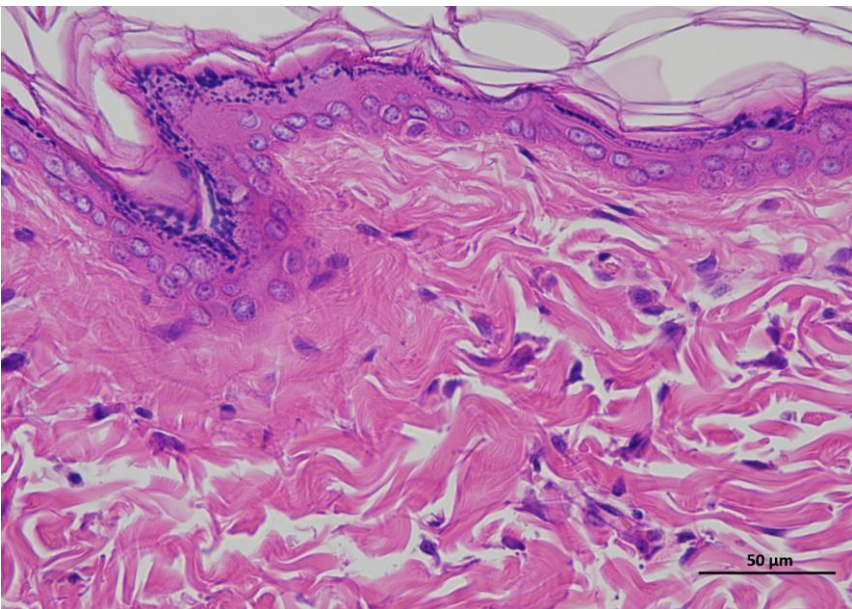
**Supplementary
Figure 2e |
Representative H&E
staining of skin
tissue of mRNA
rtBEV-L animals /
Day 0.**



5 rtBEV-L Oday 400-1



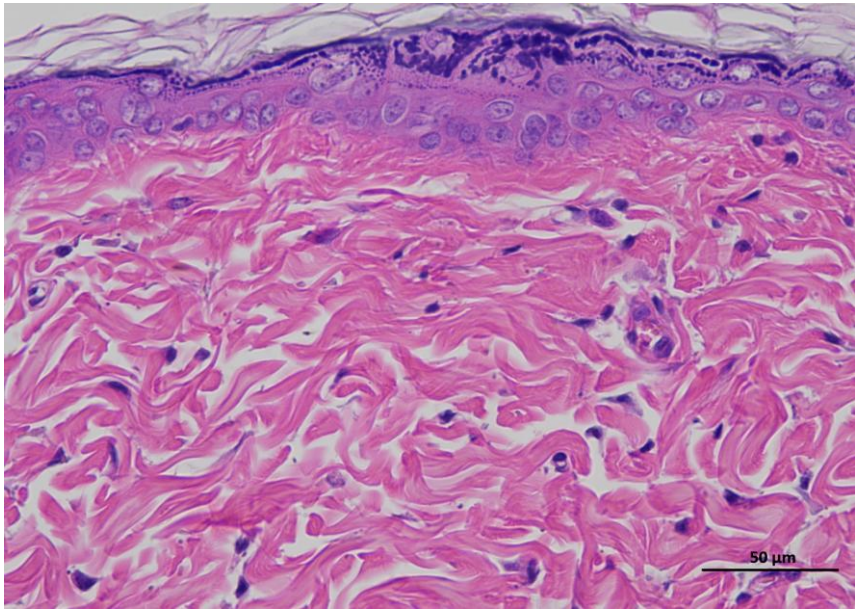
5 rtBEV-L Oday 400-2



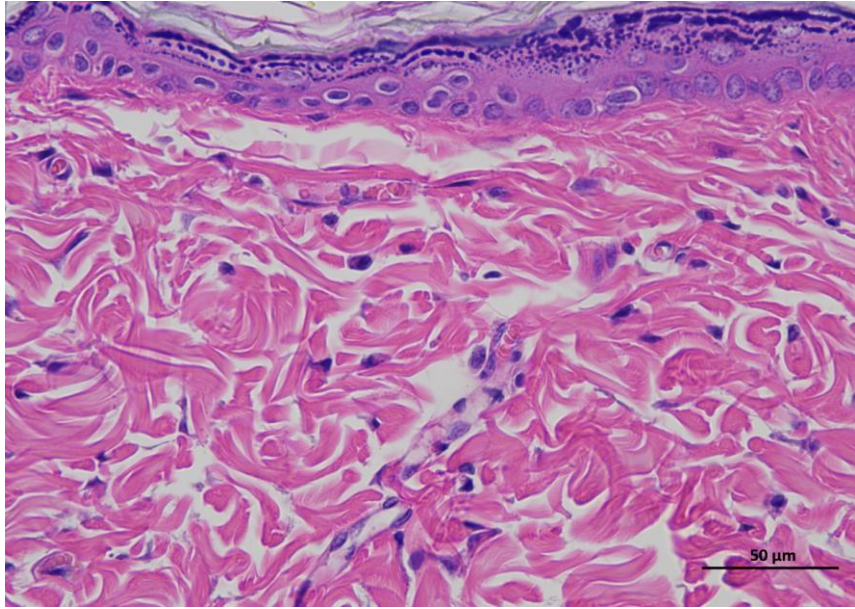
5 rtBEV-L Oday 400-3

Animal 6

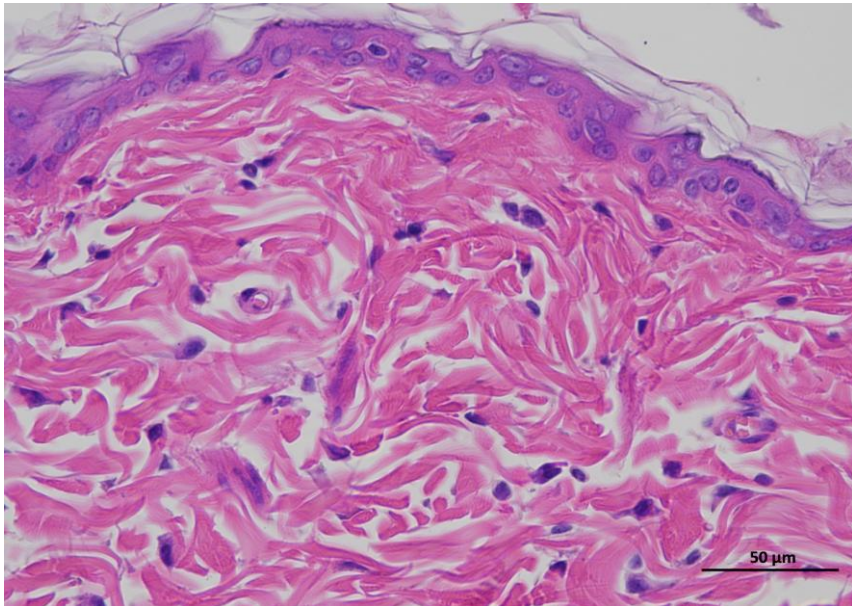
**Supplementary
Figure 2e |
Representative H&E
staining of skin
tissue of mRNA
rtBEV-L animals /
Day 0.**



6 rtBEV-L Oday 400-1



6 rtBEV-L Oday 400-2

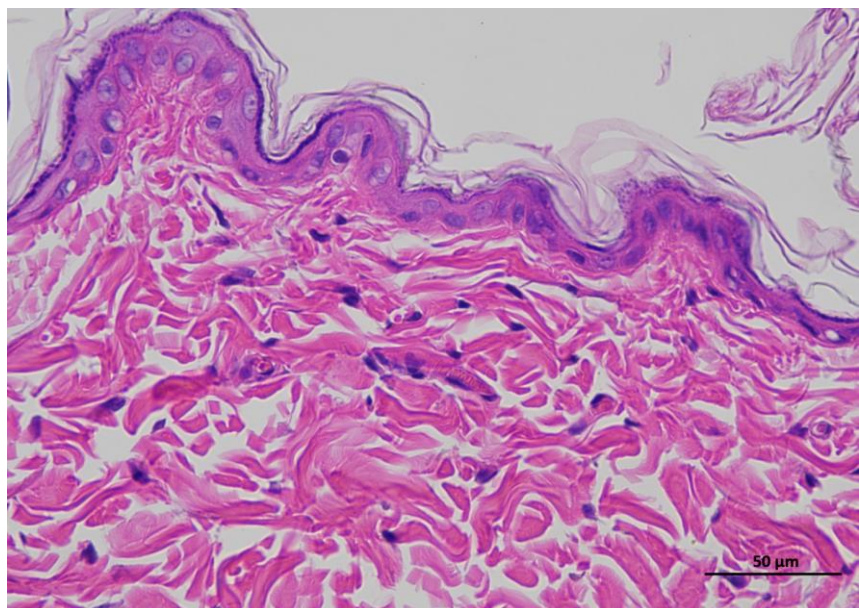
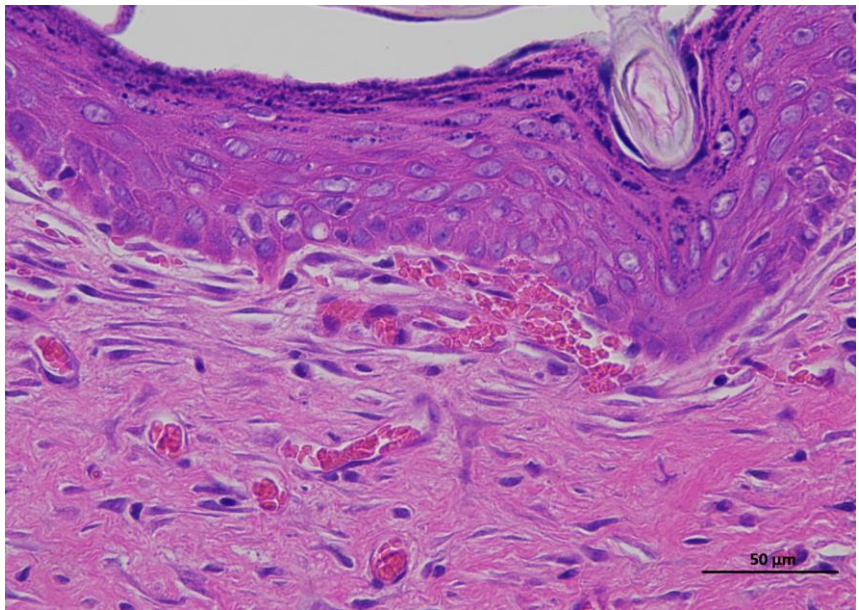
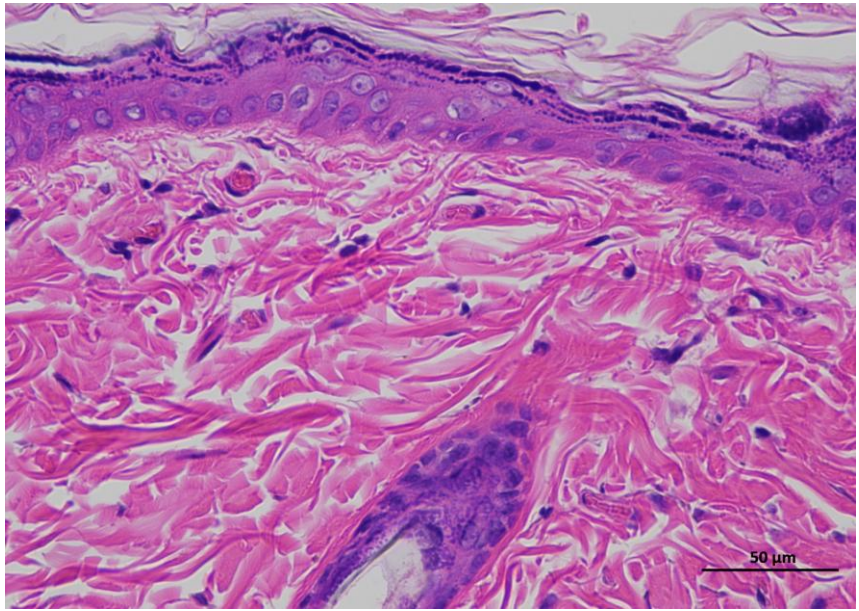


6 rtBEV-L Oday 400-3

Animal 1

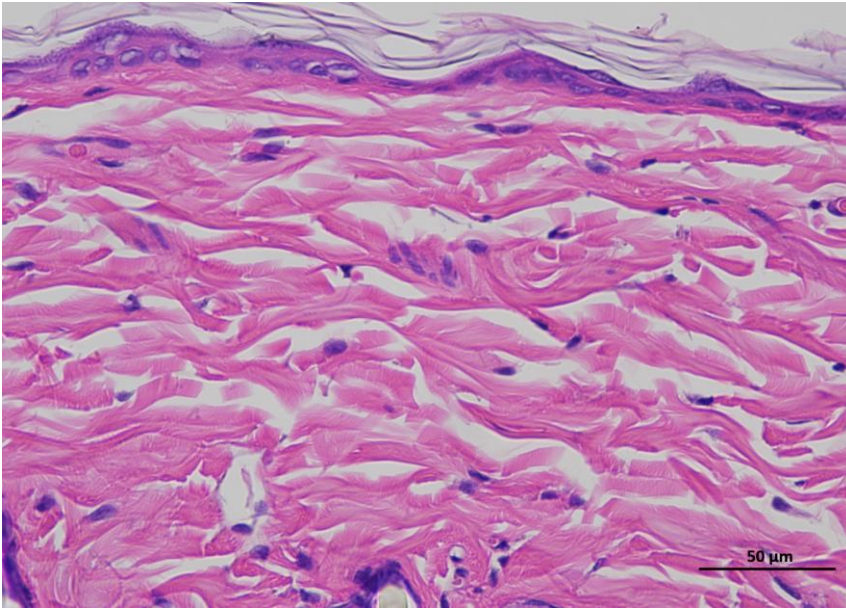
Supplementary Figure 3e | Representative H&E staining of skin tissue of rtBEV-L animals / Day 14.

Representative hematoxylin and eosin (H&E)-stained section of skin tissue collected from experimental rat. The image shows the typical architecture of the skin, including the epidermal layer with stratified keratinized epithelium and the underlying dermis composed of dense collagen fibers and connective tissue structures. (n = 6 per group).

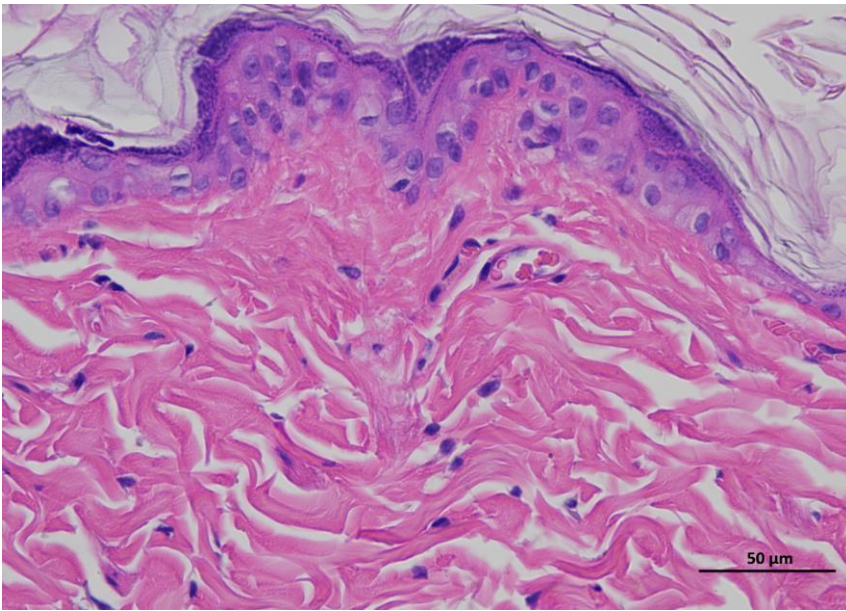


Animal 2

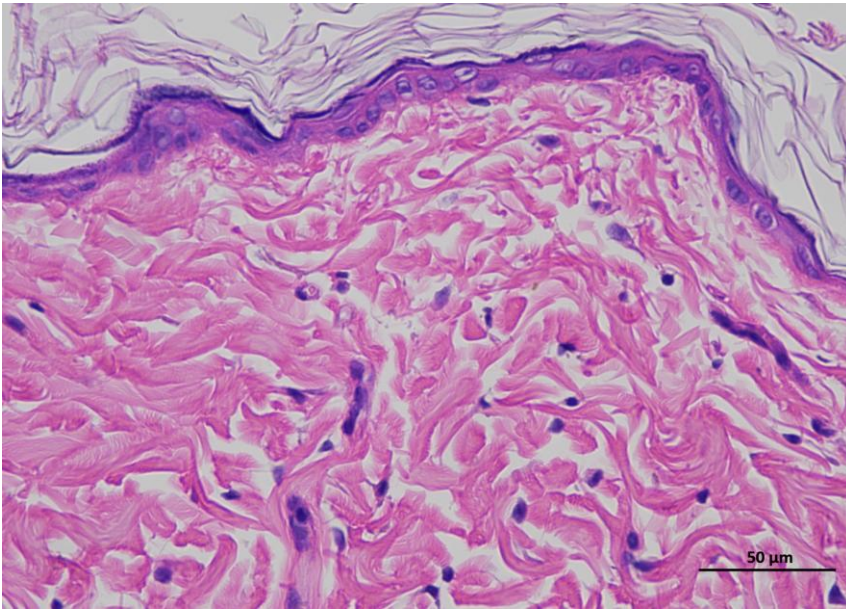
**Supplementary
Figure 3e |
Representative
H&E staining of
skin tissue of
rtBEV-L animals /
Day 14.**



2 rtBEV-L 14day 400-1



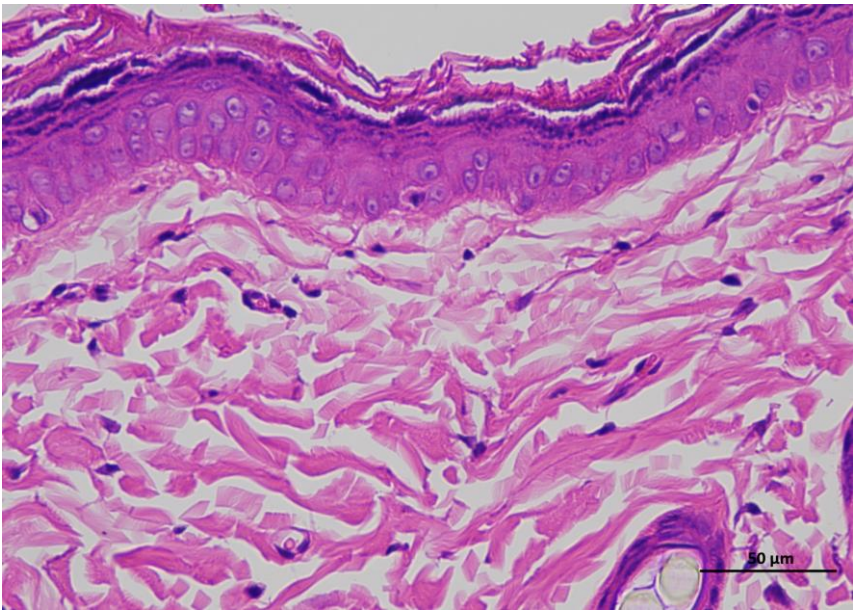
2 rtBEV-L 14day 400-2



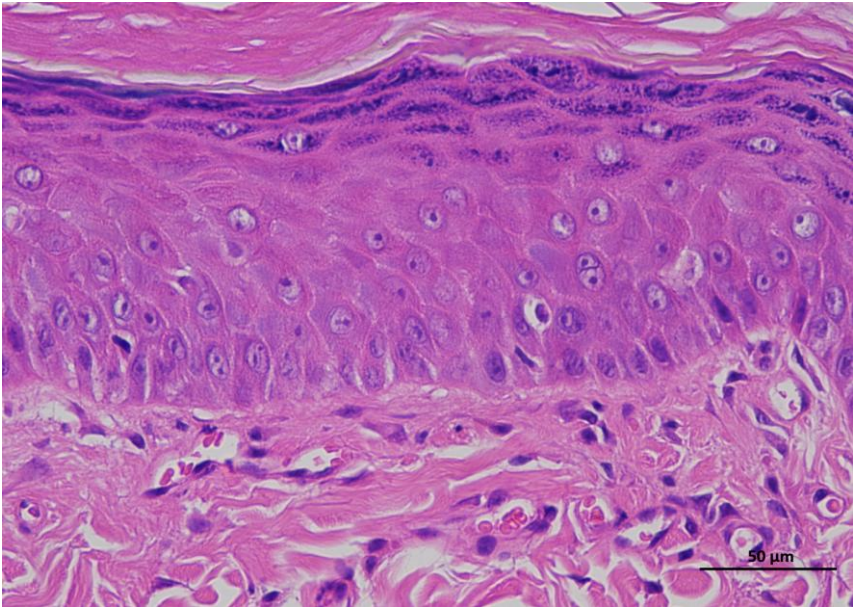
2 rtBEV-L 14day 400-3

Animal 3

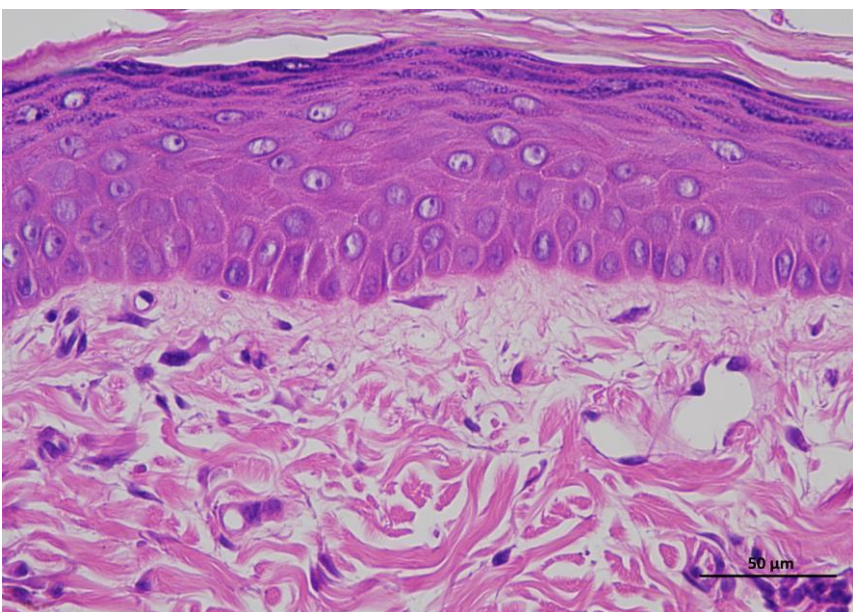
**Supplementary
Figure 3e |
Representative
H&E staining of
skin tissue of
rtBEV-L animals /
Day 14.**



3 rtBEV-L 14day 400-1



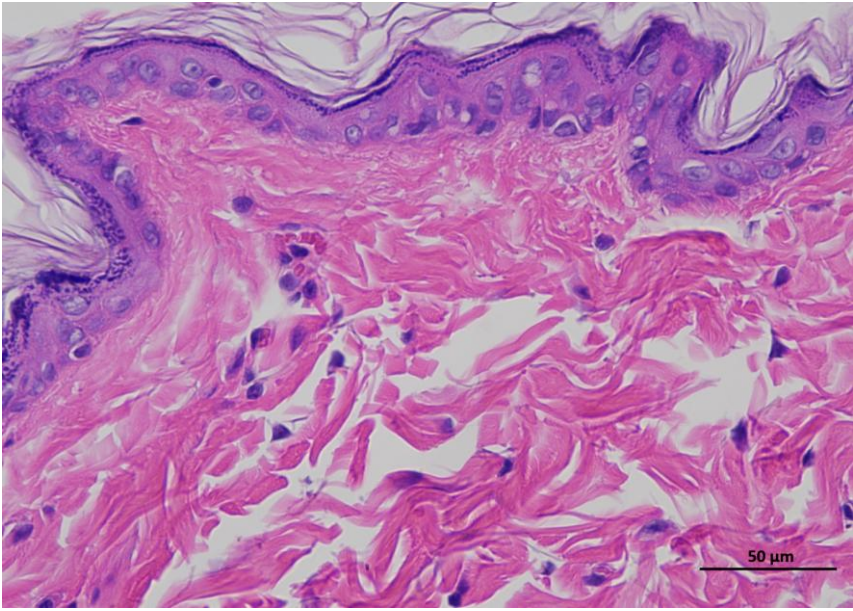
3 rtBEV-L 14day 400-2



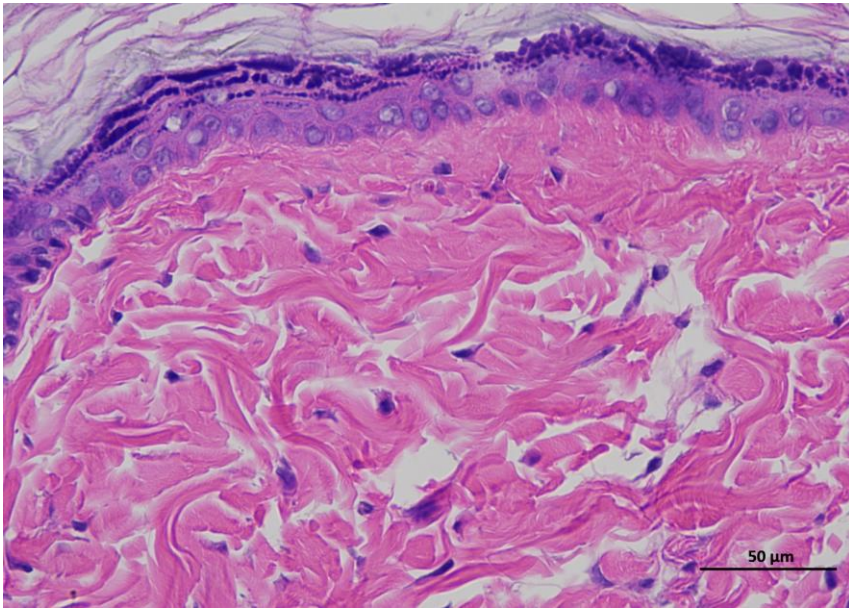
3 rtBEV-L 14day 400-3

Animal 4

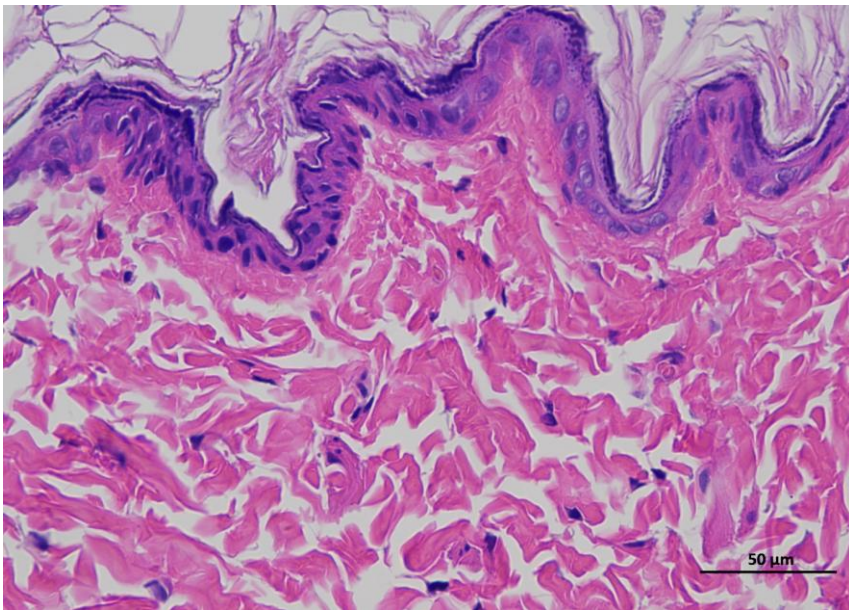
**Supplementary
Figure 3e |
Representative
H&E staining of
skin tissue of
rtBEV-L animals /
Day 14.**



4 rtBEV-L 14day 400-1



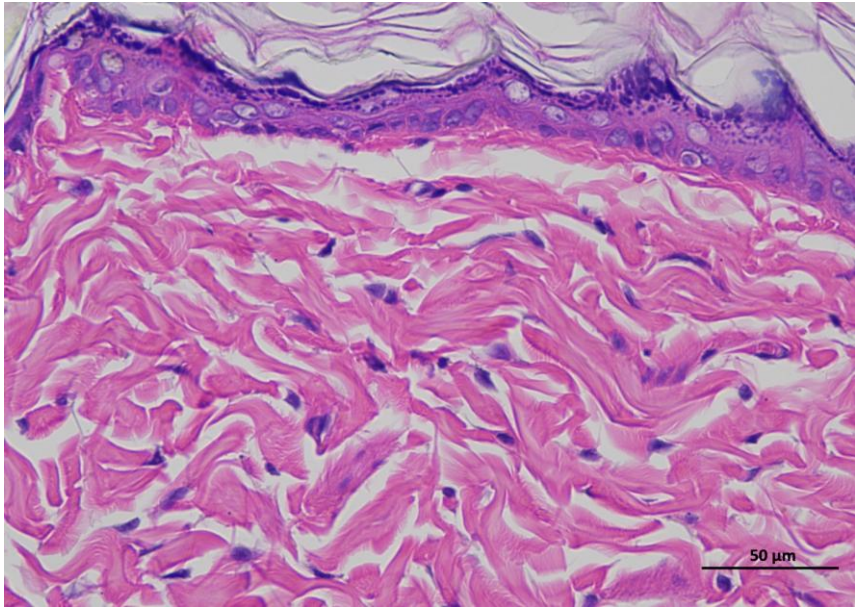
4 rtBEV-L 14day 400-2



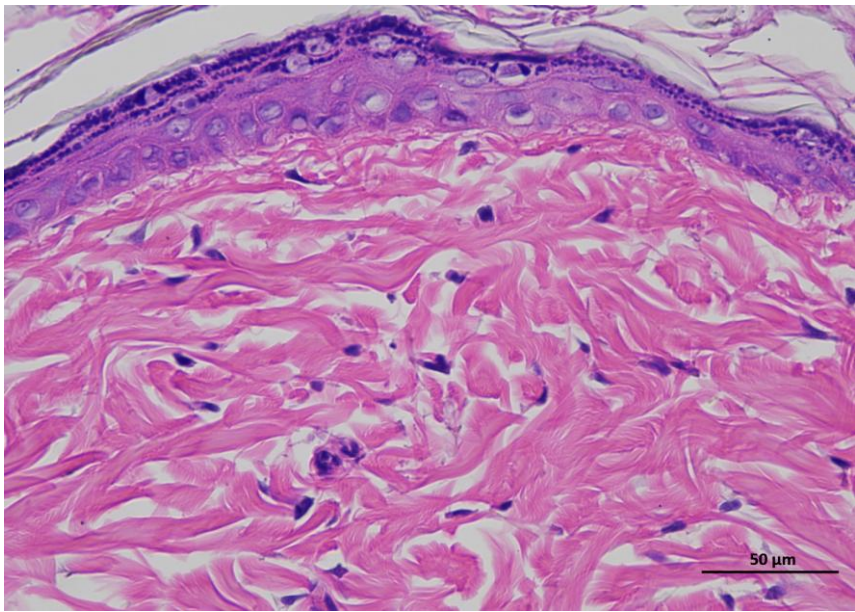
4 rtBEV-L 14day 400-3

Animal 5

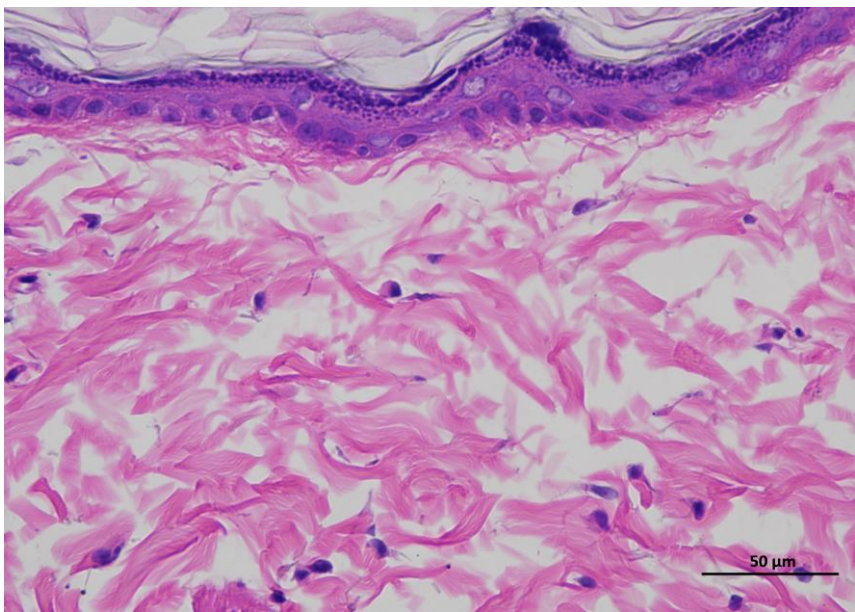
**Supplementary
Figure 3e |
Representative
H&E staining of
skin tissue of
rtBEV-L animals /
Day 14.**



5 rtBEV-L 14day 400-1



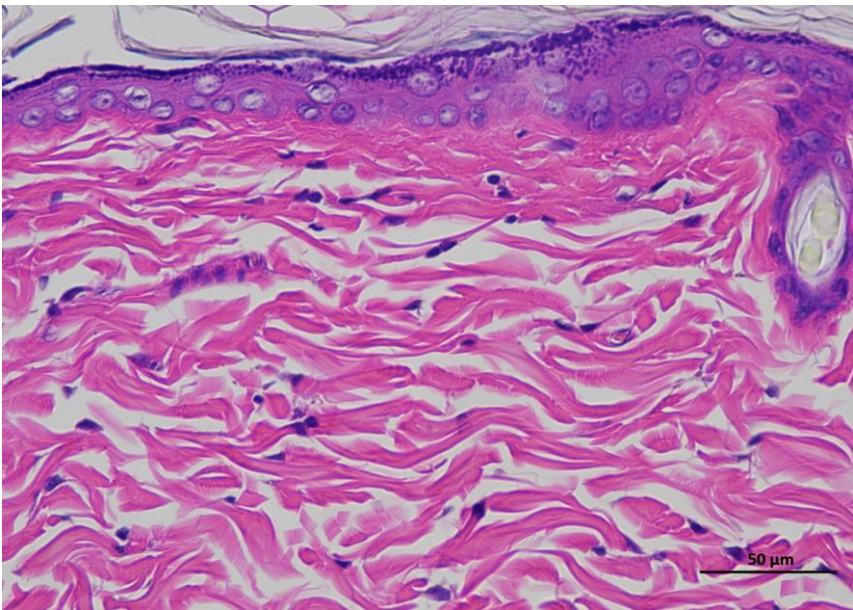
5 rtBEV-L 14day 400-2



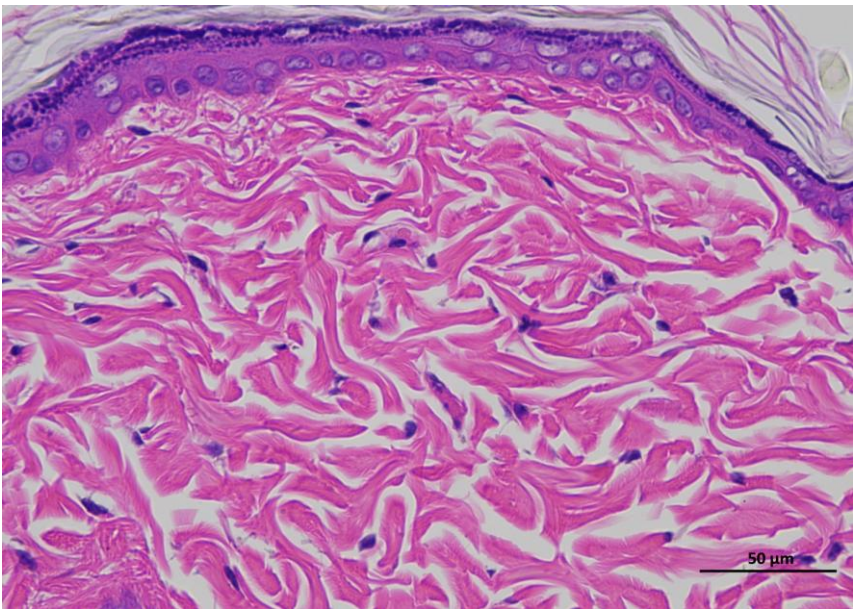
5 rtBEV-L 14day 400-3

Animal 6

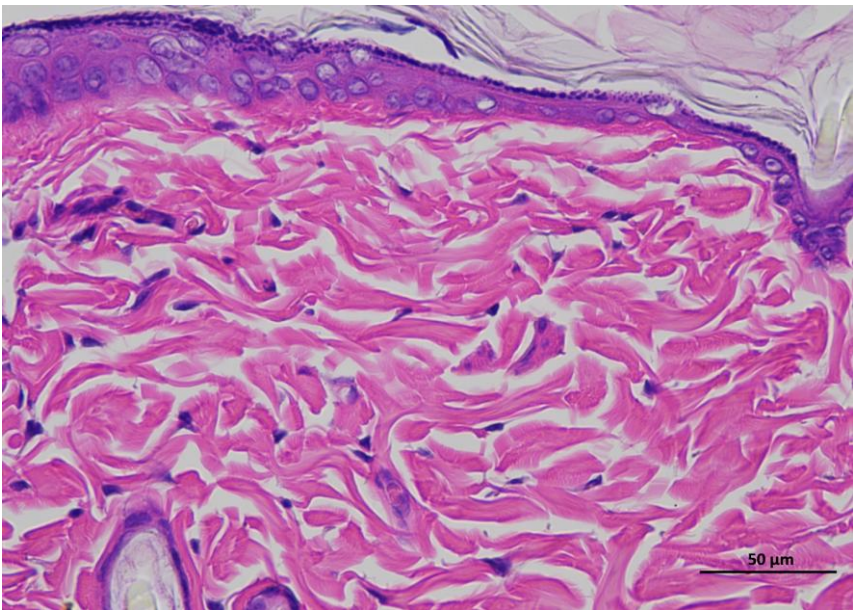
**Supplementary
Figure 3e |
Representative
H&E staining of
skin tissue of
rtBEV-L animals /
Day 14.**



6 rtBEV-L 14day 400-1



6 rtBEV-L 14day 400-2

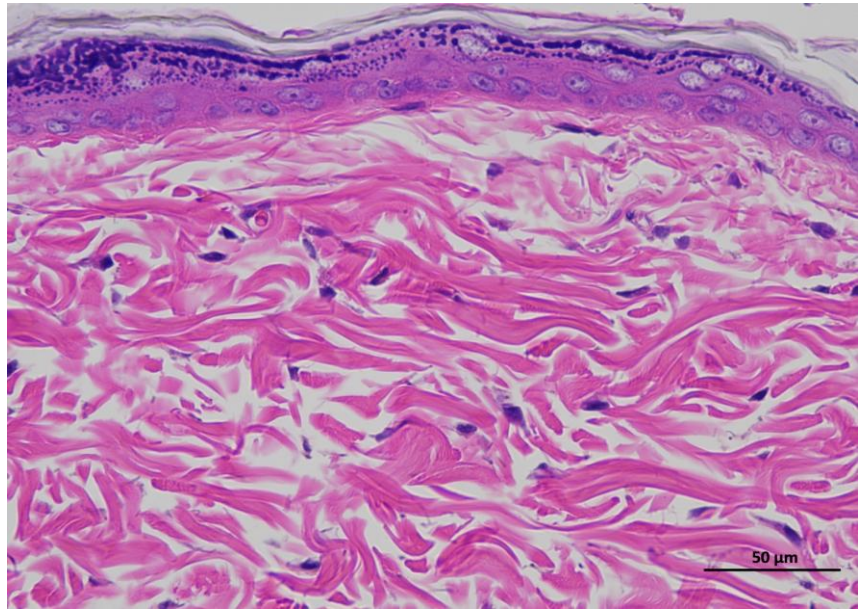


6 rtBEV-L 14day 400-3

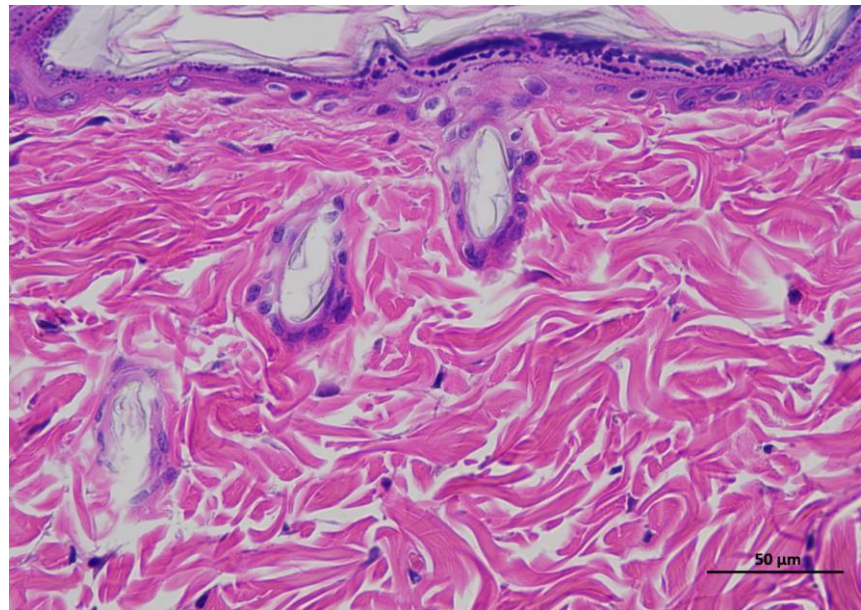
Animal 1

Supplementary Figure 2f | Representative H&E staining of skin tissue of rtBEV-H animals / Day 0.

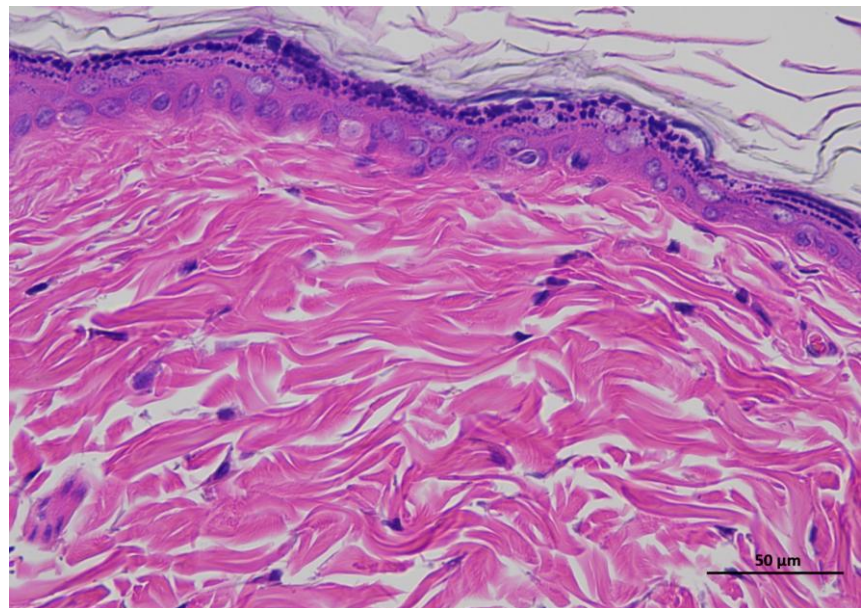
Representative hematoxylin and eosin (H&E)-stained section of skin tissue collected from experimental rat. The image shows the typical architecture of the skin, including the epidermal layer with stratified keratinized epithelium and the underlying dermis composed of dense collagen fibers and connective tissue structures. (n = 6 per group).



1 rtBEV-H 0day 400-1



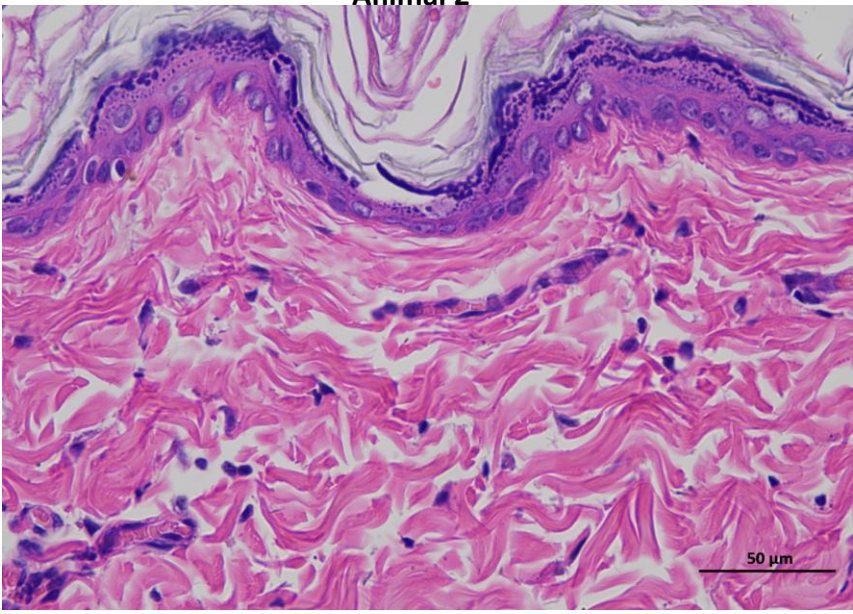
1 rtBEV-H 0day 400-2



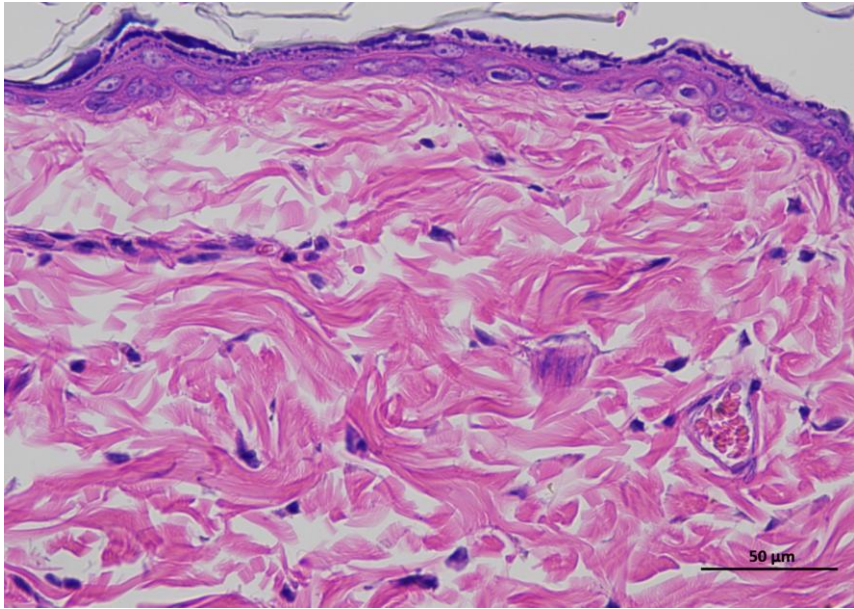
1 rtBEV-H 0day 400-3

Animal 2

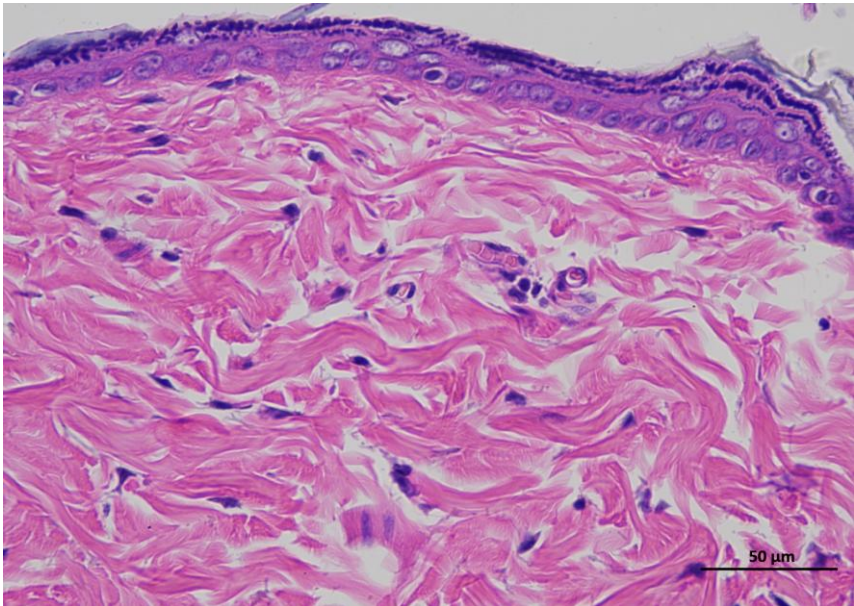
Supplementary
Figure 2f|
Representative H&E
staining of skin
tissue of mRNA
rtBEV-H animals /
Day 0.



2 rtBEV-H 0day 400-1



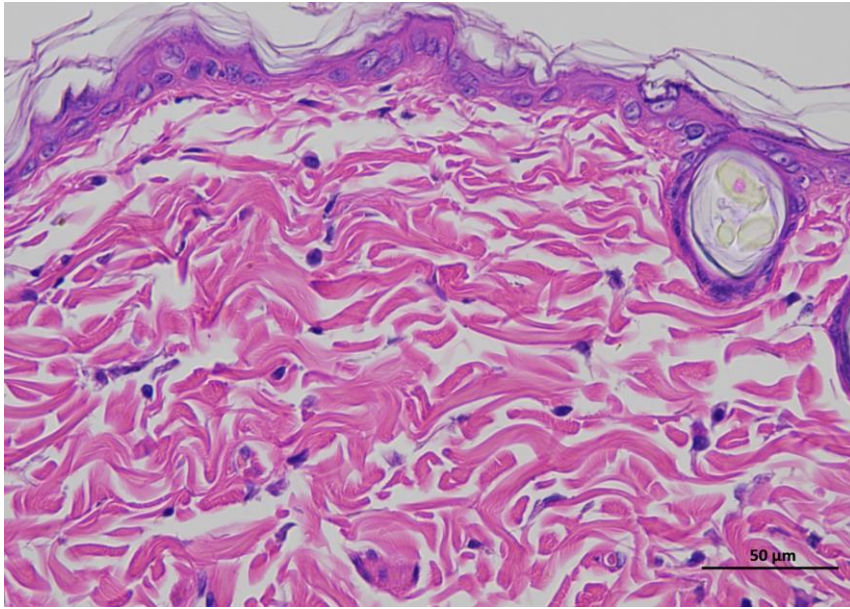
2 rtBEV-H 0day 400-2



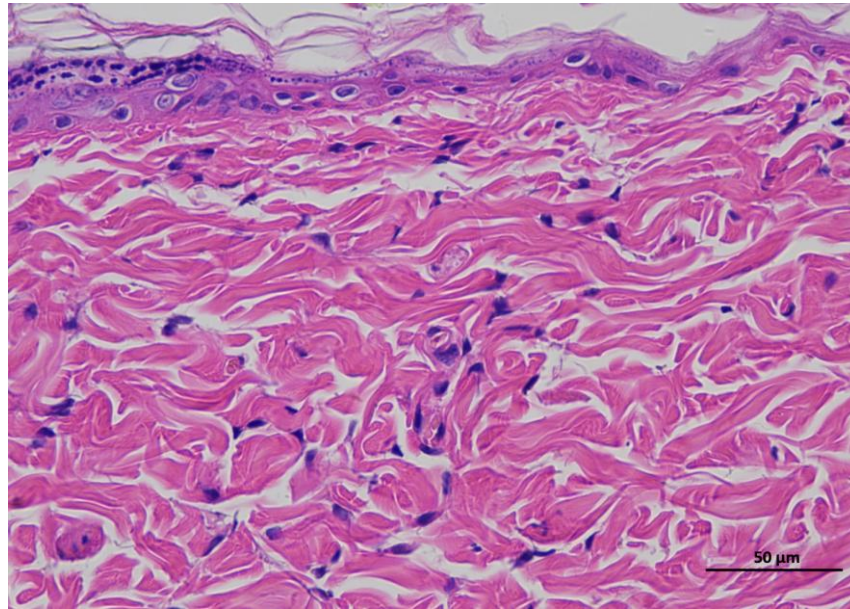
2 rtBEV-H 0day 400-3

Animal 3

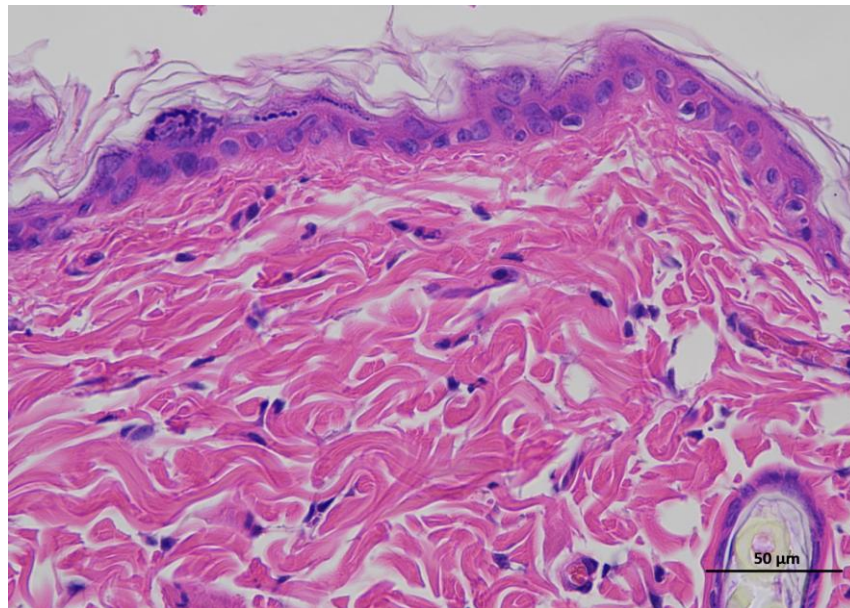
**Supplementary
Figure 2f|
Representative H&E
staining of skin
tissue of mRNA
rtBEV-H animals /
Day 0.**



3 rtBEV-H 0day 400-1



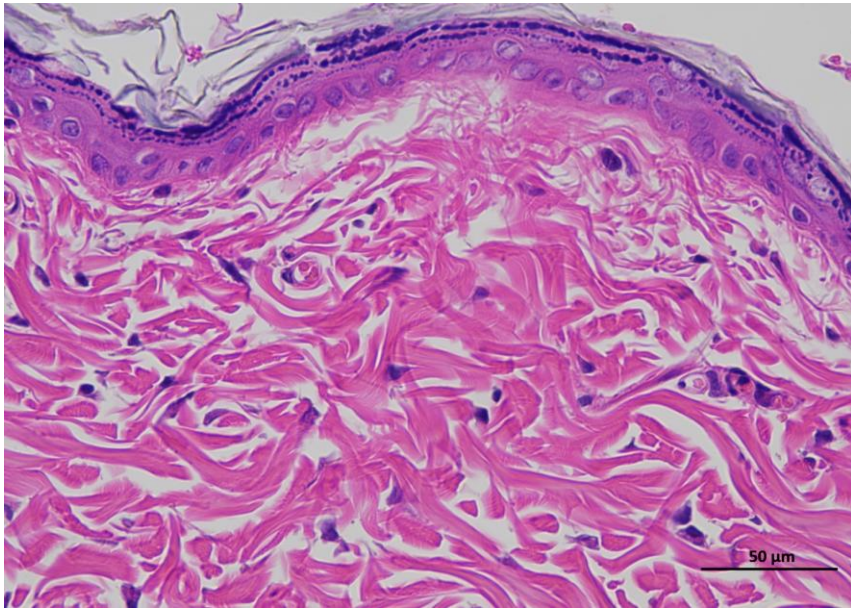
3 rtBEV-H 0day 400-2



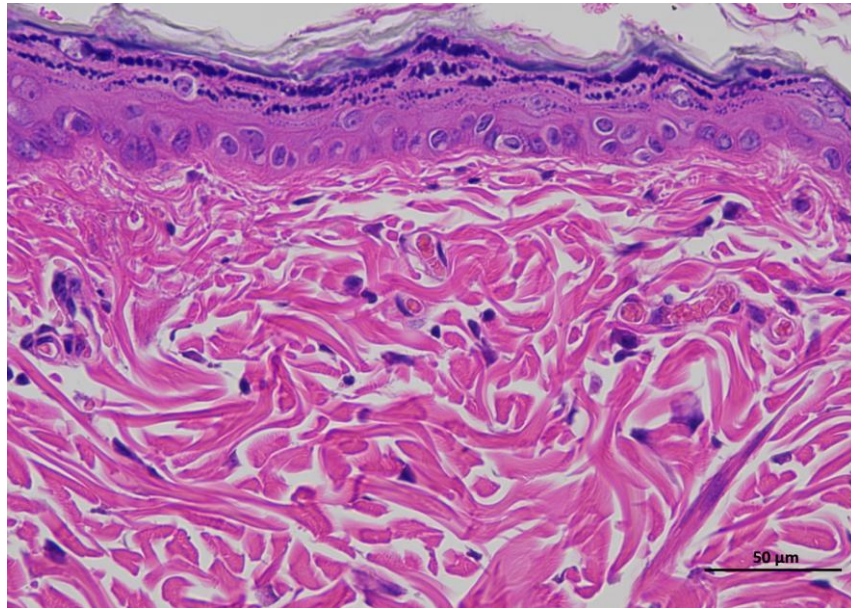
3 rtBEV-H 0day 400-3

Animal 4

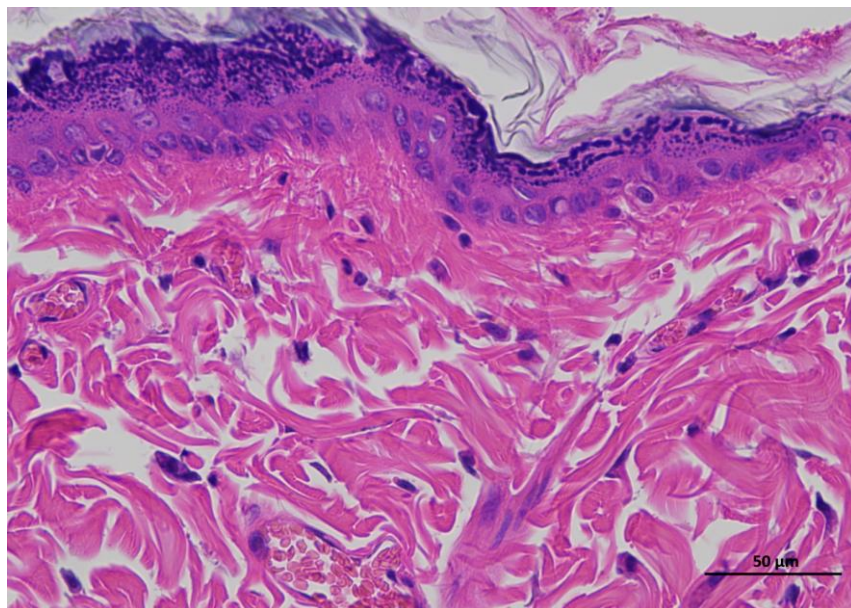
**Supplementary
Figure 2f|
Representative H&E
staining of skin
tissue of mRNA
rtBEV-H animals /
Day 0.**



4 rtBEV-H 0day 400-1



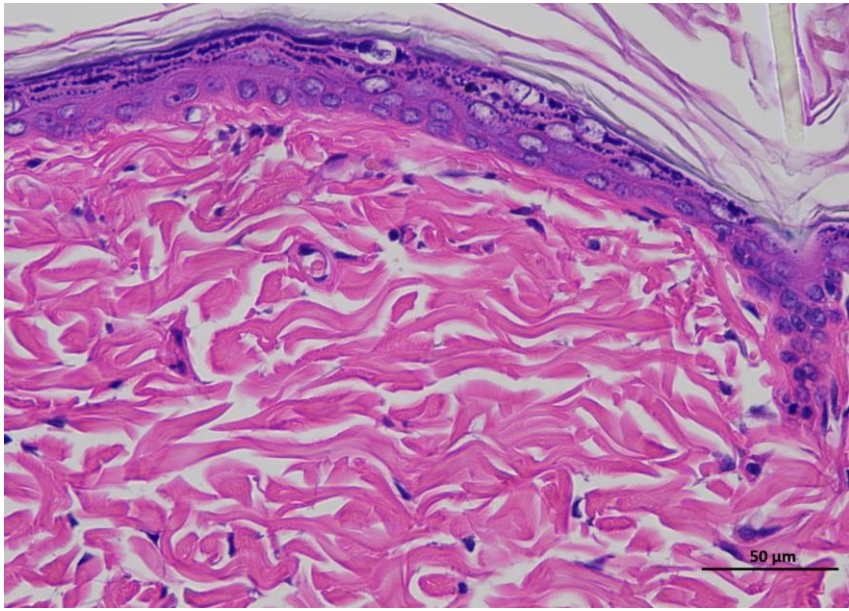
4 rtBEV-H 0day 400-2



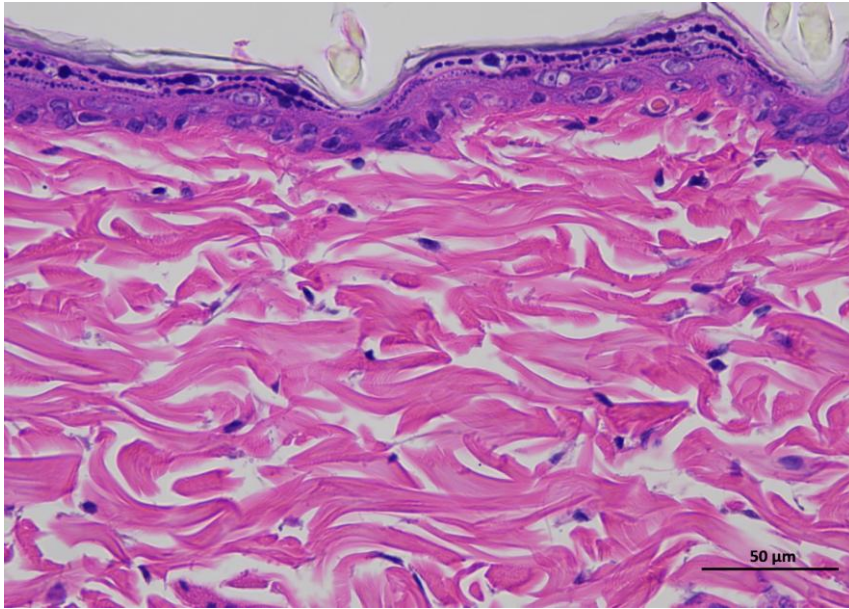
4 rtBEV-H 0day 400-3

Animal 5

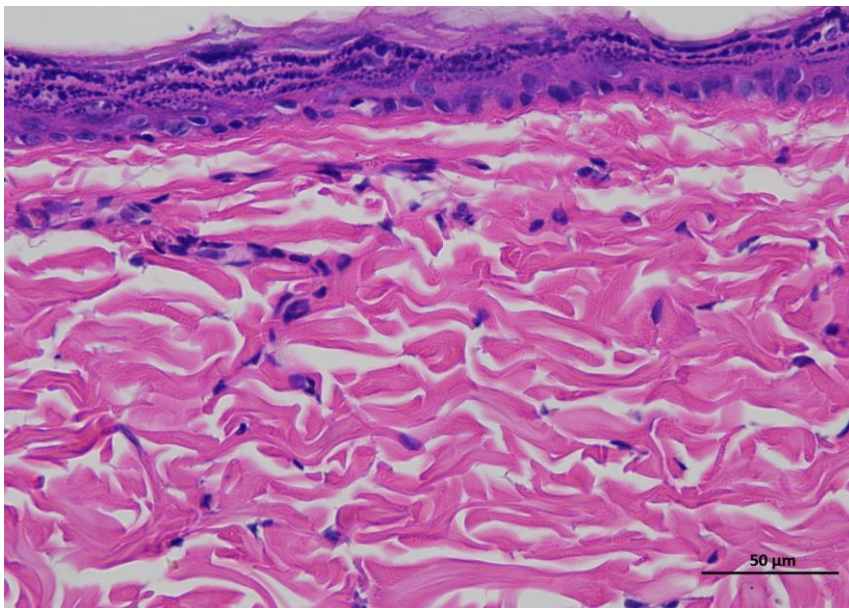
**Supplementary
Figure 2f|
Representative H&E
staining of skin
tissue of mRNA
rtBEV-H animals /
Day 0.**



5 rtBEV-H 0day 400-1



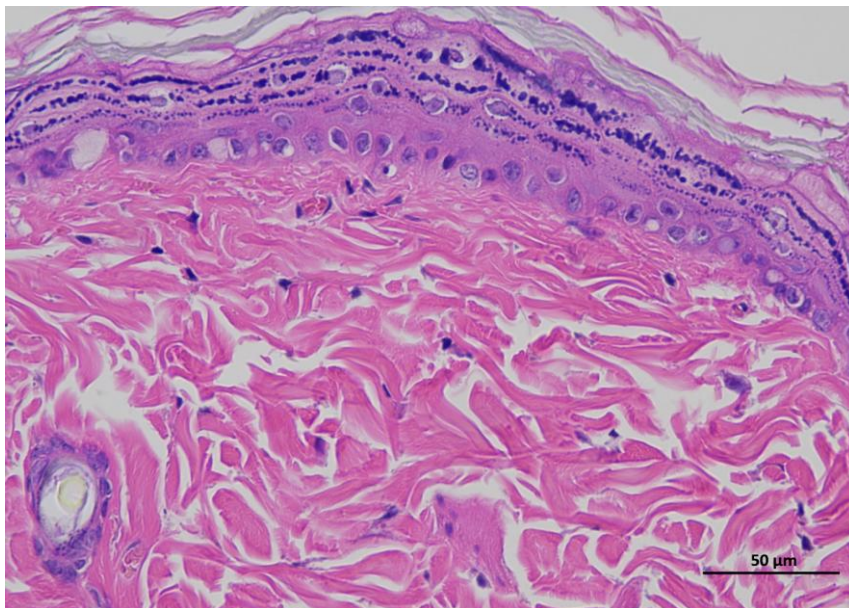
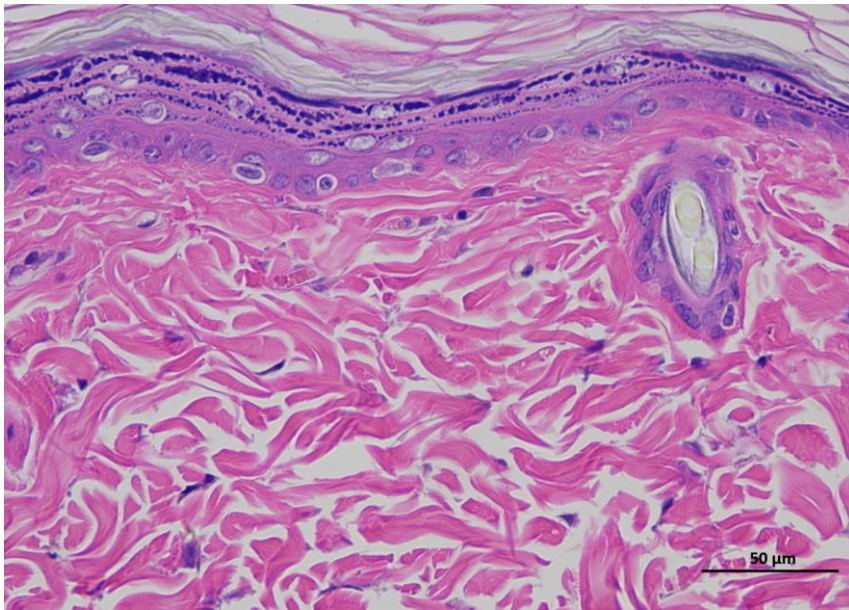
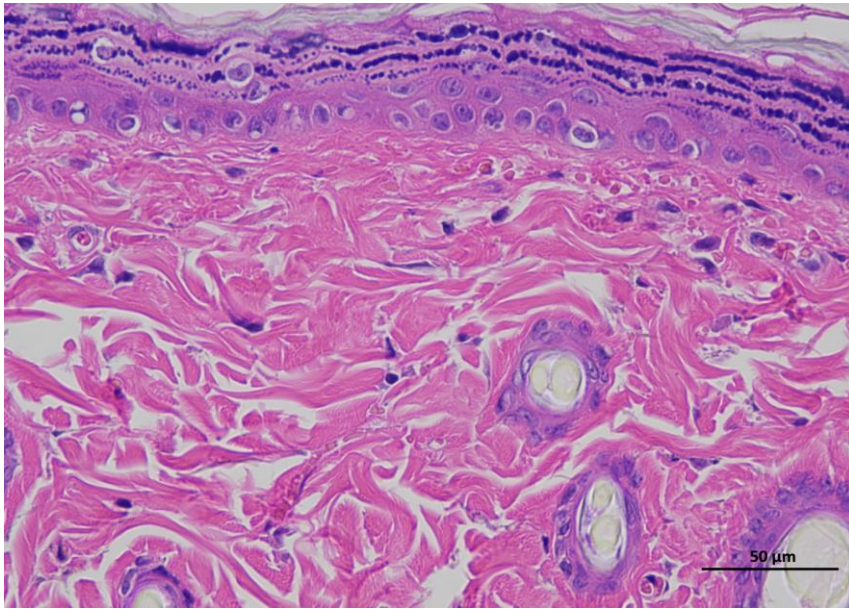
5 rtBEV-H 0day 400-2



5 rtBEV-H 0day 400-3

Animal 6

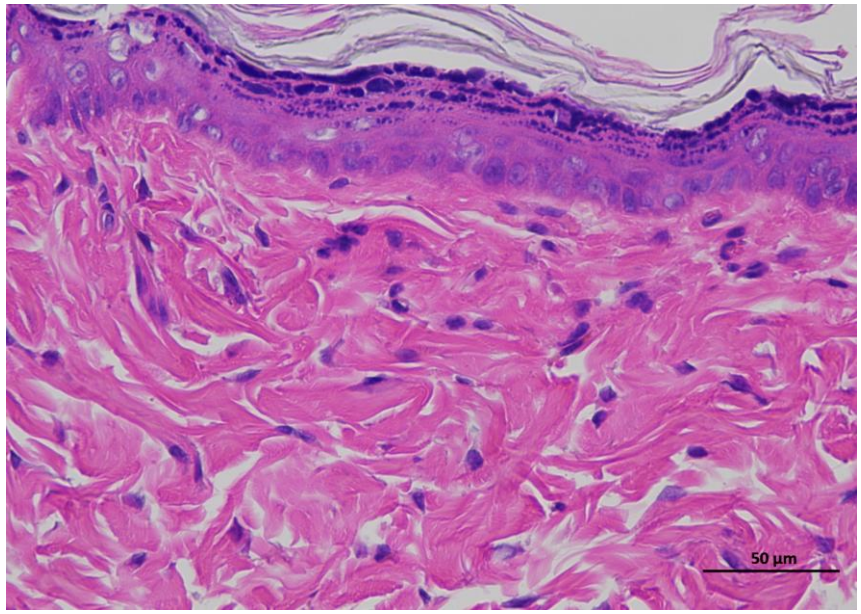
**Supplementary
Figure 2f|
Representative H&E
staining of skin
tissue of mRNA
rtBEV-H animals /
Day 0.**



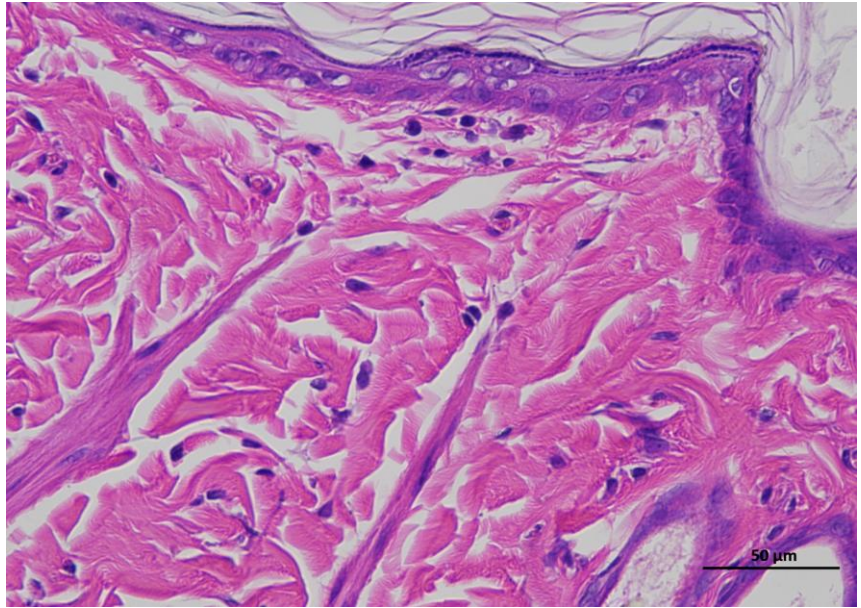
Animal 1

Supplementary Figure 3f | Representative H&E staining of skin tissue of rtBEV-H animals / Day 14.

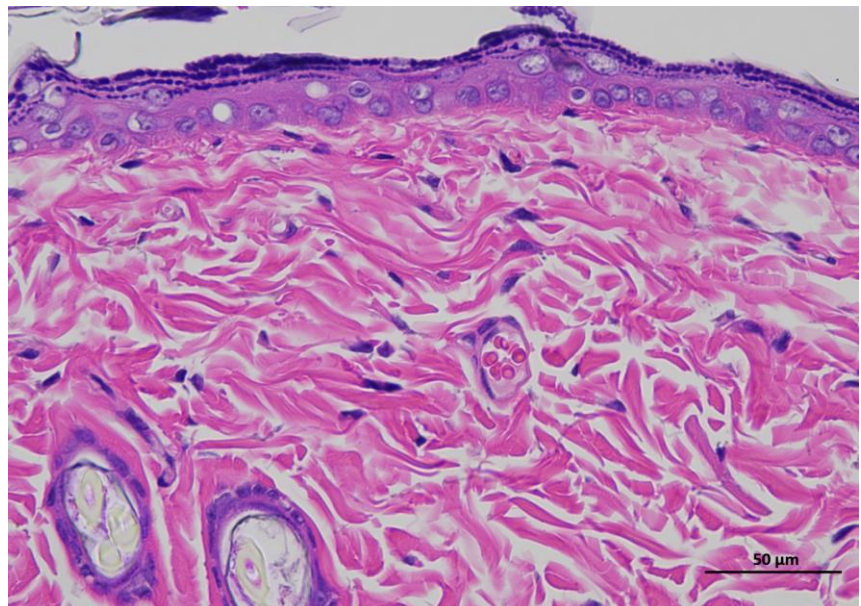
Representative hematoxylin and eosin (H&E)-stained section of skin tissue collected from experimental rat. The image shows the typical architecture of the skin, including the epidermal layer with stratified keratinized epithelium and the underlying dermis composed of dense collagen fibers and connective tissue structures. (n = 6 per group).



1 rtBEV-H 14day 400-1



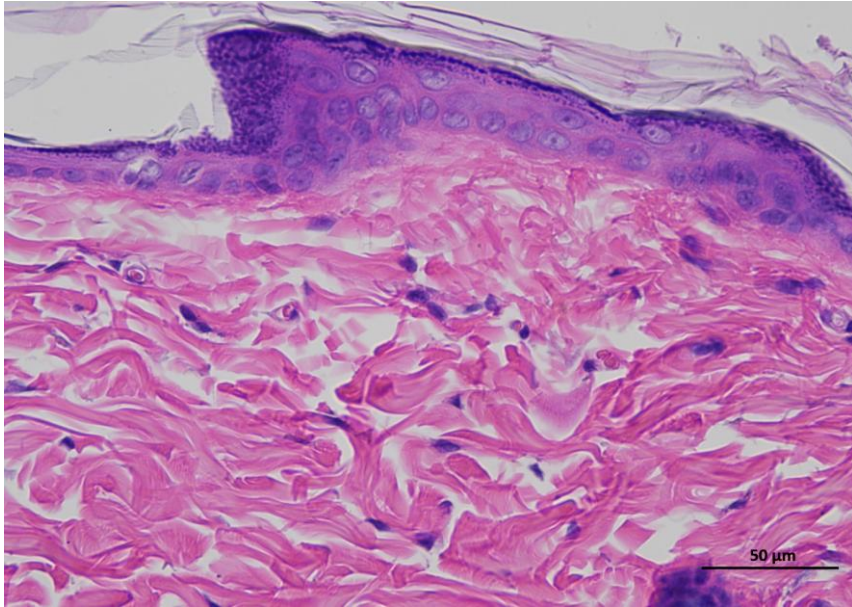
1 rtBEV-H 14day 400-2



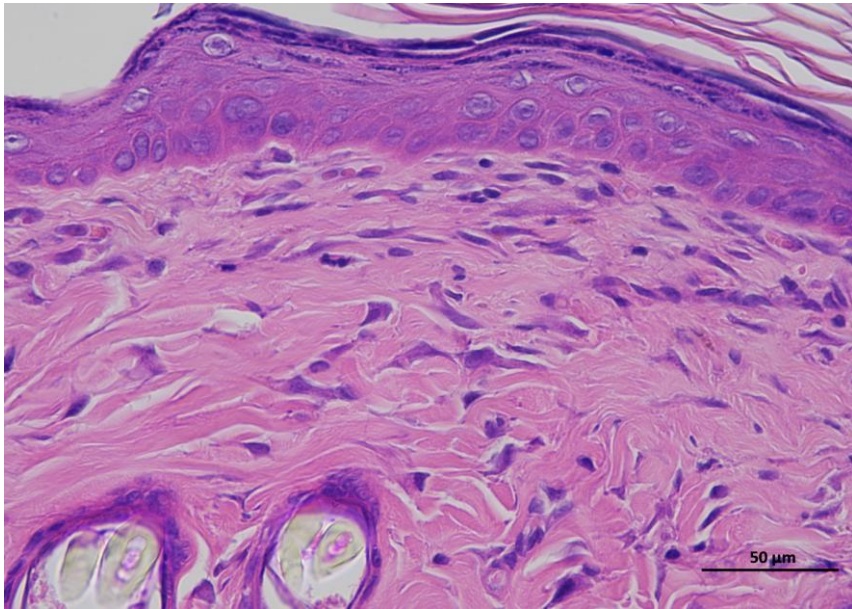
1 rtBEV-H 14day 400-3

Animal 1

**Supplementary
Figure 3f |
Representative
H&E staining of
skin tissue of
rtBEV-H animals
/ Day 14.**



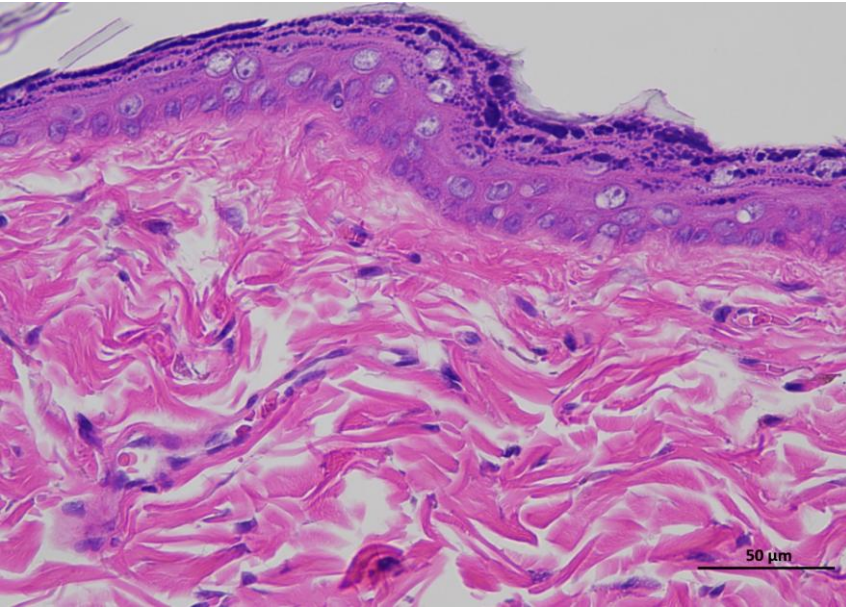
1 rtBEV-H 14day 400-4



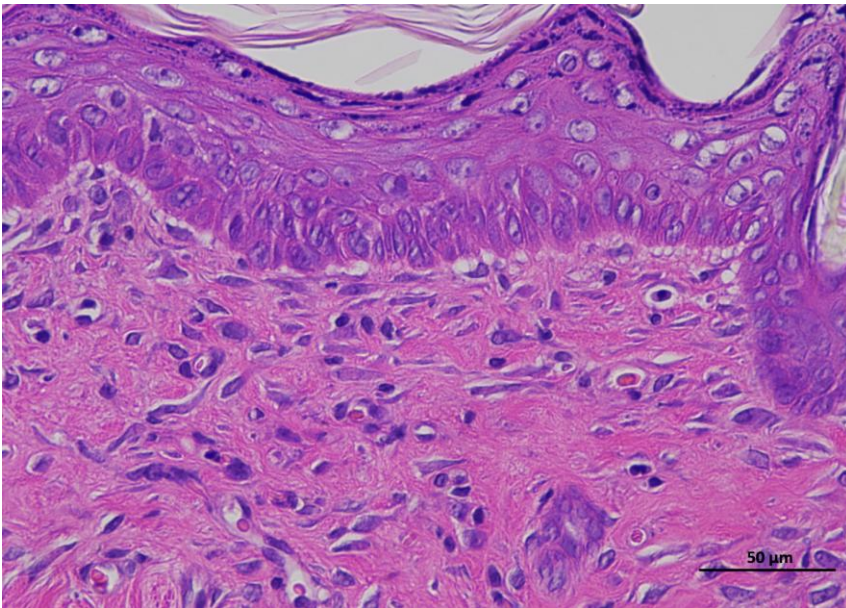
1 rtBEV-H 14day 400-5

Animal 2

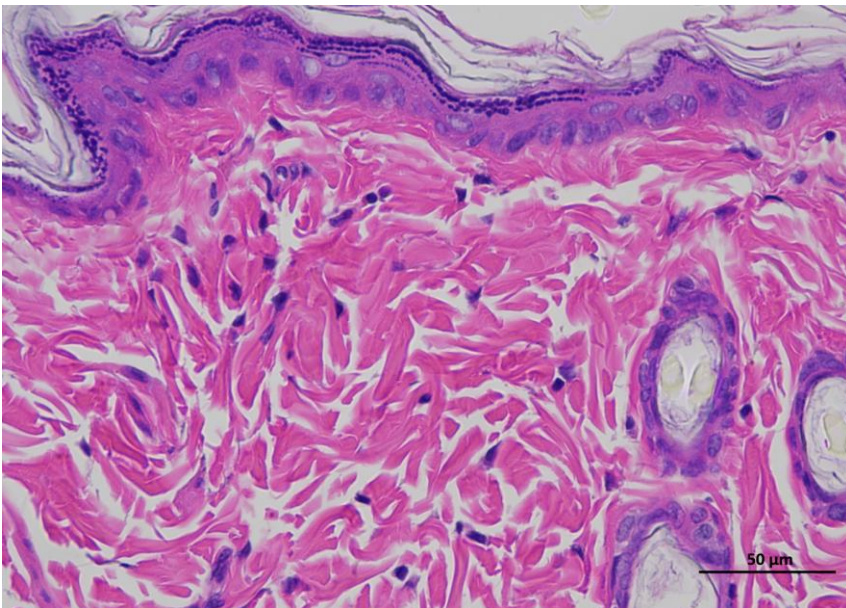
**Supplementary
Figure 3f |
Representative
H&E staining of
skin tissue of
rtBEV-H animals
/ Day 14.**



2 rtBEV-H 14day 400-1



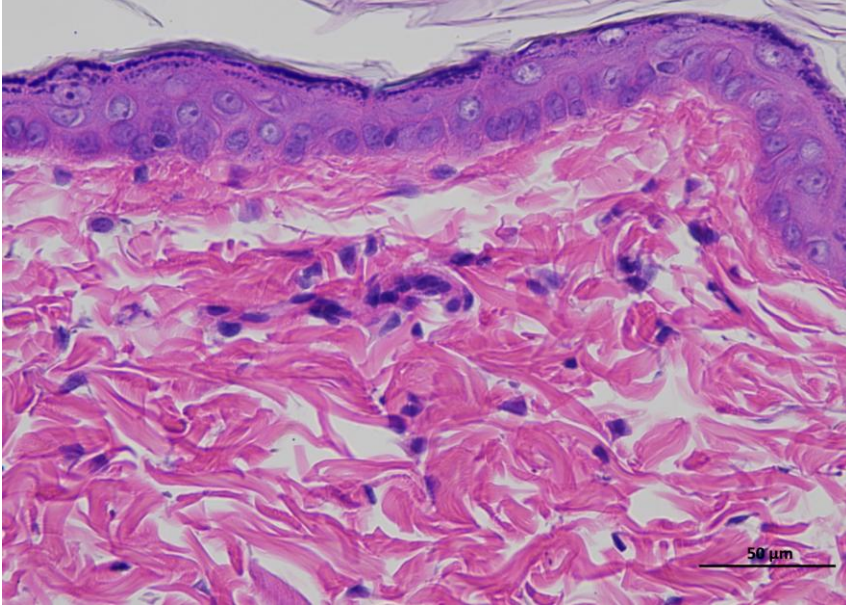
2 rtBEV-H 14day 400-2



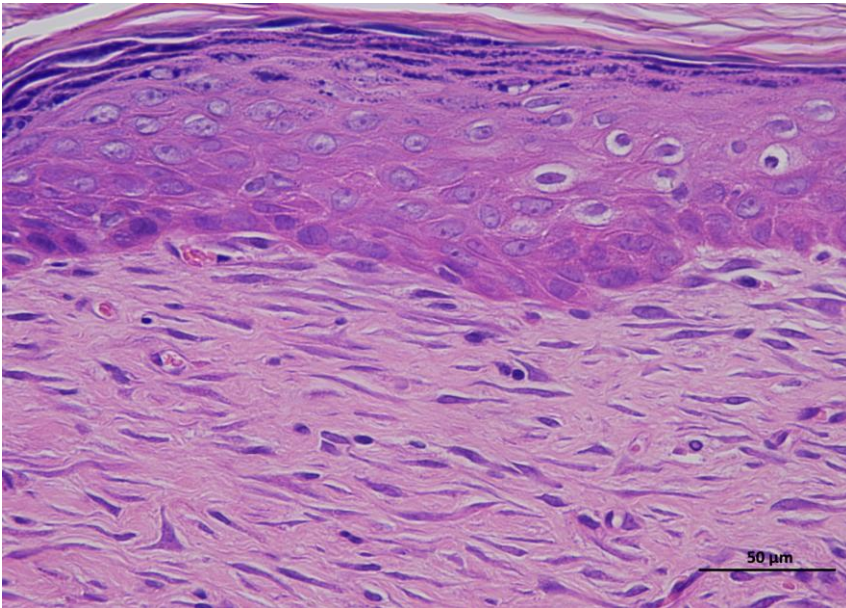
2 rtBEV-H 14day 400-3

Animal 2

Supplementary
Figure 3f |
Representative
H&E staining of
skin tissue of
rtBEV-H animals
/ Day 14.



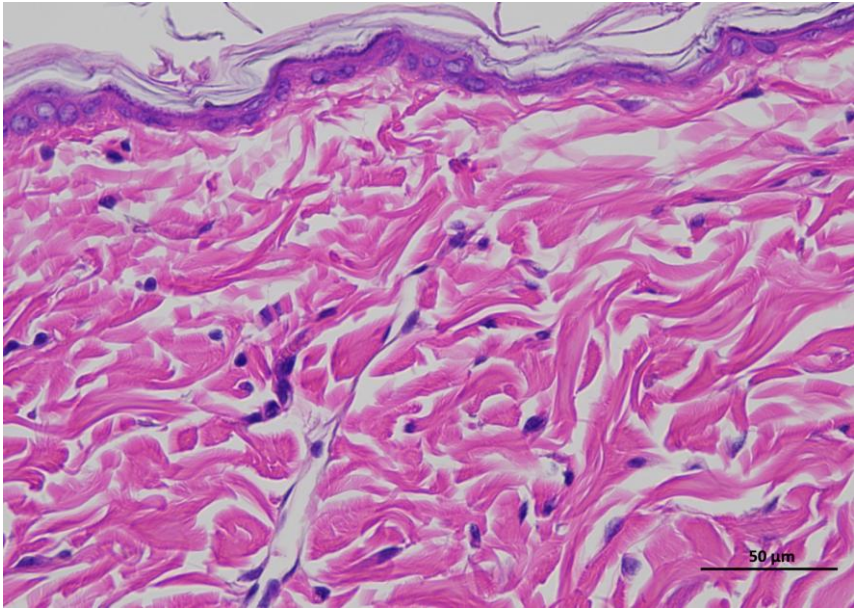
2 rtBEV-H 14day 400-4



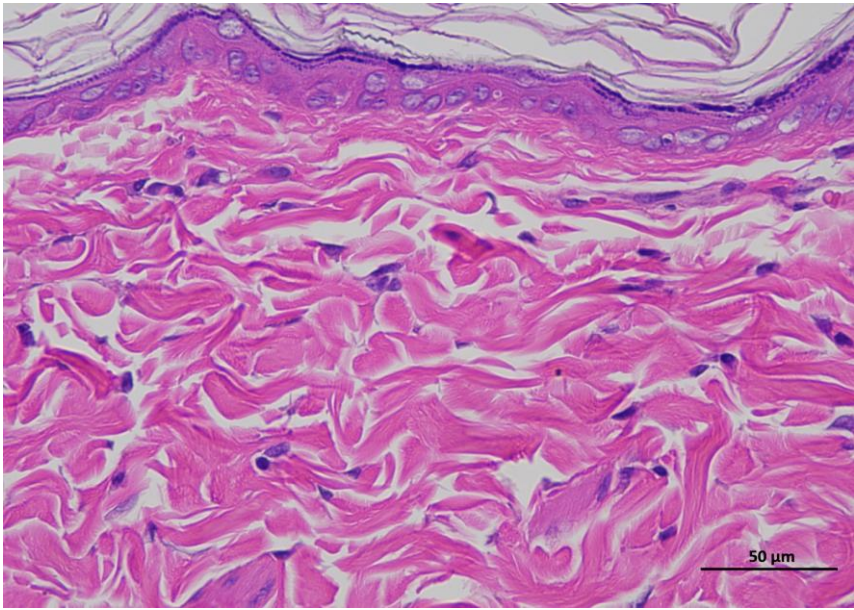
2 rtBEV-H 14day 400-5

Animal 3

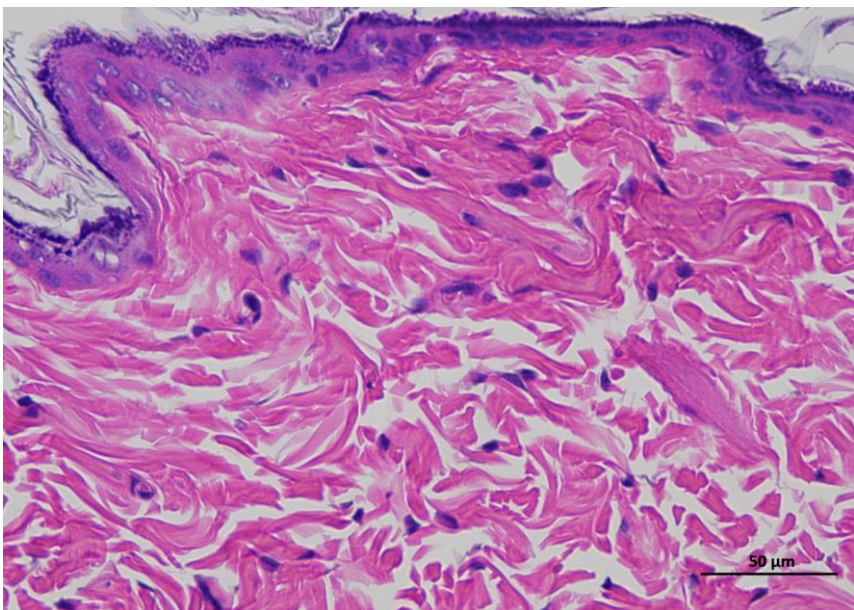
**Supplementary
Figure 3f |
Representative
H&E staining of
skin tissue of
rtBEV-H animals
/ Day 14.**



3 rtBEV-H 14day 400-1



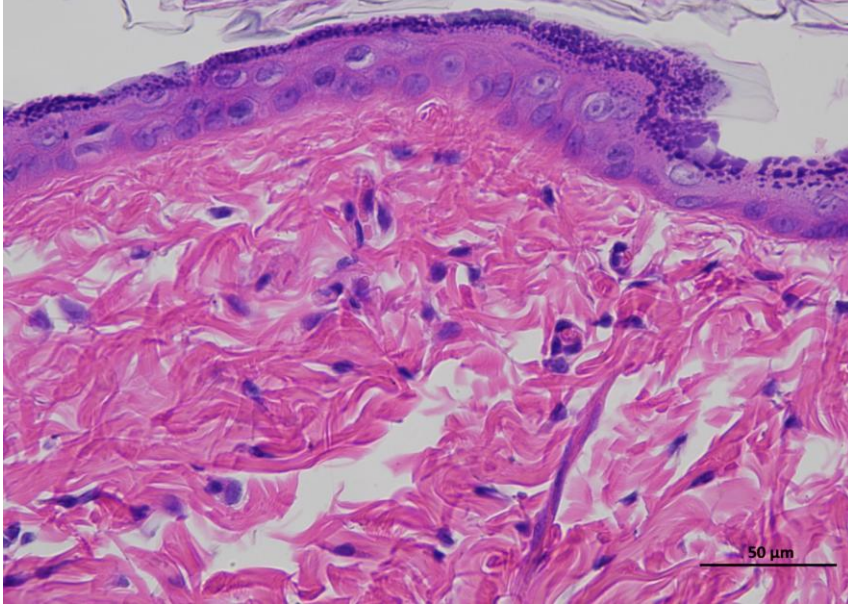
3 rtBEV-H 14day 400-2



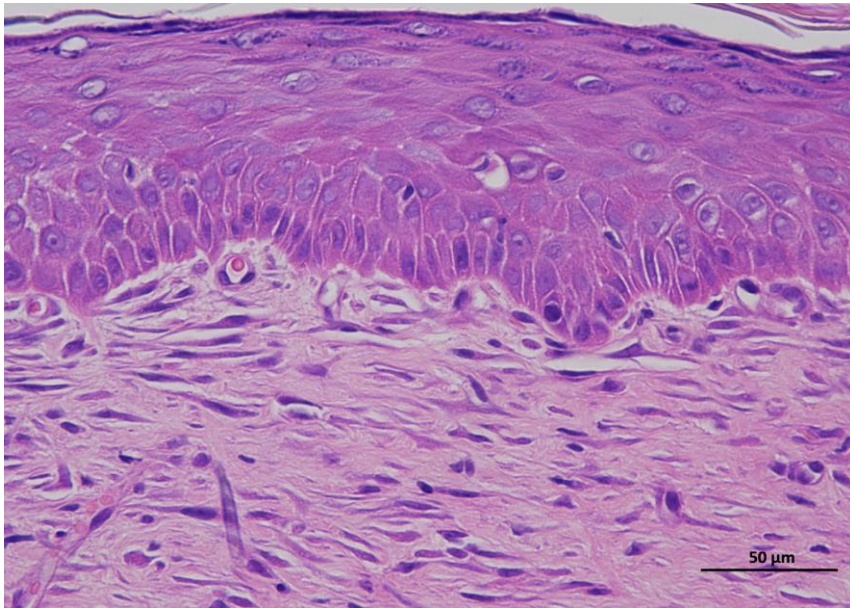
3 rtBEV-H 14day 400-3

Animal 3

**Supplementary
Figure 3f |
Representative
H&E staining of
skin tissue of
rtBEV-H animals
/ Day 14.**



3 rtBEV-H 14day 400-4



3 rtBEV-H 14day 400-5