Research Square

Preprints are preliminary reports that have not undergone peer review.
They should not be considered conclusive, used to inform clinical practice,
or referenced by the media as validated information.

# Long-term Morphological Outcomes of Patient-Specific PEEK Cranioplasty in Infants and Toddlers: A 5-Year Case Series Assessing Cranial Growth and Symmetry

**yanzhao wang**

wangyanzhao25@mails.tsinghua.edu.cn

Qilu Hospital of Shandong University

**Wei Qiu**

Qilu Hospital of Shandong University

**Jie Gong**

Qilu Hospital of Shandong University

**Research Article**

**Keywords:** Pediatric cranioplasty, PEEK, Skull lesions, Infants and Toddlers, Cranial growth, CVAI

**Posted Date:** May 21st, 2026

**DOI:** https://doi.org/10.21203/rs.3.rs-9245261/v1

**License:** This work is licensed under a Creative Commons Attribution 4.0 International License. Read Full License

**Additional Declarations:** No competing interests reported.

## Abstract

Objective: The use of rigid alloplastic materials for cranial reconstruction in infants remains controversial due to theoretical concerns regarding growth restriction. This study aims to evaluate the long-term safety and morphological outcomes of primary personalized polyetheretherketone (PEEK) cranioplasty following the resection of skull lesions in infants and toddlers.

Methods: A retrospective analysis was conducted on five consecutive pediatric patients (mean age 14.4 months; range 5–19 months) who underwent skull lesion resection and immediate reconstruction with computer-aided design (CAD)/3D-printed PEEK inlays. To objectively assess cranial symmetry, the Cranial Vault Asymmetry Index (CVAI) was calculated using preoperative and long-term follow-up (more than 1 year) three-dimensional CT data.

Results: During a mean follow-up period of 32 months (range 16–60 months), no implant-related complications, such as infection, exposure, or migration, were observed. The mean CVAI improved from 4.19% ± 2.58% preoperatively to 2.17% ± 1.55% at the final follow-up. Notably, the youngest patient (operated at 5 months) demonstrated significant normalization of cranial shape, with the CVAI decreasing from 6.57% to 0.75% over 5 years. Patients with pre-existing asymmetry showed a trend toward improvement, while those with initial symmetry remained stable.

Conclusions: This preliminary case series indicates that personalized PEEK cranioplasty may be a safe and feasible technique for reconstructing large skull defects in infants and toddlers. In this small cohort, no radiological evidence of growth restriction or secondary craniosynostosis was identified during the follow-up period. The observed improvement in cranial symmetry suggests that physiological remodeling can occur around rigid implants. These findings are hypothesis-generating and warrant validation through larger, prospective studies.


## Introduction

The management of large-scale cranial defects in infants and toddlers represents a formidable challenge in pediatric neurosurgery. While various etiologies, including congenital anomalies, trauma, and tumor resections, can necessitate cranioplasty, the optimal timing and choice of reconstructive material remain subjects of intense debate. [1]This is particularly true for defects following the resection of benign but aggressive skull lesions, such as Langerhans cell histiocytosis (LCH) or giant cell reparative granuloma (GCRG), where achieving both immediate structural protection and long-term aesthetic symmetry is paramount.[2][3][4]

Historically, autologous bone has been regarded as the "gold standard" for pediatric cranioplasty due to its biocompatibility and osteoconductive potential. However, clinical reality in the youngest cohorts often falls short of these theoretical benefits. Previous literature, including high-impact studies, has documented staggering bone resorption rates—often exceeding 80%—in children under the age of two.[5] Such failures lead to repeated surgical interventions, increased psychological burden on families, and compromised neuroprotection during critical stages of brain development.[6]

Polyetheretherketone (PEEK), a semi-crystalline thermoplastic with a Young’s modulus closely mimicking that of human cortical bone, has emerged as a compelling alternative. Through Computer-Aided Design and Manufacturing (CAD/CAM), personalized PEEK implants provide superior contour matching and structural integrity. [7] Nevertheless, a major "dogma" persists in pediatric practice: the concern that rigid, non-resorbable alloplastic materials may act as a "restrictive cage,"inhibiting the physiological expansion of the rapidly growing infantile skull and potentially inducing secondary craniosynostosis or significant asymmetry.[8]

Current evidence regarding the long-term impact of PEEK on the developing cranium remains sparse, particularly in infants operated on during their first two years of life—the period of most rapid brain growth. In this study, we present a longitudinal case series of five infants and toddlers who underwent primary PEEK cranioplasty following resection of skull lesions.[9] [10]By utilizing the Cranial Vault Asymmetry Index (CVAI) [11] for quantitative morphological analysis and providing follow-up data for up to five years, we aimed to evaluate whether personalized PEEK inlays can safely accommodate cranial growth while maintaining long-term structural and aesthetic stability.

# Methods

## Patient Population and Ethical Considerations

A retrospective clinical study was conducted on a consecutive series of infants and toddlers who underwent personalized PEEK cranioplasty following the resection of benign but aggressive skull lesions at our institution between 2019 and 2022. Inclusion criteria were: (1) age ≤ 24 months at the time of surgery; (2) primary reconstruction using CAD/CAM-designed PEEK inlays; and (3) a minimum follow-up period of 12 months with complete radiological data. The study was approved by the Institutional Review Board. **The requirement for informed consent was waived** due to the retrospective nature of the study and the use of de-identified data. (Table.1)

Preoperative Planning and Implant Design

All patients underwent high-resolution thin-section computed tomography (CT) (slice thickness ≤ 1.25 mm). The DICOM data were imported into specialized reconstruction software (e.g., Mimics, Materialise, Belgium). Following virtual resection of the lesion, a digital 3D model of the cranial defect was generated. A personalized PEEK implant was then designed using a mirror-image technique or anatomical contour matching. To accommodate the unique requirements of the pediatric cranium, all implants were designed as inlays with a bevelled edge to ensure a flush interface with the native bone, thereby minimizing palpable ridges and preventing restricted expansion.

Surgical Technique

Under general anesthesia, a tailored scalp incision was performed to expose the lesion and the surrounding healthy bone margins. Following total lesion resection, the sterilized patient-specific PEEK implant was placed into the defect. Fixation was achieved using a limited number of low-profile titanium micro-plates and screws (1.5 mm system). Strategic care was taken to avoid bridging or tethering active cranial sutures (e.g., coronal, sagittal, or lambdoid sutures) to allow for continued physiological expansion. The pericranium and scalp were closed in a standard multilayered fashion. Fig. 3

Morphometric Quantitative Analysis: The Modified CVAI Method

To objectively and comprehensively evaluate cranial symmetry, we employed a modified Cranial Vault Asymmetry Index (CVAI) assessment based on 3D-CT multi-planar reconstruction (MPR).

Measurement Protocol:

Measurements were performed on the axial slice representing the maximum cranial circumference. Unlike the traditional single-diagonal method, we introduced an enhanced multi-vector approach to minimize measurement bias:

1. Standard Diagonals: The primary diagonals were measured between the frontozygomatic suture and the contralateral eurion (Diagonal A: Right Frontal - Left Occipital; Diagonal B: Left Frontal - Right Occipital).

2. 30° Offset Diagonals: To capture paracentral asymmetry, additional diagonals (A’ and B’) were measured at a 30° angle from the anterior midline toward the right and left parietal-occipital regions, respectively.

Calculation and Averaging:

The CVAI for each set of diagonals was calculated using the following optimized formula:

CVAI (%) = |Diagonal A(A') - Diagonal B(B')| / Shorter Diagonal × 100%

(Note: We utilized the shorter diagonal as the denominator to enhance the sensitivity of the index in detecting subtle asymmetries.)Fig. 1

The final CVAI value for each patient at each follow-up point was defined as the mean of the standard and 30° offset calculations. This dual-vector averaging approach provides a more robust representation of the overall cranial vault morphology. A mean CVAI < 3.5% was defined as the threshold for clinical symmetry, while values > 6.25% indicated significant asymmetry. [12]

(The symmetry was assessed using a multi-vector approach on the axial slice of maximum cranial circumference. (A) Standard diagonals (A and B) measured between the frontozygomatic suture and the contralateral eurion. (B) Enhanced paracentral vectors (A’ and B’) measured at a 30° offset from the anterior midline to capture subtle parietal-occipital asymmetries. The final CVAI represents the mean value derived from both standard and offset diagonal calculations, utilizing the shorter diagonal as the denominator to enhance sensitivity.)

## Statistical Analysis

Data were analyzed using SPSS (version 26.0). Continuous variables were expressed as mean ± standard deviation (SD). Given the small sample size, descriptive statistics were primarily utilized to illustrate trends in cranial growth and symmetry over time.

## Results

# Clinical Outcomes and Safety

The personalized PEEK cranioplasty was successfully performed in all five patients. The mean follow-up duration was 32 months (range, 16–60 months). No perioperative mortality or major surgical complications, such as intracranial hemorrhage or graft displacement, occurred. Throughout the long-term follow-up period, all implants remained clinically stable with no evidence of infection, skin breakdown, or implant exposure. All guardians expressed high satisfaction with the cosmetic restoration of the cranial contour.

## Morphological Quantitative Analysis (CVAI)

The quantitative assessment using 3D-CT data demonstrated a significant trend toward improved cranial symmetry. The mean preoperative CVAI was 4.19% ± 2.58%, which decreased to 2.17% ± 1.55% at the final follow-up.

Notably, in the youngest patient (Case 1, operated at 5 months of age), the CVAI showed a remarkable reduction from 6.57% (preoperative) to 0.75% (5-year follow-up), representing near-perfect normalization of the cranial vault despite the presence of a rigid implant. For patients who presented with mild preoperative asymmetry (CVAI < 3.5%), the cranial shape remained stable without progressive deformity during growth. No radiological signs of secondary craniosynostosis or restrictive growth patterns were observed in any of the longitudinal imaging studies. (Fig. 2)

## Discussion

This preliminary case series represents the first quantitative, longitudinal morphometric assessment of infants undergoing primary PEEK cranioplasty following the resection of cranial lesions. Our pivotal finding contradicts conventional clinical apprehension: at mid-term follow-up, the use of rigid, personalized PEEK implants demonstrated no radiological evidence of restricted cranial growth or progression of secondary asymmetry. On the contrary, existing asymmetries exhibited a trend toward normalization, while inherent symmetry was successfully preserved.

The most compelling observation was documented in our youngest patient (5 months old), whose cranial morphology achieved remarkable normalization over a five-year period. This observation challenges the reductionist view of alloplastic implants as static, growth-limiting "plates." We propose the "Sutural Compensatory Growth Hypothesis," a concept corroborated by our team's previous investigations [13]. In infancy, calvarial expansion is primarily driven by rapid brain development, which translates into mechanical force vectors acting upon patent sutures [9].

A precision-matched PEEK inlay may function as a stable, non-expansive "anatomical anchor" within this dynamic system. The surrounding native bone, interfaced with patent sutures, retains its osteogenic potential and appears capable of three-dimensional remodeling around the implant through differential sutural growth. This process accommodates the increasing intracranial volume and facilitates the restoration of global cranial contour. This conceptual framework aligns with clinical paradigms in craniosynostosis surgery, where strategic osteotomies allow for the redistribution of expansive growth forces [14]. Furthermore, our findings resonate with recent large-scale pediatric series reporting favorable PEEK outcomes, although those studies lacked a specific focus on the infantile cohort [15].

Regarding safety, our series demonstrated an excellent profile with zero implant-related complications, such as infection, migration, exposure, or foreign body reactions. This is particularly noteworthy in supraorbital reconstructions (Case 4), where the thin cutaneous envelope and irregular contours pose significant challenges. The successful outcome in such a vulnerable region may be attributed to the inlay design and the superior biocompatibility of PEEK [16]. This reliability stands in stark contrast to the prohibitively high failure rates of autologous bone grafts in infants, suggesting that PEEK may be the more robust alternative when autologous options are unviable or compromised [17].

## Study Limitations and Future Directions

Despite the favorable long-term outcomes observed, several limitations of this study must be acknowledged. First, the **sample size is relatively small (n = 5)**, which is inherent to the rarity of large-scale skull lesions requiring primary reconstruction in this specific age group. Consequently, the statistical power is insufficient to perform advanced inferential analyses. Second, while the 5-year follow-up provides crucial data on mid-term growth, the **lifelong evolution** of the PEEK-bone interface and the potential for late-onset complications remain to be fully elucidated.

Future research should focus on multi-center prospective trials with larger cohorts to validate these findings. Additionally, incorporating **advanced biomechanical modeling**, such as Finite Element Analysis (FEA), could provide deeper insights into how intracranial pressure is redistributed following rigid inlay cranioplasty in the developing pediatric skull.

## Conclusion

In conclusion, our longitudinal case series demonstrates that personalized PEEK cranioplasty is a safe and structurally superior strategy for cranial reconstruction in infants and toddlers. By utilizing a CAD/CAM-designed **inlay technique**, the procedure effectively provides immediate neuroprotection and restores aesthetic symmetry without impeding physiological cranial expansion. Our quantitative analysis using a **modified multi-vector CVAI** confirms that the "gap expansion" phenomenon and compensatory growth at patent sutures allow the pediatric cranium to accommodate rigid implants during the most dynamic phases of brain development. These findings suggest that the young age of a patient should not be considered an absolute contraindication for PEEK reconstruction, offering a viable solution to the high resorption rates associated with traditional autologous bone grafts.

## Declarations

**Declaration of Interest**

The authors declare that they have no known competing financial interests or personal relationships that could have appeared to influence the work reported in this paper.

All authors (Yanzhao Wang, Jie Gong, and Wei Qiu) have participated in the research and/or article preparation. The authors have no relevant financial or non-financial interests to disclose.

The authors declare that the research was conducted in the absence of any commercial or financial relationships that could be construed as a potential conflict of interest.

# Author Contribution

All authors (Yanzhao Wang, Jie Gong, and Wei Qiu) have participated in the research and/or article preparation. The authors have no relevant financial or non-financial interests to disclose.

## References


1. Bykowski, Michael R et al. "Pediatric Cranioplasty". Clinics in plastic surgery vol. 46, 2 (2019): 173-183.
2. Baek, Sang Oon et al. "Split Calvarial Bone Graft for Reconstruction of Skull Defect in Langerhans Cell Histiocytosis". The Journal of Craniofacial Surgery vol. 31, 6 (2020): e595-e597.
3. Amin, Md Rezaul et al. "Preoperative planning of craniectomy and reconstruction using three-dimension-printed cranioplasty for treatment of calvarial lesion". Surgical Neurology International Vol 15 (2024): 241.
4. Abdullah, Faliq et al. "Paediatric Langerhans Cell Histiocytosis: A 20-Year Single-Centre Retrospective Study of 35 Cases". Cureus vol. 17, 12 (2025): e99421.

5. Behbahani M, Rosenberg DM, et al. Cranioplasty in Infants Less Than 24 Months of Age: A Retrospective Case Review of Pitfalls, Outcomes, and Complications. World Neurosurg. 2019 Dec;132:e479-e486.
6. Verhoef, L. L. et al. "Calcium phosphate vs. autologous cranioplasty in a pediatric population". Journal of Cranio-Maxillo-Facial Surgery : official publication of the European Association for Cranio-Maxillo-Facial Surgery vol. 53, 9 (2025): 1481-1486.
7. Sikder, Prabaha et al. "A comprehensive review on the State of the Art in the research and development of poly-ether-ether-ketone (PEEK) biomaterial-based implants". Acta biomaterialia vol. 191, (2025): 29-52.
8. Frassanito, Paolo et al. "Cranial Repair in Children: Techniques, Materials, and Peculiar Issues". Advances and technical standards in neurosurgery vol. 49, (2024): 307-326.
9. Meyer-Marcotty P, Kunz F et al. Cranial growth in infants—A longitudinal three-dimensional analysis of the first months of life. J Craniomaxillofac Surg. 2018 Jun;46(6):987-993.
10. Frassanito, Paolo et al. "Cranial Repair in Children: Techniques, Materials, and Peculiar Issues". Advances and technical standards in neurosurgery vol. 49, (2024): 307-326.
11. Miyabayashi, Hiroshi et al. "Denominator of Cranial Vault Asymmetry Index: Choosing Between Longer and Shorter Diagonal Lengths". The Journal of craniofacial surgery vol. 34,4 (2023): e369-e372.
12. Callejas Pastor CA, Jung IY, et al. Two-Dimensional Image-Based Screening Tool for Infants with Positional Cranial Deformities: A Machine Learning Approach. Diagnostics (Basel). 2020 Jul 19;10(7):495.
13. Wang C, Yang C, et al. Gap Expansion Between Cranial Bone and Polyether Ether Ketone Implant in Cranioplasty of Pediatric Patients after Decompressive Craniectomy at Follow-up. Neurotrauma Rep. 2025 Aug 11;6(1):660-668.
14. Geoffroy M, François PM, Khonsari RH, Laporte S. Paediatric skull growth models: A systematic review of applications to normal skulls and craniosynostoses. J Stomatol Oral Maxillofac Surg. 2022 Oct;123(5):e533-e543.
15. Bi C,Wu H,Liu J, et al. Stability of cranial defect size following decompressive craniectomy for traumatic brain injury in the pediatric population: A retrospective study. Sci Rep. 2025;15(1):23365.
16. Maria Punchaka, Lawrance K,et al.Outcomes following polyetheretherketone (PEEK) cranioplasty:Systematic review and meta-analysis. Central neurocytoma Journal of Clinical Neuroscience,2017,(41):30–35.
17. Honigmann Philipp, Sharma Neha, et al. Patient-Specific Surgical Implants Made of 3D Printed PEEK: Material, Technology, and Scope of Surgical Application. Biomed Res Int,2018,2018:4520636.

# Table

**Table 1. Patient Characteristics and CVAI Outcomes**

| Case | Sex | Age at Surgery (months) | Diagnosis | Defect Location | Pre-op CVAI (%) | Follow-up (months) | Follow-up CVAI (%) | CVAI Change |
|---|---|---|---|---|---|---|---|---|
| 1 | M | 5 | GCRG | R Fronto-parietal | 6.57 (Moderate) | 60 | 0.75 (Symmetrical) | -5.82 |
| 2 | M | 17 | LCH | L Frontal | 2.77 (Symmetrical) | 36 | 2.89 (Symmetrical) | +0.12 |
| 3 | F | 12 | NF1 | R Fronto-temporal | 6.82 (Moderate) | 24 | 3.79 (Mild) | -3.03 |
| 4 | F | 19 | LCH | R Supraorbital | 1.97 (Symmetrical) | 16 | 1.95 (Symmetrical) | -0.02 |
| 5 | F | 12 | LCH | R Temporal | 2.83 (Symmetrical) | 48 | 1.46 (Symmetrical) | -1.37 |

*GCRG: Giant Cell Reparative Granuloma; LCH: Langerhans Cell Histiocytosis; NF1: Neurofibromatosis Type 1*

## Figures

**Figure 1: Schematic illustration of the modified CVAI measurement**

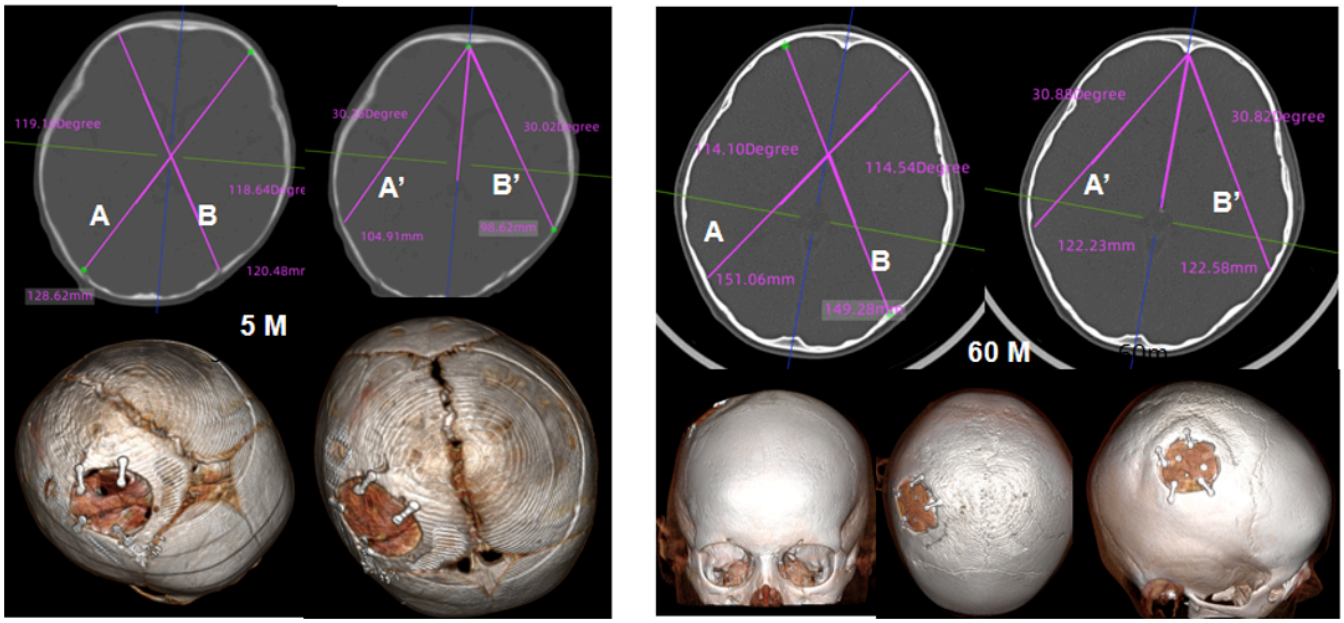


(The symmetry was assessed using a multi-vector approach on the axial slice of maximum cranial circumference. (A) Standard diagonals (A and B) measured between the frontozygomatic suture and the contralateral eurion. (B) Enhanced paracentral vectors (A' and B') measured at a 30° offset from the anterior midline to capture subtle parietal-occipital asymmetries. The final CVAI represents the mean value derived from both standard and offset diagonal calculations, utilizing the shorter diagonal as the denominator to enhance sensitivity..)

**Figure 1**

See image above for figure legend.

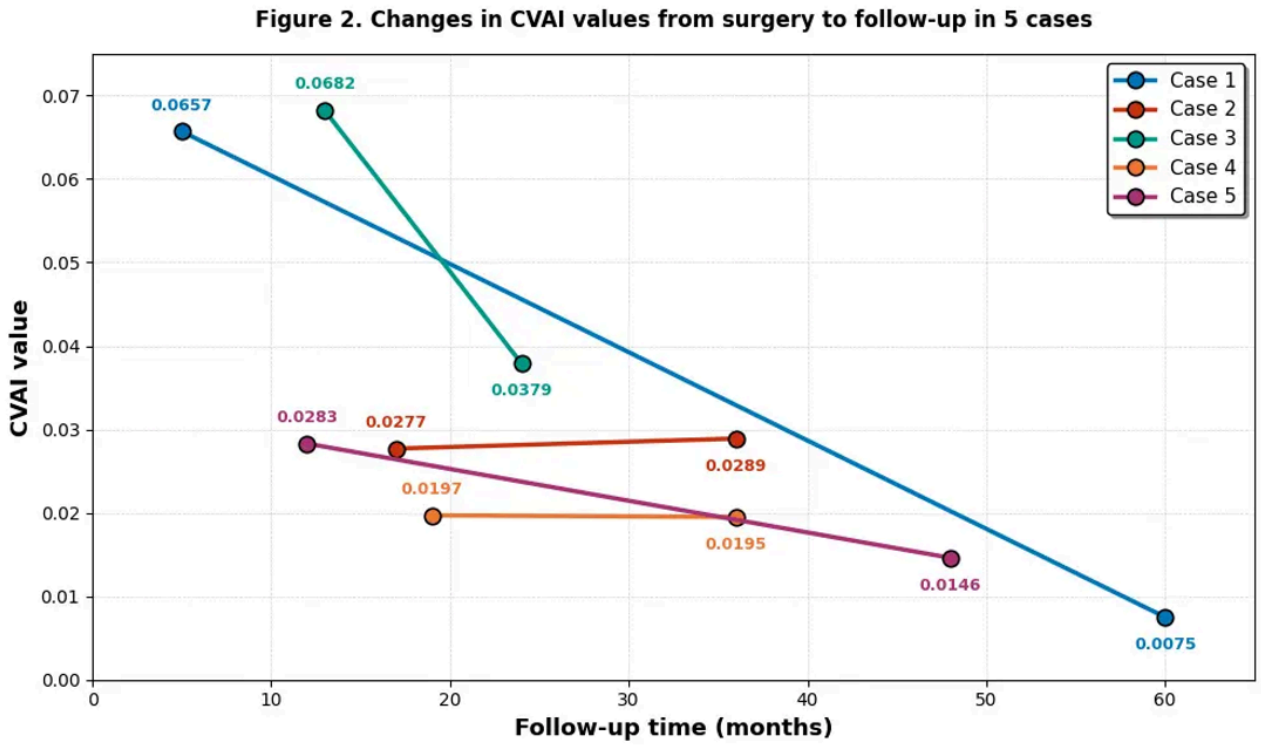


(Distribution and longitudinal trends of Mean Modified CVAI values. The scatter plot illustrates the progressive reduction in cranial asymmetry for all patients (n=5). The most significant improvement was observed in patients with higher baseline asymmetry, while those with initially low CVAI maintained stable cranial contours throughout the follow-up period.)

## Figure 2

See image above for figure legend.

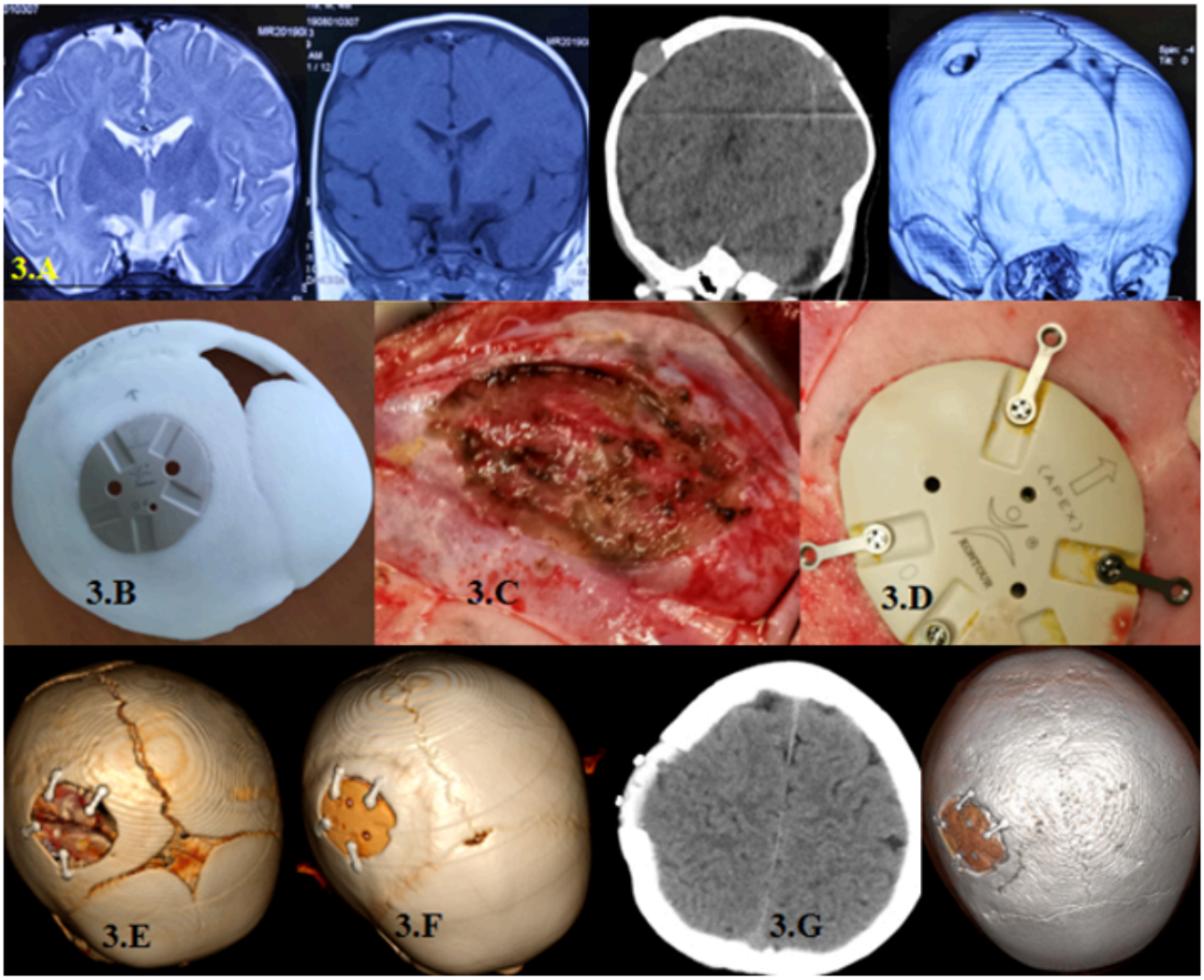


**Figure 3**

Representative Case of Cranial Morphological Normalization (Case 1).

A 5-month-old male presented with a 10-day history of a palpable, firm, and fixed mass (approx. 2 × 2.5 cm) in the right frontoparietal region.(A) Preoperative Imaging: Axial CT and MRI reveal an aggressive cranial lesion in the right frontoparietal bone with significant calvarial destruction.(B) Surgical Planning: Preoperative 3D-printed skull model and the customized PEEK implant designed via CAD/CAM technology.(C) Intraoperative Findings: The lesion was found to be infiltrating the periosteum; a total resection was performed.(D) Reconstruction: Rigid fixation of the personalized PEEK inlay implant using a low-profile micro-plate and screw system.(E–G) Longitudinal Follow-up: Postoperative CT scans at 1 month (E), 1 year (F), and 5 years (G).Clinical Progress: The 5-year follow-up imaging demonstrates remarkable cranial growth and remodeling. Despite the rigid nature of the implant, the overall cranial symmetry significantly improved, with the Cranial Vault Asymmetry Index (CVAI) decreasing from a preoperative 6.57% to 0.75% at the final follow-up, representing near-perfect normalization. Pathological Diagnosis: Giant cell reparative granuloma (GCRG).