Research Square

Preprints are preliminary reports that have not undergone peer review.
They should not be considered conclusive, used to inform clinical practice,
or referenced by the media as validated information.

Comparative Study on the Intestinal Health Status of Wild and Cultured African Cat Fish (Clarias Gariepinus)

Kingsley Unekwu Ogbe

ogbekingsley90@gmail.com

Prince Abubakar Audu University Anyigba

Victoria Sokolayame Emmanuel

Confluence University of Science and Technology Osara

Peace Onas Somdare

Federal University Lokoja

Haulatu Umaru Wintola

Prince Abubakar Audu University Anyigba

Onyeja Iye Omada

Kogi State College of Education Technical Mopa

Research Article

Keywords: Intestinal health, Captured, culture, Clarias gariepinus

Posted Date: June 1st, 2026

DOI: https://doi.org/10.21203/rs.3.rs-9168705/v1

License: This work is licensed under a Creative Commons Attribution 4.0 International License.
Read Full License

Additional Declarations: No competing interests reported.

Abstract

Background

The aim of this study was to determine and compare the intestinal health status of *Clarias gariepinus* gotten from the wild and from the pond through histological, biochemical and parasitological studies. The intestine of 15 wild and pond cultured *Clarias gariepinus* was used for the study, with a mean weight of 300g.

Results

The cultured *Clarias gariepinus* had a higher amylase (U/mg) and lipase (U/g) of 295.65 ± 57.44, and 54.20 ± 1221 as compared with wild *Clarias gariepinus* of 271.95 ± 66.00 and 46.60 ± 19.13, they was no significant difference ($p > 0.05$) in both the amylase and lipase between the wild and cultured Fish. The wild *Clarias gariepinus* had higher antioxidant enzyme activities, with significant difference ($p < 0.05$) in catalase and Thymidine phosphorylase, while significant difference was not recorded for Supoxide dismtase, and Glthathione peroxidase. The intestinal morphology of the cultured wild *Clarias gariepinus* shows prominent mucosal with minimal inflammation of the sudmucosa, with no abnormalities seen, while the intestinal morphology of the cultured fish shows erosion of mucosal granular lining with intense inflammation of the submucosal. The parasitological study shows the presence of both nematode and Cestoda, while the captured *Clarias gariepnus* shows the presence of Nematode, Trematode, Protozoan, and Cestoda

Conclusion

the wild *Clarias gariepinus* shows a higher intestinal health status by higher antioxidant capacity, proper intestinal histology, with low parasitic infestations compared to the cultured *Clarias gariepinus*. They were significant difference ($p < 0.05$) in the intestinal health status between the wild and cultured *Clarias gariepinus*. These reveal the needs for improvement of sustainable aqua-cultural practices among fish farmers for healthy fish production

Introduction

The high demand for fish has been on an increasing rate due to the rapid increase in human population across the globe, as a result wild caught fish could not only meet the increasing demand for fish. Fish culture through artificial means has become the best alternative in meeting the demand for fish and fish products [1]. However they have been increase rate in fish disease which has resulted in poor fish production through aquaculture and this may be as result of poor aqua cultural practices such as feed, feeding rate, feeding time and poor water quality [2]. Fish intestinal health plays an important role in the in nutrient assimilations which result in growth, development and immune functions. A healthy intestines

enables fish to sufficiently digest food, absorbed vital nutrients and maintain a robust essential nutrient, and can also act as a barrier against pathogens leading to good fish health and vitality in fish populations especially in in fish culture setting, which can stress the digestive system [3]. A healthy gut contains helpful bacterial that aid in digestions, produce essential vitamins and hinder the growth of harmful bacteria. Intestinal wall can also act as a barrier to hinder the entry of harmful substances and pathogens into the blood stream [4].

In contrast to cultured fish, wild fish inhabit environment with high dissolved oxygen levels, low densities, and low levels of ammonia and nitrogen; however, high levels of heavy metals in the wild may also be harmful to intestinal health. Although both a lower and an excessive intake can results in slower growth rates, wild fish have a richer diet compositions and the food they eat may contain particular nutrients that are easily digested to influence intestinal health [5].

Comparative studies of cultured and captured fishery show measurable differences in intestinal structure, disease resistance, which is an important implication for health and aquaculture.

Results

Intestina digestive enzymes and anti oxidant parameters

As shown in Table 1, pond cultured *Clarias gariepinus* had a higher activities of both amylase and lipase ($P < 0.05$). There was no significant difference ($P < 0.05$), in the intestinal digestive enzymes of both the culture and wild *C. gariepinus*.

Table 1
Intestinal Digestive enzymes

Parameters	Wild	Cultured	P- value
Amylase (U/mg prot)	271.95 ± 66.0a	295.65 ± 57.44a	0.562
Lipase(U/mg prot)	46.60 ± 19.12a	54.13 ± 12.17a	0.479

Value are presented as Mean and S.D, Value with different letter are significantly different at $P < 0.05$

Intestinal antioxidants parameters

As shown in Table 2, the wild *Clarias gariepinus* had higher activities of SOD, CPX. CAT and TP. They were a significant difference in the CAT and TP value of the wild and cultured *C. gariepinus*, while significant difference was not observed in SOD and CPX.

Table 2
Intestinal antioxidant enzymes

Parameters	Wild	Cultured	P- value
SOD (U/mg prot)	92.66 ± 91.85a	61.98 ± 40.52a	0.514
GPx (Prot	123.00 ± 23.39a	105.94 ± 27.95a	0.318
CAT (U/mg prot)	564.71 ± 135.93a	251.41 ± 159.69b	0.002
TP (g/dl)	8.30 ± 0.46a	7.08 ± 0.86b	0.000

Parasites species in wild and cultured C. gariepinus.

As shown in Table 3, **the parasites species identifid in cultured C. gariepinus are** *Camallanus sp, Paracamallanus cyathopharynx, Procamallanus laeviconchus, Contracaecum spp, Capillaria spp* and *Polyonchobothrium clarias*, while the following species of parasites where seen in the intestine of wild *C. gariepinus; Orientocreadium batrachoides, Protoopalina sp, Camallanus sp, Paracamallanus cyathopharynx, Procamallanus laeviconchus, Contracaecum spp, Capillaria spp* and *Polyonchobothrium clarias*

Table 3
Parasites species in wild and cultured *C. gariepinus*

S/N	Cultured Clarias	Captured Clarias
1	*Camallanus sp*	*Procamallanus laeviconchus*
2	*Paracamallanus cyathopharynx*	*Capillaria spp*
3	*Procamallanus laeviconchus*	*Orientocreadium batrachoides*
4	*Contracaecum spp*	*Protoopalina sp*
5	*Capillaria spp*	*Paracamallanus cyathopharynx*
6	*Polyonchobothrium clarias*	*Polyonchobothrium clarias*
7		*Contracaecum spp*
8		*Camallanus spp*

Parasite abundance in wild and cultured C.gariepinus

As shown in Figs. 1,2 and 3 below, *Camallanus sp* had the highest abundance in cultured C.gariepinus of 53.33%, followed by *Procamallanus laeviconchus* of 20%. The highest parasite abundance was seen in *Procamallanus laeviconchus* and *Polyonchobothrium clarias* at 20% respectively. for both wild and cultured C. gariepinus, *Camallanus sp* and *Procamallanus laeviconchus* had the highest abundance of 30% and 20% respectively.

Intestinal mophology

Discussion

The intestinal digestive enzymes show higher activities of both amylase and lipase in cultured *Clarias gariepinus*, this may be as a result of higher concentration of carbohydrate and fat in the compounded feed. This result is disagree with Hang *et al*. [6] ,wang et al. [7] which showed that wild rice field eel had higher trypsin and lipase activities, this agreed with Wu et al. [8] with show higher amylase activity in cultured fish.

The wild *C. gariepinus* had higher activities of Intestinal antioxidants parameters, of SOD, GPx. CAT and TP. Which indicate stronger antioxidant defense and less damage in the wild fish Hang *et al.* [6] The low anti oxidative activities in cultured fish may be as a result of diet formulation and culture conditions [9]

Across species and environment both wild and cultured fish commonly harbor intestinal parasites. Presence of parasite in fish largely depend on environment and management. In this study farmed *Clarias gariepinus* had higher prevalence and abundance of parasites, Omeji, et al. [10] which may be as a result of poor aquaculture practices such as water management, over feeding and poor bio security and hygiene in the culture environment, this is in. this result disagreed with Aliyu and Abubakar [11] who concluded that wild *Clarias gariepinus* in River Nasarawa, Nigeria, had a higher prevalence of intestinal parasites, which may possibly linked to environmental pollution as a result of anthropogenic activities.

the intestinal tissue morphology of the Cultured *Clarias gariepinus* shows erosion of mucosal glandular lining with intense inflammation of submucosa, wild fish generally exhibbit good intestinal mophological structure. Previous work shows that cultured fish have reduced villu circumfrence/ width and thinner or damaged muscle layers, indicationg decreased absortive surface and weaker barrier function. [6, 12, 13]

Conclusion

Based on the findings of this study, it can be concluded that cultured *Clarias gariepinus* exhibited improved digestive capacity but a compromised antioxidant defense when compared with wild counterparts, which demonstrated greater physiological resilience, better-preserved intestinal structure, and enhanced adaptive capacity, while differences in parasite prevalence between the two groups further reflected the influence of environmental conditions, collectively indicating that diet, environment, and management practices play critical roles in shaping fish gut health emphasizing the need for improved aquaculture conditions.

Materials and Methods

Sample collection

A total number of 30 *Clarias gariepinus* were used for this experiment, with an average body weight of 4.2 ± 3.8 g and 45.3 ± 5.1g, the wild fish were obtained from Kpata river in Lokoja Kogi State, Nigeria, while the cultured fish was obtain from Sokvikia farms located at Area 4 Zango City Lokoja, Kogi State. The fish was dissected in an aseptic setting. The fish were anaesthetized on ice and sacrificed using percussive method before dissection for organ resection. The foregut and hindgut were removed with a sterilized scalpel. A portion of the foregut was removed and frozen at -20^{0}C for analysis of intestinal parameters, while the remaining of the foregut was gathered and preserved in Bouin's solution to examine tissue morphology. Additionally, each hindgut was examined under a microscope to look for intestinal parasites

Analysis of antioxidant parameters and digestive enzyme
Evaluation of Enzymatic Activity

The oxidative parameters Catalase (CAT), Superoxide Dismutase (SOD), Glutathione peroxidae GPx and Total Phenolic content (TP) were analyzed using Enzyme linked immunosorbent assay (ELISA). The ELISA was performed following the manufacturer's instructions with minor adjustments. All reagents were prepared in advance, and both standard and samples were analysed in duplicate.

Intestinal Tissue Morphology

Following at least 48 hours of fixing in Bouin's solution, the foregut samples were dehydrated with ethanol, made transparent with xylene, embedded in paraffin, sectioned (8mm), and stained with hematoxylin–eosin (H&E). The intestinal morphology parameters were observed by taking pictures of the sections using an optical microscope (Nikon YS100 micrographic system) [14]

Intestinal Parasitic Examination

Dissecting scissors were used to cut the fish ventral side from the anal opening to the lower jaw, revealing the body cavity and the majority of its internal organs. The intestine was kept apart and separate sample plate with 0.9% saline solution. For sedimentation and flotation, the content of the intestines were cleaned in saline solution. A drop of the residue was placed on slide, the wet mount was inspected for parasites with the aid of microscope (Olympus CX40) using the ×10 and ×40 objectives for various parasites. The parasites were identified using a standard text [15, 16]

Statistical Analysis

The mean and standard deviation were used to express the experimental results. Levene's test for quality of variance was applied to all data using SPSS 22.0 software, and independent sample t-test were utilised to identify significant difference at $p < 0.05$

Declarations

This research was carried out in accordance with international council for laboratory animal science ethical guideline for researchers.

Ethical Approval: The experimental protocols were approved by the College of Heath Science Research Ethical committee (CHSREC) Prince Abubakar Audu UniversityAnyigba, Kogi State, Nigeria (CREC-CHS/PAAU/2024/0024)

Consent for Publication: not applicable

Availability of data and materials: The datasets used and /or analysed during the current study are available from the corresponding author on reasonable request for protection of intellectual property

Competitive interests: not applicable

Funding: self funding

Authors' contributions

OG: designed the experimental design and laboratory analysis

VS: Performed histological examination of the fish intestine and a man contribution in drafting the manuscript

SP: analysis of data, removal of the fish intestine for laboratory examination

WH: statistical analysis of data and drafting of manuscript abstract

OO: designed the experimental design and laboratory analysis

All authors read and approved the final manuscript

Acknowledgement: not applicable

References

1. Naylor R, Kishore A, Sumaila U, Issifu, Hunter B, Belton B, Bush S, Cao L, Gelcich S, Gephart J, Golden C, Jonell M, Koehn J, Little D, Thilsted S, Tigchelaar M, Crona B. Blue food demand across geographic and temporal scales. Nat Commun. 2021;12. 10.1038/s41467-021-25516-4.
2. Walker P, Winton J. Emerging viral disease of fish and shrimp. Vet Res. 2010;41. 10.1051/vetres/2010022.
3. Luan Y, Li M, Zhou W, Yao Y, Yang Y, Zhang Z, Ringo E, Olsen R, Clarke J, Xie S, Mai K, Ran C, Zhou Z. The Fish microbiota: research progress and potential applications. Engineering. 2023. 10.1016/j.eng.2022.12.011.

4. Kanika N, Liaqat N, Chen H, Ke J, Lu G, Wang J, Wang C. Fish gut microbiome and its application in aquaculture and biological conservation. Frontiers in Microbiology. 2025; 15.10.3389/fmicb.2024.1521048.
5. Fuentes A, Fernández-Segovia I, Serra JA, Barat JM. Comparison of wild and cultured sea bass (Dicentrarchus labrax) quality. Food Chem 2010.119:1514–8.
6. Hang H, Yuan Q, Rahman M, Lv W, Huang W, Hu W, Zhou W. Comparative studies on the intestinal health of wild and cultured rice Eel (Monopterus albus). Front Immunol. 2024;15. 10.3389/fimmu.2024.1411544.
7. Wang J, Li S, Sun Z, Lu C, Zhao R, Liu T, Wang D, Zheng X. Comparative study of immune responses and intestinal microbiota in the gut – liver axis between wild and farmed pike perch (Sander Lucioperca). Front Immunol. 2024. 10.3389/fimmu.2024.1473686.
8. Wu B, Lei H, Zhen J, Zhao L, Song B, Zeng Y. Comparative research on intestinal functions of wild and cultured Hemibarbus maculates in Jialing River. Animals: Open Access J MDPI. 2023;13. 10.3390/ANI13020189.
9. Kocabas M, Kutluyer F, Benzer F, Erisir M. Assessment of Biomarkers of oxidative stress and antioxidant in wild and farmed coruh trout (Salmo coruhensis) Spermatozoa. Turk Tarim ve Doga Bilimleri Dergisi. 2019; 10.30910/turkjans.557108
10. Omeji S, Adadu M, Kolndadacha O. Parasitic incidence in cultured and wild Nile tilapia (Oreochromis niloticus) in Makurdi, Benue State, Nigeria. Global J fisheries Sci. 2022. 10.31248/gjfs2022.036.
11. Aliyu A, Abubakar B. Prevalence of gastrointestinal parasites of African Ctfish (Clarias gariepinus) from Nasarawa, Nasarawa State, Nigeria. Sahel journal of Life Sciences FUDMA. 2024.
12. Deng Q, Feng Z, Xiang J, Wu H, Yang X, Zhang Z, Li C, Cheng X, Xie M, Li S. Comparative analysis of intestinal morphology and gut microbiota of spinibarbus sinensis under different aquaculture systems, Biology.2024; 13. 10.3390/biology13110869
13. Wang Q, Ruan Z, Wang Y, Zhang Y, Chai X. Comparison of growth performance, oxidative stress, and intestinal microbiota of rockfish (sebastiscus marmoratus) in different culture modes. Fish Physiol Biochem. 2025;51. 10.1007/s10695-025-01450-w.
14. Shi Y, Zhong L, Liu Y, Zhang J, Lv Z, Li Y. Effects of dietary and rographolide levels on growth performance, antioxidant capacity, intestinal immune function and microbioma of rice field eel (Monopterus albus). Animals. 2020;10:17–44.
15. Ajala OO, Fawole OO. Multiple infections of Helminths in the alimentary system of Clarias gariepinus (Burchell, 1822) in a tropical reservoir. Int J Fisheries Aquaculture. 2014;6(6):62–70.
16. Kawe E, Ibrahim M, Oladejo O. (2016). Endoparasitic infections in African catfish (Clarias gariepinus) from Nigerian rivers. Journal of Aquatic Parasitology. 2016; 8(2):45–52.

Plates

Plates 1 and 2 are available in the Supplementary Files section

Figures

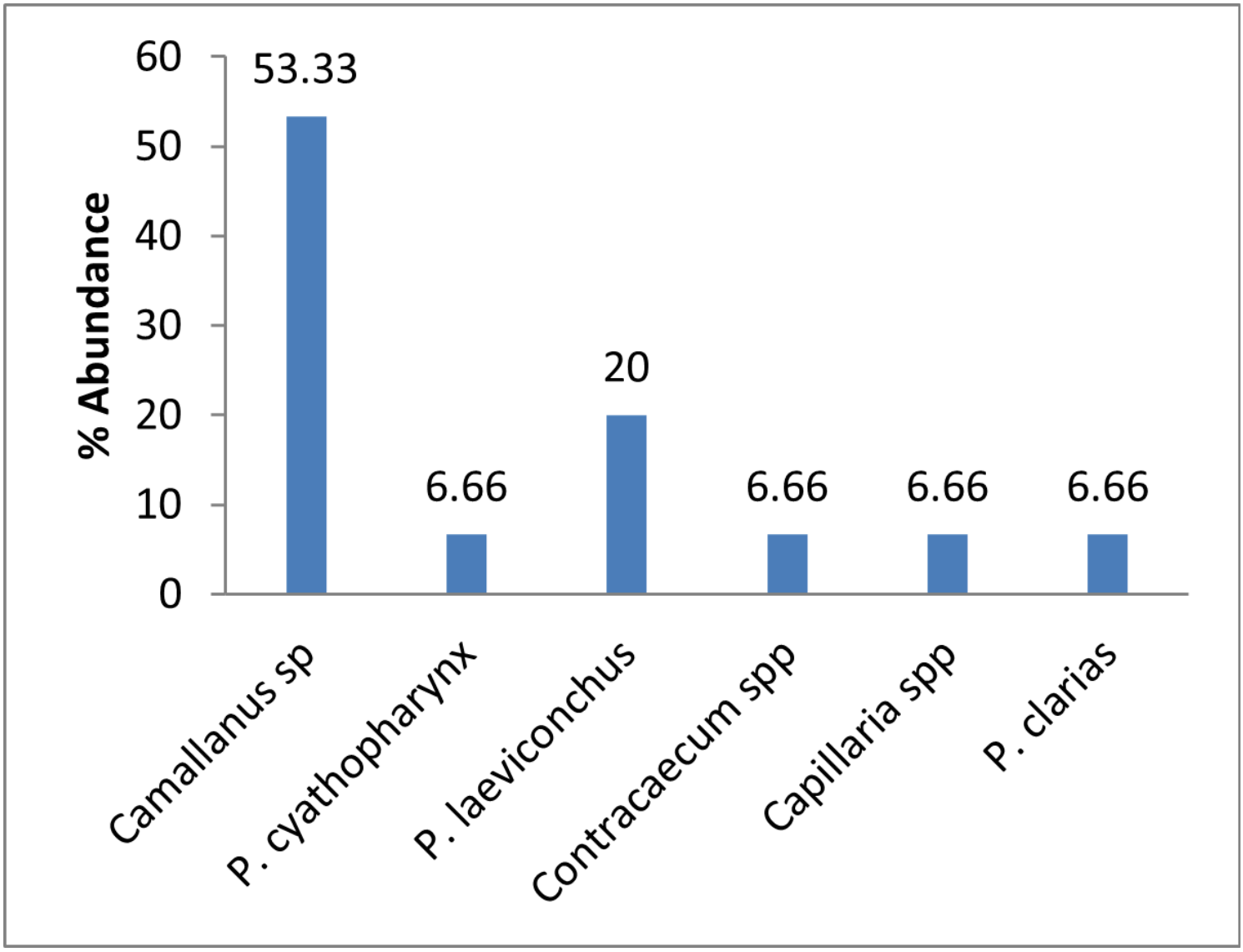

Figure 1

Parasite Abundance of Cultured *Clarias gariepinus*

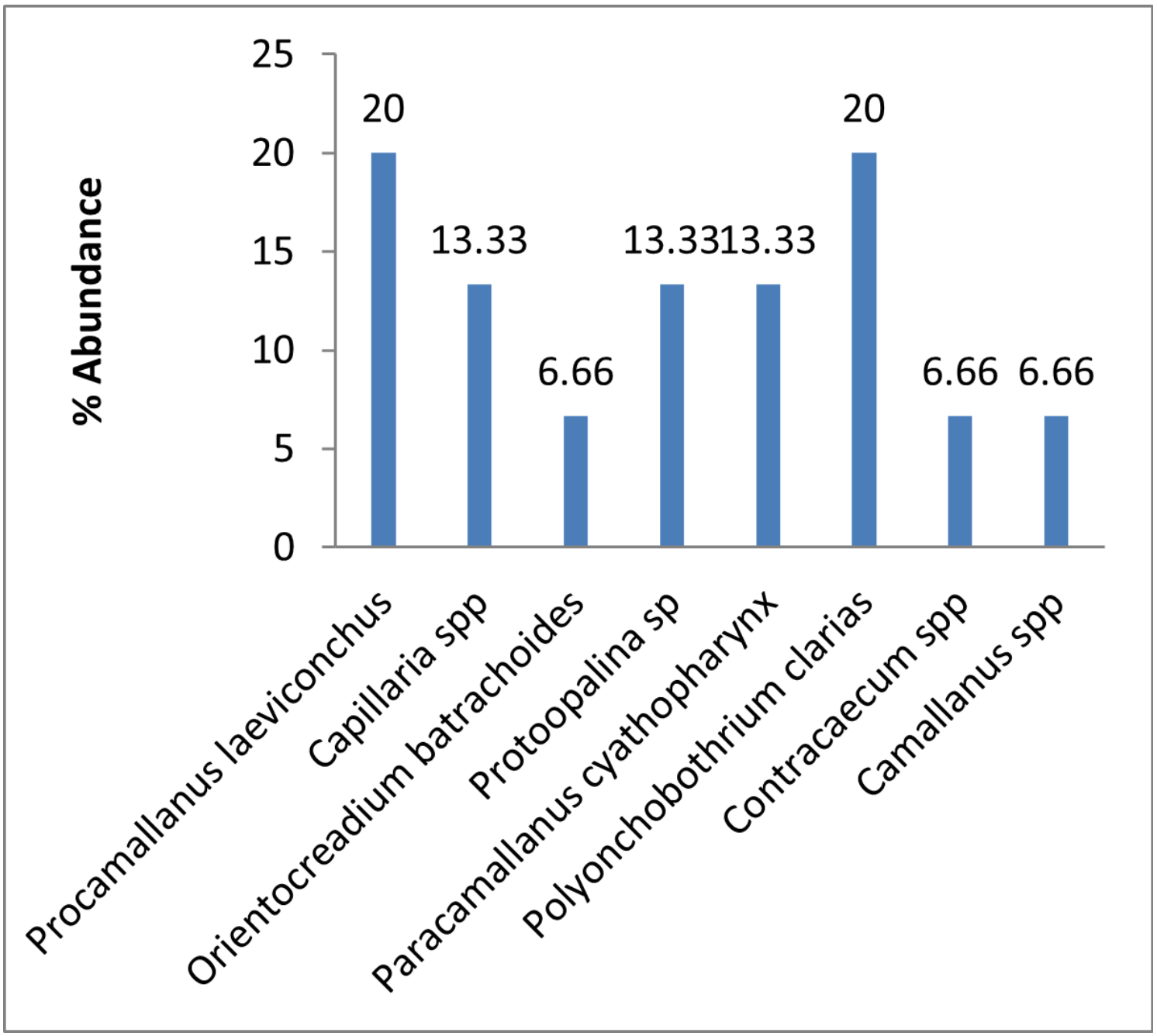

Figure 2

Parasitic Abundance of captured *Clarias gariepinus*

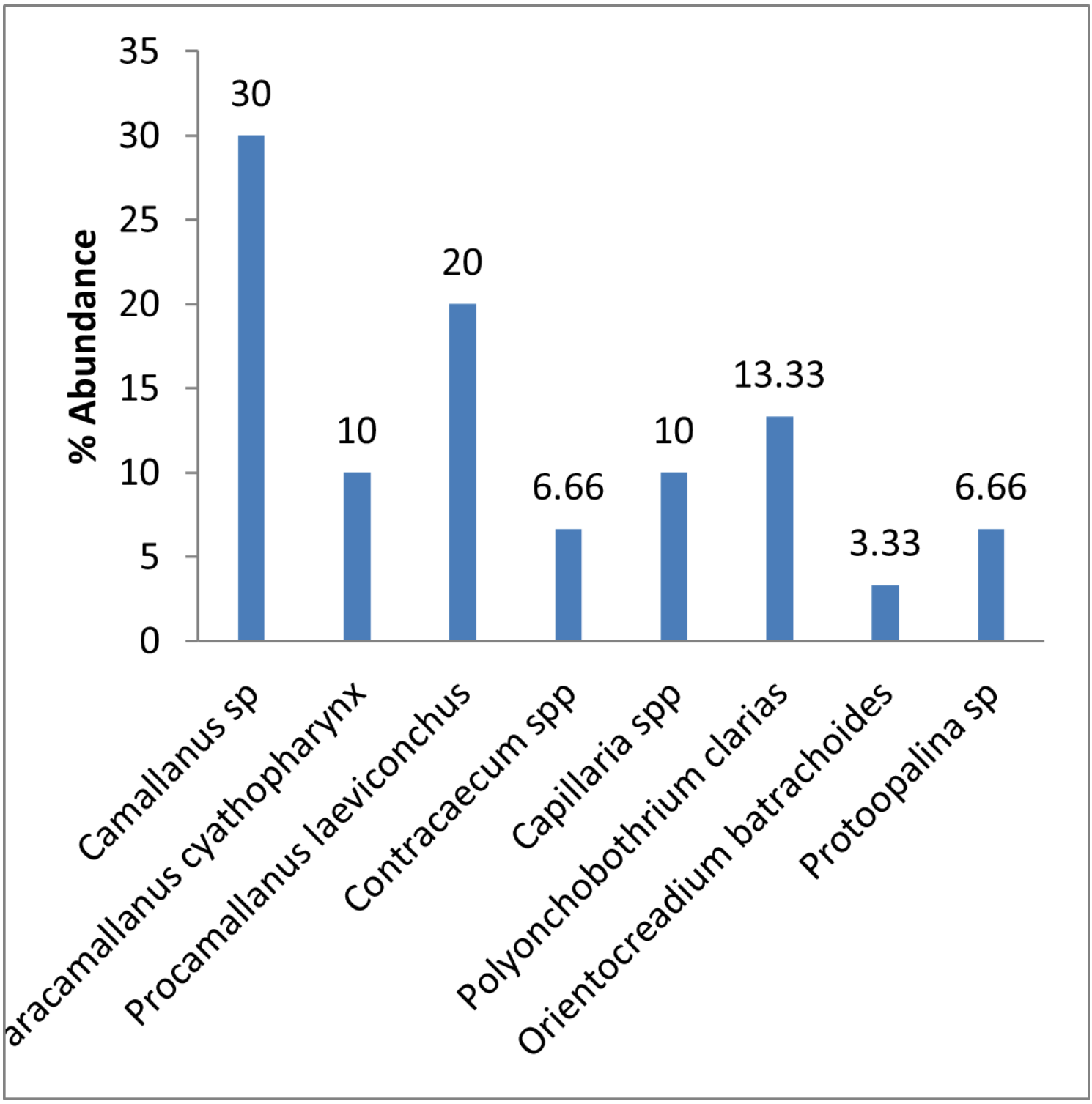

Figure 3

parasitic species abundances for cultured and captured *Clarias gariepinus*

Supplementary Files

This is a list of supplementary files associated with this preprint. Click to download.

- Plate1.png
- Plate2.png