Research Square

Preprints are preliminary reports that have not undergone peer review.
They should not be considered conclusive, used to inform clinical practice,
or referenced by the media as validated information.

Anaesthetic Challenges in the Perioperative Care of Ischiopagus Twins with Shared Circulation During Kidney Repositioning; a Case Report

Nethmi Munasinghe,
Teaching Hospital Peradeniya
Sayomi Warnakula
Teaching Hospital Peradeniya
Ashani Ratnayake
University of Peradeniya
Mathula Hettiarcahchi
University of Peradeniya
Sanduni Rupasinghe
sandurupesinghe@gmail.com

University of Peradeniya

Case Report

Keywords: Ischiophagus twins, Kidney Repositioning, Shared Circulation

Posted Date: March 8th, 2026

DOI: https://doi.org/10.21203/rs.3.rs-8960346/v1

License: This work is licensed under a Creative Commons Attribution 4.0 International License.
Read Full License

Additional Declarations: No competing interests reported.

Abstract

Background

Conjoined twins are rare, occurring in approximately 1 in 200,000 live births. Ischiopagus twins represent a small subset and pose significant anaesthetic challenges, particularly when vital organs and vascular structures are shared.

Case presentation

We report the anaesthetic management of three-year-old ischiopagus twins weighing 17 kg, who shared the bladder, rectum, urethra, and a single kidney supplied by an aberrant arterial connection between both aortae. Preoperative imaging guided surgical planning. Anaesthesia was induced simultaneously using inhalational agents due to shared circulation, followed by individual endotracheal intubation. Separate anaesthesia workstations and teams were assigned to each child. Anaesthesia was maintained with isoflurane and target-controlled remifentanil infusion. During ligation of the aberrant vessel, Twin 1 developed haemodynamic instability, managed with fluid resuscitation, fresh frozen plasma, and noradrenaline. Intraoperative monitoring relied on frequent venous blood gas analysis. Both children were transferred to intensive care and successfully weaned from vasopressor support within 12 hours.

Conclusion

This case highlights the importance of meticulous planning, multidisciplinary coordination, and vigilant intraoperative management when caring for conjoined twins with shared circulation.

Introduction

Conjoined twins are a rare condition, occurring in 1:200,000 live births. Ischiopagus twins, accounting for 6–11% of them, present unique challenges in anaesthesia, requiring meticulous planning and multidisciplinary approach(1). They are monozygotic, monochorionic twins who arise from a single fertilised ovum and develop with a shared placenta.

Conjoined twins are classified based on the area where their bodies are joined. The term *“pagus”* means fixed. They are broadly grouped into symmetrical twins, who are similar in size, and asymmetrical twins, where one twin is smaller and dependent on the other. Symmetrical conjoined twins may be joined at different regions of the body. These include the chest (*thoracopagus* or *xiphopagus*), often involving the heart or liver; the abdomen (*omphalopagus*), usually sharing the liver and gastrointestinal tract; the sacral region (*pygopagus*), involving the pelvis and lower nervous system; the head (*craniopagus*), with shared brain structures or blood vessels; and the pelvis (*ischiopagus*), commonly sharing the urogenital system and rectum. Ischiopagus twins may have four normal lower limbs or three limbs, with one fused and underdeveloped, sometimes associated with an omphalocele(2).

Anaesthetic care during separation surgery for conjoined twins is complex. Two babies must be managed at the same time, often with shared blood circulation. Other congenital abnormalities may also be present. The paediatric age group adds further challenges. Surgery is usually long and may involve major blood loss. Maintaining body temperature can be difficult. Careful planning, preparation, and team rehearsal are essential for safe management (3).

We aim to describe our anaesthetic approach to the surgical repositioning of a shared kidney in ischiopagus twins. Similar to previously reported cases, the twins were joined at the pelvic region; however, this case was further complicated by the presence of a shared kidney and aberrant vascular anatomy. These anatomical variations added significant complexity to perioperative management and required careful planning and intraoperative adaptation.

Case Description

Three-year-old Ischiopagus twins weighing 17kg shared a bladder, rectum, and urethra. Twin 2 (T2) had one Kidney, while the other was shared. (Fig. <link rid="fig1">1</link>,1). An aberrant vessel connecting both aortas supplied the shared kidney. (Fig. 1,2). The Surgery repositioned the kidney to Twin1 (T1).

Preoperative planning involved detailed contrast-enhanced imaging to define shared organs and vascular anatomy. Multidisciplinary discussions were conducted with paediatric surgeons, anaesthesiologists, intensivists, and nursing teams to plan positioning, airway management, vascular access, and postoperative care.

The operating room was prepared with separate anaesthesia machines and dedicated personnel for each twin. General anaesthesia was induced simultaneously with sevoflurane, followed by individual intubation due to shared circulation. Central venous lines were inserted to support haemodynamic monitoring and fluid management. Standard monitoring included electrocardiography, invasive arterial pressure, pulse oximetry, capnography, temperature monitoring, and urine output measurement. Active warming measures were used throughout the procedure to maintain normothermia and reduce the risk of hypothermia. Positioning was challenging, with flexed lower limbs covered to allow surgical access. (Fig. 1,3)

Anaesthesia was maintained with Isoflurane and TCI Remifentanil.

Hemodynamics were managed to prevent hypovolemia and autotransfusion, but T1 became unstable after aberrant arterial clamping, requiring fluid resuscitation, FFP, and Noradrenaline. Monitoring urine output was challenging during the 7-hour surgery, so perfusion was guided by frequent VBG analysis. Both were deeply extubated to prevent asynchronous recovery. (Fig. 1,2).

They were then transferred intubated to the paediatric intensive care unit for close monitoring. Once haemodynamically stable, both twins were successfully extubated. Noradrenaline support was discontinued within 12 hours. Renal function and urine output remained satisfactory throughout the

postoperative period. Pain control was managed using paracetamol and local wound infiltration catheter, avoiding opioids to support early recovery and reduce respiratory compromise.

Discussion

Anaesthetic management of conjoined twins with shared circulation is complicated. It requires deliberate modifications to standard practice. Whether the aim is sepration of the twins or not, evidence shows that multidisciplinary management, duplicate monitoring and expecting physiological variations is essential (4).

The possibility of cross circulation is key concern for anaesthetists. This can lead to unpredictable drug distribution and delayed or exaggerated responses if agents are administered sequentially However simultaneous inhalational induction has proven successful (2). In our case, this approach allowed controlled induction and stable airway management in both children.

Managing Blood loss, fluids, and normothermia is difficult but crucial. Careful titration of fluids and blood products is essential, as even small volume changes may result in significant haemodynamic instability (2, 5). Cardiovascular instability after ligation of the aberrant artery may occur due to uneven blood flow, even when both hearts are structurally normal. This is likely caused by sudden changes in preload and systemic vascular resistance. The rapid weaning from vasopressors suggests early adaptation to separated circulation.

Assessing end-organ perfusion was challenging because urine output could not be reliably monitored during the prolonged procedure. Serial venous blood gas analysis has shown to provide useful real-time information on acid–base balance and tissue perfusion (6). These measurements supported timely and informed haemodynamic interventions. This experience shows the importance of adjusting monitoring methods when standard measures are not available or reliable.

Transport and positioning pose significant challenges and evidence regarding this were limited. The twins share body structures and have limited mobility. Routine movements such as transfer from ward to operating room, positioning on the operating table, and intraoperative repositioning are inherently complex. This carry risks of dislodging monitors, airway devices, or vascular access. Each child must be stabilised with secured airways, normothermia, and adequate fluid balance before any movement (2).

Postoperative care was mainly focused on maintaining haemodynamic stability, providing effective pain relief, and monitoring for early signs of organ dysfunction. Both children were closely monitored in a paediatric intensive care unit. Continuous intensive care monitoring is recommended after complex procedures such as this, as it allows early detection and treatment of complications and helps guide fluid, haemodynamic, and analgesic management (2).

This case highlights the importance of careful preparation, flexibility, and teamwork when managing rare and complex congenital conditions.

Conclusion

Conjoined twins create complex anaesthetic challenges, especially in cases of shared circulation. This case shows the importance of adapting anaesthetic care to suit each child's physiology. Anticipating haemodynamic instability and planning for limited monitoring are essential. Careful planning, clear communication, and close teamwork throughout the perioperative period are needed for successful outcomes.

Declarations

Ethics approval and consent to participate

Ethical approval was not required for this case report as per institutional policy. Written informed consent for clinical management was obtained from the patient's legal guardians.

Consent for publication

Written informed consent for publication of clinical details and images was obtained from the patient's legal guardians. A copy of the written consent is available for review by the Editor of this journal.

Availability of data and materials

All data generated or analysed during this study are included in this published article. No additional datasets were generated.

Competing interests

The authors declare that they have no competing interests.

Funding

No funding was received for this study.

Authors' contributions

NM contributed to the conceptualization of the case report, primary anaesthetic management of the patient, overall clinical supervision, and preparation of the original manuscript draft. SW contributed to the literature review and revision of the manuscript for important intellectual content. AR contributed to critical revision of the manuscript, perioperativepatient management, academic supervision, and final

approval of the version to be published. MH contributed to surgical coordination, data collection, preparation of figures, and assistance with manuscript drafting. SR contributed to the literature review, editing, and refinement of the manuscript according to journal requirements.

All authors read and approved the final manuscript.

Acknowledgements

None.

Clinical trial number

Not applicable

References

1. Ismiarto YD, et al. Surgical Correction of Ischiopagus Tripus Conjoined Twins with Fused Pelvis: Enhancing Quality of Life through Orthopedic Intervention. Am J Case Rep. 2024;25:e942126–1.
2. OrphanAnesthesia. *Anaesthesia recommendations for Conjoined twins* [Internet]. OrphanAnesthesia; c2016 [cited 2025 Dec 29]. Available from: https://www.orphananesthesia.eu/rare-diseases/published-guidelines/conjoined-twins/279-conjoined-twins/file.html
3. Kaniyil S, Pavithran P, Mubarak KK, Mohamed T. Anaesthetic challenges in conjoined twins' separation surgery. Indian J Anaesth. 2016;60(11):852–5. https://doi.org/10.4103/0019-5049.193685.
4. Chalam KS. Anaesthetic management of conjoined twins' separation surgery. Indian J Anaesth. 2009;53(3):294–301.
5. Lalwani J, Dubey K, Shah P. Anaesthesia for the separation of conjoined twins. Indian J Anaesth. 2011;55(2):177–80. https://doi.org/10.4103/0019-5049.79902.
6. Sánchez-Díaz JS, et al. Hemodynamic monitoring with two blood gases: a tool that…. Colombian J Anesthesiology. 2021;49(1):e928.

Figures

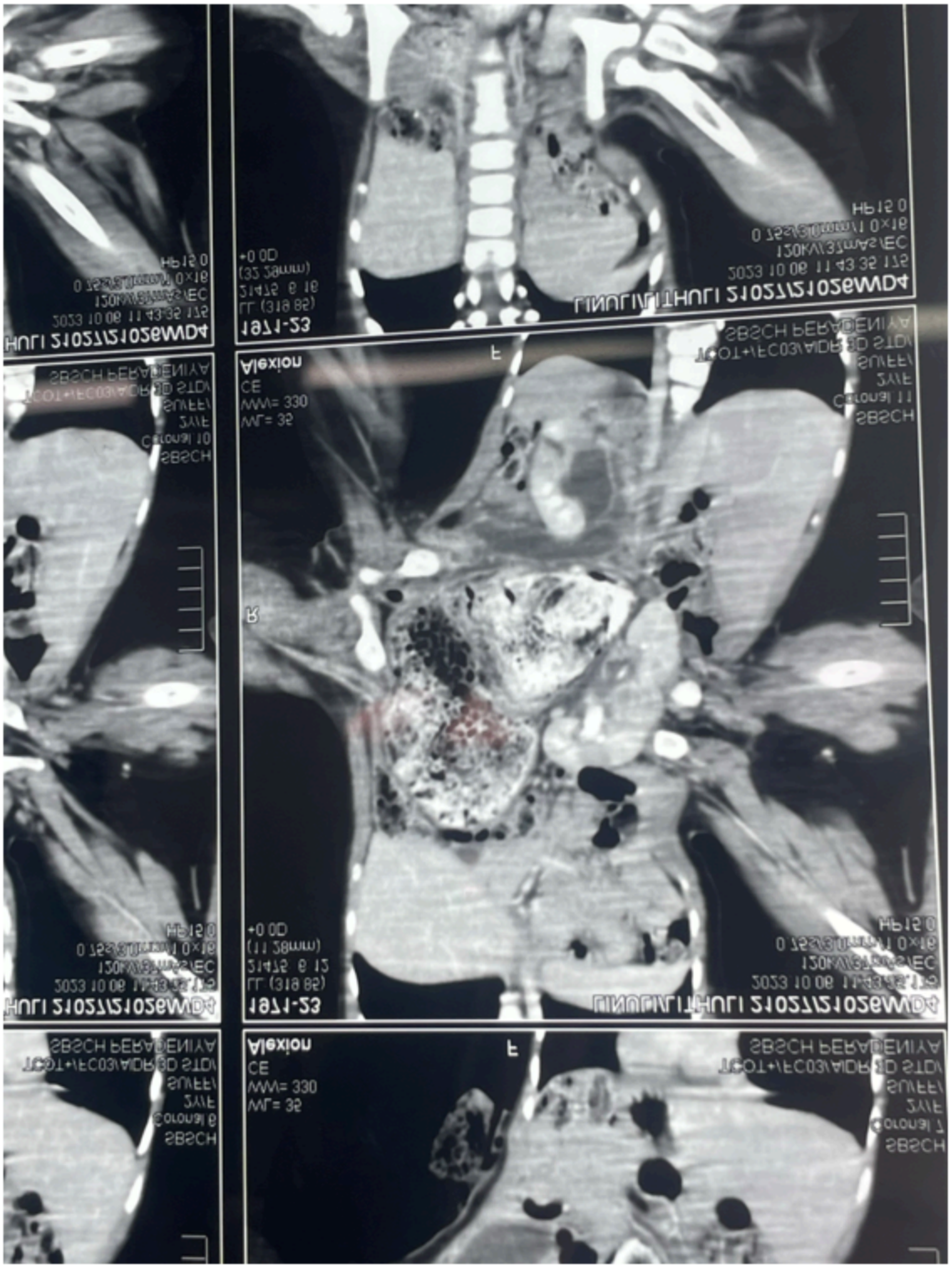

Figure 1

MRI abdomen showing shared kidney



Figure 2

simultaneous deep extubation