Research Square

Preprints are preliminary reports that have not undergone peer review.
They should not be considered conclusive, used to inform clinical practice,
or referenced by the media as validated information.

Surgery Outcomes of Lamellar Macular Eyes with or without Lamellar Hole-Associated Epiretinal Proliferation: A Meta-Analysis

hanyue xu
Sichuan University https://orcid.org/0000-0002-9905-5874
Ling Qin
Sichuan University West China Hospital
Yifan Zhang
Sichuan University West China School of Medicine
Ming Zhang (mingzhangscu@163.com)
https://orcid.org/0000-0003-0151-7813

Research article

Keywords:

Posted Date: December 11th, 2019

DOI: https://doi.org/10.21203/rs.2.18331/v1

License: This work is licensed under a Creative Commons Attribution 4.0 International License.
Read Full License

Version of Record: A version of this preprint was published on August 25th, 2020. See the published version at https://doi.org/10.1186/s12886-020-01617-4.

Abstract

Purpose: To compare the visual outcomesand rate of restored ellipsoid zone (REZ) after surgery of lamellar macular hole (LMH) with and without lamellar hole-associated epiretinal proliferation (LHEP). To determine whether all patients with LMH need surgery.

Method: Publications up to November 2019 that compared the outcomes of LMH patients with and without LHEP who were managed by surgery were included. Forest plots were created using a weighted summary of proportion meta-analysis. A random effects mode was used and I2 heterogeneity estimates were calculated. Sensitivity analysis was carried out to evaluate the stability of the meta-analysis.

Result: Four pertinent publications studying a total of 157 patients were identified. They were all retrospective studies and had a mean follow-up of at least 6 months. In all studies, the best corrected visual acuity (BCVA) had no significant differences before surgery and improved in both groups. The rate of REZ were different among studies included. Meta-analytic pooling of the improved BCVA between with and without LHEP groups was 0.15 (95 % CI, 0.02 to 0.27; p=0.02), and the pooled data revealed an odd ratio of 5.79 (95% CI, 1.15 to 29.18; p = 0.03) in the rate of restored ellipsoid zone, comparing the group without LHEP and the group with LHEP.

Conclusion: Patients with LHEP were more likely to gain restored ellipsoid zone after surgery but had lower postoperative BCVA. The surgery of LMH with LHEP appeared to be useless for improving visual acuity.

Introduction

Lamellar macular hole (LMH) is a partial-thickness loss of foveal tissue, firstly described by Gass based on biomicroscopic and angiographic findings in a case[1]. The formation of LMH can be due to cystoid macular edema, contraction of the perifoveal epiretinal membrane and virteous traction[2]. The diagnosis of LMH was redefined in 2006 by Witkin et al. with characteristics as follows: (1) irregular foveal contour; (2) break in the inner fovea; (3) intraretinal split; and (4) intact foveal photoreceptors[2].

With the development of ultrahigh-resolution optical coherence tomography (UHR-OCT), the structure of LMH has been observed more clearly. Epiretinal membranes (ERM) are visualized on UHR-OCT in most cases of LMH and represented as trapped vitreous or posterior hyaloid. There are two types of ERM, tractional ERM (T ERM) and lamellar hole-associated epiretinal proliferation (LHEP) which is also named as thick ERM and dense ERM. Based on OCT, T ERM is observed as a dense reflective line above retina, while LHEP is homogenous medium with much lower reflectivity. Meanwhile, T ERM has stronger contractile properties compared with LHEP [3]. These two kinds of ERM can occur in LMH patients simultaneously or separately, and T ERM occurs more often than LHEP.

In terms of treating LMH, surgery is still a controversial choice. Pars plana vitrectomy with internal limiting membrane (ILM) peeling is the most common method and has been reported to be useful in most

patients with LMH, especially those with significantly low visual acuity [4–6]. However, this operation still has some risks, as some patients have an unsatisfactory outcome and develop into FTMH after surgery. Moreover, the natural progress of LMH is stable and observation can still be helpful for some patients [7].

To figure out suitable patients for surgery, some previous studies focused on the surgical outcomes of patients with and without LHEP, but their results were inconsistent. Based on these studies, we aimed to compare patients with and without LHEP in the outcomes of the surgery.

Methods

We searched the Pubmed, Medline (1990-November 2008), Embase (1980-November 2008) and Clinical-trails for studies in comparing surgical outcomes of LMH patients with and without LHEP. All studies included were retrospective studies. We identified relevant studies using the terms “Lamellar macular hole”, or “LMH”, or “epiretinal membrane”, or “ERM”, or “lamellar hole-associated epiretinal proliferation”, or “LHEP”, and “surgery” or “operation” or “vitrectomy”.

Study selection

For all studies included, the inclusion criteria were if study: 1) compared LMH patients with and without LHEP; 2) provided specific numbers for patients in each group; 3) reported the best corrected visual acuity (BCVA) both before and after operation; 4) took a standard pars plana vitrectomy combining with ERM and ILM peeling; 5) had a mean follow-up of at least 6 months. Exclusion criteria included having: 1) inadequate record of surgery progress and postoperative BCVA at ≥ 6 months; 2) patients developed into FTMH before surgery.

Validity assessment

Our search identified 272 studies, of which 4 fulfilled our inclusion criteria. Figure 1 summarized the process of the study selection. NOS was used by two investigators separately to score the quality of all included studies, and the total score of every study was equal or greater than 7.

Data abstraction

All the information in the involved studies were extracted by two investigators separately, including basic characteristics, surgery method, preoperative and postoperative data using a standardized protocol. Disagreements were resolved by consensus.

Quantitative data synthesis

The summary odds ratios (OR) of LMH patients with and without LHEP with 95% confidence intervals (95%CI) were also calculated, and the weighted mean difference was calculated with the 95 % CI for BCVA. A P value < 0.05 was considered to be statistically significant.

Both fixed effect and random effects models were used to pool studies. When I^2 index, which measures the extent of the heterogeneity, was less than 50%, the final conclusions were drawn from the results of the fixed effects model, otherwise using random effects model. Funnel plots was used to identify the potential publication bias. Sensitivity analysis was carried out to evaluate the stability of the meta-analysis by omitting one study each time.

All statistical analyses were conducted with Review Manager (version 5.2; Cochrane Collaboration, Oxford, UK; http://ims.cochrane.org/revman) and STATA software (version 11.0; Stata Corp LP, College Station, TX).

Results

Characteristics of the available studies

A total of 272 records were retrieved from the electronic database search (Figure 1). After removing duplications and articles written in other languages, 140 articles were left. By reading the titles and abstracts, 10 researches related to LHEP and surgery outcomes were reserved. Two studies included patients with FTMH were excluded [8, 9], and a study recruited LMH patients with high myopia was also excluded [10]. Meanwhile, two study with incomplete information were excluded [11, 12]. In addition, another study was excluded for it was an observational study without surgery [3].

Outcomes of meta-analysis

No heterogeneity was observed in the comparing model of restored ellipsoid zone (REZ) (I^2 = 0%, P = 0.36). So fixed-model analysis was used in the meta-analysis.

The WMD in the improved logMAR BCVA between with and without LHEP groups was 0.15 (95 % CI, 0.02 to 0.27). Meta-analysis showed statistically significant difference (P = 0.02).

Only three studies reported the status of ellipsoid zone before and after surgery. The pooled data revealed an OR of 5.79 in the rate of restored ellipsoid zone, comparing the group without LHEP and the group with LHEP. It was statistically significant at the 95% level (95% CI, 1.15 to 29.18; p = 0.03) (figure 2.).

To assess potential publication bias in the meta-analysis, funnel plots were visually inspected, and no funnel plot asymmetry was visualized (Figure 3). By egger test, publication bias existed in the studies with BCVA reported (P = 0.889).

Sensitivity analysis was conducted to evaluate the influence of individual data on the pooled results of BCVA. The statistical findings of BCVA did not change by removing any one of the studies (Figure 4).

Discussion

The present study found the surgery outcomes of LMH patients with and without LHEP had significant difference. Patients with LHEP were more likely to gain restored ellipsoid zone after surgery but had lower postoperative BCVA.

The existence of ERM has been detected for several decades, while the pathogenesis and category of it are still unclear. T ERM is tractional and the retinal surface under it is usually plicated. The LMH associated with T ERM always has short diameter and shallow cleft, limited in the inner part of retina and described as “high hat” by Andrea et al. In contrast, LHEP is an atypical ERM with no traction and the LMH associated with it is larger and deeper [13]. In a previous study, glial cells and hyalocytes were found in both these two kinds of membranes, while α-SAM was only found in T ERM, explaining the tractional ability of T ERM [14].

The origin of LHEP is not clear but there are two main theories. Firstly, as LHEP has abundant clusters of fibrous long-spacing collagen, fibroblasts and hyalocytes, it is believed that the posterior detachment of vitreous body, which induce anterior and tangential traction, plays a role in the formation of ERM [14, 15]. Secondly, the finding of the cystic spaces in LHEP, which is due to the leakage of fluid from retinal vessels within it, suggesting LEHP possesses characteristics similar to that of the middle retinal layers and probably originates from there [3]. The proof that yellow color of LHEP is xanthophyll mainly produced by muller cells further certifies the relationship between LHEP and the middle retinal layers [16].

According to the results of present study, less BCVA could be regained in patients with LHEP after surgery compared with those without LHEP. In some previous studies, BCVA improved in both patients with or without LHEP [17, 18], while in other studies BCVA had no change among patients with LHEP [15, 19]. Moreover, in present study, surgery benefited patients with LHEP more than patients without LHEP in the restoration of ellipsoid zone. Hence, it can be concluded that more patients with LHEP gained ellipsoid zone restoration, while had worse postoperative BCVA. This phenomenon may can be explained by previous studies, which reported that though the defection of ellipsoid zone before surgery was associated with worse postoperative BCVA, its restoration showed no direct association with functional recover [5, 20]. Furthermore, a study explored the natural process of LMH and regarded it as a stable disease with no significant BCVA change without surgery [7]. Though the present results showed that the surgery of LMH with LHEP was not helpful for improving visual acuity, more studies comparing LHEP cases with and without surgery are necessary.

All studies included operated standard pars plana vitrectomy with traditional ERM and ILM peeling. However, in recent years, a new surgery method has been developed for LHM patients with ERM. Comparing with the regular surgery method, the main difference is about the disposition of ERM and ILM. Instead of peeling the membrane, in the new method, ERM was double inverted and ILM was flapped [21, 22]. This kind of surgery can retain LHEP and promote the recovery of LHM, and a study indicated that the development of LHEP might be a recovery progress of LMH [19]. This newly surgical method and its positive outcomes further raise a doubt in the necessity of taking surgery for LHM patients with ERM.

There are some limitations in this study that need to be mentioned. Firstly, the number of studies involved is small and more studies are required for extended exploration. Secondly, the number of patients with cataract were only stated in two studies, and the different number of patients with combined phacoemulsification and intraocular lens implantation can influence the outcome of BCVA. Thirdly, there were slight differences in the choice of the gas for the final tamponade, either air, sulphur hexafluoride (SF6) or perfluoropropane (C3F8) gas.

In conclusion, this study pooled the postoperative outcomes of LMH patients with and without LHEP and found that though more LHEP patients can gain EZR, the postoperative BCVA of them was worse than patients without LHEP.

Declarations

Ethics approval and consent to participate

Not applicable

Consent for publication

Not applicable

Availability of data and materials

The datasets used and/or analysed during the current study are available from the corresponding author on reasonable request.

Competing interests

The authors declare that they have no competing interests

Funding

Not applicable

Authors' contributions

MZ and LQ contributed to the study design. HY X and YF Z contributed to the data collection and analysis. HY X contributed to the writing of this manuscript.

Acknowledgements

Not applicable

References

1. Gass, J.D., *Lamellar macular hole: a complication of cystoid macular edema after cataract extraction: a clinicopathologic case report.* Trans Am Ophthalmol Soc, 1975. **73**: p. 231-50.
2. Witkin, A.J., et al., *Redefining lamellar holes and the vitreomacular interface: an ultrahigh-resolution optical coherence tomography study.* Ophthalmology, 2006. **113**(3): p. 388-97.
3. Pang, C.E., R.F. Spaide, and K.B. Freund, *Epiretinal proliferation seen in association with lamellar macular holes: a distinct clinical entity.* Retina, 2014. **34**(8): p. 1513-23.
4. Sanisoglu, H., et al., *Surgical therapy versus observation for lamellar macular hole: a retrospective comparison study.* Clin Ophthalmol, 2013. **7**: p. 1843-8.
5. Sun, J.P., et al., *Surgical treatment of lamellar macular hole secondary to epiretinal membrane.* Graefes Arch Clin Exp Ophthalmol, 2013. **251**(12): p. 2681-8.
6. Michalewska, Z., et al., *Surgical treatment of lamellar macular holes.* Graefes Arch Clin Exp Ophthalmol, 2010. **248**(10): p. 1395-400.
7. Bottoni, F., et al., *The natural history of lamellar macular holes: a spectral domain optical coherence tomography study.* Graefes Arch Clin Exp Ophthalmol, 2013. **251**(2): p. 467-75.
8. Ubukata, Y., et al., *The Comparison of the Surgical Outcome for the Full-Thickness Macular Hole with/without Lamellar Hole-Associated Epiretinal Proliferation.* J Ophthalmol, 2017. **2017**: p. 9640756.
9. Lee Kim, E., et al., *Characterization of Epiretinal Proliferation in Full-Thickness Macular Holes and Effects on Surgical Outcomes.* Ophthalmol Retina, 2019.
10. Lai, T.-T., S.-N. Chen, and C.-M. Yang, *3 Epiretinal proliferation in lamellar macular holes and full-thickness macular holes: clinical and surgical findings.* Graefes Archive for Clinical & Experimental Ophthalmology, 2016. **254**(4): p. 629-38.
11. Marques, M.F., et al., *Epiretinal Proliferations Associated with Lamellar Macular Holes: Clinical and Surgical Implications.* Ophthalmologica, 2018. **240**(1): p. 8-13.
12. dell'Omo, R., et al., *Role of Lamellar Hole-Associated Epiretinal Proliferation in Lamellar Macular Holes.* Am J Ophthalmol, 2017. **175**: p. 16-29.
13. Govetto, A., et al., *Lamellar Macular Hole: Two Distinct Clinical Entities?* Am J Ophthalmol, 2016. **164**: p. 99-109.
14. Compera, D., et al., *Correlative Microscopy of Lamellar Hole-Associated Epiretinal Proliferation.* J Ophthalmol, 2015. **2015**: p. 450212.
15. Parolini, B., et al., *Lamellar macular hole: a clinicopathologic correlation of surgically excised epiretinal membranes.* Invest Ophthalmol Vis Sci, 2011. **52**(12): p. 9074-83.
16. Obana, A., et al., *Evidence of Carotenoid in Surgically Removed Lamellar Hole-Associated Epiretinal Proliferation.* Invest Ophthalmol Vis Sci, 2017. **58**(12): p. 5157-5163.
17. Choi, W.S., D.J. Merlau, and S. Chang, *Vitrectomy for macular disorders associated with lamellar macular hole epiretinal proliferation.* Retina, 2018. **38**(4): p. 664-669.

18. Ko, J., et al., *Surgical outcomes of lamellar macular holes with and without lamellar hole-associated epiretinal proliferation.* Acta Ophthalmol, 2017. **95**(3): p. e221-e226.
19. Lai, T.T., S.N. Chen, and C.M. Yang, *Epiretinal proliferation in lamellar macular holes and full-thickness macular holes: clinical and surgical findings.* Graefes Arch Clin Exp Ophthalmol, 2016. **254**(4): p. 629-38.
20. Lee, C.S., et al., *Prognostic factors in vitrectomy for lamellar macular hole assessed by spectral-domain optical coherence tomography.* Acta Ophthalmol, 2012. **90**(8): p. e597-602.
21. Shiode, Y., et al., *Embedding of lamellar hole-associated epiretinal proliferation combined with internal limiting membrane inversion for the treatment of lamellar macular hole: a case report.* BMC Ophthalmol, 2018. **18**(1): p. 257.
22. Frisina, R., et al., *A Double Inverted Flap Surgical Technique for the Treatment of Idiopathic Lamellar Macular Hole Associated with Atypical Epiretinal Membrane.* Ophthalmologica, 2019. **242**(1): p. 49-58.

Table

Due to technical limitations, table 1 is only available as a download in the supplemental files section

Figures

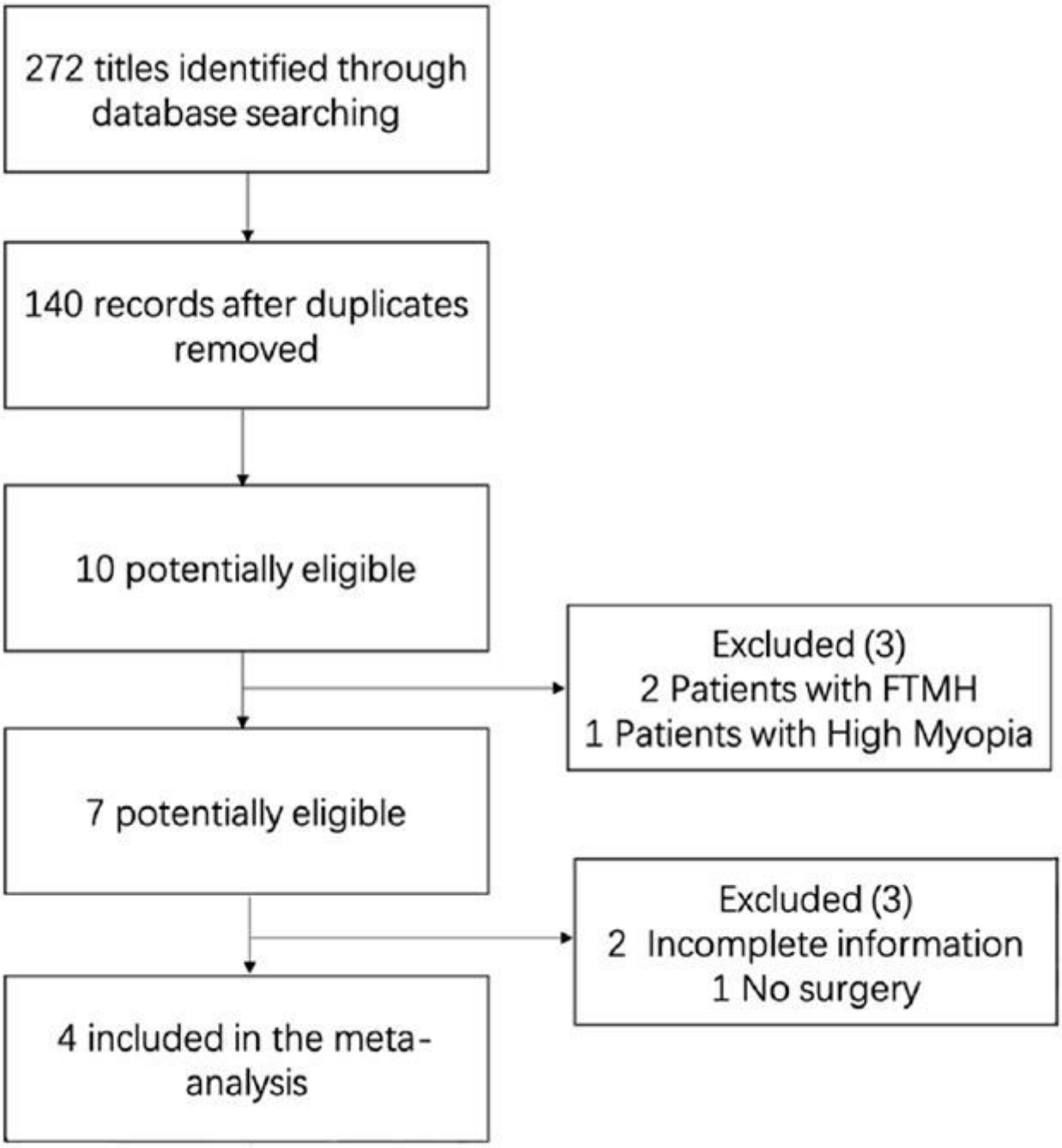

Figure 1

The flow diagram of the screening of the literatures.

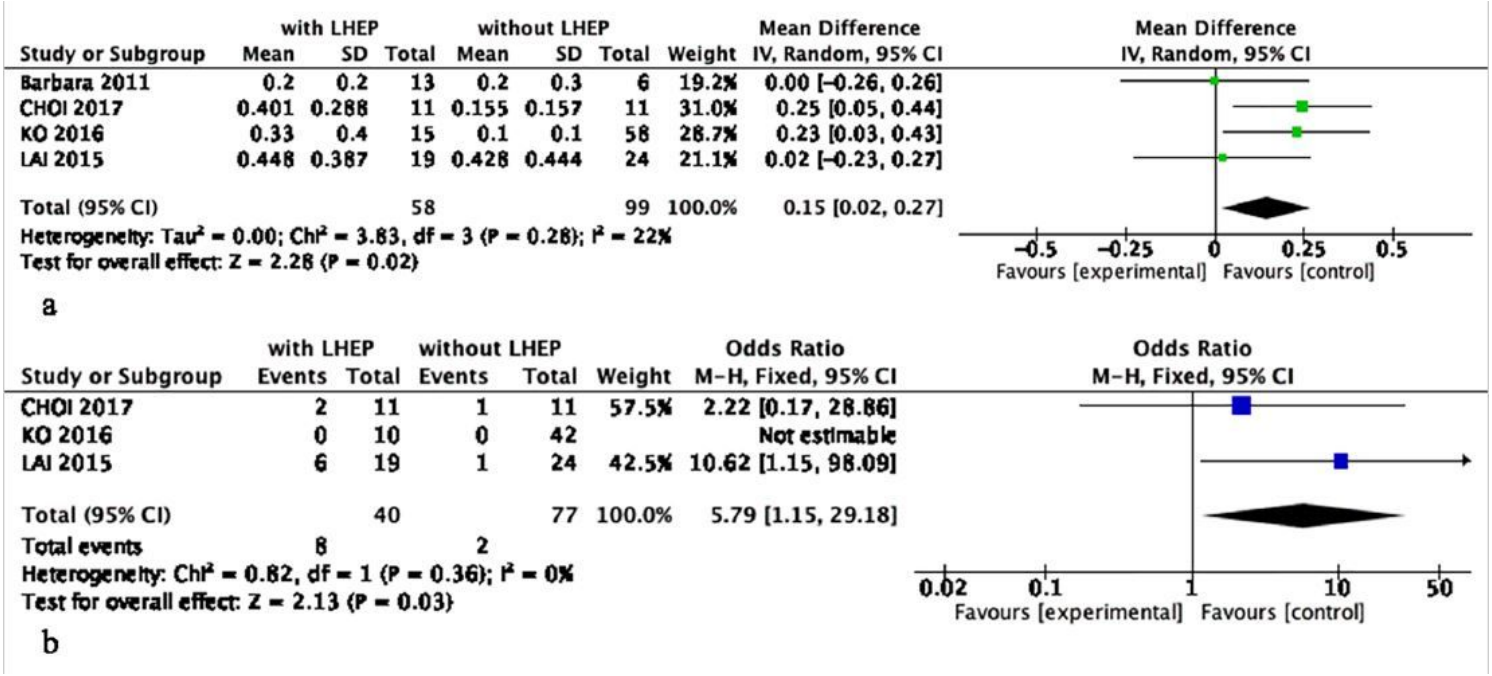

Figure 2

(a) Meta-analysis of the best corrected visual acuity in patients between eyes with or without lamellar hole-associated epiretinal proliferation (LHEP), (b) Meta-analysis of the ellipsoid zone restoration rate in patients between eyes with or without LHEP.

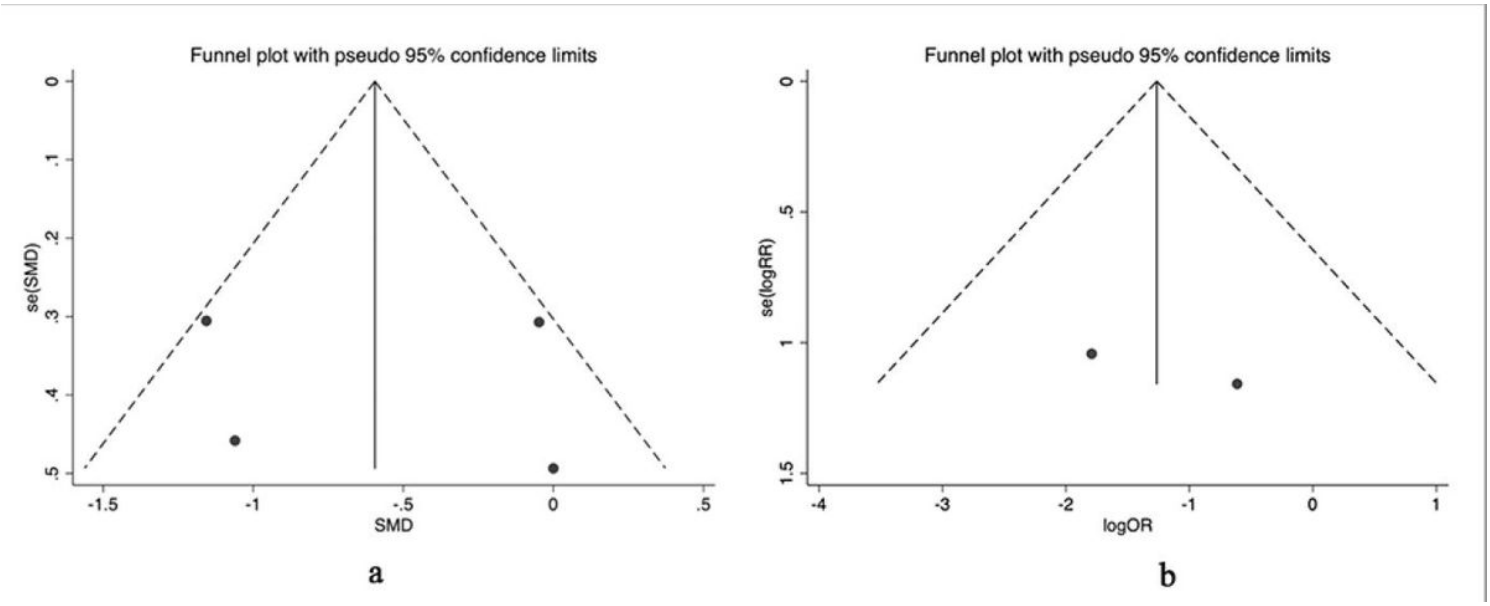

Figure 3

(a) The funnel plot of studies included in the analysis of BCVA, (b) the funnel plot of studies included in the analysis of ellipsoid zone restoration rate.

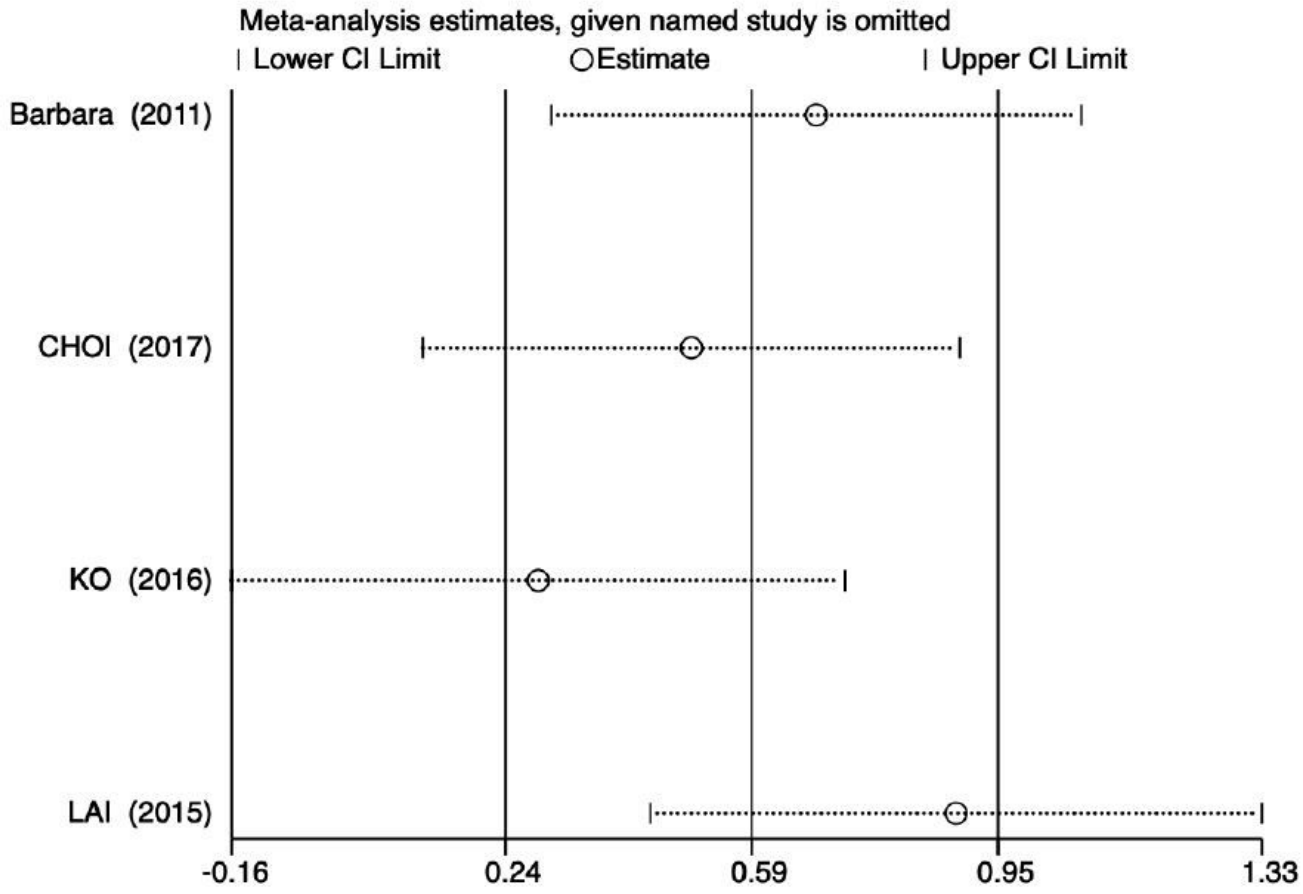

Figure 4

The sensitivity analysis on the pooled results of the best corrected visual acuity (BCVA).

Supplementary Files

This is a list of supplementary files associated with this preprint. Click to download.

- table1.xlsx
- PRISMA2009checklist.doc
- supplementary1.xlsx