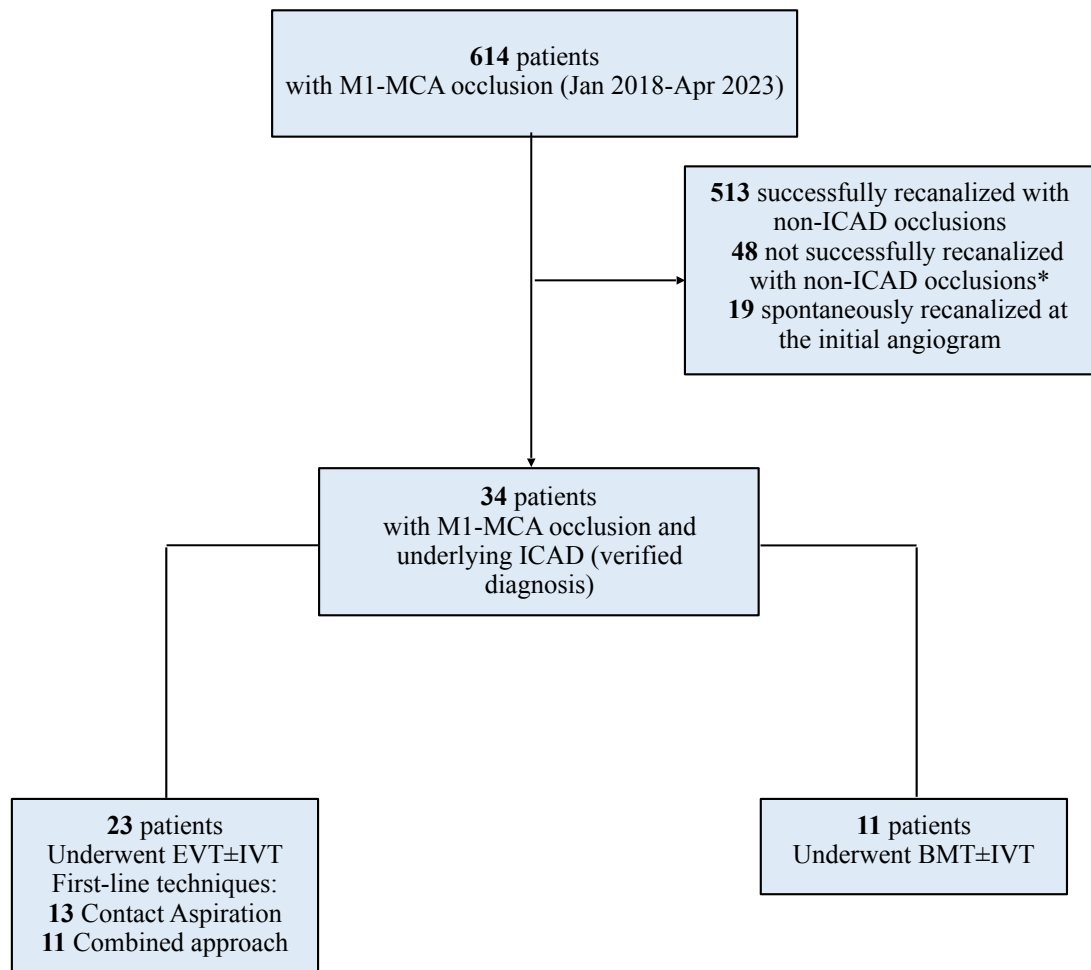


Supplemental material



Supplemental Fig.1. Flow-chart of the study: MCA: middle cerebral artery; ICAD: intracranial atherosclerotic disease; EVT: endovascular treatment; BMT: best medical therapy.

*in 7 patients it was not possible to fully exclude an underlying ICAD, however no other factors rising up the suspicion of ICAD were present