

Post-Course Survey

AAA



Assessment of a novel interactive online course for oculoplastic surgery

Unique 4 Digit Identifier

Please use the same identifier that you used for the pre-survey.

* must provide value

What training level in residency are you currently?

* must provide value

- PGY-1
- PGY-2
- PGY-3
- PGY-4

How much of the "basics of oculoplastics" part 1 module did you complete?

* must provide value

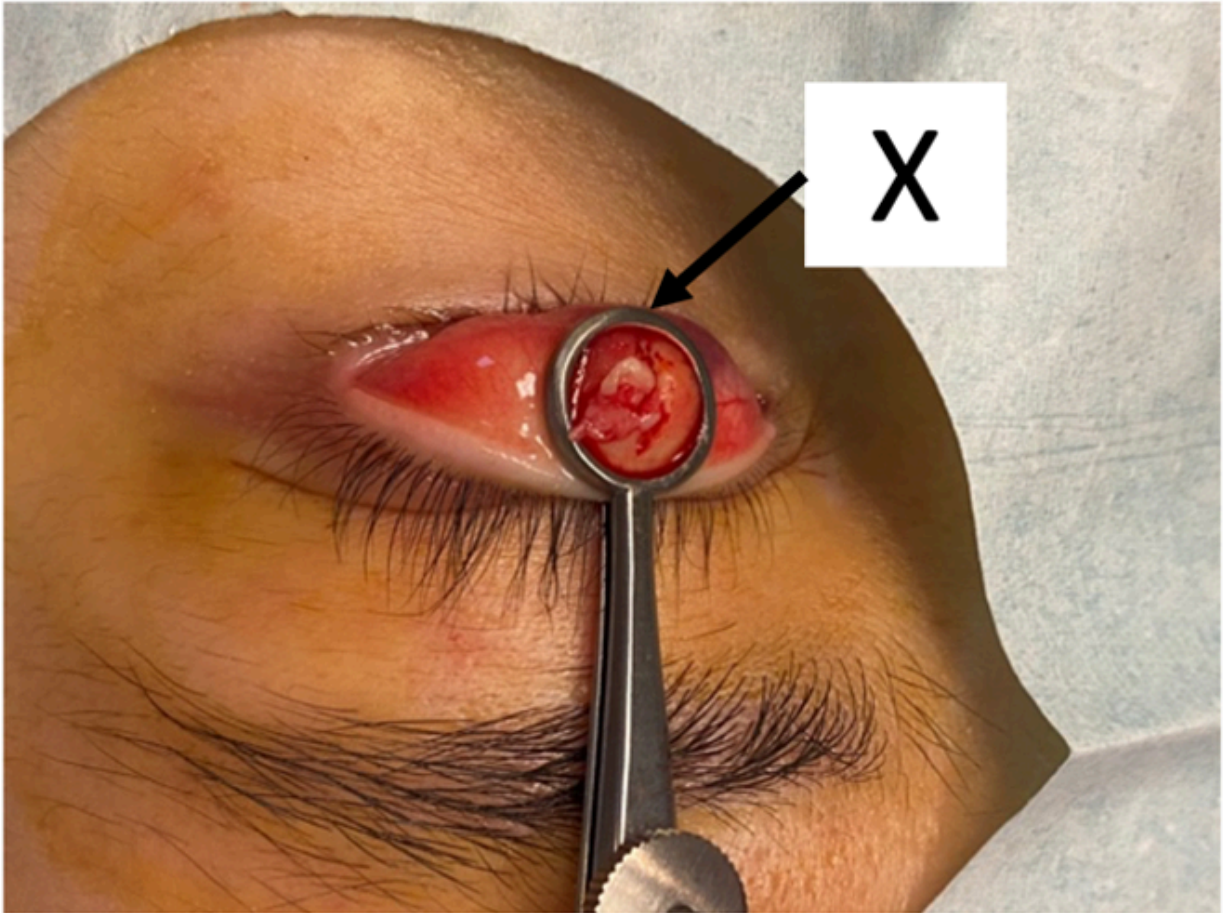
How much of the "basics of oculoplastics" part 2 module did you complete?

How much of the "intermediate oculoplastics surgery" part 1 module did you complete?

How much of the "intermediate oculoplastic surgery" part 2 module did you complete?

Clinical Assessment

1 In this surgeon's view of a chalazion excision, X marks the



* must provide value

- Superior-most aspect of the incision
- Inferior-most aspect of the incision
- Neither is correct

2 Scleral show

* must provide value

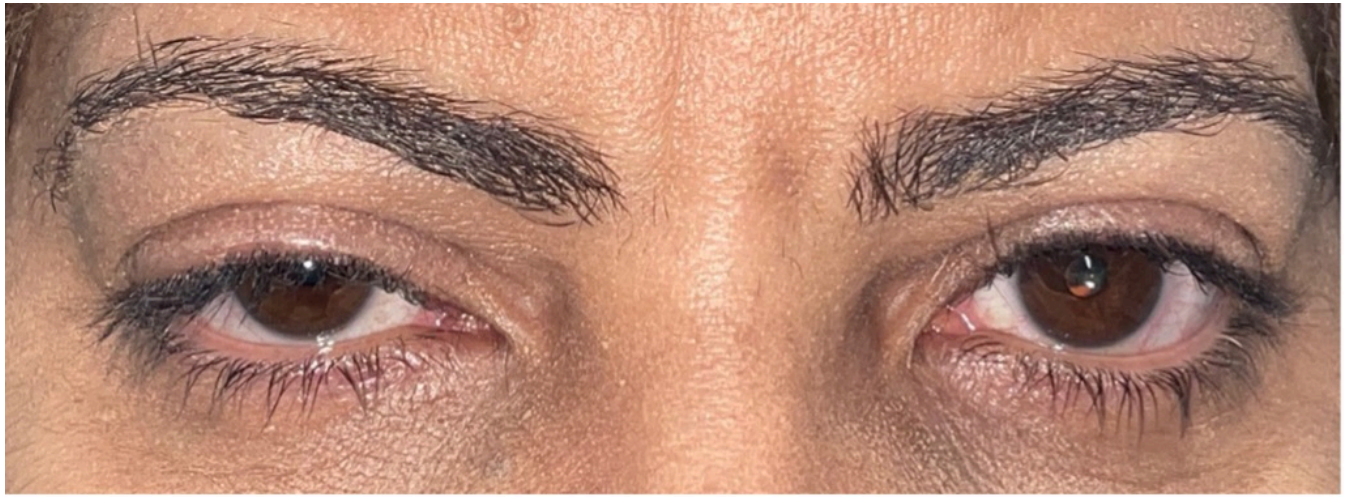- Is the same as retraction
- Refers to retraction when it is secondary to thyroid eye disease
- Refers only to upper lid retraction
- Is almost always associated with exophthalmos

3 The lid crease

* must provide value

- Is generally higher in men than women
- Is generally lower in Asian patients
- Generally does not change with aponeurotic ptosis
- Is generally higher in patients with significant dermatochalasis

4 Estimate the patient's MRD-1 OD and OS



* must provide value

- 0, 3
- 1, 4
- 3, 0
- 1, 1

5 Which of the following is true about levator function?

* must provide value

- Normal levator function is generally > 20mm
- It is performed by having the patient close their eyes, then open, while fixating the brow
- It correlates with the degree of ptosis
- A 'normal levator function' can vary between people

6-7 What are 2 tests to assess lower lid laxity?

Enter one test in each text box.

* must provide value

6-7 What are 2 tests to assess lower lid laxity?

Enter one test in each text box.

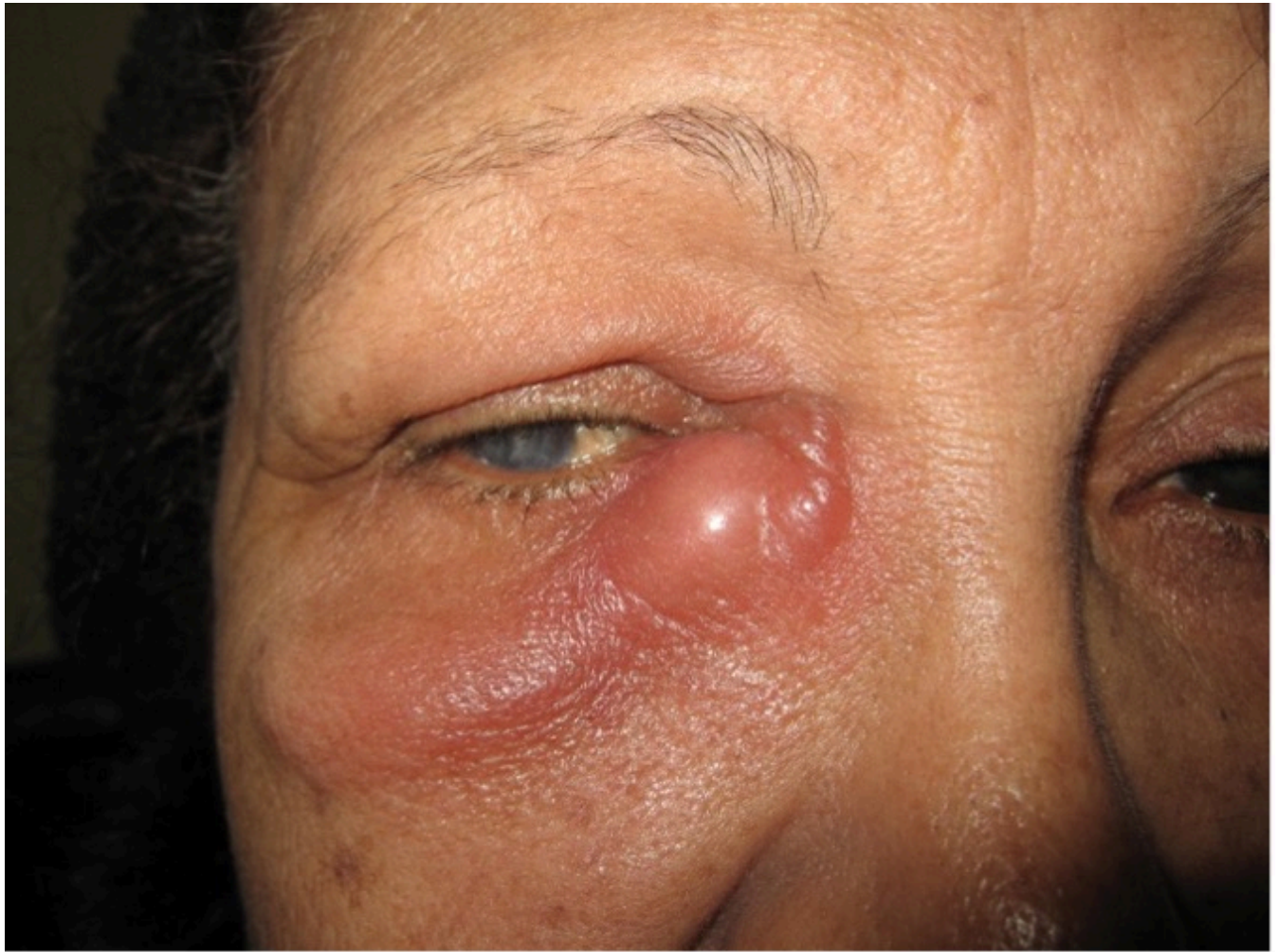* must provide value

8 A patient has fluorescein dye retention in the right eye after Fluress drops are placed in both eyes. Which of the following is true?

* must provide value

- One cannot differentiate between reflex tearing and outflow blockage at this point
- There is likely nasolacrimal duct obstruction in the right side
- Asking if the symptoms get worse on cold and windy days is the best way to differentiate between reflex tearing and outflow blockage
- The dye retention test gives you the same information as lacrimal irrigation but is less precise

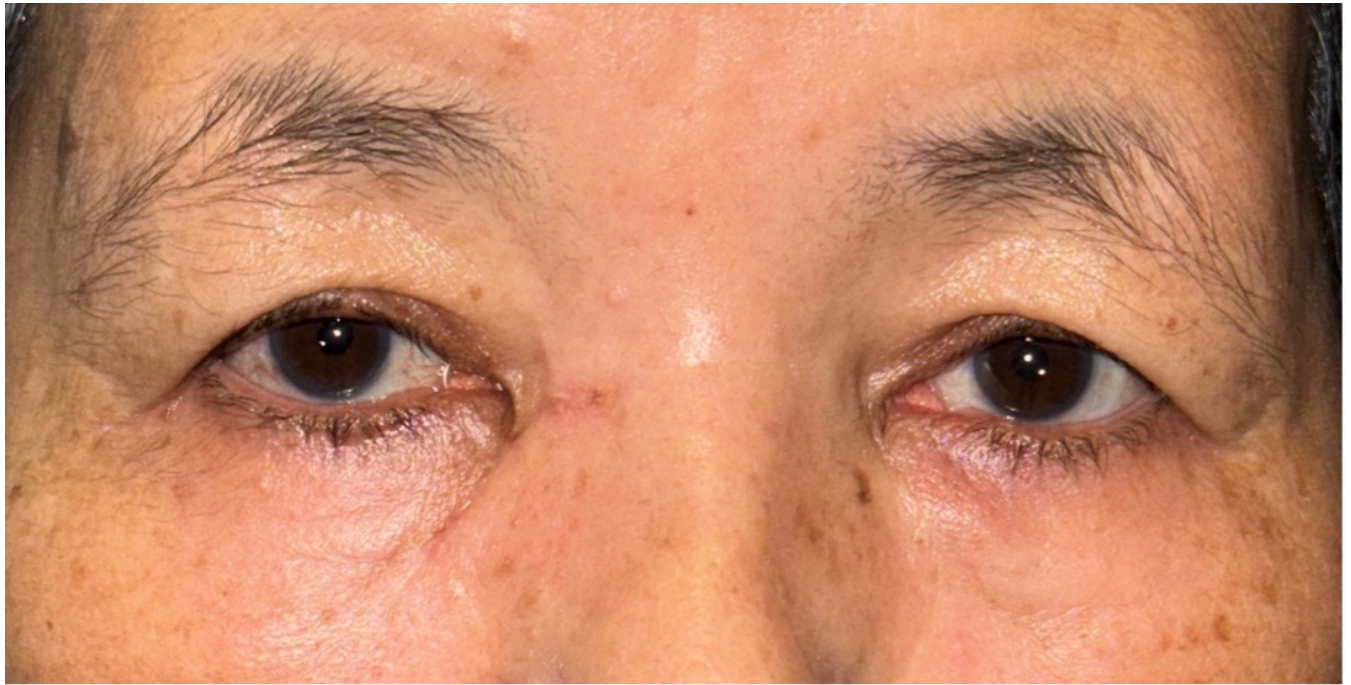9 Is this likely to be a preseptal process or an orbital process?



* must provide value

- Orbital process - it is a severe infection at high risk of extending posteriorly in orbit
- Orbital process - the upper lid involvement from a lower lid origin suggests this is not limited to the lid but is affecting the orbit as well.
- Preseptal process - infections below the medial canthal tendon are almost always preseptal
- Preseptal process - abscesses such as this one cannot go posteriorly

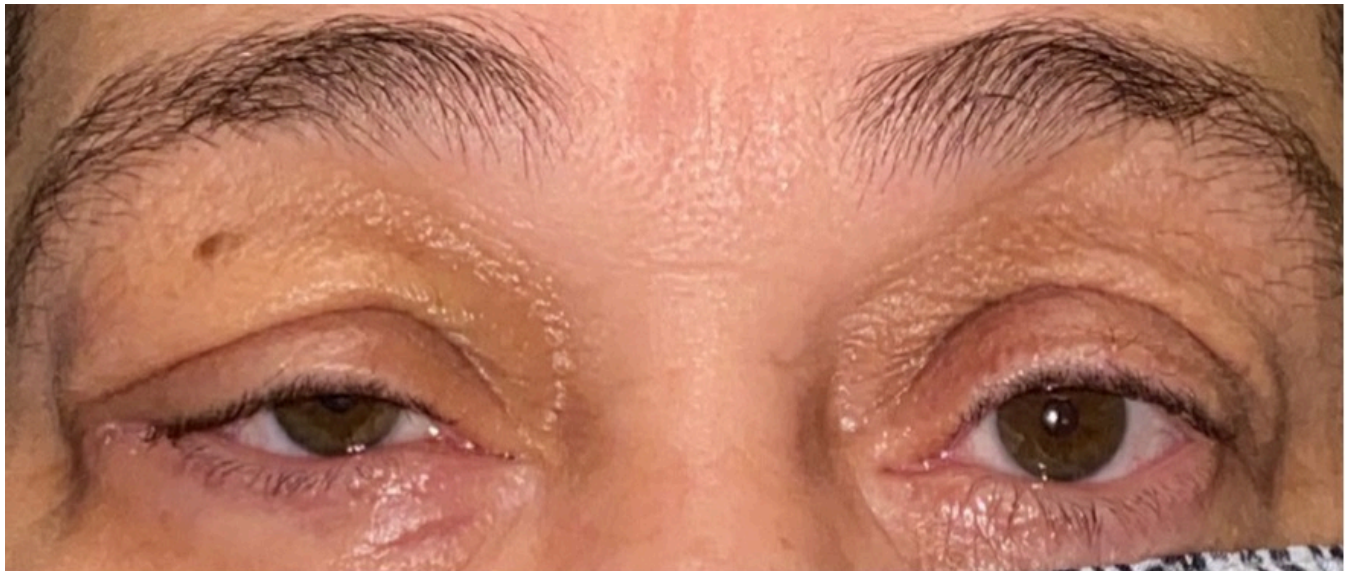10 This patient is complaining of heavy eyelids. She primarily needs



* must provide value

- Blepharoplasty
- Browlift
- Ptosis repair
- Frontalis sling

11 Which treatment is most appropriate for this patient?



* must provide value

- Browlift
- Blepharoplasty
- Ptosis surgery
- Imaging (CT) Orbits

12 Which instrument is this?



* must provide value

- Iris scissors
- Westcott scissors
- Vannas scissors
- Stevens Tenotomy scissors

13 Which is the most commonly used size of Bowman probe?

* must provide value

- 0 / 00
- 000 / 0000
- 1 / 2
- 2 / 3

14 Which is true about the relaxed skin tension lines (RSTLs)?

* must provide value

- Incisions should be placed perpendicular to minimize tension
- They should only be considered in incision planning if there is a visible wrinkle there
- RSTLs in the central forehead are parallel to the frontalis fibers
- RSTLs in the lateral canthus are parallel to the orbicularis fibers

15 In a chalazion surgery, when does the meibum exit the wound?

* must provide value

- When you incise the conjunctiva
- When you incise the tarsus
- When you incise the orbicularis
- None of the above

16 Which needle point has a cutting surface on the superior surface?

* must provide value

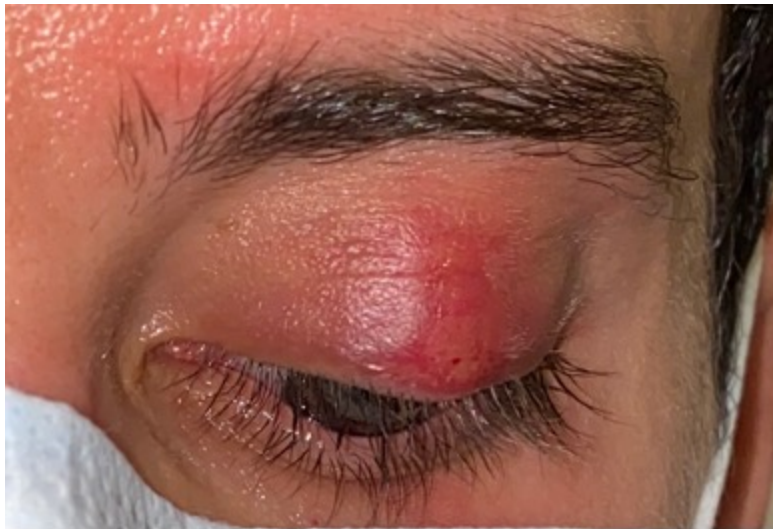- Tapered needle
- Cutting needle
- Reverse cutting needle
- Spatulated needle

17 What is the correct order of suture placement for a lid-margin laceration repair?

* must provide value

- 5-0 vicryl horizontal through tarsus, skin closure, 6-0 silk vertical lid margin suture through tarsus, 6-0 silk lash line suture
- 6-0 silk vertical lid margin suture through tarsus, 6-0 silk lash line suture, 5-0 vicryl horizontal suture through tarsus, skin closure
- 6-0 silk vertical lid margin suture through tarsus, 5-0 vicryl horizontal suture through tarsus, 6-0 silk lash line suture, skin closure
- 5-0 vicryl horizontal through tarsus, 6-0 silk lash line suture, 6-0 silk vertical lid margin suture through tarsus, skin closure

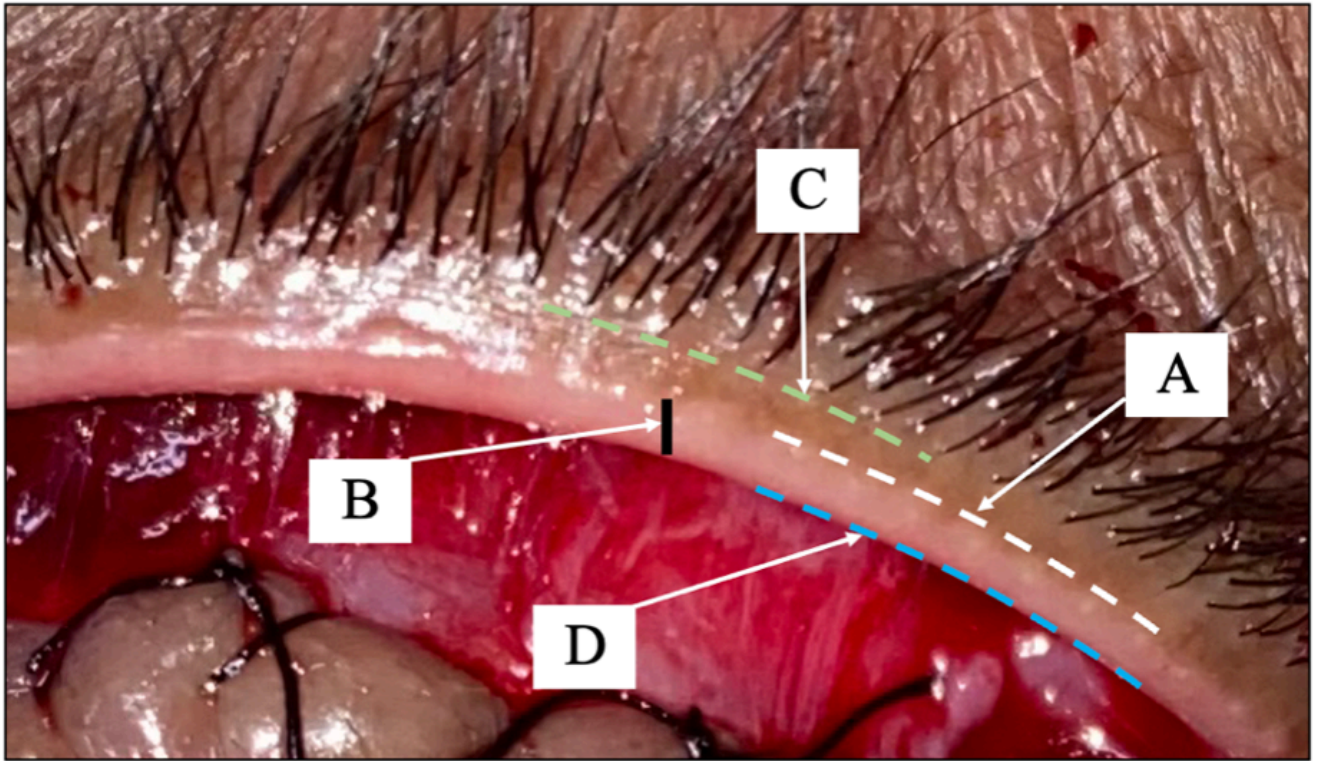
18 A 25-year old patient comes in with 2 weeks of a red, swollen eyelid. It improved in the first few days but has since been stuck looking like this. He is anxious to have the lid look better for an important function in 4 days. What is the best treatment option?



* must provide value

- Hot compresses
- Topical antibiotics
- Steroid injection
- Excision

19-20 Place the correct letters next to the names for the structures of the lid margin.



Gray line:

* must provide value

Mucocutaneous junction:

* must provide value

Tarsus:

* must provide value

Skin edge:

* must provide value

21 A negative orbital vector is

* must provide value

- When the globe is in front of the inferior orbital rim
- When the globe is behind the inferior orbital rim
- When the globe is in front of the superior orbital rim
- When the globe in behind the superior orbital rim

22 How do you minimize the damage to the levator when doing a fat excision during an upper blepharoplasty?

* must provide value

- Use a trans-conjunctival approach
- Incise the septum 2 mm superior to the tarsus
- Incise the septum 2 mm inferior to the superior orbital rim
- Do not incise the septum when removing the fat

23 In marking for a blepharoplasty, the lid crease is at 8 mm. What is the distance from the brow fat pad you should mark for the superior incision to prevent lagophthalmos?

* must provide value

- 8 mm
- 10 mm
- 12 mm
- 14 mm

24 All of these are nomograms for using the phenylephrine test in MMCR except

* must provide value

- Resection of 8mm of Muller's muscle and conjunctiva = effect of phenylephrine drop
- Resection of 6, 8, and 10mm of Muller's muscle and conjunctiva = lid elevation of 1.5, 2, and 2.5mm
- Resection of 4mm of Muller's muscle and conjunctiva for each mm of desired lid elevation.
- Resection of 1mm of Muller's muscle inferior to the tarsus and 1mm of Muller's muscle superior to the tarsus for each mm of lid elevation.

25 MMCR is relatively contra-indicated in all of these patients except

* must provide value

- Patient who cannot undergo general anesthesia
- Patient with asymmetry in lid contour
- History of trachoma
- Minimal response to Phenylephrine test

26 For an 8 mm MMCR, traction sutures should be placed at

* must provide value

- 2 mm
- 4 mm
- 8 mm
- 16 mm

27 A 90 year old nursing home patient who rubs her eyes constantly develops an entropion and a corneal ulcer. She has severe aortic stenosis. Which of the following is the best surgical procedure for her at this point?

* must provide value

- Trans-conjunctival entropion repair (with lateral tarsal strip)
- Trans-cutaneous entropion repair (with lateral tarsal strip)
- Suture correction of entropion
- Temporary tarsorrhaphy

28 Which is true regarding implants?

* must provide value

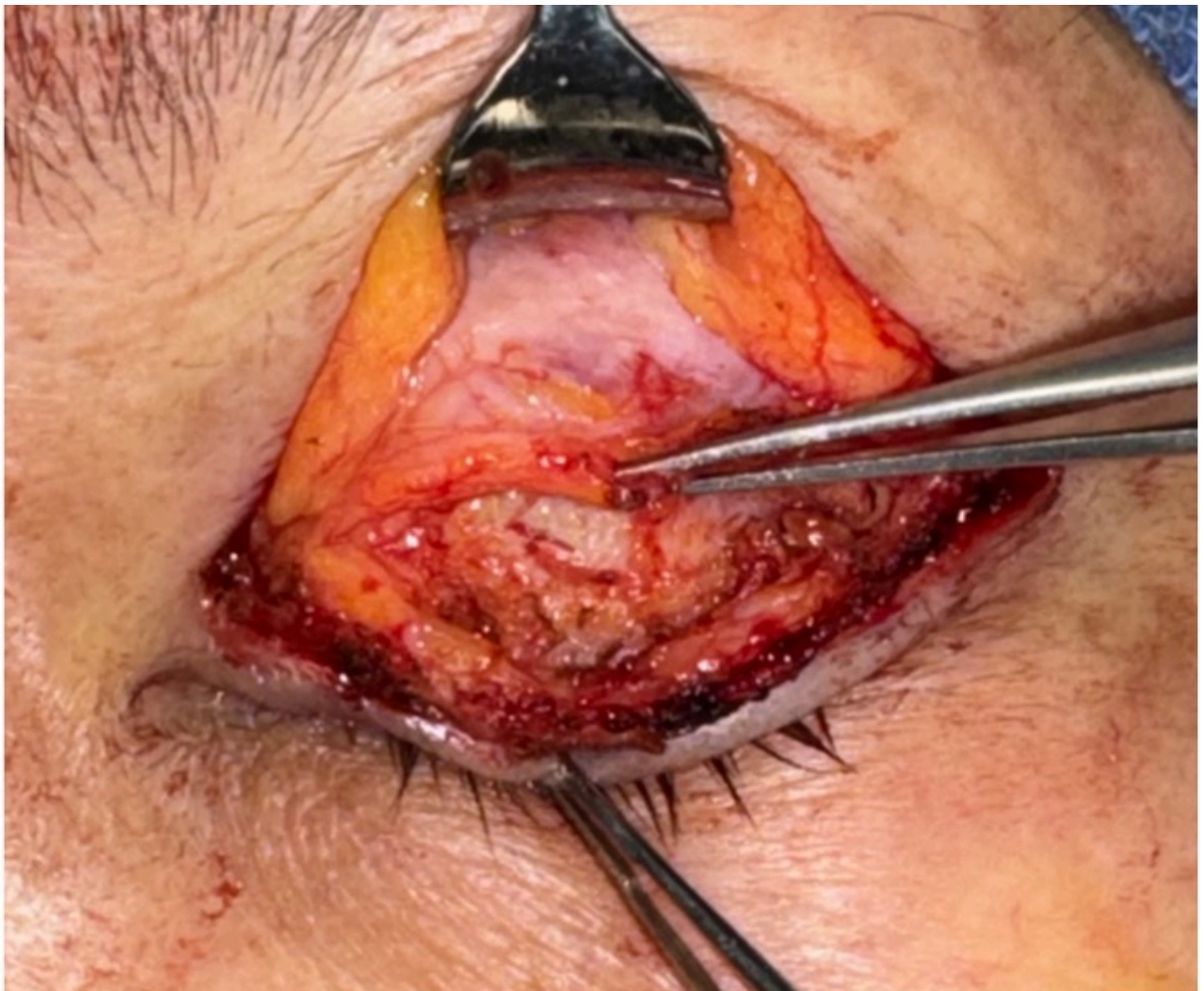
- Porous polyethylene implants give worse motility than Silicone implants
- A dermis fat graft has the least chance of implant extrusion
- Fibrovascular ingrowth is a rare complication of non-integrated implants
- A dermis fat graft results in no motility of the prosthesis because the implant is not secured to the extra-ocular muscles.

29 A 6 year old boy has bilateral congenital ptosis with an MRD1 = 0 and levator function = 5mm. Which of these is NOT true about the surgery he will undergo?

* must provide value

- The patient will very likely have lagophthalmos while sleeping
- The patient will very likely need another surgery before he reaches adulthood
- The patient will very likely have severe corneal epitheliopathy for 3-6 months after surgery
- The patient will very likely have lid lag on downgaze

30 What is the tissue immediately posterior to the tissue being held in the superior forceps?



* must provide value

- Preaponeurotic fat
- Mueller's muscle
- Levator aponeurosis
- Levator muscle

Confidence Level with Oculoplastics Survey Questions

How comfortable are you with diagnosing oculoplastics conditions in clinic? (1 - Lowest, 5 - Highest)

* must provide value

How do you rate your understanding on eyelid and soft tissue anatomy? (1 - Lowest, 5 - Highest)

* must provide value

How do you rate your understanding on the basic oculoplastic surgical principles and suturing techniques? (1 - Lowest, 5 - Highest)

* must provide value

How do you rate your understanding on the oculoplastic instruments and suture types? (1 - Lowest, 5 - Highest)

* must provide value

Do you prefer learning in an online interactive format over textbook format?

- Yes
- No
- I don't know

* must provide value

How confident are you in understanding the pathophysiology, anatomy, surgical decision making, and surgical steps of the following procedures? (1 - Lowest, 5 - Highest)

Chalazion

* must provide value

Full-thickness eyelid laceration repair

* must provide value

Blepharoplasty

* must provide value

Ectropion repair

* must provide value

Entropion repair

* must provide value

Internal Ptosis surgery

* must provide value

External Ptosis surgery

* must provide value

Evisceration

* must provide value

Enucleation

* must provide value

What rating would you give the course based on its instructional quality and relevance to the topic? (1 - Lowest, 5 - Highest)

* must provide value

Finally, would you like to share any feedback?

Submit