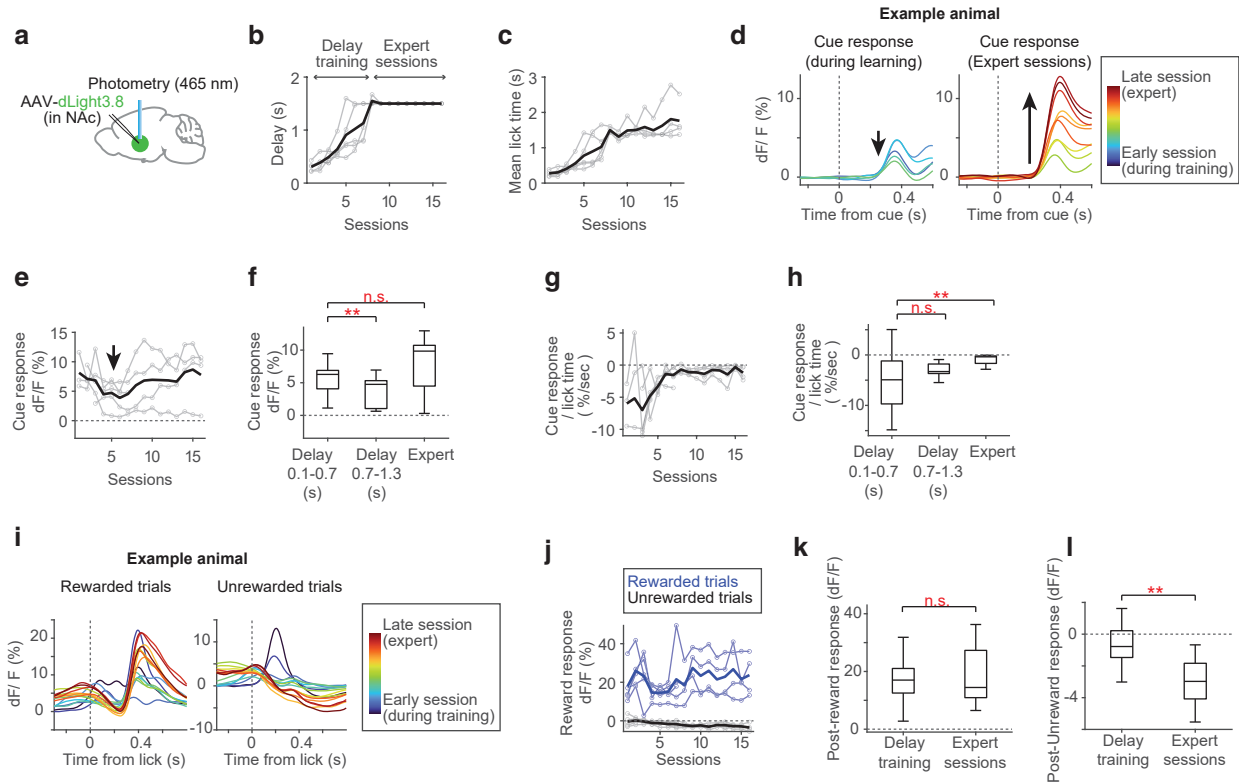


Nucleus accumbens



Dorsolateral striatum (DLS)

