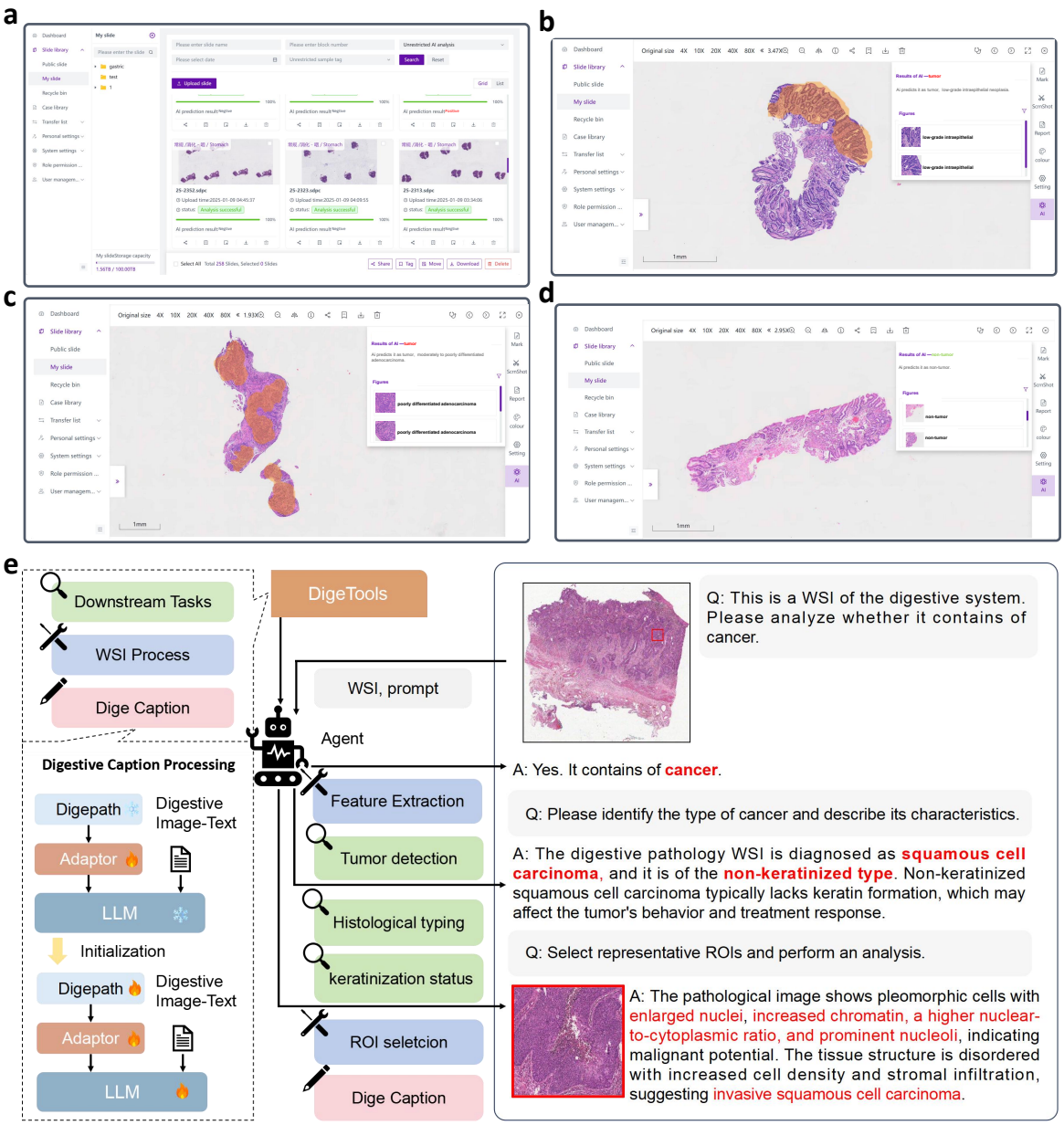
a
b
c
d
e
Downstream Tasks
WSI Process
Dige Caption
DigeTools
WSI, prompt
Agent
Feature Extraction
Tumor detection
Histological typing
keratinization status
ROI seletcion
Dige Caption
Digestive Caption Processing
Digepath
Digestive Image-Text
Adaptor
LLM
Initialization
Digepath
Digestive Image-Text
Adaptor
LLM
Q: This is a WSI of the digestive system. Please analyze whether it contains of cancer.
A: Yes. It contains of cancer.
Q: Please identify the type of cancer and describe its characteristics.
A: The digestive pathology WSI is diagnosed as squamous cell carcinoma, and it is of the non-keratinized type. Non-keratinized squamous cell carcinoma typically lacks keratin formation, which may affect the tumor's behavior and treatment response.
Q: Select representative ROIs and perform an analysis.
A: The pathological image shows pleomorphic cells with enlarged nuclei, increased chromatin, a higher nuclear-to-cytoplasmic ratio, and prominent nucleoli, indicating malignant potential. The tissue structure is disordered with increased cell density and stromal infiltration, suggesting invasive squamous cell carcinoma.