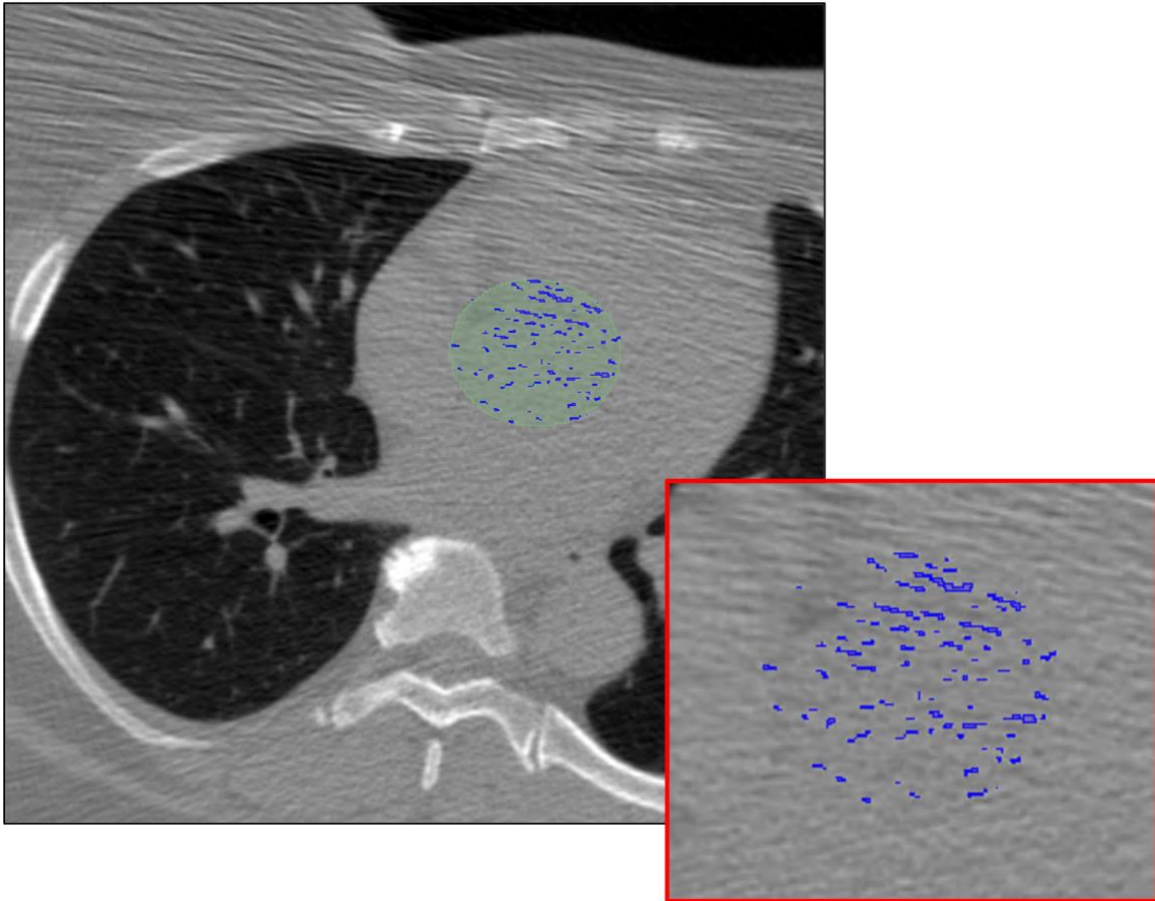


Supplementary Information

Noisy cases were identified and excluded as described in the main text. An example image is provided for reference (Supplemental Figure 1).



Supplemental Figure 1. Noisy cases requiring exclusion. Example of an extremely noisy case with a standard deviation in the aorta for voxels < 130 HU of 53.25, one of 3 cases excluded from our final evaluation. Severe streaking artifacts contribute to many erroneous candidate calcifications, seen in blue, when applying Agatston criteria within the aortic valve region, seen in green. The true AV-Agatston score for this case is 0.