

Right colectomy: Intraoperative form 1

Operation date: _____

Surgeon: _____

Patient name/ study ID: _____

Birthdate: _____

Anatomy preop CT:

ICA in front of SMA: Yes ☐ No ☐ NA ☐

JJ veins in front of SMA: Yes ☐ No ☐ NA ☐

Distance of ICV to GTH (mm) _____

Planned extend of resection:

D2 ☐

Complete D2 ☐

D3 ☐

Access:

Robotic ☐

Laparoscopic ☐

Open ☐

Converted ☐

Anastomosis:

Extracorporeal ☐

Intracorporeal ☐

Handsewn ☐

Stapler ☐

Operation performed:

D2 ☐

Complete D2 ☐

D3 ☐

Bleeding:

None ☐

Surgical hemostasis ☐

Blood loss (ml) _____

Intraoperative surgical complications:

None ☐

Bowel lesion ☐

Vascular lesion ☐

Other ☐

Intraoperative general complications:

None ☐

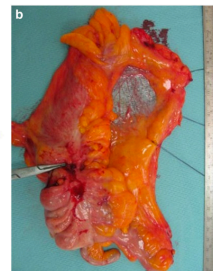
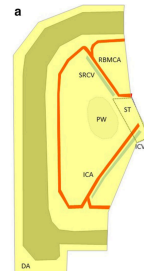
Cardiac ☐

Respiratory ☐

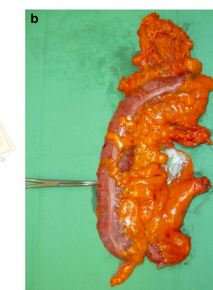
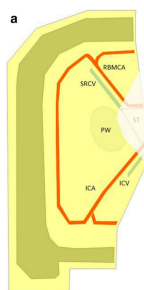
Other ☐

Specimen quality:

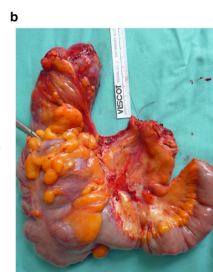
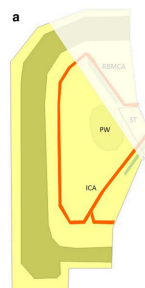
0 ☐



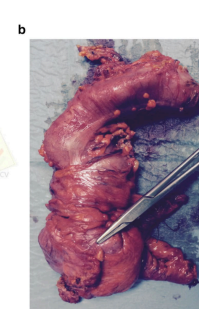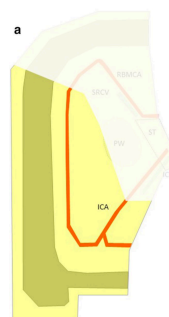
I ☐



II ☐



III ☐



Right colectomy: Intraoperative form 2

Vascular anatomy:

Blood vessel visualized:

SMV☐

GTH☐

SMA☐

MCA☐

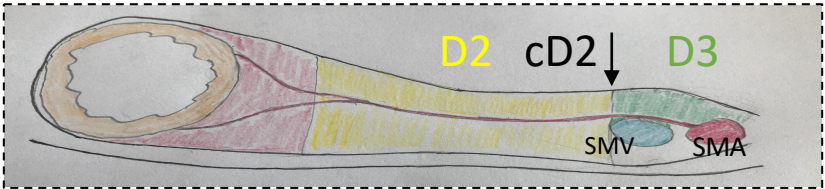
Level of vascular ligature:

To the right of SMV☐

Central☐

Photodocumentation: ☐

Extend of lymphadenectomy:



Mark with cross

