

# Dietary cottonseed consumption induced subfertility in male and female rats: a potent eco-friendly rodenticide compound

**Fariborz Nowzari**

Shiraz University

**Farhad Rahmanifar**

Shiraz University

**Nader Tanideh**

Shiraz Medical School: Shiraz University of Medical Sciences

**Mohammad Reza Dorvash**

Shiraz Medical School: Shiraz University of Medical Sciences

**Arezoo Khoradmehr**

Bushehr University of Medical Sciences

**Neda Baghban**

Bushehr University of Medical Sciences

**Amin Tamadon** (✉ [amintamaddon@yahoo.com](mailto:amintamaddon@yahoo.com))

Bushehr University of Medical Sciences <https://orcid.org/0000-0002-0222-3035>

---

## Research

**Keywords:** Cottonseed flour, Rat, Fertility, Rodenticide

**Posted Date:** May 21st, 2021

**DOI:** <https://doi.org/10.21203/rs.3.rs-538459/v1>

**License:** © ⓘ This work is licensed under a Creative Commons Attribution 4.0 International License.

[Read Full License](#)

---

# Abstract

Effects of cottonseed flour in male and female rats' fertility based on hormonal and histomorphometry changes were studied. Sixty-four Sprague-Dawley adult male and female rats were randomly divided into control and treatment groups. Treatment group was received diets containing cottonseed flour for 35 days. Control group was given standard rat food. Body and testis weights, epididymis semen evaluation indices and serum sex steroid hormones were determined. Histomorphometry alterations of testes and ovary were evaluated. Then, normal female and male rats were mated by rats in both groups and after 35 days, number of pups was measured. However, there was no significant difference in whole body and testes weights, sperm concentration and viability between the control and treatment groups, respectively. Moreover, sperm motility in the treatment rats was significantly lower than the control group. Serum hormones alterations were not significant, but histomorphometry evaluations of testes showed significant changes in the testis structures after chronic consumption of cottonseed flour. In the female rats, body weight did not have significant difference between the treatment and control groups. Histomorphometry data in female ovary showed significant reduction of primary follicle volume and number in the treatment group against control. Follicle stimulating hormone showed insignificant reduction in the treatment group. Number of pups was significantly reduced in the female rats fed by cottonseed flour. Cottonseed flour in rat diet had adverse effects on rat reproduction. Therefore, it can be used as an efficient product for control of the rat population as a natural rodenticide agent.

# Introduction

Rodent population control is necessary to avoid some zoonosis disease and prevent human food from wasting (1). Common rodenticides are chemical baits or liquids, which kill rodent if they feed from them, but rodenticides can also harm other mammals and birds (2). In addition, there are some report on the death of due to the consumption of rodenticides bait and chemical compounds (3). Therefore, this double-bladed weapon against rodent can cause life treating problems and contamination of water, soil and foods that increase cancer due to teratogens activities (4–6). Humans are exposed to rodenticides via dermal contact, inhalation or ingestion by occupational or non-occupational exposure (7). The risk of these chemicals for human health and increasing their consumptions in developed and developing societies for controlling rodents, increase the importance of replacement of these materials with other safe and biodegradable compounds.

The eco-friendly pesticide compounds, which have fewer side effects on other species including human and animals and do not pollute water and foods, have been considered in the current decade (8–10). Using degradable natural toxins is one way to save the environment. Some herbal toxins can be used as organic compounds for rodent population controls. Cotton plant, *Gossypium hirsutum*, is a common plant cultured by human. Its fiber and oil were used in textile industry and food industry, respectively (11). Cottonseed is rich in fatty acids and is a source of energy and protein for ruminant feedstuff (12). Beside various benefits of this plant, cotton plant contains a toxic pigment, gossypol. Gossypol is a yellow pigment of cotton plants and a phenolic compound in roots, stems, leaves, seeds, and flower buds of

cotton (13). Gossypol can cause anorexia, a decrease in the growth rate, labored breathing and dyspnea, which also can cause lymphocyte cytotoxicity leading to immunodeficiency and toxic hepatitis (14, 15). On the other hand, gossypol as anti-viral agent has been used for therapeutic purposes in human (16).

The male contraceptive effect of gossypol has been approved in human (17). Gossypol has high potential for crossing from gonadal barrier that increases its efficiency of antifertility in mammals (18). There are a lot of research about antifertility effect of gossypol on male animals but limited data are available about females (19). Gossypol consumption in human has more potential for inducing infertility (20). Gossypol affect male fertility by decreasing sperm motility, concentration and viability (21). In addition, decrease in serum LH, FSH and testosterone has been reported (22). Antifertility effects of gossypol on males' mammals have been reported to be dose, time and strain dependent. For example, 5–10 mg/kg daily gossypol acetic acid for 12 weeks in hamsters and rats induces complete infertility, but this amount of gossypol has no significant effect on rabbit fertility (23). Cui et al. (24) showed gossypol along with methyltestosterone and ethinyl estradiol have infertility effect by apoptosis of rat's germinal cells and can be used as contraceptive drugs for rodent's population control. In addition, ultrastructure investigating with electron microscopy showed that gossypol affect epididymal structure resulting in disruption of sperm maturation (25). In conclusion, gossypol induces infertility in male rats and other rodents such as mice and hamsters and also on humans due to oxidative stress and damage to mitochondrial, germinal layers of seminiferous tube and Sertoli cells, but its effects are reversible (21, 26).

In female mammalian, reduction of follicles number and hormonal change that affect estrous cycle as well as an increase in atretic follicle number that is responsible for infertility has been reported (22, 27). In addition, in pervious study on females, embryotoxic effect was investigated by *in vitro* and *in vivo* study and the results showed interferes of embryonic development by gossypol administration (15). Its effect on estrous cycle has been reported in some case so that it caused to prolonged diestrus. However, there is controversies about cycling changes due to gossypol consumption (22).

Chemical based rodenticides are useful initially for immediate reduction of rat's population but, as above mentioned, they are harmful. Because of low toxicity, cost effectiveness and specificity of plant materials, herbal rodenticides have more potential for pest management (28, 29). In this study, we evaluate the effect of diets containing gossypol on fertility histomorphometry and hormonal changes in male and female rats to investigate its potential for using as an eco-friendly rodenticide compound.

## Materials And Methods

### Animals and treatment

16 male and 48 female adult Sprague-Dawley rats with approximately 220 g weight were purchased from Center of Comparative and Experimental Medicine of Shiraz University of Medical Sciences. Male rats were randomly allocated into two groups (n = 8) and females were kept in two groups (control n = 32 and treatment n = 16), each group was kept in a type III polypropylene cage. All rats were housed in a room

with 12h light/dark condition cycle at temperature of  $23 \pm 1^\circ\text{C}$ . Water for all group was provided *ad libitum*. The control male and female rats had access to conventional rat pellet. The treatment male and female rats were fed by pellet containing 20% cottonseed flour. Body weight of all rats was measured every week for 35 days.

## Preparation of plate and administration

Cottonseeds were obtained from Fars province cotton farms and grinding in grinder machine, sieved with 60 mesh sieves to separate coat of cottonseeds from the shell. The shell of cottonseeds was used in plate component. Conventional rodent chew was obtained from Center of Comparative and Experimental Medicine and was grinded to become powder. For producing one kg of pellet, rodent chew flour (800 g), cottonseed shell flour (200 g) and water were mixed for 10 min, converted to pellet using a pellet making machine and dried near fans for one day. All treatment rats were fed with the cottonseed pellet for 35 days. Every week, the amount of food was measured to control each rat fed by 15 g pellet every day.

## Pregnancy test

After 35 days, control female rats ( $n = 16$ ) were mated with treatment male rats and treatment females ( $n = 16$ ) were mated with control male rats (ratio of 1 male per 2 females) for 4 days. Vaginal plug was checked every day in morning and each female that had vaginal plug, was separated from the male. After 22 days of pregnancy, the numbers of pups were recorded.

## Serum sampling and sperm analysis

After 35 days of cottonseed consumption, 8 male and 24 female rats were euthanized for sample collecting. Blood samples were collected from heart and stored in tubes and allowed to become clotted, then centrifuged at 2000 rpm for 15 min. Serum obtained was freeze in  $-70$  until hormone analysis. Left testis, epididymis and ovary were collected and fixed in 10% formalin-buffer. Right testis of each rat was collected and epididymis was dissected from testis for sperm analysis. Right dissected testis was weighed using a digital weighing scale (Acculab® ALC 210.4). Right epididymis was immediately sliced with scalpel and threw into a medium size Eppendorf tube containing 1.5 ml warmed phosphate buffered saline (PBS), then incubated in  $37^\circ\text{C}$  for 30 min. Then, some drops of the sample were set on a microscope slide and observed by a light microscope with  $40\times$  objective lens magnification to investigate sperm motility and estimate the percentage. For counting sperm, semen was diluted with PBS and set on Neubauer chamber. Five squares from central of the chamber were checked to count the number of sperm. To investigate the sperm viability, semen was stained with eosin-nigrosin solution for 30 min and set on a microscopy slide. Dead sperm (violet head) and vital sperm (unstained head) in 10 random fields of slide were counted and the viability percentage was calculated.

## Histological and histomorphometric analysis

The left testis, epididymis and ovary were fixed in formalin-buffer 10% for one month. Tissue processing was done by tissue processor machine (model DS 2080/H, DID SABZ Co, Orumieh, Iran). After tissue processing, samples were embedded in paraffin. Testis and epididymis samples were cut in  $5\ \mu\text{m}$  using

microtome and set on microscope slides. After rehydration in decreasing dilution of ethanol, they were stained with hematoxylin and eosin.

A camera (Dino-Lite®, New Taipei City, Taiwan) was set up on a light microscope. In Dino capture 2.0 (version 1.4.2.D) program the input magnification set on 725× and the objective lens was on 10× and unit set on 1 μm. For investigation of changes in spermatogenesis, some indices in seminiferous tubules were evaluated.

For the first index, lumen diameter and total diameter of five tubules per each slide were measured. Then according to the following formulas, cellular diameter, lumen area, cellular area and cross-section area were calculated.

$$\text{Cellular diameter} = (\text{total diameter} - \text{lumen diameter})/2$$

$$\text{Lumen area} = 3.142 \times (\text{lumen diameter})^2/4$$

$$\text{Cellular area} = 3.142 \times (\text{cellular diameter})^2$$

$$\text{Cross section area} = 3.142 \times (\text{total diameter})^2/4$$

Evaluation of the spermatogenesis index was performed on the basis of a modified scale of 0 to 7. For this purpose, the appearance of the spermatogenic cells throughout the seminiferous tubules was evaluated. Number of cell layers, types of cells, and the presence of late spermatids in the seminiferous tubules were considered in this index. The indices were as follows: 0, presence of no spermatogenic cells; 1, presence of only spermatogonia; 2, presence of spermatogonia and spermatocytes present; 3, spermatogonia, spermatocytes and round (early) spermatids with < 25 late spermatids per tubule; 4, presence of spermatogonia, spermatocytes, and round spermatids with up to 25–50 late spermatids per tubule; 5, presence of spermatogonia, spermatocytes, and round spermatids with up to 50–75 late spermatids per tubule; 6, presence of spermatogonia, spermatocytes, and round spermatids as well as up to 75–100 late spermatids per tubule; and 7, presence of all cell types present with > 100 late spermatids per tubule.

The last index was the number of tubules per 5×5 mm<sup>2</sup> of transverse sections of seminiferous tubules. Based on this number, the numerical density of tubules was calculated as following formula.

$$\text{Numerical density} = \text{number of profiles per unit area}/(\text{total diameter} + \text{average thickness of the section}).$$

Left ovary was processed like testis with the difference that there are 10 slices (each 20 μm thickness) between 2 histology samples. Primary follicle was presented as one-layer cuboidal granulosa cells, secondary follicle was presented with two layer of cuboidal granulosa (with or without antrum), and tertiary follicle was presented as large antrum and several layers of granulosa cells. Number of primary and secondary follicles was measured by 40x objective microscopy and every area was observed with crinkle pattern. All data were obtained by a reproductive expert with blind observation. Tertiary and corpus

luteum were measured by 10x microscopy. Area of follicle was measured by Dino capture 2.0 (version 1.4.2.D) tools. For calculating volume, we calculated radius of these area and gain circle diameter. If we suppose that 1 slice with its distance to another slice forms a cone frustum, we can use con volume equation for calculating total volume of a follicle.

$$V = \pi d^2 h / 6$$

In this equation,  $d$  is circle diameter and  $h$  is distance between 2 slices (according to our slicing pattern is 200  $\mu\text{m}$ ).

## Hormone analysis

Luteinizing hormone (LH), follicle-stimulating hormone (FSH) measured by radioimmunoassay (RIA) kit (Padyab Teb Company, Tehran, Iran). and testosterone were analysis by ELISA kit (PGI Company, Tehran, Iran). For testosterone analysis, all reagents, samples, control and standards were first prepared as instructed. Standard and control samples were added to wells. Labaled HRP-conjugate was added to each well and incubated at 37°C. Then, they were washed and TMB substrate was added to each well and incubated at room temperature. Finally, stop solution was added to wells and read immediately. For FSH and LH hormonal analysis, briefly, buffer bottle was warmed to melt and diluted with 100 mL distilled water. Other components except separating reagent were added to assay buffer and replaced stopper. Working standards were prepared as company instruction. briefly, 200  $\mu\text{L}$  assay buffer was pipetted to non-specific binding and 100  $\mu\text{L}$  was pipetted to zero standard tubes. 100  $\mu\text{L}$  antiserum was pipetted into all tubes except non-specific binding (NSB) and total count (TC) tubes and all tubes were vortexed and stored for 4 h at room temperature. Next, 100  $\mu\text{L}$  tracer was pipetted into all tubes. TC tubes were stopped and put aside for counting. For second time, all tubes were vortexed and stored overnight at room temperature. Next, 400  $\mu\text{L}$  second antibody was added to each tube except TC tube, vortexed and incubated at room temperature for 10 min. Then, all tubes were centrifuged for 10 min at 1500  $\times g$  and the supernatant was discarded. The tubes were inverted on absorbent tissues to allow them drain for 5 min. The radioactivity present in each tube was determined by counting at last 60 sec in Gamma scintillation counter (Dream GAMMA counter-5, LabLogic Company, USA) and compered with a standard curve for determining concentration of LH and FSH in samples. A standard curve for LH was drawn with Y-axis, present of Radio activity and X-axis, concentration of determinate LH. Sensitivity of LH and FSH kit was determined as 0.22 mIU/mL and 0.09 mIU/mL, respectively.

## Statistical analysis

The analysis was performed using GraphPad prism version 6 software (GraphPad software, La Jolla, USA). Means and standard error (SE) of the data of sperm analysis, weights, histomorphometry indices of seminiferous tubules, and hormone assays were subjected to Kolmogorov-Smirnov test of normality and analyzed by independent sample t-test. The post-hoc test was performed by LSD test. The spermatogenesis index of seminiferous tubules and ovary structural change indices were compared using Mann-Whitney U test. P-value less than 0.05 was considered statistically significant.

# Results

## Body weight and testis weight

Change in body weight of male and female rats and testis weight of both groups have been presented in Fig. 1. There isn't any significant change in testis and body weight in both groups. Anyway, testis and body weight of treatment group were a little less than controls.

## Number of pups per litters

Infant number of control females mated by treatment males in comparison with control females mated by control males were significantly changed. The results have been presented in Fig. 2D ( $5.6 \pm 0.8$  vs.  $8.5 \pm 0.18$  respectively,  $P = 0.004$ ).

## Sperm analysis

Sperm motility, sperm viability and sperm concentration of every rats were measured and presented in Fig. 2. Sperm motility of rats fed by cottonseed was significantly lower than control groups ( $22.5\%$  vs.  $66.25\%$  respectively;  $P < 0.05$ ). Sperm viability of treatment rats was 18% lower than control rats and sperm concentration in treatment rats was lower than controls ( $P < 0.05$ ).

## Histological data

With first histological microscopy, tubules in control group with thin layer of connective tissue surrounding the cells and normal germinal epithelium progression from spermatogonia, spermatocyte (I, II), spermatid (immature and mature), spermatozoa were observed. Normal leydig cells were seen between tubules. Sertoli cells can be seen with a little care (Fig. 3A). Hypospermatogenesis in males fed by cottonseed was easily observed (Fig. 3B). In addition, tubules seem to be stretched in treatments. Spermatozoa decreased compared to the control group (Fig. 3B). With loop microscope observation, decrease in density of tubules were easily seen (Figs. 4A and 4B).

In stereological indices, lumen diameter and lumen area in males fed by cottonseed ( $150.0 \pm 7.6 \mu\text{m}$ ,  $18843.1 \pm 1918.9 \times 10^3 \mu\text{m}^2$ , respectively) were significantly more than the males fed by normal diet ( $87.0 \pm 5.5 \mu\text{m}$ ,  $6298.2 \pm 822.5 \times 10^3 \mu\text{m}^2$ ;  $P < 0.001$ ,  $P < 0.001$ , respectively; Figs. 5A and 5B). Cellular diameter in treatment group was not more than the males fed by normal diet ( $P = 0.2$ ; Fig. 5C). Cellular area, total diameter and cross-section area in treatment group were more than the males fed by normal diet ( $P < 0.001$ ; Fig. 5D-F).

Spermatogenesis indices of seminiferous tubules in rats fed by cottonseed ( $4.0 \pm 0.1$ ) were less than the control group ( $6.5 \pm 0.1$ ) as a result of reduction in number of spermatid cells ( $P < 0.001$ ; Fig. 5G). Number of tubules per unit of testis in rats fed by cottonseed ( $3.5 \pm 0.1$ ) was less than the control group ( $5.0 \pm 0.2$ ,  $P < 0.001$ ; Fig. 5H). Numerical density of seminiferous tubules in rats fed by cottonseed was less than the control group ( $P < 0.001$ ; Fig. 5I).

On the other hand, total corpus luteum decreased in treatment group but not significant. Ovarian cyst was presence in treatment group. Number of primary follicles in rats fed by cottonseed were decreased in comparison with the control groups (3.8 vs 9.5,  $P = 0.03$ ). There was no significant decrease in number of secondary and tertiary follicles as well as corpus luteum numbers. In addition, total primary follicle volume was decreased in cottonseed fed group ( $P = 0.02$ ). Other follicle volumes did not significantly change. Ovary volume showed slightly increase in volume in group fed cottonseed. In addition, number of atretic follicles increased in treatment group ( $P < 0.05$ ; Fig. 7).

## Hormone analysis data

Testosterone and gonadotropin hormone's change in both groups were presented in Fig. 8. Level of serum testosterone in rats fed by cottonseed showed a higher value than the control group ( $2.0 \pm 0.4$  vs.  $1.3 \pm 0.2$ , respectively;  $P = 0.2$ ). Serum gonadotropin hormone and LH in treatment rats ( $2.35 \pm 0.76$ ) were higher than the control ( $0.9 \pm 0.3$ ,  $P = 0.09$ ). Treatment FSH ( $0.9 \pm 0.2$ ) was lower than the controls ( $1.3 \pm 0.3$ ,  $P = 0.2$ ).

## Discussion

In this study, we evaluated consumption of cottonseed flour (16 g per day) on fertility changes in male and female rats. Deleterious effect of gossypol on fertility of male mammals has been widely reported in the literature. In this study, testis weight and body weight in two group was similar and all rats have their normal appetite during the experiments that shown this amount of cottonseed haven't enough gossypol to have toxicity effect on growth. Singla et al. (19) used cottonseed oil for investigating its effect on rats. Their results showed cottonseed oil consumption in appropriate dose had not any effect on body weight of animals (19). It seems that higher dose of this plant could affect body weight of rats due to changes on bait's taste. In addition, there isn't any clinical sign of gossypol toxicity like diarrhea, dehydration and distended abdomens in this research.

Significant decrease in number of pups per litters is the result of subfertility in males and females because of decrease of number of primary follicle and alter estrus cycle, sperm concentration and motility. Sperm motility is an important factor, which is affected by gossypol due to inhibition of the ATPase activity in the spermatozoa (30) and reduction of mitochondrial activity (31). Serum testosterone and LH level increased in cottonseed group but there was not statistically significant. Other studies showed that intra peritoneal administration of gossypol reduced testosterone level (21, 22). It seems that administration route could affect content of gossypol reached to sexual organs. Correspondingly, in our study, we used whole cottonseed flour, so there are some other ingredients in cottonseed flour that may increase testosterone and LH level in serum.

Anyway, despite of rise in testosterone level, subfertility effect was seen and also sperm concentration was decreased, so infertility effect of gossypol is more because of spermatogenesis dysfunction and sperm motility disorder. According to this, a decrease in the sperm concentration is not just because of reduction of testosterone and it has some other reasons that can reduce it by gossypol. Due to

suggestion of other studies (32–34), sperm concentration decreased by damage of germ cell and shedding immature spermatid in epididymis and seminiferous tubule or directly attaching of gossypol to membrane of seminiferous tubule and following by facilitating the cell destruction through increase fragility of membrane in the testis. However, the other research stated that a decrease in the sperm concentration is due to a decrease in the serum testosterone (35). Depletion of spermatogenic cell in seminiferous tubule, histopathology investigation shows main toxicity effect of gossypol that previously reported (36). In a study conducted by Saleh et al. (37), gossypol acetate intra peritoneal administration in male rats significantly reduced the semen quality as evidenced by the decrease in the sperm count and motility. Moreover, it has been reported that it changed the morphology of sperm and inhibited the  $\alpha$ -glucosidase activity in gossypol group. Activity of  $\alpha$ -glucosidase is widely used as an indicative marker for sperm count, so low level of this enzyme indicates epididymal obstruction (37). In addition, it's clear that gossypol can affect spermatogonia cells and results in depletion of all cells in seminiferous tubules.

Gossypol inhibits spermatogenesis by impairing sperm motility with specific mitochondrial injury of the sperm tail (38) and decreasing concentration of semen (21). Gossypol can reduce cellular and microtubular  $\beta$ -tubular content in spermatocytes and spermatids (39). Another effect of gossypol is spermatozoid disturbance mechanism including the inhibition of release and utilization of ATP by the sperm cells (40). In a study conducted by Santana et al. (41), gossypol acetic acid was administrated by gastric gavage in male rats for investigation their infertility mechanism. They concluded that gavage administration of 5 mg/kg body weight of gossypol acetic acid could induce subfertility in male rats (41). They reported that the major mechanism of inducing infertility by gossypol is inhibition of sperm production and motility due to dramatic drop in the production of mitochondrial ATP (41). Furthermore, gossypol induces oxidative stress by increasing the formation of ROS and lipid peroxides, that affect plasma membrane permeability, ATPase activity, and glucose transport in sperms (42). In addition, gossypol inhibits Mg-ATPase and Ca-Mg-ATPase activity and calcium influx (31, 43) in spermatozoid plasmatic membranes (31). Infertility is the inability to conceive due to low semen quality that can cause by negative effect of cytotoxic component on spermatogenesis (44), so, it was resulted that cottonseed flour consumption could alter fertility in male rats.

Female rats fed cottonseed have body weight as same as females of the control group. The ovary volume was slightly higher than that of the control group. Hormonal analysis showed higher LH and lower FSH hormone. Other studies reported hormonal changes during gossypol administration. Lin et al. (45) reported that progesterone level was reduced in female rats that received 25 mg/kg gossypol via intramuscular injection. In vitro studies reported that gossypol consumption could inhibit progesterone level secretion level in luteal cells (46).

Histomorphometry analysis showed reduction of primary follicle number and volume. FSH reduction could alter the follicular maturation and reduce the follicular number. This can cause temporary infertility. The primordial follicle is fixed at the time of birth and stopping diets containing gossypol could return fertility. The reduction of follicle has been reported in previous research on sheep, rats and mouse ovaries (22, 27). Furthermore, atretic follicle number was higher in treatment group, atretic follicle characterized

as discontinuous basement membrane, retracted oocyte, pyknotic nucleus and disorganized granulosa cells. Study conducted by Gadelha et al. (47), showed laying hens fed by cottonseed had more atretic follicles at all stages of development. The mechanism of ovarian toxicity of gossypol has not been fully understood, but may be due to cytotoxic and apoptotic activities. Embryonic changes have been reported in few literatures. Louvandini et al. (48) and Jimenez et al. (49) reported gossypol can effect on male lambs of pregnant female sheep fed by cottonseed. They reported that male lambs showed significant lower growth and lower testis weight as a proportion of the total body weight, and reduced lower testosterone level than female rats (48, 49).

## **Conclusions**

In this study, it was showed that using cottonseed flour as a source of gossypol instead of gossypol acetic acid or other sources of gossypol such as cottonseed oil can induce infertility without toxic effects on body weight and has potential for using as a cheap and environment friendly contraception material. Gossypol could alter spermatogenesis and reduce sperm motility and viability in male rats. In addition, it can reduce follicular number in female rat and alter hormonal level. Moreover, it was demonstrated that cottonseed flour consumption in an appropriate daily dose could affect reproduction in male and female rats and it could be used as an effective contraceptive diet for rodent and to replace chemical rodenticide products.

## **Declarations**

## **Ethics approval and consent to participate**

This investigation was performed in accordance with relevant guidelines and regulations of animal studies of Ethical Committee of Shiraz University of Medical Sciences.

## **Consent for publication**

Not applicable.

## **Availability of data and material**

The data used to support the findings of this study are included within the article.

## **Funding**

This work was financially supported by grant of the Entrepreneurship Center of Shiraz University and vice chancellor for research and technology of Shiraz University of Medical Sciences.

# Competing interests

Author Fariborz Nowzari was employed by the company Arka Co. The remaining authors declare that the research was conducted in the absence of any commercial or financial relationships that could be construed as a potential conflict of interest.

# Authors' contributions

A.T., F.R., and N.T. conceived and designed the format of the manuscript. F.N., M.R.D., N.T. and F.R. collected the data, and drafted and edited the manuscript. A.T. drew the Figures. All the authors reviewed the manuscript and all of them contributed to the critical reading and discussion of the manuscript. All authors have read and agreed to the published version of the manuscript.

# Acknowledgments

Not applicable.

# References

1. Panti-May JA, Sodá-Tamayo L, Gamboa-Tec N, Cetina-Franco R, Cigarroa-Toledo N, Machaín-Williams C, et al. Perceptions of rodent-associated problems: an experience in urban and rural areas of Yucatan, Mexico. *Urban Ecosystems*. 2017;20(5):983-8.
2. Walther B, Geduhn A, Schenke D, Schlötelburg A, Jacob J. Baiting location affects anticoagulant rodenticide exposure of non-target small mammals on farms. *Pest Management Science*. 2021;77(2):611-9.
3. Sugunan S, Krishnan R, Kumar KS, Geetha S. Rodenticide poisoning in children: A study of clinical profile and electrocardiographic changes. *Indian Journal of Child Health*. 2017;4(2):136-9.
4. Hill III T, Nelms MD, Edwards SW, Martin M, Judson R, Corton JC, et al. Editor's highlight: Negative Predictors of carcinogenicity for environmental chemicals. *Toxicological Sciences*. 2017;155(1):157-69.
5. Jeephet K, Kamsa-Ard S, Bhudhisawasdi V, Kamsa-Ard S, Luvira V, Luvira V. Association between pesticide use and cholangiocarcinoma. *Asian Pacific Journal of Cancer Prevention*. 2016;17(8):3979-82.
6. Ou Y, Mai J, Zhuang J, Liu X, Wu Y, Gao X, et al. Risk factors of different congenital heart defects in Guangdong, China. *Pediatric research*. 2016;79(4):549-58.
7. VoPham T, Bertrand KA, Hart JE, Laden F, Brooks MM, Yuan J-M, et al. Pesticide exposure and liver cancer: a review. *Cancer Causes & Control*. 2017;28(3):177-90.

8. Govindarajan M, Rajeswary M, Hoti S, Bhattacharyya A, Benelli G. Eugenol,  $\alpha$ -pinene and  $\beta$ -caryophyllene from *Plectranthus barbatus* essential oil as eco-friendly larvicides against malaria, dengue and Japanese encephalitis mosquito vectors. *Parasitology research*. 2016;115(2):807-15.
9. Kedia A, Prakash B, Mishra PK, Singh P, Dubey NK. Botanicals as eco friendly biorational alternatives of synthetic pesticides against *Callosobruchus* spp.(Coleoptera: Bruchidae)—a review. *Journal of Food Science and Technology*. 2015;52(3):1239-57.
10. Zhang C, Qu Y, Wu X, Song D, Ling Y, Yang X. Eco-friendly insecticide discovery via peptidomimetics: Design, synthesis, and aphicidal activity of novel insect kinin analogues. *Journal of agricultural and food chemistry*. 2015;63(18):4527-32.
11. Soto-Blanco B. Gossipol e fatores antinutricionais da soja. *Toxicologia Aplicada à Veterinária Manole, São Paulo*. 2008:531-45.
12. Rico J, de Souza J, Allen M, Lock A. Nutrient digestibility and milk production responses to increasing levels of palmitic acid supplementation vary in cows receiving diets with or without whole cottonseed. *Journal of animal science*. 2017;95(1):436-46.
13. Tian X, Ruan J, Huang J, Fang X, Mao Y, Wang L, et al. Gossypol: phytoalexin of cotton. *Science China Life Sciences*. 2016;59(2):122-9.
14. Xu W-b, Xu L-h, Lu H-s, Ou-Yang D-y, Shi H-j, Di J-f, et al. The immunosuppressive effect of gossypol in mice is mediated by inhibition of lymphocyte proliferation and by induction of cell apoptosis. *Acta Pharmacologica Sinica*. 2009;30(5):597-604.
15. Gadelha ICN, Fonseca NBS, Oloris SCS, Melo MM, Soto-Blanco B. Gossypol toxicity from cottonseed products. *The Scientific World Journal*. 2014;2014.
16. Keshmiri-Neghab H, Goliaei B. Therapeutic potential of gossypol: an overview. *Pharmaceutical biology*. 2014;52(1):124-8.
17. Lim W, Ham J, Park S, Bae H, You S, Song G. Gossypol induces disruption of spermatogenesis and Steroidogenesis in male mice. *Journal of agricultural and food chemistry*. 2019;67(7):2075-85.
18. Dabrowski K, Rinchar J, Lee K, Blom J, Ciereszko A, Ottobre J. Effects of diets containing gossypol on reproductive capacity of rainbow trout (*Oncorhynchus mykiss*). *Biology of reproduction*. 2000;62(2):227-34.
19. Singla N, Garg M. Effect of crude cottonseed oil containing gossypol on fertility of male and estrous cycle of female *Bandicota bengalensis* Gray and Hardwicke. *Journal of Applied Animal Research*. 2013;41(2):156-65.
20. Coutinho EM. Gossypol: a contraceptive for men. *Contraception*. 2002;65(4):259-63.
21. El-Sharaky A, Newairy A, Elguindy N, Elwafa A. Spermatotoxicity, biochemical changes and histological alteration induced by gossypol in testicular and hepatic tissues of male rats. *Food and Chemical Toxicology*. 2010;48(12):3354-61.
22. Gadelha ICN, Fernandes de Macedo M, Oloris SCS, Melo MM, Soto-Blanco B. Gossypol promotes degeneration of ovarian follicles in rats. *The Scientific World Journal*. 2014;2014.

23. Chang M, Gu Z, Saksena S. Effects of gossypol on the fertility of male rats, hamsters and rabbits. *Contraception*. 1980;21(5):461-9.
24. Cui G-H, Xu Z-L, Yang Z-J, Xu Y-Y, Xue S-P. A combined regimen of gossypol plus methyltestosterone and ethinylestradiol as a contraceptive induces germ cell apoptosis and expression of its related genes in rats. *Contraception*. 2004;70(4):335-42.
25. de Andrade SF, Oliva SU, Klinefelter GR, De Grava Kempinas W. Epididymis-specific pathologic disorders in rats exposed to gossypol from weaning through puberty. *Toxicologic pathology*. 2006;34(6):730-7.
26. Hassan ME, Smith GW, Ott RS, Faulkner DB, Firkins LD, Ehrhart E, et al. Reversibility of the reproductive toxicity of gossypol in peripubertal bulls. *Theriogenology*. 2004;61(6):1171-9.
27. Câmara ACL, Gadelha ICN, Borges PAC, de Paiva SA, Melo MM, Soto-Blanco B. Toxicity of gossypol from cottonseed cake to sheep ovarian follicles. *PLoS One*. 2015;10(11):e0143708.
28. Dubey N, Srivastava B, Kumar A. Current status of plant products as botanical pesticides in storage pest management. *Journal of biopesticides*. 2008;1(2):182-6.
29. Singh J, Mirza A. Natural Biological Products from Plants as Rodenticides. *Natural Bioactive Products in Sustainable Agriculture*: Springer; 2020. p. 235-57.
30. Kalla NR, Vasudev M. Studies on the male antifertility agent-Gossypol acetic acid. II. Effect of gossypol acetic acid on the motility and ATPase activity of human spermatozoa. *Andrologia*. 1981;13(2):95-8.
31. Breitbart H, Rubinstein S, Nass-Arden L. Effect of gossypol-acetic acid on calcium transport and ATPase activity in plasma membranes from ram and bull spermatozoa. *International journal of andrology*. 1984;7(5):439-47.
32. Ali IN, Fakhrildin MBM, Al-Obaidi SA. EFFECT OF AQUEOUS AND ALCOHOLIC EXTRACTS OF COTTONSEED ON SOME PARAMETERS OF SPERMS AND REPRODUCTIVE PERFORMANCE OF ALBINO MICE. *Al-Nahrain Journal of Science*. 2010;13(4):151-8.
33. Amini A, Kamkar F. The effects of gossypol on spermatogenesis in NMRI mice. *Iranian Journal of Science and Technology (Sciences)*. 2005;29(1):123-33.
34. Farrag AK, Ismail HI, Khalifa EA, El-Gamal MM. The possible synergistic effect of gossypol (cottonseed oil) and *Schistosomiasis mansoni* on the male reproductive organs in experimenting infected mice. *Tanta Medical Sci J*. 2007;2(1):78-91.
35. Matsumoto AM. Effects of chronic testosterone administration in normal men: safety and efficacy of high dosage testosterone and parallel dose-dependent suppression of luteinizing hormone, follicle-stimulating hormone, and sperm production. *The Journal of Clinical Endocrinology & Metabolism*. 1990;70(1):282-7.
36. da Silva KM, Zart AL, Brum KB, dos Santos Fernandes CE. Histopathological and histomorphometric testicular characteristics associated to reproductive condition in *Bos indicus* (Nellore) bulls. *Semina: Ciências Agrárias*. 2015;36(1):1935-44.

37. Saleh SR, Attia R, Ghareeb DA. The ameliorating effect of berberine-rich fraction against gossypol-induced testicular inflammation and oxidative stress. *Oxidative medicine and cellular longevity*. 2018;2018.
38. Akinola O, Dosunmu O, Dini L, Ajayi S. Proteinaceous diet inhibits gossypol-induced spermatotoxicity. *European Journal of Histochemistry*. 2006:205-8.
39. Teng O. Reversible changes in the content of cellular and microtubular tubulin in spermatogenic cells after gossypol treatment. *Contraception*. 1997;55(3):183-8.
40. Ueno H, Sahni MK, Segal SJ, Koide S. Interaction of gossypol with sperm macromolecules and enzymes. *Contraception*. 1988;37(3):333-41.
41. Santana AT, Guelfi M, Medeiros HC, Tavares MA, Bizerra PF, Mingatto FE. Mechanisms involved in reproductive damage caused by gossypol in rats and protective effects of vitamin E. *Biological research*. 2015;48(1):1-8.
42. El-Mokadem M, Taha T, Samak M, Yassen A. Alleviation of reproductive toxicity of gossypol using selenium supplementation in rams. *Journal of Animal Science*. 2012;90(9):3274-85.
43. Breitbart H, Mayevsky A, Nass-Arden L. Molecular mechanisms of gossypol action on sperm motility. *The International journal of biochemistry*. 1989;21(10):1097-102.
44. Panahi M, Karimaghai N, Rahmanifar F, Tamadon A, Vahdati A, Mehrabani D, et al. Stereological evaluation of testes in busulfan-induced infertility of hamster. *Comparative Clinical Pathology*. 2015;24(5):1051-6.
45. Lin YC, Fukaya T, Rikihisa Y, Walton A. Gossypol in female fertility control: ovum implantation and early pregnancy inhibited in rats. *Life Sciences*. 1985;37(1):39-47.
46. Lin Y, Coskun S, Sanbuissho A. Effects of gossypol on in vitro bovine oocyte maturation and steroidogenesis in bovine granulosa cells. *Theriogenology*. 1994;41(8):1601-11.
47. Gadelha I, Lima M, Melo M, Soto-Blanco B. Gossypol promotes the degeneration of chicken ovarian follicles in vitro. *Brazilian Journal of Poultry Science*. 2016;18(3):505-10.
48. Louvandini H, Corrêa PS, Amorín R, Liu L, Ieda EH, Jimenez CR, et al. Gestational and lactational exposure to gossypol alters the testis transcriptome. *BMC genomics*. 2020;21(1):1-11.
49. Jimenez CR, Moretti DB, da Silva TP, Corrêa PS, da Costa RLD, Mui TS, et al. Cottonseed (gossypol) intake during gestation and lactation does affect the ovarian population in ewes and lambs? *Research in Veterinary Science*. 2020.

## Figures

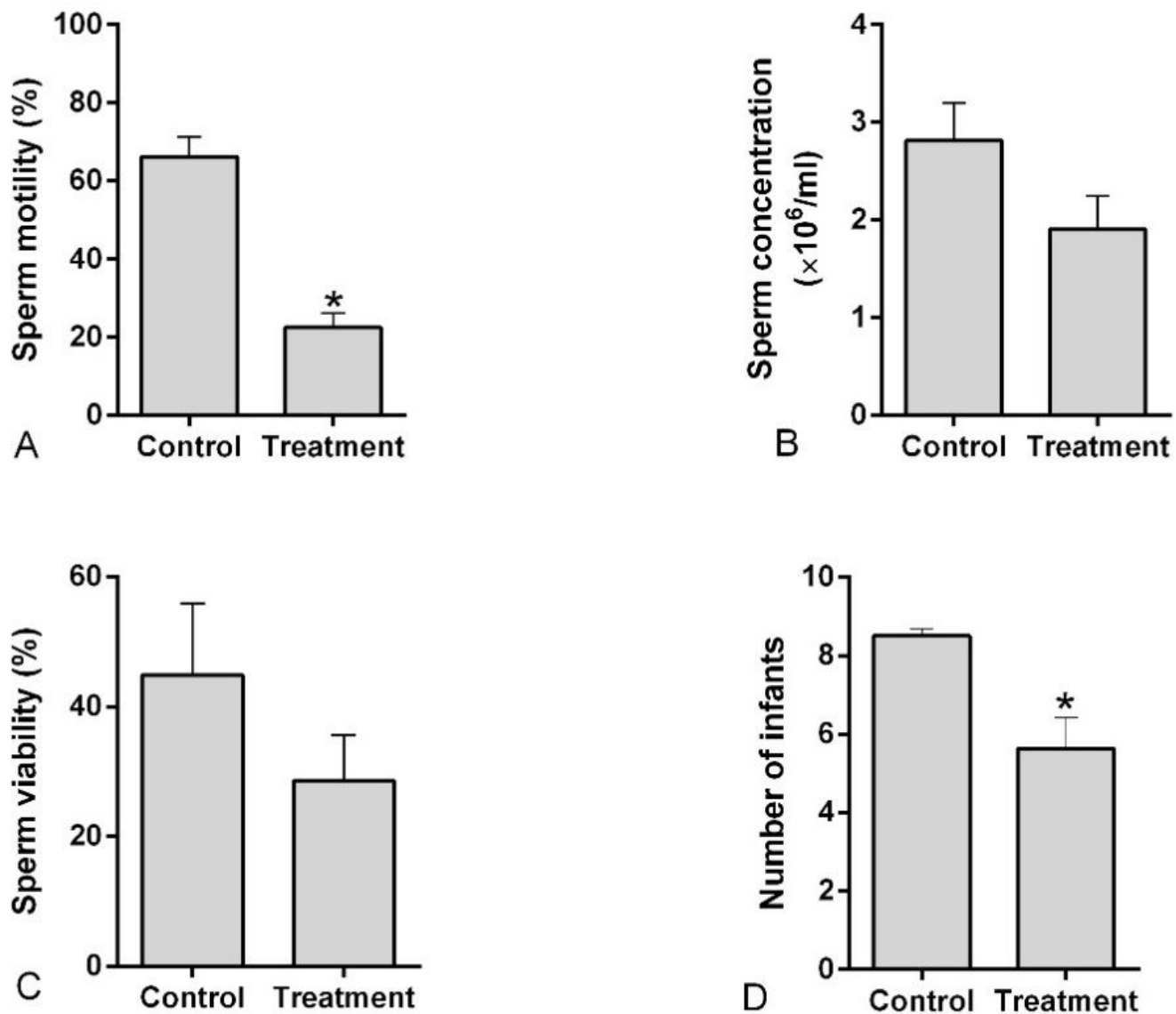
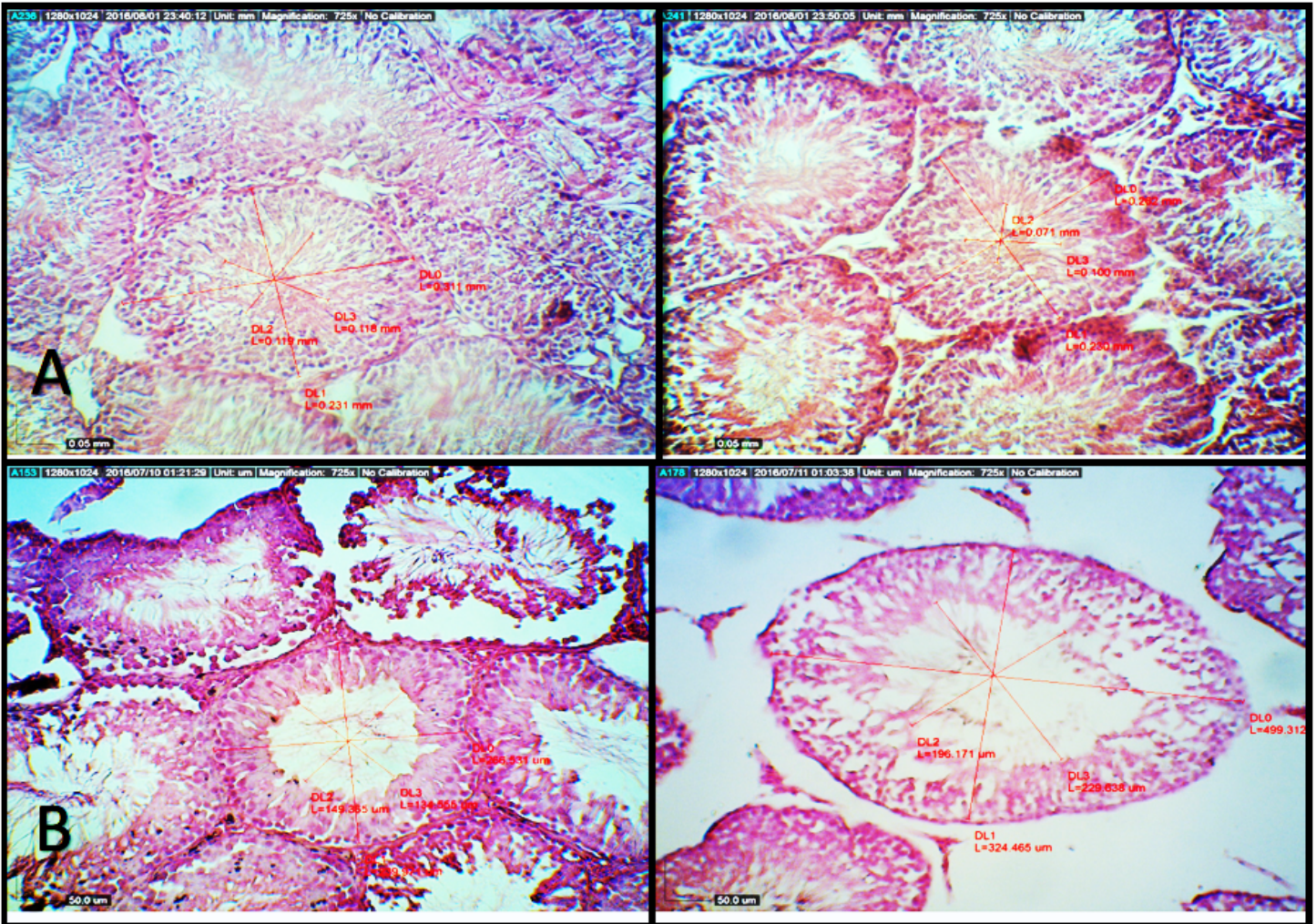


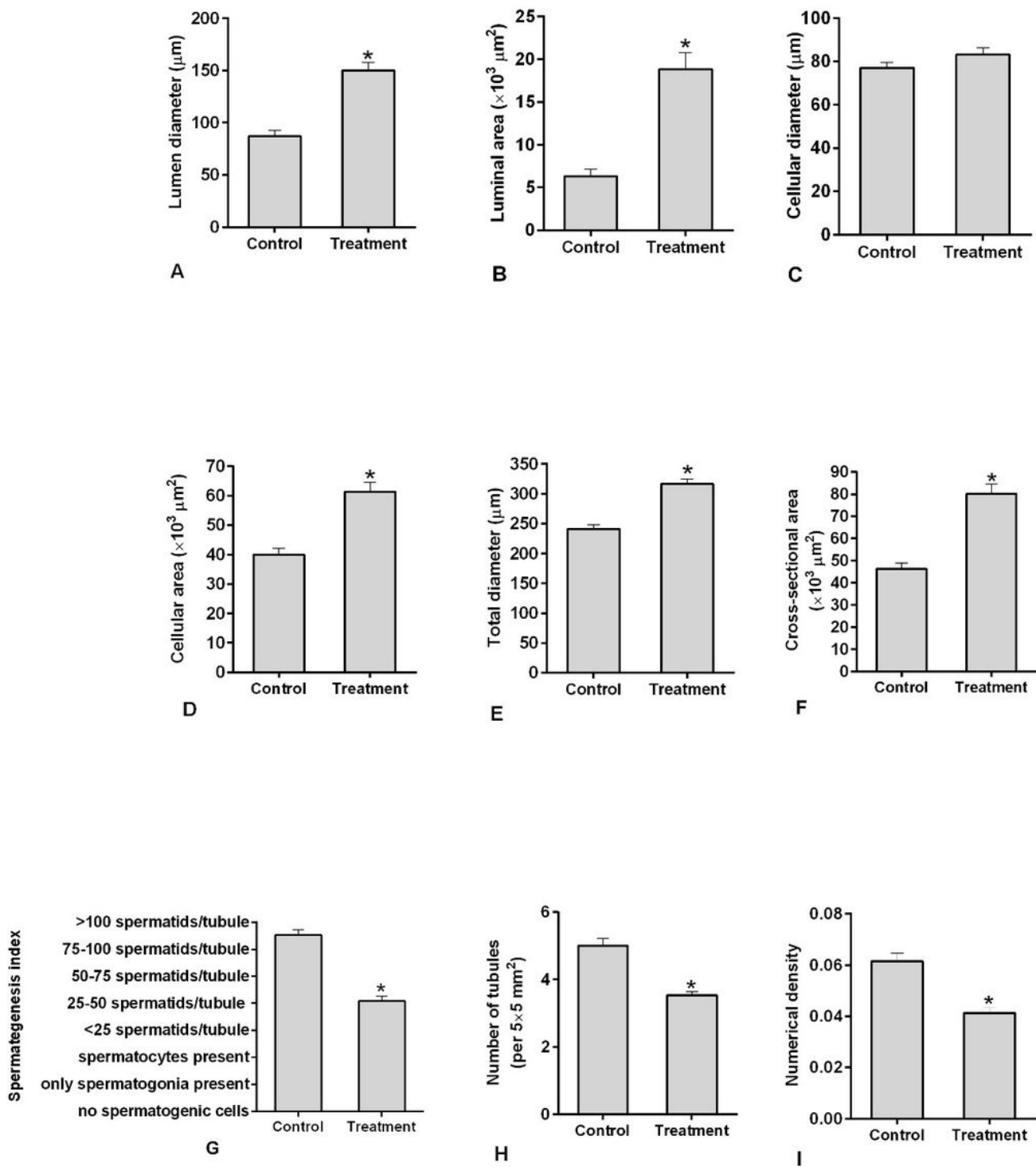
Figure 1

Mean and standard error of Testis weight (A) and body weight (B) of male control and treatment groups and female control and treatment groups (C).



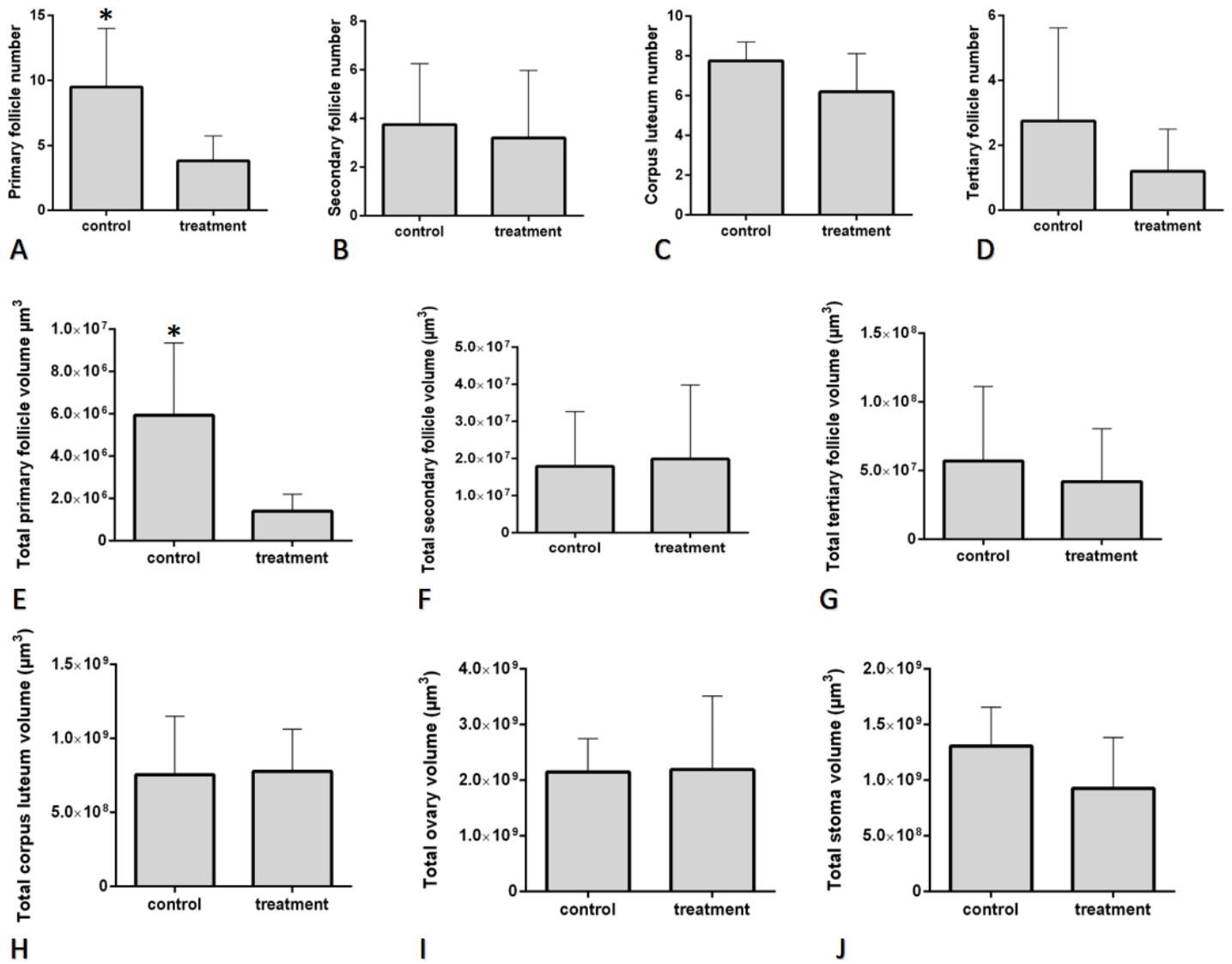
**Figure 2**

Mean and standard error of sperm analysis and number of infants in control and treatments groups. A) Sperm motility (%), B) Sperm concentration ((10)<sup>6</sup> /ml), C) Sperm viability (%), D) Number of infants. Star (\*) show significant difference between control and treatment groups.



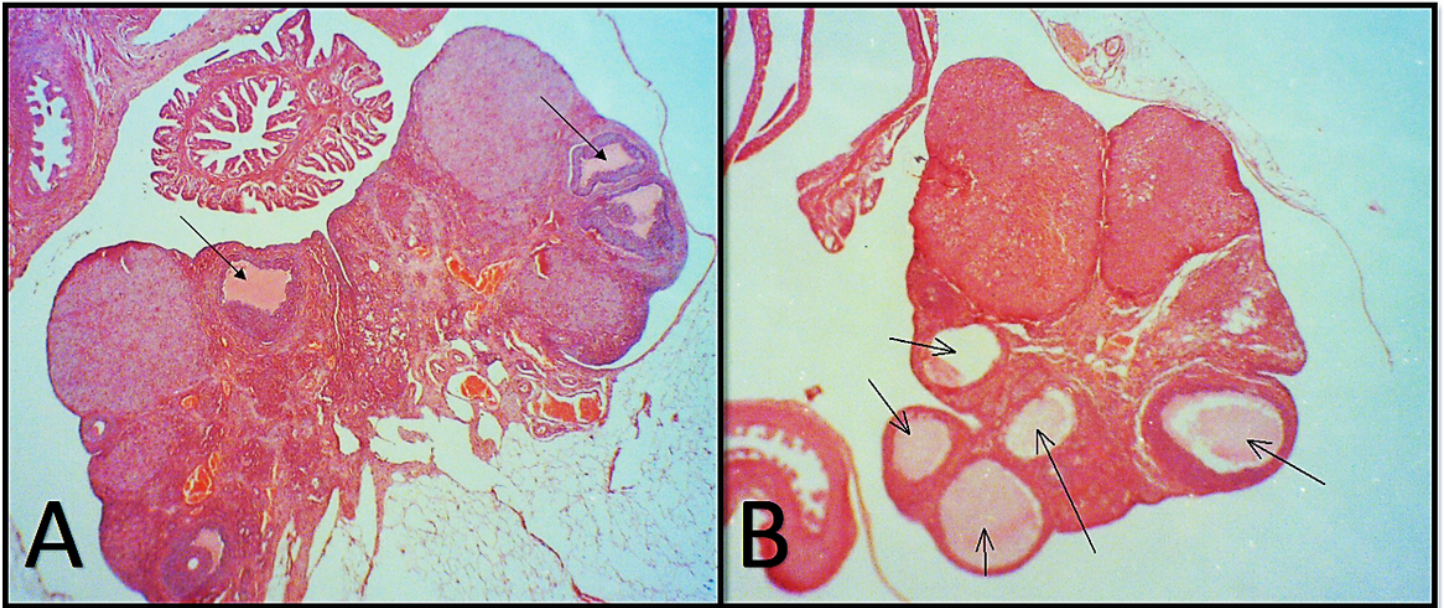
**Figure 3**

Section of testes showing seminiferous tubule. H&E staining. Control (A) and treatments group (B) with 100x magnification. Scale bars are 50  $\mu\text{m}$ .



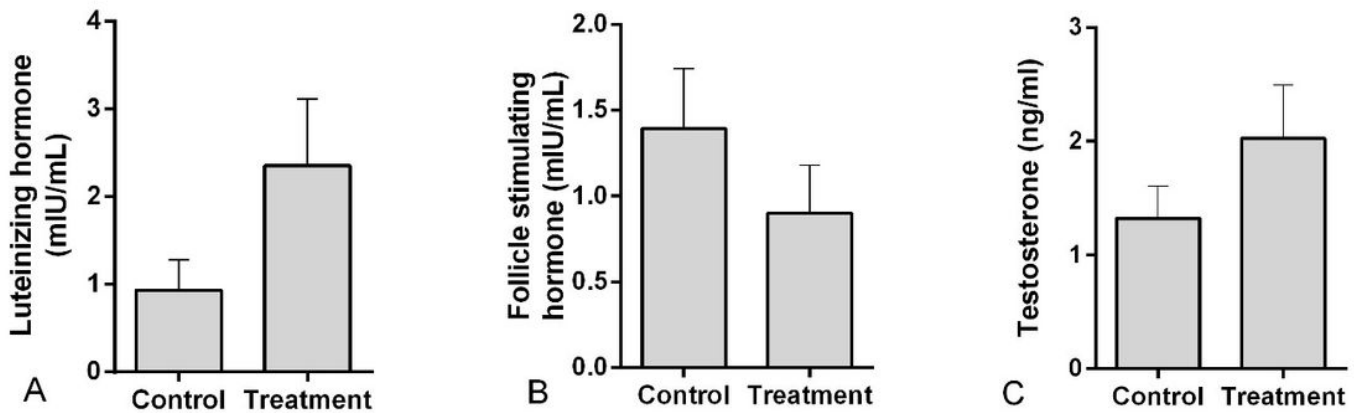
**Figure 4**

Cross-section of testes showing whole seminiferous tubule with loop microscopy 30x magnification. H&A staining. Control group (A) and treatment group (B).



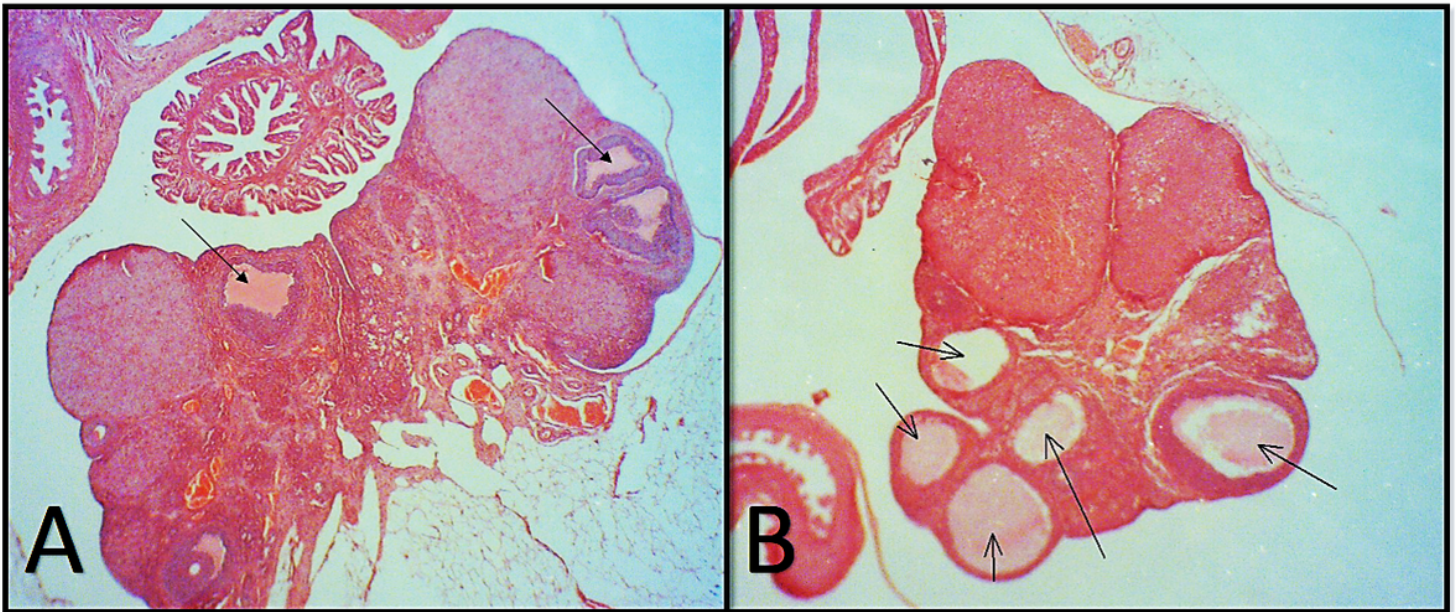
**Figure 5**

Mean and standard error of stereological indices And spermatogenesis index of control and treatment group. A) lumen diameter ( $\mu\text{m}$ ), B) lumen area ( $\mu\text{m}^2$ ), C) cellular diameter ( $\mu\text{m}$ ), D) cellular area ( $\mu\text{m}^2$ ), E) total diameter ( $\mu\text{m}$ ), F) cross-section area ( $\mu\text{m}^2$ ), H) number of tubules per unit area of testis, I) numerical density of seminiferous tubules, G) spermatogenesis index Star (\*) show significant difference between control group and group fed by cottonseed.



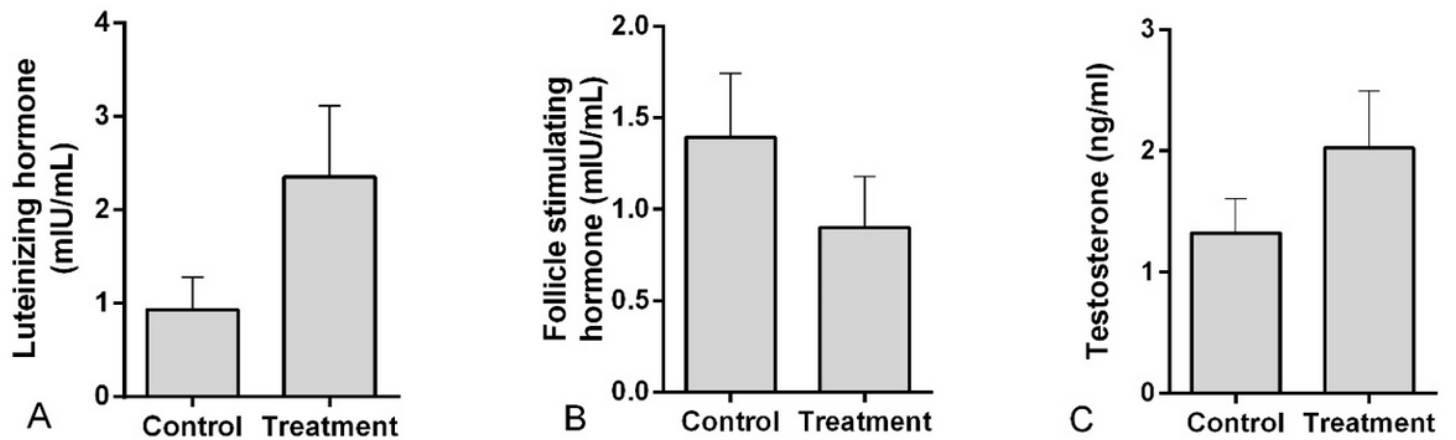
**Figure 6**

Mean and standard error of ovary index of control and treatment group. A) primary follicle number, B) secondary follicle number, C) tertiary follicle number, D) corpus luteum number, E) total primary follicle volume ( $\mu\text{m}^3$ ), F) total secondary follicle volume ( $\mu\text{m}^3$ ), G) total tertiary follicle volume ( $\mu\text{m}^3$ ), H) total corpus luteum volume ( $\mu\text{m}^3$ ), I) total ovary volume ( $\mu\text{m}^3$ ), J) total stroma volume ( $\mu\text{m}^3$ ). Star (\*) show significant difference between control group and group fed by cottonseed.



**Figure 7**

Cross section of ovary showing whole ovary with loop microscopy 30X magnification. H&A staining. Control group (A) and treatment group (B). notice to atretic follicle in both groups



**Figure 8**

Mean and standard error of hormone serum in control and treatment group. A) Luteinizing hormone (mIU/mL), B) Follicle stimulating hormone (mIU/mL), C) Testosterone (ng/ml).