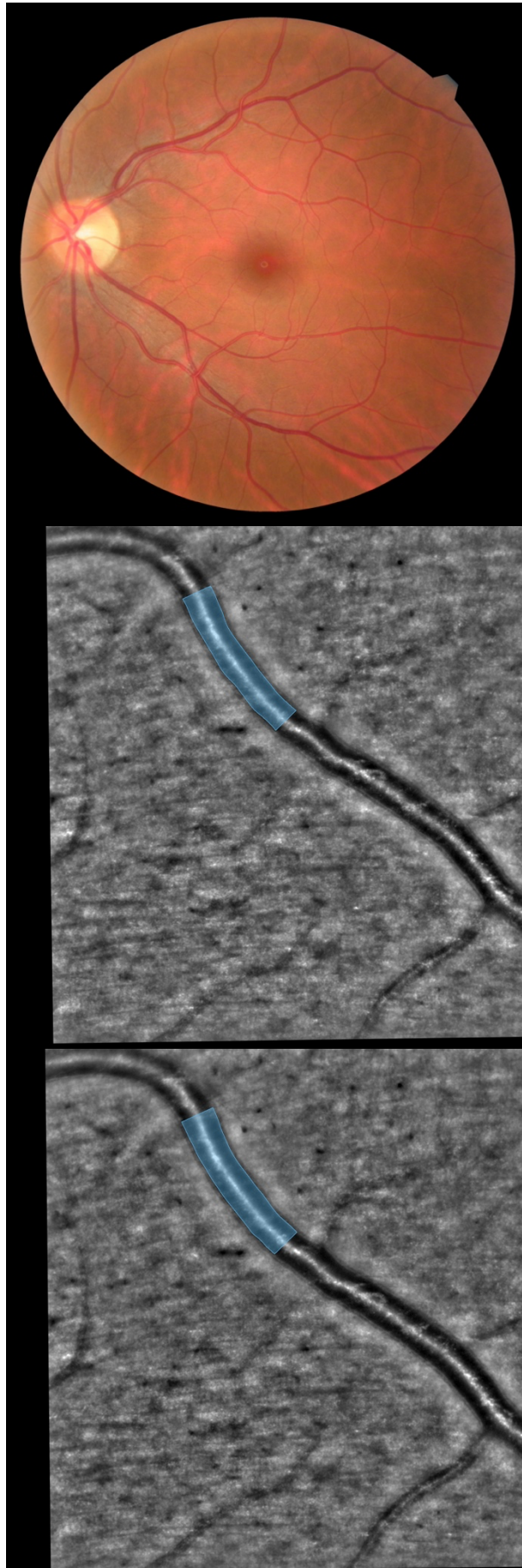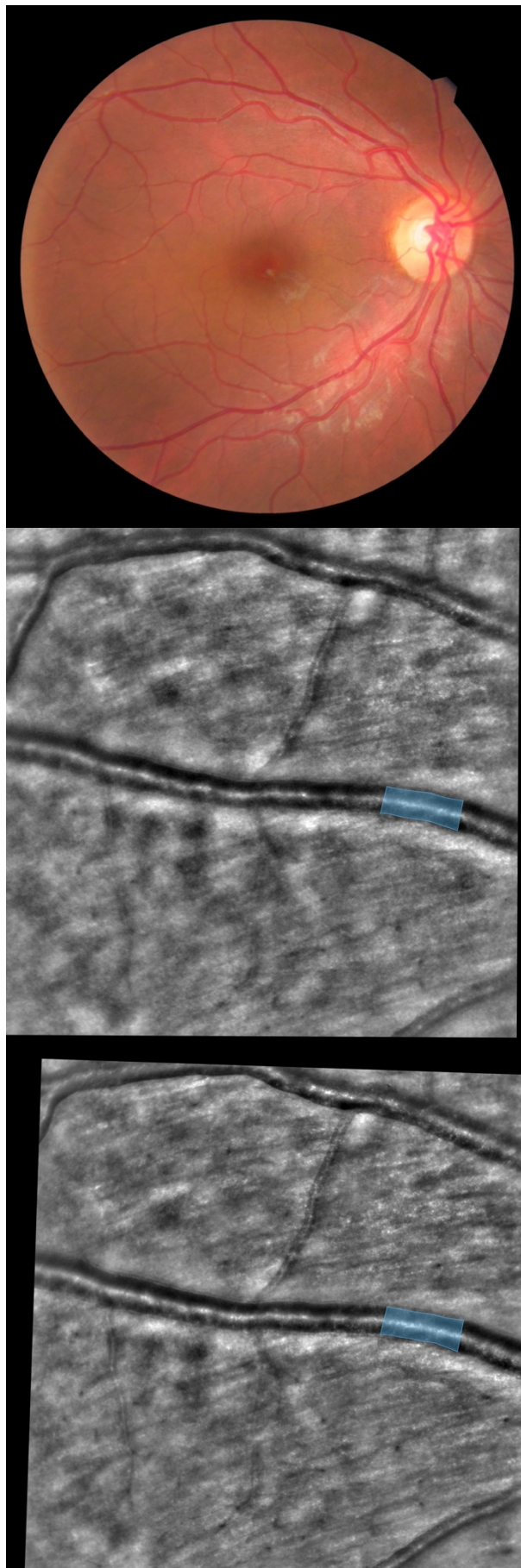
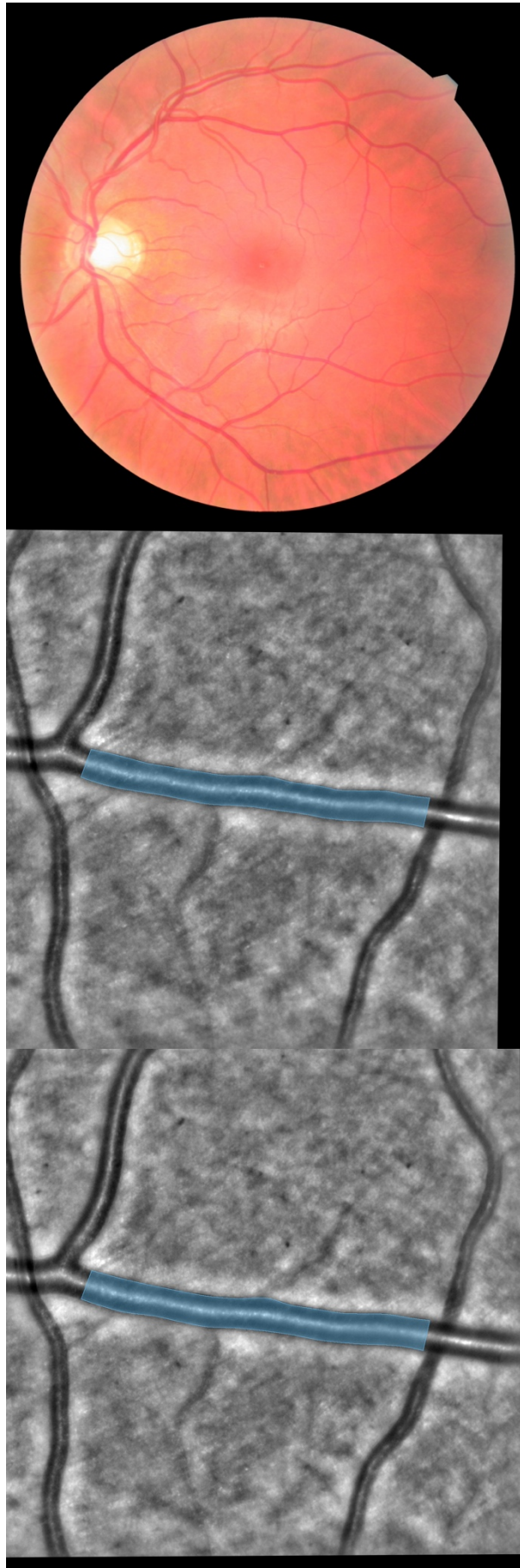


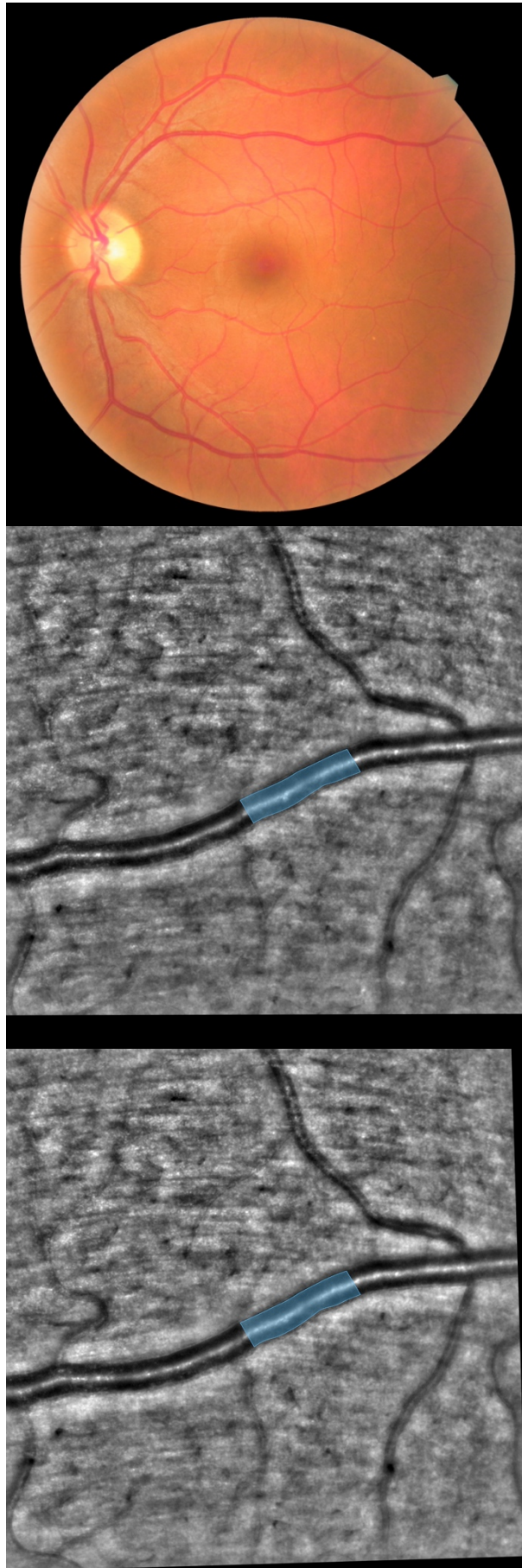
Healthy control's left eye (HC03 case). Top: Color fundus photography. Middle: rtx1 fundus after contralateral photic stimulation. Right: rtx1 fundus after ipsilateral photic stimulation.



Healthy control's right eye (HC08 case). Top: Color fundus photography. Middle: rtx1 fundus after contralateral photic stimulation. Right: rtx1 fundus after ipsilateral photic stimulation.



Diabetic patient's left eye (DM02 case). Top: Color fundus photography. Middle: rtx1 fundus after contralateral photic stimulation. Right: rtx1 fundus after ipsilateral photic stimulation.



Diabetic patient's left eye (DM04 case). Top: Color fundus photography. Middle: rtx1 fundus after contralateral photic stimulation. Right: rtx1 fundus after ipsilateral photic stimulation.