Research Square

Preprints are preliminary reports that have not undergone peer review.
They should not be considered conclusive, used to inform clinical practice,
or referenced by the media as validated information.

NIPBL::NACC1 Fusion Hepatic Carcinoma Comprehensive Clinicopathologic and Genomic Characterization with Prognostic and Therapeutic Implications

JESUS DELGADO DE LA MORA
Weill Cornell Medicine https://orcid.org/0000-0003-4188-2989

Majd Al Assaad
Weill Cornell Medicine https://orcid.org/0000-0002-9512-0253

Xiaofei Wang
Weill Cornell Medicine

Eda Nur Kozan
Weill Cornell Medicine https://orcid.org/0000-0001-8363-5068

Alissa Seeman
Weill Cornell Medicine

Kathryn Gorski
Weill Cornell Medicine https://orcid.org/0009-0005-6277-9691

Sam P. Gulino
Children's National Health System https://orcid.org/0009-0009-5343-9723

Max F. Levine
isabl, Inc

Julianne Szczepanski
University of Michigan–Ann Arbor https://orcid.org/0000-0002-5687-9857

Maria Westerhoff
University of Michigan–Ann Arbor https://orcid.org/0000-0002-3094-0111

Erika Patel
Weill Cornell Medicine https://orcid.org/0009-0007-5916-8106

Andrea Sboner
Weill Cornell Medicine https://orcid.org/0000-0001-6915-3070

Olivier Elemento
Weill Cornell Medicine https://orcid.org/0000-0002-8061-9617

Amitabh Srivastava
Memorial Sloan Kettering Cancer Center https://orcid.org/0000-0001-5165-8142

Carlie Sigel
Memorial Sloan Kettering Cancer Center https://orcid.org/0000-0001-6276-3968

Jinru Shia
Memorial Sloan Kettering Cancer Center https://orcid.org/0000-0002-4351-2511
José Jessurun
Weill Cornell Medicine https://orcid.org/0000-0002-1692-9880
Juan Miguel Mosquera
jmm9018@med.cornell.edu
Weill Cornell Medicine https://orcid.org/0000-0003-4666-6476

Research Article

Keywords: NIPBL:NACC1 fusion, primary hepatic carcinoma, inhibin, gene fusion, liver neoplasms

Posted Date: November 24th, 2026

DOI: https://doi.org/10.21203/rs.3.rs-11813860/v1

License: This work is licensed under a Creative Commons Attribution 4.0 International License.
Read Full License

Additional Declarations: The authors declare potential competing interests as follows: M.F.L. is an employee of Isabl, Inc. The remaining authors declare no conflicts of interest.

NIPBL::NACC1 Fusion Hepatic Carcinoma

Comprehensive Clinicopathologic and Genomic Characterization with Prognostic and Therapeutic Implications

Jesus Delgado-de la Mora, MD [1,2], Majd Al Assaad, MD [1,2], Xiaofei Wang, PhD [2,3], Eda Nur Kozan, MD [1,2], Alissa Seeman, MS [1,2], Kathryn Gorski, MS [2,3], Sam P. Gulino, MD [4], Max F. Levine, MS [5], Julianne Szczepanski, MD [6], Maria Westerhoff, MD [6], Erika Patel, MD[1], Andrea Sboner, PhD [1,2,3], Olivier Elemento, PhD [2,3], Amitabh Srivastava, MBBS [7], Carlie Sigel, MD [7], Jinru Shia, MD [7], José Jessurun, MD [1], Juan Miguel Mosquera, MD, MSc [1,2*]

[1] Department of Pathology and Laboratory Medicine, Weill Cornell Medicine, New York, NY;

[2] Englander Institute for Precision Medicine, Weill Cornell Medicine, New York, NY;

[3] Institute for Computational Biomedicine, Weill Cornell Medicine, New York, NY;

[4] Division of Pathology & Laboratory Medicine, Children's National Hospital, Washington, DC;

[5] Isabl, Inc., New York, NY;

[6] Department of Pathology, University of Michigan, Ann Arbor, MI

[7] Department of Pathology, Memorial Sloan Kettering Cancer Center, New York, NY

Presented in part at the 115th Annual Meeting of the United States and Canadian Academy of Pathology in March 2026.

[*]**Correspondence:**

Juan Miguel Mosquera, MD, MSc.

Department of Pathology and Laboratory Medicine, Weill Cornell Medicine, 1300 York Avenue, Box 69

New York, NY 10065, USA

Tel: +1 212 746 2700

Email: jmm9018@med.cornell.edu

Running title: *NIPBL::NACC1* fusion hepatic carcinoma: outcome and genomics

Conflict of interest statement: M.F.L. is an employee of Isabl, Inc. The remaining authors declare no conflicts of interest.

Abstract

NIPBL::NACC1 fusion hepatic carcinoma is a rare and distinct primary hepatic neoplasm characterized by recognizable morphological and immunophenotypic features, and a recurrent *NIPBL::NACC1* gene fusion. Clinicopathologic determinants of outcome and response to systemic therapy remain incompletely defined. We assembled the largest cohort to date of 51 patients, comprising 5 new cases, 11 previously reported by our group, and 35 additional cases from the literature. Clinicopathologic data were reviewed in all cases, and whole-genome sequencing was performed in a subset. This information was compared with a large intrahepatic cholangiocarcinoma cohort. *NIPBL::NACC1* fusion hepatic carcinoma showed a marked female predominance (80.4%) and occurred predominantly in young patients (median age, 33.5 years) without a predisposing chronic liver disease. Tumors were large and well-circumscribed. Microscopically, although marked architectural heterogeneity was present, almost all tumors exhibited areas with a follicular or pseudoglandular growth pattern. These tumors exhibited universal immunoreactivity for inhibin-α, and cytokeratin 7, and were positive for albumin by RNA *in situ* hybridization. The expression of neuroendocrine markers was also frequent. *NIPBL::NACC1* fusion was the sole constant genomic alteration. Compared with intrahepatic cholangiocarcinoma, this tumor occurred in younger patients, showed marked female predominance, larger tumor size, higher resectability, and lacked the canonical genomic drivers associated with intrahepatic cholangiocarcinoma. Disease progression was observed in 8 of 9 patients treated with gemcitabine-based chemotherapy. All disease-specific deaths occurred in patients aged 40 years or younger (10/27; 37.0%), with no deaths among those older than 40 years (0/20). Younger age, larger tumor size, and major vascular invasion were associated with poor

outcome. These findings have implications for prognostic assessment and clinical management and underscore the importance of accurate diagnosis given the limited response to conventional systemic therapy for intrahepatic cholangiocarcinoma.

Key words: *NIPBL::NACC1* fusion, primary hepatic carcinoma, inhibin, gene fusion, liver neoplasms

INTRODUCTION

NIPBL::NACC1 fusion hepatic carcinoma (NNFHC) is a rare primary hepatic neoplasm that has been described under multiple diagnostic labels [1–5], including thyroid-like cholangiocarcinoma, solid-tubulocystic subtype of small duct intrahepatic cholangiocarcinoma (iCCA) and cholangioblastic cholangiocarcinoma [6]. These tumors commonly arise in young patients, display distinctive histomorphology, show diffuse inhibin expression, and appear to follow a clinically heterogeneous course. The first case report with features of this neoplasm was published in 1979 as a well-differentiated peripheral cholangiocarcinoma [1], and displayed several features that we now recognize as characteristic of this entity, *i.e.*, presentation in a young patient and an unusual glandular architecture with colloid-like luminal material reminiscent of follicular thyroid tumors. This publication was followed several years later by a report of a young woman with a similar tumor, which showed strong and diffuse inhibin reactivity, a distinctive feature that is not typical of other hepatic tumors [2]. A recurrent *NIPBL::NACC1* gene fusion was subsequently identified by Argani et al [3], and further genomic profiling has characterized NNFHC as molecularly distinct from conventional iCCA [4].

In this study, we present the largest cohort to date of this neoplasm with special attention to the clinicopathologic features associated with disease-specific mortality and a detailed description of the genomic landscape.

MATERIALS AND METHODS

Study Cohort

This study was approved by the Institutional Review Board of Weill Cornell Medicine (WCM; protocol 1007011157; most recent approval 3 June 2026) and was conducted in accordance with the Declaration of Helsinki. Informed consent was obtained from all patients from WCM and collaborating institutions; data for previously published cases were obtained from the published literature. We analyzed a total of 51 cases of NNFHC, including 11 cases previously reported by our group [4], 5 new cases, and 35 cases identified in published reports, including meeting abstracts (**Supplementary Table 1**).

Cases from WCM and Collaborative Institutions: Histologic evaluation of hematoxylin and eosin–stained slides and immunohistochemical reactions was performed. From electronic medical records the demographic, clinical and radiological information was obtained. Response to treatment, either by surgery alone or with the addition of chemotherapy was assessed following standard criteria [7]. Patient status at last follow-up was classified as no evidence of disease (NED), alive with disease (AWD), or died of disease (DOD).

Cases from published reports: Available clinical, pathologic, molecular, treatment, and outcome data were collected from original publications or public sources. Cases were included if they demonstrated a characteristic morphologic and immunophenotypic profile, including diffuse inhibin expression, and/or molecular confirmation of an *NIPBL::NACC1* fusion [2–5,8–33]. Three reported cases described as cholangioblastic cholangiocarcinoma [34], thyroid-like cholangiocarcinoma [35], or NNFHC [36] were excluded because neither diffuse inhibin expression nor molecular confirmation of an *NIPBL::NACC1* fusion was documented.

Immunohistochemistry and in situ Hybridization

Immunohistochemistry (IHC), RNA *in situ* hybridization (ISH) for albumin, and fluorescence *in situ* hybridization (FISH) were performed using the same protocols previously described [4] (**Table 1 and Supplementary Table 2**). *NIPBL::NACC1* gene rearrangements were evaluated by FISH break-apart and fusion assays.

Whole-Genome Sequencing and Analysis

WGS was performed on three new cases and involved standardized library preparation, sequencing, and bioinformatic analysis workflows as described in our previous report [4]. TMB was recorded as reported by each assay. TMB-high was defined as ≥13 mut/Mb according to the current FDA definition [37]; values ≥10 mut/Mb are also reported for comparison with prior literature.

Comparative Genomic and Clinical Analysis Using Public Intrahepatic Cholangiocarcinoma Cohort

To compare the genomic and clinical features of NNFHC, publicly available molecular data from a cohort of iCCA were obtained from the cBioPortal for Cancer Genomics [38–42], which includes 412 tumor–normal pairs analyzed using the MSK-IMPACT targeted sequencing assay. Frequencies of genomic alterations, including mutations, copy-number alterations, and structural variants (SV), were extracted directly from the dataset. A subset of recurrent and biologically relevant genes commonly reported in iCCA was selected for comparative analysis with the NNFHC cohort. Because targeted sequencing

coverage varies across genes, the number of evaluable cases differed by alteration and is reported individually for each variable. Visualization of genomic alteration frequencies was performed using Python (version 3.11) with the matplotlib, pandas, and numpy libraries.

Clinical information, including demographic characteristics, tumor size, prior liver disease, type of treatment, and outcome was obtained for comparative analyses. For the NNFHC cohort, the number of evaluable cases varied. To account for substantial differences in baseline disease characteristics, a matched survival analysis was performed restricting the iCCA cohort to resected, node-negative, non-metastatic patients. Nearest-neighbor matching age at diagnosis was performed with replacement using Python (scikit-learn, version 1.3). After deduplication of matched controls, the final comparison cohort comprised 31 NNFHC and 26 iCCA patients.

Statistical Analysis

Descriptive statistics were used to summarize clinicopathological, immunophenotypic, molecular, and treatment-related variables. Continuous variables were reported as median with interquartile range (IQR), and categorical variables as counts and percentages. Comparisons between patients with NED and those who DOD were performed using the Mann–Whitney U test for continuous variables and Fisher's exact test or chi-square test for categorical variables, as appropriate based on cell counts.

Survival curves were estimated using the Kaplan–Meier method and compared using the log-rank test. Median follow-up was estimated using the reverse Kaplan–Meier method. An age-stratified analysis was performed within the NNFHC cohort using a cutoff of 40 years, based on the observed distribution of disease-specific deaths. Univariate logistic

regression analysis was performed to evaluate associations between individual clinicopathologic variables and DOD, with results reported as odds ratios (ORs) with 95% confidence intervals (CIs). Given the limited sample size and the number of outcome events, no multivariable logistic regression models were constructed. All statistical analyses were conducted using two-sided tests, and a p value <0.05 was considered statistically significant.

RESULTS

Clinical Characteristics

A marked female predominance (80.4%) and a median age at diagnosis of 33.5 years (IQR, 24.0–47.2) was observed in patients with *NIPBL::NACC1* fusion hepatic carcinoma. Tumors were incidentally detected in 5 patients (9.8%). Among symptomatic patients, the most common presenting complaint was abdominal pain with or without vomiting (25 patients, 49.0%), followed by a palpable abdominal mass (6 patients, 11.8%). Less frequent presentations included weight loss, liver failure, back pain, or ascites (1 patient each, 2.0%). Among cases with available data, the median time from symptom onset to diagnosis was 6 months (IQR, 3.0–48.0; n=11). Concurrent liver disease was uncommon, and most patients (64.7%) had no predisposing liver disease. Non-fibrotic steatosis or steatohepatitis was reported in 6 patients (11.8%), alcohol-related and hepatitis B–associated cirrhosis were each observed in one patient (2.0%). Extrahepatic comorbidities included obesity or morbid obesity (5 patients, 16.6%) and polycystic ovary syndrome (3 of 30 patients, 10%). Other comorbid conditions were reported only sporadically (**Supplementary Table 1**). Serologic tumor markers were available in a subset of cases and were typically unremarkable including CA 19-9 and alpha-fetoprotein, which were tested in 8/12 and 13/14 cases, respectively. CA-125 and carcinoembryonic antigen were within normal limits in all evaluated cases.

Pathologic Features and Immunoprofile of NIPBL::NACC1 Fusion Hepatic Carcinoma

Among cases with available gross descriptions, tumors showed no lobar predilection. All were well circumscribed solid masses, exhibiting cystic (77.7%) and hemorrhagic (57.7%) changes. Most tumors were single (82.0%); multifocality was observed in 10.5% of cases (**Supplementary Table 1**). Microscopically, architectural heterogeneity was present in nearly all tumors (95.5%). The predominant pattern was follicular or pseudoglandular (97.7%) followed by macro- and microcystic (63.6%), trabecular (54.5%), insular (45.4%), papillary or pseudopapillary (13.6%), and high-grade solid (9.1%). (**Figure 1**). Features of local aggressiveness were frequently reported. Vascular invasion was identified in 64.3% of cases (18/28), whereas perineural invasion was uncommon (3.6%, 1/28). Focal tumor necrosis was present in 35.5% of cases (11/31).

Inhibin-α, albumin RNA ISH, cytokeratin AE1/AE3, and CK7 were positive in all tested cases, whereas CK19 was positive in 93.3% (**Table 1**). Neuroendocrine marker expression was frequently observed, with synaptophysin and chromogranin A positivity in 74.5% and 53.7% of cases, respectively. Expression of at least one neuroendocrine marker was present in 81.2% of tumors and was more often focal (71.0%). In contrast, INSM1 was uniformly negative in all reported cases. Because of the expression of neuroendocrine markers, two cases reviewed in consultation were initially misdiagnosed as metastatic neuroendocrine tumors. One such case is illustrated in **Figure 2**.

Markers of hepatocellular differentiation were infrequently expressed, with glypican-3 and arginase-1 positive in 10.0% and 6.7% of cases, respectively. HepPar-1 was negative in all cases. With the exception of CDX2 expression that was observed in a subset of cases (23.1%), additional markers were negative, including those associated with thyroid,

pulmonary, Müllerian, pancreatic, mesothelial, and melanocytic lineages (**Supplementary Table 2**).

Molecular landscape of NIPBL::NACC1 Fusion Hepatic Carcinoma

Molecular profiling from 28 tumors was available and included results of WGS (n=7), whole-exome sequencing (n=1), targeted next-generation sequencing panels (n=16), RNA-seq (n=3), and PCR for *BRAF V600E* (n=1) (**Supplementary Table 3**). The only consistent genomic alteration was the *NIPBL::NACC1* fusion. Among tumors analyzed by WGS, the rearrangement was identified in all cases, occurring as part of complex structural variants in four tumors and simple rearrangements in three (**Figure 3**). Apart from this disease-defining gene fusion, the genomic landscape was characterized by sparse and largely non-recurrent alterations. Occasional mutations were identified in genes such as *CREBBP*, *MST1R*, *KMT2A*, *GNAS*, and *MGA*, as well as copy-number losses involving *RB1* or *PTEN* (**Supplementary Table 3**). Among WGS cases, the only gene altered in more than one tumor was *TP53* (2/7), with distinct single-nucleotide variants. No recurrent pathogenic alterations were identified in genes commonly present in iCCA, including *IDH1, BAP1, ARID1A, KRAS, BRAF, FGFR2, CDKN2A* or *ATM* (**Figure 4**). The clinically relevant biomarkers are summarized in **Table 2**. Tumor mutational burden (TMB) was ≥ 10 mut/Mb in 4 of 15 cases (26.7%; range 10.0-40.7 mut/Mb), and only one case (6.7%) met the current FDA definition of TMB-high (≥13 mut/Mb) [37]. All tumors assessed for microsatellite instability were stable (0/14). Other potentially relevant alterations included one case with *MET* amplification and a likely oncogenic truncating *MGA* variant (p.R2466*) without established therapeutic implications. Denominators varied according to biomarker availability and assay coverage.

Comparative Clinical Features Between NIPBL::NACC1 Fusion Hepatic Carcinoma and Intrahepatic Cholangiocarcinoma

Compared to iCCA (n=412), NNFHC (n=51) occurred in significantly younger patients (median 33.5 vs. 63.9 years; p<0.01) and showed a marked female predominance (80.4% vs. 53.9%; p<0.01). Tumors were larger at presentation (median 15.0 vs. 6.0 cm; p<0.01) and more frequently solitary liver lesions (82% vs. 36%; p<0.01). In contrast, iCCA more frequently presented with metastatic disease (43% vs. 11%; p<0.01) and had CA19-9 elevation (61.3% vs 22.2%; p<0.01). More patients with NNFHC underwent surgical resection (90% vs. 51%; P<0.01). No NNFHC patient with documented nodal staging had lymph node metastases at presentation (0/5), compared with 20.1% of iCCA; nodal involvement was documented only at recurrence, in 2 patients.

Given these differences in baseline disease characteristics, overall survival was compared with that of patients with resected, node-negative, non-metastatic iCCA selected by nearest-neighbor matching on age. This analysis included 31 patients with NNFHC and 26 matched patients with iCCA with a median follow up of 16.0 months and 61.4 months, respectively. Although no statistically significant difference in overall survival was observed between the matched cohorts (log-rank P=0.078), a trend was present (**Figure 5**).

An age-associated difference in outcome was observed within the NNFHC cohort. All disease-specific deaths occurred among patients aged ≤40 years (10/27 [37.0%]; median follow-up 25.0 months), whereas no disease-specific deaths were observed among patients

older than 40 years (0/20; median follow-up 13.0 months). This pattern persisted after excluding patients with metastatic disease at presentation.

Treatment outcomes and prognostic factors

Treatment and outcomes are summarized in **Table 3**. Patients treated with surgical resection alone had the most favorable outcomes; most remained free of disease and none died of disease. Outcomes were more heterogeneous among patients who received systemic therapy in addition to surgery, with lower rates of disease-free status and more disease-specific deaths. These differences likely reflect, at least in part, patient selection: tumors in patients receiving additional therapy were larger than in those treated with surgery alone (median 18.5 vs. 12.1 cm), and most patients with positive margins (3/4) received adjuvant therapy. All 5 patients treated with systemic therapy alone had locally advanced or metastatic disease, and none achieved disease-free status. Among the 9 patients treated with regimens commonly used for iCCA (gemcitabine plus cisplatin or oxaliplatin, with or without immunotherapy), 8 had progressive disease and 1 had stable disease.

Clinicopathologic Determinants of Outcome

Comparison of patients by survival status demonstrated distinct clinicopathologic differences. Patients who DOD were younger at diagnosis (median 25.0 vs. 42.0 years) and had larger tumors (21.5 vs. 12.0 cm). They also more frequently exhibited adverse pathologic features, including major vascular invasion, vascular and/or perineural invasion, tumor necrosis, and positive surgical margins (all $p<0.05$) (**Table 4**). Univariable logistic regression analysis identified factors associated with disease-specific death (**Supplementary Table 4**). Younger

age at diagnosis was associated with a higher likelihood of disease-specific death (OR 0.90 per year increase, 95% CI 0.82–0.98, p=0.01), as was larger tumor size (OR 1.14 per cm increase, 95% CI 1.05–1.27, p<0.01). Markers of locally aggressive disease were also strongly associated with adverse outcome, including major vascular invasion (OR 25.3, 95% CI 2.10–305.00, p=0.01), vascular and/or perineural invasion, and positive surgical margins (both p≤0.01).

DISCUSSION

In this study, we present the largest clinicopathologic and molecular characterization to date of *NIPBL::NACC1* fusion hepatic carcinoma [2–5,8–33], a neoplasm characterized by a distinct morphological, immunophenotypic and clinical profile, a distinctive genomic landscape that differs from iCCA, and heterogeneous outcomes.

NNFHC exhibits a distinctive clinical presentation. Most patients are young women who present with large, single tumors without a predisposing hepatic disease and, unlike iCCA, without documented nodal metastases at presentation. Because of these features, the tumors may raise a clinical or radiologic impression of hepatocellular adenomas. Despite their large size, many patients remain candidates for surgical resection, in contrast with conventional iCCA [43], which more frequently presents with multifocal or metastatic disease (solitary tumor 82% vs. 36%; metastatic disease 11% vs 43%). This relatively high resectability may be explained, at least in part, by their presentation as a single, well-circumscribed neoplasm. Consistent with the overall favorable clinical attributes of NNFHC, survival analysis comparing NNFHC with age-matched patients with resected, node-negative, non-metastatic iCCA showed numerical separation of the curves at later time points, although the difference was not statistically significant (**Figure 5**), longer follow-up and additional

cases will be required to determine whether this reflects a true survival difference. Additionally, like hepatic adenomas, a potential hormonal association has been suggested based on the strong female predominance, and the reported history of oral contraceptives use, and the presence of obesity or polycystic ovarian syndrome in a subset of patients [2,9,21,24,25,30]. However, available data remain limited and no consistent association with hormone receptor expression by IHC has been demonstrated [23,25].

The clinical behavior of NNFHC is heterogeneous, with a subset of patients achieving durable disease control following surgical resection, while others develop aggressive, locally advanced or unresectable disease and experience poor outcomes. This variability appears to reflect underlying biological differences within this entity. Notably, adverse outcomes are associated with a constellation of clinicopathologic features, including younger age at presentation, larger tumor size, and evidence of locally aggressive growth, namely major vascular invasion, vascular and/or perineural invasion, and positive surgical margins, despite the circumscribed appearance of these tumors. In particular, the observation that disease-specific deaths occurred exclusively in patients aged 40 years or younger, with no deaths observed in older patients, suggests that age may represent a simple and potentially clinically useful prognostic stratifier. Importantly, this heterogeneity is not explained by recurrent secondary genomic alterations, suggesting that differences in tumor behavior may be driven by mechanisms beyond the DNA level. Histologically, tumor necrosis and hemorrhage were more frequent among patients who died of disease, and solid/insular growth, high-grade solid areas and higher Ki-67 indices showed a similar trend without reaching statistical significance **(Table 4)**. A tentative hypothesis is that the hormonal milieu of young patients may contribute to the development of a more aggressive tumor.

NNFHC is characterized by marked morphologic heterogeneity, with most tumors exhibiting multiple architectural patterns within the same lesion. Because of this variability and the frequent expression of neuroendocrine markers, several tumor types are considered in the differential diagnosis. A follicular architecture with colloid-like luminal secretions may suggest a metastatic follicular thyroid carcinoma [8,11,13,15,17,18], whereas trabecular or solid patterns with expression of synaptophysin and chromogranin can be misinterpreted as a neuroendocrine neoplasm [3,9,30]. At variance with most endocrine tumors involving the liver, INSM1 is invariably negative [2–4,10,22,23,27,30]. In practice, a limited immunohistochemical panel is helpful in distinguishing NNFHC from metastatic neuroendocrine tumors, particularly where molecular testing is not available. NNFHC shows diffuse inhibin expression, albumin RNA ISH positivity and INSM1 negativity, even when synaptophysin or chromogranin is expressed, whereas neuroendocrine tumors are typically INSM1-positive, and negative for inhibin and albumin ISH. Diffuse nuclear GATA4 expression has recently been proposed as an additional marker [44], although its specificity against morphologic mimics, including neuroendocrine tumors, remains to be established. In the absence of a known extrahepatic primary tumor, and bearing in mind that NNFHC may itself metastasize (Figure 2), this profile strongly supports the diagnosis, which can be confirmed by detection of the *NIPBL::NACC1* fusion or gene rearrangement; this fusion was absent in 324 other hepatobiliary neoplasms in a recent series [44]. In summary, the diagnosis of NNFHC can be strongly suspected in young female patients with large hepatic tumors showing follicular or mixed architectural patterns and diffuse immunoreactivity for inhibin. In most cases, this constellation of findings is distinctive enough to support the diagnosis without the need for molecular confirmation, consistent with the complete concordance between this phenotype and fusion status in all cases tested to date [4,44].

NNFHC is defined by a recurrent *NIPBL::NACC1* fusion [3,4], which represents the only consistent genomic alteration identified across cases and likely constitutes the oncogenic driver in this tumor. Beyond this fusion, the genomic landscape lacks recurrent alterations in genes commonly implicated in hepatobiliary malignancies [4], including *IDH1/2, FGFR2, BAP1, ARID1A,* and *KRAS,* frequently identified in iCCA [45]. This genomic simplicity parallels other fusion-driven neoplasms in which a single oncogenic event is sufficient to initiate and sustain tumorigenesis in the absence of other mutations [46]. To better understand the biological consequences of the *NIPBL::NACC1* fusion, it is important to consider the functional roles of these genes. *NIPBL* encodes a cohesin-loading factor involved in chromatin organization and regulation of higher-order genome structure [47,48], while *NACC1* encodes a transcriptional coregulator implicated in cell proliferation and survival [49,50]. The fusion retains only the N-terminal portion of *NIPBL* (exons 1–8 or 1–9), losing the C-terminal HEAT-repeat region required for cohesin loading, together with the entire coding sequence of *NACC1*, including its BTB/POZ and BEN domains [3,4,48]. This suggests that the chimeric protein acts primarily through *NACC1*-dependent transcriptional programs rather than through cohesin loading. The absence of recurrent secondary genomic alterations, coupled with the different outcomes primarily related to patient age, suggests that additional layers of biological regulation, such as transcriptional states, epigenetic programs, or tumor–microenvironment may play a critical role in determining tumor behavior.

The precise cell of origin of NNFHC remains unknown. The immunophenotype of these tumors, characterized by CK7 and CK19 expression with albumin RNA ISH positivity, has been previously interpreted as evidence of biliary differentiation [3,5]; however, none of these markers is specific to the biliary lineage. Albumin RNA-ISH strongly supports a hepatic origin [4], while CK7 and CK19 are broadly expressed across multiple carcinoma types and in hepatic progenitor cells [4,51,52]. Additionally, the frequent expression of

neuroendocrine markers including synaptophysin and chromogranin with consistent INSM1 negativity raises the possibility of derivation from hepatic progenitor cells, which express neuroendocrine markers under certain conditions while lacking markers of terminal neuroendocrine commitment [51,52]. This interpretation is supported by a recent whole-transcriptome study of 10 NNFHC and 324 other hepatobiliary neoplasms, which identified consistent upregulation of *INHA*, *GATA4*, and synaptic genes, but not of *INSM1,* relative to every other tumor type, and placed these tumors in an intermediate position between hepatocellular and biliary lineages, with a mature biliary epithelial program reduced to the level of HCC [44]. In the same dataset, these tumors showed higher *ALB* and *HNF4A* and lower *KRT19* and *HNF1B* expression than iCCA, and composite developmental maturity and progenitor scores did not differ from those of conventional iCCA or HCC, differing only from hepatoblastoma, which showed a more immature profile [44]. Taken together, these findings point to a tumor of intrahepatic origin with partial hepatocellular and biliary features, but without commitment to a mature lineage and without the immature profile of hepatoblastoma. This differentiation state is compatible with, but does not establish, derivation from a bipotential hepatic progenitor cell. Definitive characterization of the cell of origin will require dedicated epigenomic studies, ideally incorporating single-cell or spatial approaches.

The clinical management of NNFHC has important implications given its distinct biology and behavior. Long-term disease control was most frequently observed among patients undergoing complete surgical resection. In contrast, conventional systemic therapies used for iCCA demonstrated limited efficacy [43], with disease progression observed in 8 of 9 patients treated with gemcitabine-based regimens. Although the small number of treated patients and the advanced disease setting preclude definitive assessment of treatment efficacy, these findings highlight the inadequacy of considering this tumor as a subtype of cholangiocarcinoma and treating it accordingly. Although TMB ≥10 mut/Mb was observed

in 4 cases, only one met the current FDA threshold for TMB-high (≥13 mut/Mb), and the potential benefit of immune checkpoint inhibition in NNFHC remains unknown [37,53,54].

We acknowledge that our study has limitations. The retrospective design and the integration of cases from multiple sources introduce inherent variability in clinical data, treatment approaches, and follow-up. The matched survival comparison with iCCA was limited by sample size and age difference between cohorts, and the short median follow-up in the NNFHC cohort precluded definitive survival conclusions. Additionally, the age cutoff of 40 years was derived from the observed dataset and has not been independently validated. Finally, the 10 tumors from a recent transcriptomic study [44] were not included in the present cohort, because that study was published after data collection and analysis had been completed, it did not report case-level clinical or outcome data, and overlap with previously reported cases could not be excluded; its published findings are, however, considered in this Discussion.

Despite these limitations, the integration of clinicopathologic and genomic data across this large dataset provides a comprehensive characterization of NNFHC with novel observations not previously established, including 1) the identification of clinicopathologic factors associated with disease-specific mortality, including age, tumor size, and major vascular invasion; 2) the observation that all disease-specific deaths occurred in patients aged 40 years or younger, identifying age as a simple potential prognostic stratifier that warrants independent validation; 3) the systematic documentation of limited response to iCCA-directed chemotherapy; and 4) immunophenotypic and molecular observations that support the classification of this tumor as a distinct entity. Collectively, these findings have direct implications for prognostic assessment, treatment selection, and the design of future prospective studies.

ACKNOWLEDGEMENTS

Whole-genome sequencing was performed at the New York Genome Center, supported by an Agreement with Illumina, Inc., and Weill Cornell Medicine. Project support for this research was provided in part by the Center for Translational Pathology of the Department of Pathology and Laboratory Medicine at Weill Cornell Medicine. This work was supported by the Englander Institute for Precision Medicine, Weill Cornell Medicine, New York, NY.

AUTHOR CONTRIBUTIONS

JDM, JJ and JMM conceived and designed the study. JDM, JJ and JMM provided cases, performed pathology review and collected clinical data. JDM analysed the data, performed the statistical analyses, prepared the figures and wrote the manuscript with JMM. MAA and ENK reviewed cases, collected clinical data and coordinated whole-genome sequencing with JDM and JMM. EP collected cases and clinical data, generated hypotheses and contributed to writing the manuscript. ASe performed FISH studies. XW, KG, ASb and OE performed bioinformatic analyses; KG and ASb provided methodological support and managed the molecular data repository. MFL contributed to the processing of whole-genome sequencing data. SPG, JSz, MW, ASr, CS and JSh provided cases and contributed to the development of the study. JJ and JMM supervised the study. All authors were involved in writing the paper and had final approval of the submitted and published versions.

DATA AVAILABILITY STATEMENT

The clinicopathologic data supporting the findings of this study are available in the article and its supplementary material. Whole-genome sequencing data are not publicly available because they include germline information that could compromise patient privacy; de-identified data are available from the corresponding author upon reasonable request, subject to institutional review board approval and a data use agreement. Genomic and clinical data for the intrahepatic cholangiocarcinoma comparison cohort are publicly available from cBioPortal (Intrahepatic Cholangiocarcinoma, MSK, Hepatology 2021).

REFERENCES

1. Foucar E, Kaplan LR, Gold JH, et al. Well-differentiated peripheral cholangiocarcinoma with an unusual clinical course. Gastroenterology 1979; 77: 347–353.

2. Vrettou E, Hytiroglou P, Sikas N, et al. Hepatic adenocarcinoma expressing inhibin in a young patient on oral contraceptives. Virchows Arch 2005; 446: 560–565.

3. Argani P, Palsgrove DN, Anders RA, et al. A novel NIPBL-NACC1 gene fusion is characteristic of the cholangioblastic variant of intrahepatic cholangiocarcinoma. Am J Surg Pathol 2021; 45: 1550–1560.

4. Hissong E, Al Assaad M, Bal M, et al. NIPBL::NACC1 fusion hepatic carcinoma. Am J Surg Pathol 2024; 48: 183–193.

5. Argani P, Oshima K, Anders RA, et al. Cholangioblastic cholangiocarcinoma (NIPBL::NACC1 cholangiocarcinoma): expanded morphologic spectrum and further genetic characterization. Am J Surg Pathol 2025; 49: 303–314.

6. WHO Classification of Tumours Editorial Board. Digestive System Tumours. WHO Classification of Tumours (6th edn, Vol 1). International Agency for Research on Cancer: Lyon, 2026.

7. Eisenhauer EA, Therasse P, Bogaerts J, et al. New response evaluation criteria in solid tumours: revised RECIST guideline (version 1.1). Eur J Cancer 2009; 45: 228–247.

8. Fornelli A, Bondi A, Jovine E, et al. Intrahepatic cholangiocarcinoma resembling a thyroid follicular neoplasm. Virchows Arch 2010; 456: 339–342.

9. Braxton DR, Saxe D, Damjanov N, et al. Molecular and cytogenomic profiling of hepatic adenocarcinoma expressing inhibinA, a mimicker of neuroendocrine tumors: proposal to reclassify as “cholangioblastic variant of intrahepatic cholangiocarcinoma”. Hum Pathol 2017; 62: 232–241.

10. Wen KW, Joseph NM, Srivastava A, et al. Inhibin-positive hepatic carcinoma: proposal for a solid-tubulocystic variant of intrahepatic cholangiocarcinoma. Hum Pathol 2021; 116: 82–93.

11. Chablé-Montero F, Shah A, Montante-Montes de Oca D, et al. Thyroid-like cholangiocarcinoma of the liver: an unusual morphologic variant with follicular, trabecular and insular patterns. Ann Hepatol 2012; 11: 961–965.

12. Kaminsky P, Preiss J, Sasatomi E, et al. Biliary adenofibroma: a rare hepatic lesion with malignant features. Hepatology 2017; 65: 380–383.

13. Chen SH, Zheng ZY, Wang HL, et al. Thyroid-like intrahepatic cholangiocarcinoma: report of a case and review of the literature. Int J Surg Pathol 2018; 26: 649–654.

14. Liu J, Lichtenberg T, Hoadley KA, et al. An integrated TCGA pan-cancer clinical data resource to drive high-quality survival outcome analytics. Cell 2018; 173: 400–416.

15. Mittal N, Bal M, Ramadwar M, et al. Pathologic doppelgänger: thyroid-like intrahepatic cholangiocarcinoma with synchronous primary thyroid carcinoma in a young woman. Ann Hepatobiliary Pancreat Surg 2020; 24: 182–187.

16. Saraireh H, Al Yassin S. A case of cholangioblastic variant of intrahepatic cholangiocarcinoma [abstract]. Am J Gastroenterol 2020; 115(Suppl): S2474.

17. Bardia A, Elhence PA, Nag P, et al. Thyroid follicle-like cholangiocarcinoma in liver: a novel variant and what we know so far? J Gastrointest Cancer 2021; 52: 792–796.

18. Hissong E, Chiu K, Park H, et al. Thyroid-like cholangiocarcinoma: histopathological, immunohistochemical, in-situ hybridization and molecular studies on an uncommon emerging entity. Int J Surg Pathol 2021; 29: 920–925.

19. Liang TZ, Whang G, Chopra S. Primary hepatic carcinoma with inhibin positivity in a young male patient: a rare tumor previously only reported in females. Virchows Arch 2021; 478: 605–610.

20. Ayvazyan KhA, Gurmikov BN, Anvari RO, et al. Cholangioblastic liver carcinoma. Annals of HPB Surgery 2022; 27: 125–134 (in Russian).

21. González IA, Linn RL, Wilkins BJ. Solid-tubulocystic variant of intrahepatic cholangiocarcinoma: report of a pediatric case with molecular characterization. Pediatr Dev Pathol 2022; 25: 661–667.

22. Huang G, Howard LN, Alonsozana E, et al. Molecular characteristics and immunogenomic profiling of cholangioblastic variant of intrahepatic cholangiocarcinoma in a 68-year-old patient. Anticancer Res 2022; 42: 5475–5478.

23. Syrnioti A, Athanasiou E, Hytiroglou P. Hepatic carcinoma expressing inhibin: case report of a proposed novel entity and review of the literature. J Pathol Transl Med 2022; 56: 225–230.

24. Verhoeff K, Bacani J, Fung C, et al. A cholangioblastic variant of cholangiocarcinoma. ACG Case Rep J 2022; 9: e00746.

25. Bakhshwin A, Lai KK, Ammoun A, et al. Inhibin-positive “cholangioblastic” variant of intrahepatic cholangiocarcinoma: report of 3 new patients with review of the literature. Int J Surg Pathol 2023; 31: 1495–1504.

26. Marichez A, Lavoine E, Bardou D, et al. Cholangioblastic variant of intrahepatic cholangiocarcinoma: a recently described biliary cancer in young patients. Dig Liver Dis 2023; 55: 1145–1146.

27. Ozcan B, Dursun SK, Dursun N. Cholangiocarcinoma expressing inhibin A, a mimicker of neuroendocrine tumours: a rare case of cholangioblastic variant of intrahepatic cholangiocarcinoma [abstract]. Virchows Arch 2024; 485(Suppl 1): S239.

28. Roman E, Obeng R, Sandhu N. Cholangioblastic variant of intrahepatic cholangiocarcinoma in a 33-year-old female [abstract]. Am J Gastroenterol 2024; 119(Suppl): S4596.

29. Thomann J, Guber R, Movahedi B, et al. Cholangioblastic variant of intrahepatic cholangiocarcinoma – first case reported in a young female with situs inversus totalis [abstract]. HPB 2024; 26(Suppl 1): S188.

30. Berry N, Baltzinger P, Baltrés A, et al. Quand le phénotype neuroendocrine induit en erreur: une tumeur hépatique au profil trompeur [When the neuroendocrine phenotype is misleading: a hepatic tumor with a deceptive profile]. Ann Pathol 2026; 46: 39–44.

31. Fiorletta Quiroga E, Policarpio-Nicolas MLC. Cytologic findings of cholangioblastic variant of intrahepatic cholangiocarcinoma: a rare variant and cytologic pitfall. Diagn Cytopathol 2026; 54: 43–49.

32. Zhu X. Case 8: 26 y.o. F presents with abdominal pain and large mass in liver. In 100 Rare Tumors of the Digestive System: A Case-Based Reference for Surgical Pathologists, Liao X (ed). Academic Press (Elsevier): Amsterdam, 2025; 389–393.

33. Zhang S, Hasan N, Han J, et al. A camouflaging mystery: solid-tubulocystic variant of intrahepatic cholangiocarcinoma. Hum Pathol Rep 2025; 42: 300797.

34. Gambella A, Lesniak L, Lesniak A, et al. Next-generation pathology insights on cholangioblastic cholangiocarcinoma cell of origin [abstract]. Virchows Arch 2024; 485(Suppl 1): S67.

35. Bondarenko E, Kalinin D, Urusova L, et al. Case report: rare observation of thyroid-like cholangiocarcinoma. Front Med (Lausanne) 2025; 11: 1458586.

36. Bajpai P, Ghandour F, Jain E, et al. Defining molecular signatures of the solid/pseudopapillary and pseudoglandular patterns in so-called “solid-tubulocystic intrahepatic cholangiocarcinoma vs. NIPBL::NACC1 fusion hepatic carcinoma”. Pathol Res Pract 2025; 270: 155962.

37. U.S. Food and Drug Administration. FDA grants traditional approval for pembrolizumab or pembrolizumab and berahyaluronidase alfa-pmph for unresectable or metastatic TMB-H solid tumors with updated indication. October 16, 2026. [Accessed November 19, 2026]: Available from: https://www.fda.gov/drugs/cancer-approvals/fda-grants-traditional-approval-pembrolizumab-or-pembrolizumab-and-berahyaluronidase-alfa-pmph

38. Jeon Y, Kwon SM, Rhee H, et al. Molecular and radiopathologic spectrum between HCC and intrahepatic cholangiocarcinoma. Hepatology 2023; 77: 92–108.

39. Cerami E, Gao J, Dogrusoz U, et al. The cBio cancer genomics portal: an open platform for exploring multidimensional cancer genomics data. Cancer Discov 2012; 2: 401–404.

40. Gao J, Aksoy BA, Dogrusoz U, et al. Integrative analysis of complex cancer genomics and clinical profiles using the cBioPortal. Sci Signal 2013; 6: pl1.

41. Boerner T, Drill E, Pak LM, et al. Genetic determinants of outcome in intrahepatic cholangiocarcinoma. Hepatology 2021; 74: 1429–1444.

42. de Bruijn I, Kundra R, Mastrogiacomo B, et al. Analysis and visualization of longitudinal genomic and clinical data from the AACR Project GENIE Biopharma Collaborative in cBioPortal. Cancer Res 2023; 83: 3861–3867.

43. Moris D, Palta M, Kim C, et al. Advances in the treatment of intrahepatic cholangiocarcinoma: an overview of the current and future therapeutic landscape for clinicians. CA Cancer J Clin 2023; 73: 198–222.

44. Argani P, Singhi AH, Shaker N, et al. Whole transcriptome sequencing reveals a GATA4-INHA program and progenitor cell of origin in cholangioblastic cholangiocarcinoma. Mod Pathol 2026; DOI:10.1016/j.modpat.2026.101109.

45. Zhou ZJ, Ye YH, Hu ZQ, et al. Whole-exome sequencing reveals genomic landscape of intrahepatic cholangiocarcinoma and identifies SAV1 as a potential driver. Nat Commun 2024; 15: 9960.

46. Mertens F, Johansson B, Fioretos T, et al. The emerging complexity of gene fusions in cancer. Nat Rev Cancer 2015; 15: 371–381.

47. Gao D, Zhu B, Cao X, et al. Roles of NIPBL in maintenance of genome stability. Semin Cell Dev Biol 2019; 90: 181–186.

48. Alonso-Gil D, Losada A. NIPBL and cohesin: new take on a classic tale. Trends Cell Biol 2023; 33: 860–871.

49. Nakayama K, Rahman MT, Rahman M, et al. Biological role and prognostic significance of NAC1 in ovarian cancer. Gynecol Oncol 2010; 119: 469–478.

50. Gao M, Wu RC, Herlinger AL, et al. Identification of the NAC1-regulated genes in ovarian cancer. Am J Pathol 2014; 184: 133–140.

51. Roskams TA, Libbrecht L, Desmet VJ. Progenitor cells in diseased human liver. Semin Liver Dis 2003; 23: 385–396.

52. Roskams T, Cassiman D, De Vos R, et al. Neuroregulation of the neuroendocrine compartment of the liver. Anat Rec A Discov Mol Cell Evol Biol 2004; 280: 910–923.

53. Samstein RM, Lee CH, Shoushtari AN, et al. Tumor mutational load predicts survival after immunotherapy across multiple cancer types. Nat Genet 2019; 51: 202–206.

54. Marabelle A, Fakih M, Lopez J, et al. Association of tumour mutational burden with outcomes in patients with advanced solid tumours treated with pembrolizumab: prospective biomarker analysis of the multicohort, open-label, phase 2 KEYNOTE-158 study. Lancet Oncol 2020; 21: 1353–1365.

FIGURE LEGENDS

Figure 1. Morphologic and immunophenotypic spectrum of *NIPBL::NACC1* fusion hepatic carcinoma (NNFHC). Representative histologic features illustrating the architectural and cytologic heterogeneity of NNFHC. (A) Follicular morphology. (B) Microcystic architecture. (C) Microcystic architecture with prominent hemorrhagic areas. (D) Trabecular growth pattern. (E) Solid growth pattern. (F) Papillary architecture. At higher magnification, characteristic cytologic features of this entity are demonstrated, including intranuclear pseudoinclusions (G) and nuclear grooves (H). (I) Diffuse cytoplasmic inhibin-α expression by immunohistochemistry. Hematoxylin and eosin–stained sections unless otherwise indicated.

Figure 2. *NIPBL::NACC1* fusion hepatic carcinoma with metastasis to pancreas: a potential diagnostic pitfall. A middle-aged man was diagnosed with pancreatic neuroendocrine tumor, for which he received treatment without clinical response. Liver biopsy (top panel) demonstrates (A–B) follicular and trabecular architecture. (C) Tumor cells are positive for synaptophysin by immunohistochemistry, while chromogranin is negative (not shown). Pancreatic tumor resection (lower panel) demonstrates (D–F) follicular, trabecular, and cystic morphology. Tumor cells show strong expression of (G) inhibin, along with (H) synaptophysin and multifocal (I) chromogranin. (J) Fluorescence *in situ* hybridization assay confirms the *NIPBL::NACC1* gene fusion.

Figure 3. Complex structural variants are elucidated in a subset of *NIPBL::NACC1* fusion hepatic carcinoma. The top panel illustrates an example of a simple *NIPBL::NACC1*

structural variant. (A) H&E and genome circos plot of Case 3. A cartoon of *NIPBL::NACC1* fusion (B) illustrates a simple interchromosomal rearrangement between chromosomes 5 and 19. Whole-genome sequencing structural variant plot (C) demonstrates a simple translocation involving *NIPBL* (chromosome 5, intron 9) and *NACC1* (chromosome 19, intron 1). The lower panel illustrates an example of a complex *NIPBL::NACC1* structural variant. (D) H&E and genome circos plot of Case 9. A cartoon of *NIPBL::NACC1* fusion (E) illustrates again a simple interchromosomal rearrangement involving chromosomes 5 and 19. However, whole-genome sequencing analysis elucidates a complex structural variant (F) that involves, in addition to *NIPBL* and *NACC1*, a rearrangement with chromosome 16 and associated copy-number alterations.

Figure 4. Comparative genomic landscape of *NIPBL::NACC1* fusion hepatic carcinoma (NNFHC) and intrahepatic cholangiocarcinoma (iCCA). (A) Frequency of selected genomic alterations and biomarkers in NNFHC and iCCA. NNFHC is characterized by a recurrent *NIPBL::NACC1* rearrangement and a relative absence of canonical iCCA-associated driver alterations, including *IDH1, ARID1A, BAP1, KRAS, FGFR2, CDKN2A*, and others. *TP53* represents the only overlapping alteration identified in both groups. A subset of NNFHC demonstrates high tumor mutational burden (TMB ≥10 mutations/Mb). (B) Heatmap representation of alteration frequencies across the same set of genes and biomarkers, illustrating the distinct genomic profile of NNFHC compared to iCCA. Values are expressed as percentages. Denominators vary across genes due to differences in sequencing platforms and data availability and are indicated for each alteration.

Figure 5. Overall survival of *NIPBL::NACC1* fusion hepatic carcinoma (NNFHC) compared with clinically comparable intrahepatic cholangiocarcinoma (iCCA). Kaplan–

Meier overall survival curves comparing NNFHC (n=31) with a matched iCCA cohort (n=26) restricted to resected, node-negative, non-metastatic patients. Matching was performed by nearest-neighbor age-matching with replacement; after deduplication of matched controls, the final comparison cohort comprised 31 NNFHC and 26 unique iCCA patients. Median overall survival was not reached in the NNFHC cohort and was 62.8 months in the matched iCCA cohort (log-rank P=0.078). Median follow-up was 16.0 months for NNFHC and 61.4 months for iCCA. Shaded areas represent 95% confidence intervals. Vertical tick marks indicate censored observations.

SUPPLEMENTARY MATERIAL ONLINE

Supplementary Table 1. Clinicopathologic, treatment, and outcome features of 51 patients with *NIPBL::NACC1* fusion hepatic carcinoma

Supplementary Table 2. Detailed immunophenotypic profile of *NIPBL::NACC1* fusion hepatic carcinoma (published cases and current cohort)

Supplementary Table 3. Summary of molecular findings in *NIPBL::NACC1* fusion hepatic carcinoma (published cases and current cohort)

Supplementary Table 4. Univariable logistic regression analysis of factors associated with disease-specific death in *NIPBL::NACC1* fusion hepatic carcinoma

Table 1. Core immunophenotypic profile of *NIPBL::NACC1* fusion hepatic carcinoma (published cases and current cohort)

Antibody	Cases tested[1]	Positive cases, n (%)
Hepatic / hepatobiliary		
Inhibin	48	48 (100.0)
Albumin (RNA ISH)	25	25 (100.0)
Cytokeratins		
CK AE1/AE3 (pan-CK)	17	17 (100.0)
CK7	45	45 (100.0)
CK19	30	28 (93.3)
Neuroendocrine markers		
Synaptophysin	47	35 (74.5)
Chromogranin	41	22 (53.7)
INSM1	16	0 (0.0)
Hepatocellular markers		
Glypican-3	20	2 (10.0)
Arginase	15	1 (6.7)
HepPar-1	36	0 (0.0)
Thyroid / lung markers		
Thyroglobulin	11	1 (9.1)
TTF1	24	1 (4.2)
Müllerian / renal markers		
PAX8	15	0 (0.0)
Intestinal markers		
CDX2	13	3 (23.1)

[1]Total unique cases compiled (n=48); the number of cases tested varies by antibody.

Table 2. Clinically relevant genomic biomarkers in *NIPBL::NACC1* fusion hepatic carcinoma

Biomarker	Clinical relevance	Positive n/N (%)
TMB-high (≥13 mut/Mb)	FDA-approved tissue-agnostic ICI indication	1/15 (6.7%)
TMB 10-<13 mut/Mb	Efficacy of ICI not confirmed	3/15 (20.0%)
MET amplification	MET inhibitors approved in NSCLC (OncoKB Level 3B)	1/7 (14.3%)
MGA (c.7396C>T p.R2466*)	Likely oncogenic (loss of function)	1/10 (10.0%)
MSI-H	FDA-approved tissue-agnostic ICI indication	0/14 (0.0%)
ERBB2/HER2 alteration (mutation or amplification)	Anti-HER2 strategies if present	0/9 (0.0%)
FGFR alteration (panel-reported)	FGFR-targeted therapy if present	0/8 (0.0%)
NTRK1/2/3 alteration (panel-reported)	TRK inhibitors if present	0/9 (0.0%)
RET alteration (panel-reported)	RET inhibitors if present	0/8 (0.0%)
BRAF V600E	BRAF/MEK inhibitors if present	0/8 (0.0%)
KRAS mutation	Common iCCA driver; informs biology	0/8 (0.0%)
PD-L1 ≥1%	Context-dependent ICI biomarker	0/3 (0.0%)

ICI, immune checkpoint inhibitor(s); **MSI**, microsatellite instability; **MSI-H**, microsatellite instability–high; **TMB**, tumor mutational burden
mut/Mb, mutations per megabase; **n/N**, number positive/number assessed; **PD-L1**, programmed death-ligand 1; NSCLC, non-small cell lung cancer
Denominators reflect only cases in which each biomarker was explicitly reported as assessed.
TMB/MSI values were derived from heterogeneous platforms (whole genome sequencing/whole exome sequencing/targeted panels/RNA-based reporting) and are shown as published.

Table 3. Treatment categories and clinical outcomes in *NIPBL::NACC1* fusion hepatic carcinoma

Treatment category	n	NED n (%)	AWD n (%)	DOD n (%)	Unknown n (%)	Median follow-up (IQR, months)
Surgery ± chemotherapy						
Surgery only	22	19 (86.4)	2 (9.1)	0 (0.0)	1 (4.5)	15.0 (10.0–36.0)
Surgery + adjuvant therapy	13	5 (38.5)	2 (15.4)	5 (38.5)	1 (7.7)	15.5 (8.5–24.5)
Neoadjuvant therapy + surgery	8	3 (37.5)	2 (25.0)	3 (37.5)	0 (0.0)	20.0 (8.5–35.5)
Systemic therapy without surgery[1]	5	0 (0.0)	3 (60.0)	2 (40.0)	0 (0.0)	12.0 (2.0–15.0)
Unknown / insufficient data	3	0 (0.0)	1 (33.3)	0 (0.0)	2 (66.7)	6.0 (not estimable)

n, number of patients; NED, no evidence of disease; AWD, alive with disease; DOD, died of disease; IQR, interquartile range.
[1]Includes radiotherapy and/or locoregional therapies when reported.
Unknown indicates outcome not reported or insufficient follow-up. Percentages are calculated within each treatment category.

Table 4. Clinicopathologic comparison of patients with no evidence of disease and those who died of disease in *NIPBL::NACC1* fusion hepatic carcinoma

Variable	No evidence of disease (n=27)	Died of disease (n=10)	p-Value
Age	42.0 (28.0–49.5)	25.0 (18.2–31.2)	**<0.01***
Sex (female)	22/27	9/10	0.64
Tumor size	12.0 (6.5–16.0)	21.5 (14.0–27.0)	**<0.01***
Major vascular invasion	0/26	4/10	**0.01***
Macroscopic findings			
Cystic areas	16/19	5/6	1.00
Hemorrhagic areas	9/19	6/6	**0.04***
Microscopic morphology			
Follicular/pseudoglandular	22/23	9/9	1.00
Papillary/pseudopapillary	2/23	2/9	0.30
Solid/insular	9/23	6/9	0.10
Trabecular	12/23	5/9	1.00
Microcystic	14/23	7/9	0.44
High-grade morphology	1/23	2/9	0.18
Neuroendocrine differentiation	18/24	8/10	1.00
Ki-67 index (%)	15.0 (10.0–45.0)	35.0 (24.0–45.0)	0.47
Necrosis	7/22	4/5	**0.04***
Vascular and/or perineural invasion	7/16	7/7	**0.01***
Focality (unifocal)	22/25	9/10	1.00
Positive surgical margins (R1)	1/20	4/7	**<0.01***
Follow-up (months)	13.0 (5.0–36.0)	22.0 (6.0–35.5)	0.82

Statistical comparisons were performed using Fisher's exact test, chi-square test, or Mann–Whitney U test, as appropriate.
*Statistically significant.

Figures

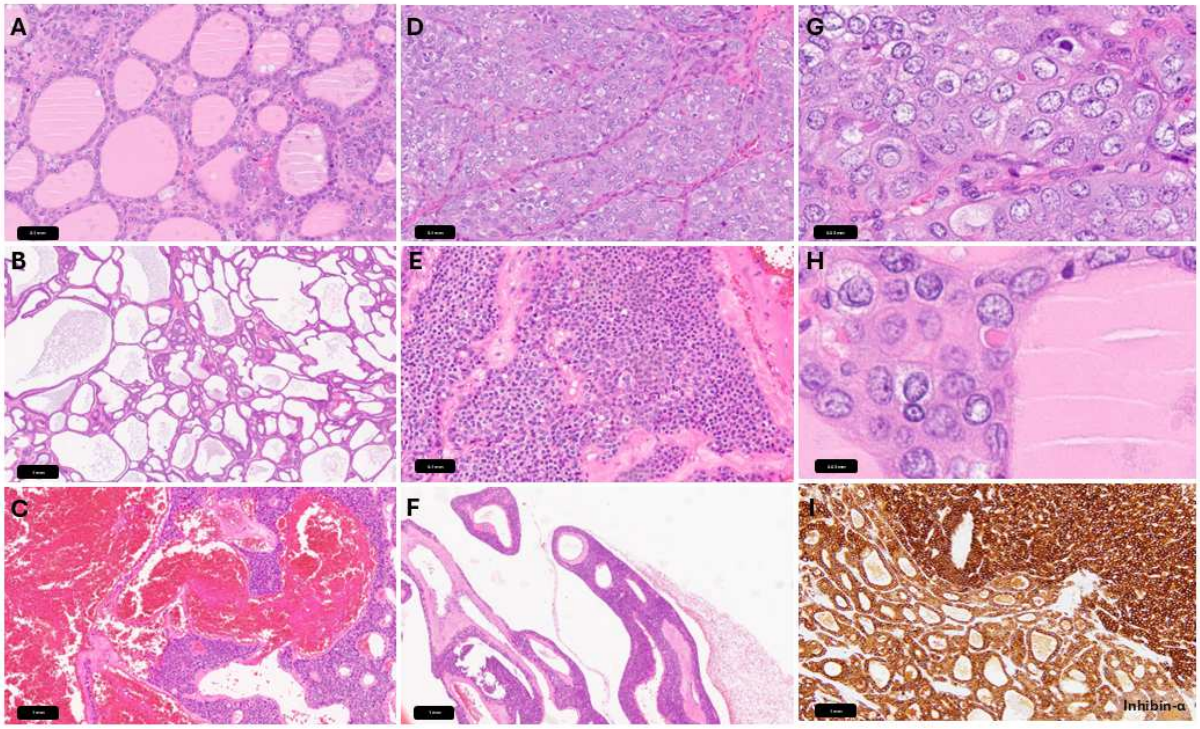

Figure 1

Figure 1

Figure 1. Morphologic and immunophenotypic spectrum of *NIPBL::NACC1* fusion hepatic carcinoma (NNFHC). Representative histologic features illustrating the architectural and cytologic heterogeneity of NNFHC. (A) Follicular morphology. (B) Microcystic architecture. (C) Microcystic architecture with prominent hemorrhagic areas. (D) Trabecular growth pattern. (E) Solid growth pattern. (F) Papillary architecture. At higher magnification, characteristic cytologic features of this entity are demonstrated, including intranuclear pseudoinclusions (G) and nuclear grooves (H). (I) Diffuse cytoplasmic inhibin-α expression by immunohistochemistry. Hematoxylin and eosin–stained sections unless otherwise indicated.

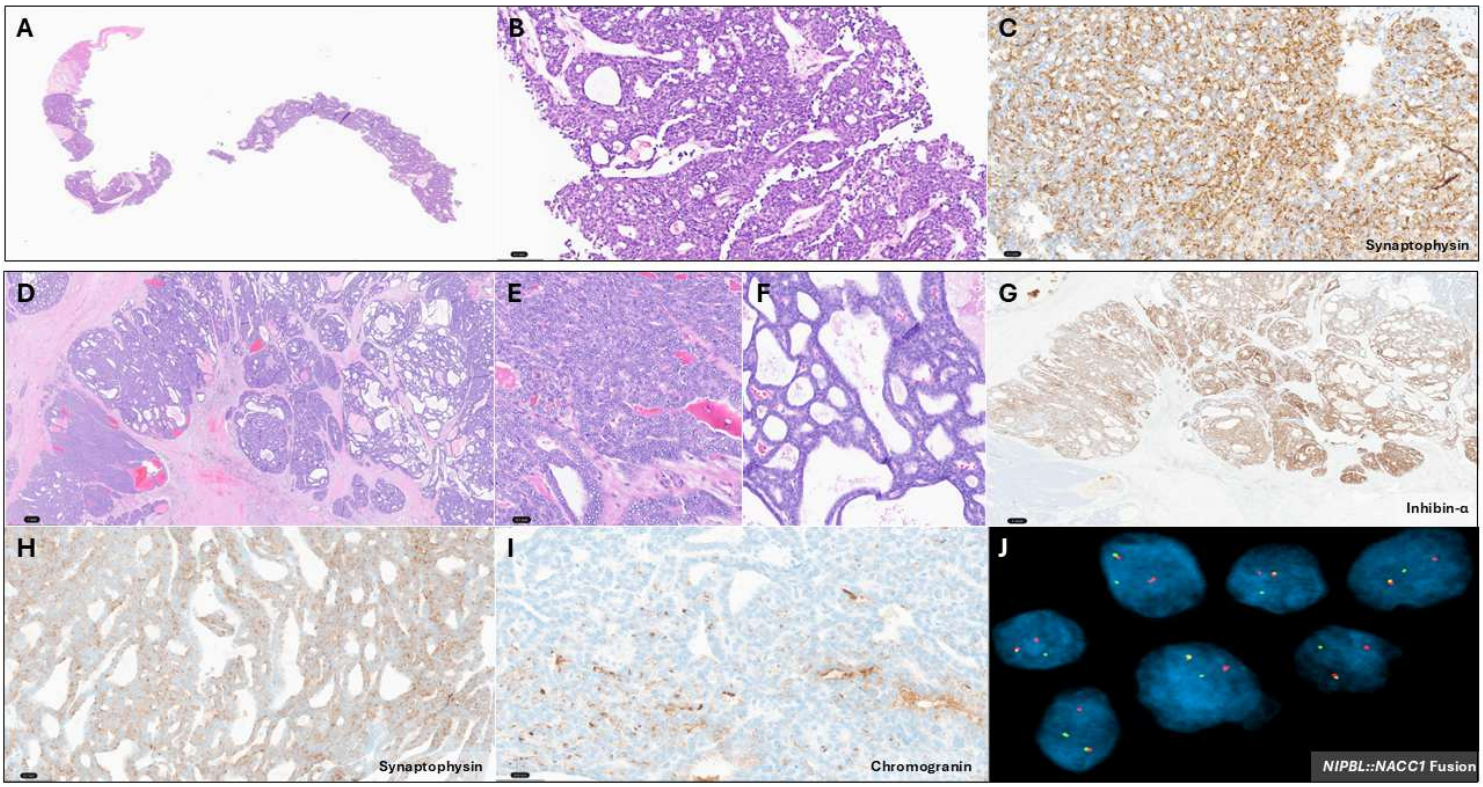

Figure 2

Figure 2

Figure 2. *NIPBL::NACC1* fusion hepatic carcinoma with metastasis to pancreas: a potential diagnostic pitfall. A middle-aged man was diagnosed with pancreatic neuroendocrine tumor, for which he received treatment without clinical response. Liver biopsy (top panel) demonstrates (A–B) follicular and trabecular architecture. (C) Tumor cells are positive for synaptophysin by immunohistochemistry, while chromogranin is negative (not shown). Pancreatic tumor resection (lower panel) demonstrates (D–F) follicular, trabecular, and cystic morphology. Tumor cells show strong expression of (G) inhibin, along with (H) synaptophysin and multifocal (I) chromogranin. (J) Fluorescence *in situ* hybridization assay confirms the *NIPBL::NACC1* gene fusion.

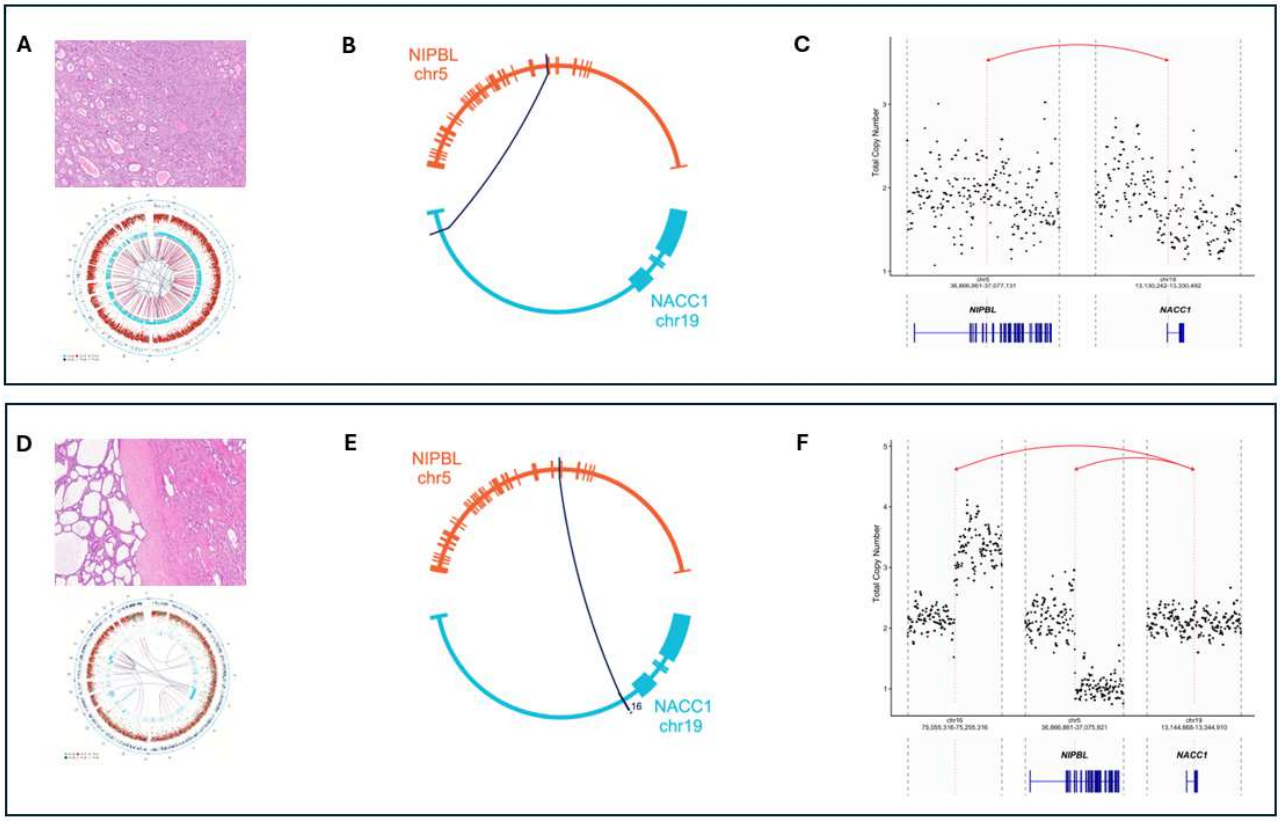

Figure 3

Figure 3. Complex structural variants are elucidated in a subset of *NIPBL::NACC1*fusion hepatic carcinoma. The top panel illustrates an example of a simple *NIPBL::NACC1* structural variant. (A) H&E and genome circos plot of Case 3. A cartoon of *NIPBL::NACC1* fusion (B) illustrates a simple interchromosomal rearrangement between chromosomes 5 and 19. Whole-genome sequencing structural variant plot (C) demonstrates a simple translocation involving *NIPBL* (chromosome 5, intron 9) and *NACC1*(chromosome 19, intron 1). The lower panel illustrates an example of a complex *NIPBL::NACC1* structural variant. (D) H&E and genome circos plot of Case 9. A cartoon of *NIPBL::NACC1* fusion (E) illustrates again a simple interchromosomal rearrangement involving chromosomes 5 and 19. However, whole-genome sequencing analysis elucidates a complex structural variant (F) that involves, in addition to *NIPBL* and *NACC1*, a rearrangement with chromosome 16 and associated copy-number alterations.

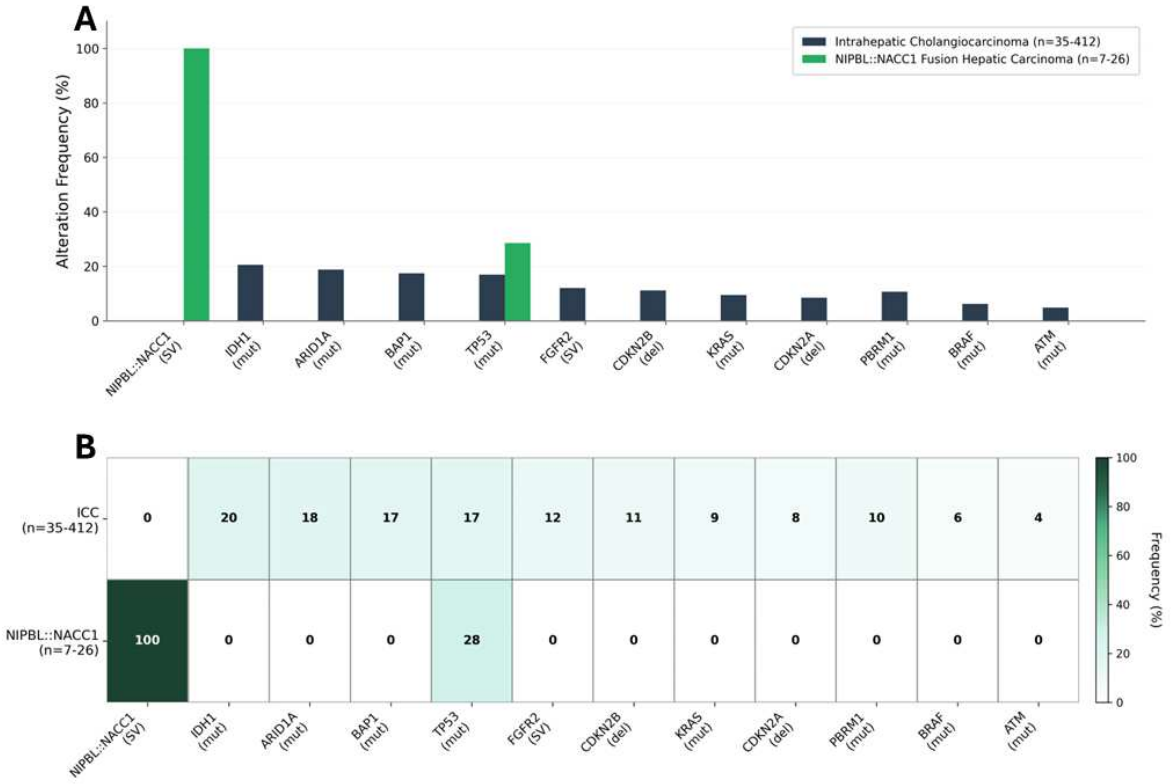

Figure 4

Figure 4

Figure 4. Comparative genomic landscape of *NIPBL::NACC1* fusion hepatic carcinoma (NNFHC) and intrahepatic cholangiocarcinoma (iCCA).(A) Frequency of selected genomic alterations and biomarkers in NNFHC and iCCA. NNFHC is characterized by a recurrent *NIPBL::NACC1* rearrangement and a relative absence of canonical iCCA-associated driver alterations, including *IDH1, ARID1A, BAP1, KRAS, FGFR2, CDKN2A*, and others. *TP53* represents the only overlapping alteration identified in both groups. A subset of NNFHC demonstrates high tumor mutational burden (TMB ≥10 mutations/Mb). (B) Heatmap representation of alteration frequencies across the same set of genes and biomarkers, illustrating the distinct genomic profile of NNFHC compared to iCCA. Values are expressed as percentages. Denominators vary across genes due to differences in sequencing platforms and data availability and are indicated for each alteration.

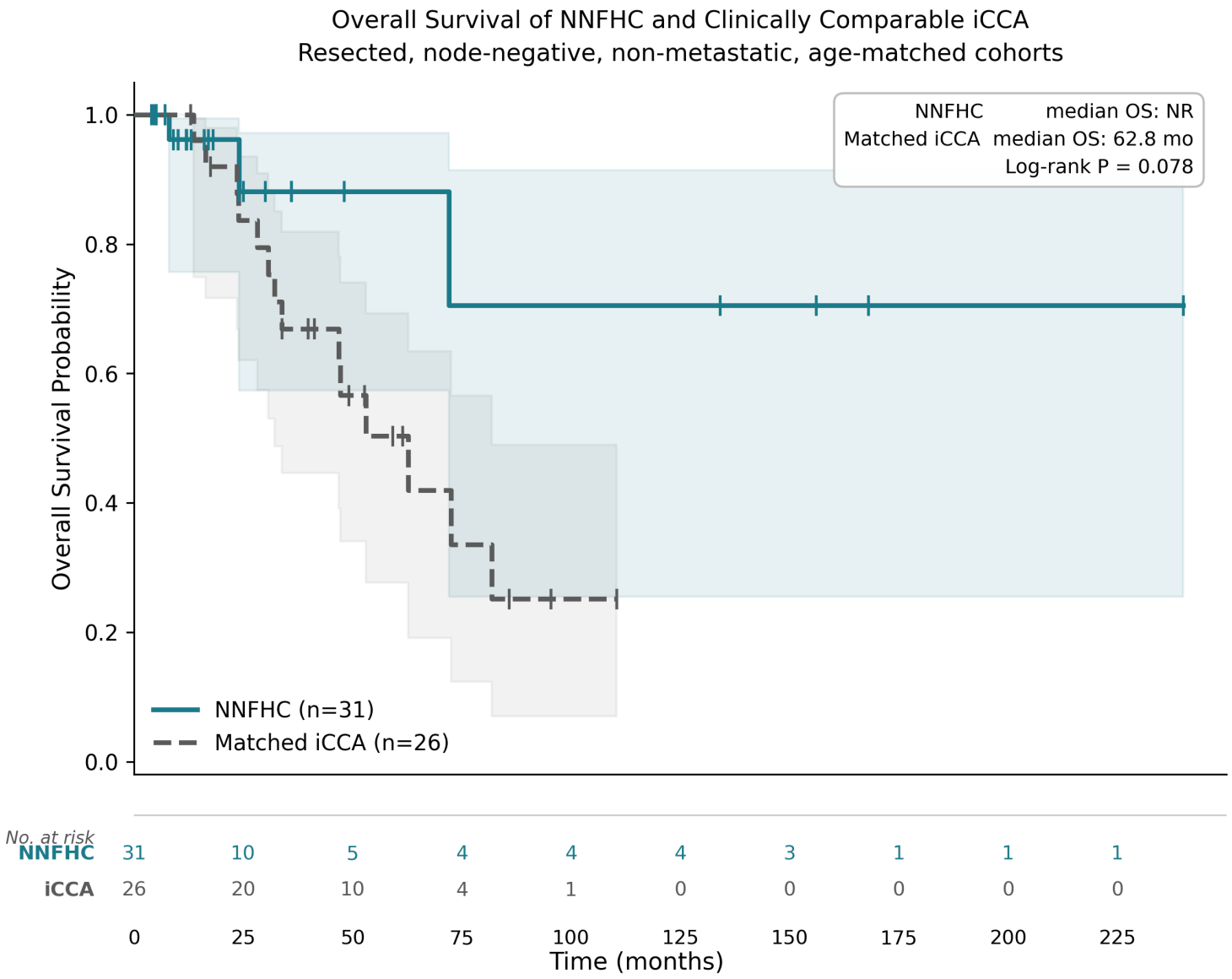

Figure 5

Figure 5. Overall survival of *NIPBL::NACC1* fusion hepatic carcinoma (NNFHC) compared with clinically comparable intrahepatic cholangiocarcinoma (iCCA). Kaplan–Meier overall survival curves comparing NNFHC (n=31) with a matched iCCA cohort (n=26) restricted to resected, node-negative, non-metastatic patients. Matching was performed by nearest-neighbor age-matching with replacement; after deduplication of matched controls, the final comparison cohort comprised 31 NNFHC and 26 unique iCCA patients. Median overall survival was not reached in the NNFHC cohort and was 62.8 months in the matched iCCA cohort (log-rank P=0.078). Median follow-up was 16.0 months for NNFHC and 61.4 months for iCCA. Shaded areas represent 95% confidence intervals. Vertical tick marks indicate censored observations.

Supplementary Files

This is a list of supplementary files associated with this preprint. Click to download.

- 111126NIPBLNACC1SupplTable1.docx
- 062426NIPBLNACC1SupplTable2.docx
- 112026NIPBLNACC1SupplTable3.docx
- 062426NIPBLNACC1SupplTable4.docx