Research Square

Preprints are preliminary reports that have not undergone peer review.
They should not be considered conclusive, used to inform clinical practice,
or referenced by the media as validated information.

Bilateral low-lying soleus and flexor hallucis longus muscle bellies: an incidental MRI finding that mimics posterior ankle and tarsal tunnel pathology

Berna Dirim Mete[1]

bernadirim@gmail.com

İzmir Demokrasi Üniversitesi

Seçil Aydın[1]

İzmir Demokrasi Üniversitesi

Bengisu Tankut[1]

İzmir Demokrasi Üniversitesi

Mehmet Bilgin Eser

İzmir Demokrasi Üniversitesi

Research Article

Keywords: Flexor hallucis longus, Soleus, Low-lying muscle belly, Anatomical variation, Tarsal tunnel syndrome, Magnetic resonance imaging

Posted Date: November 26th, 2026

DOI: https://doi.org/10.21203/rs.3.rs-11799423/v1

License: This work is licensed under a Creative Commons Attribution 4.0 International License.
Read Full License

Additional Declarations: No competing interests reported.

Abstract

Purpose

Low-lying muscle bellies of the flexor hallucis longus (FHL) and soleus are anatomical variations that can be overlooked in hindfoot imaging and surgical planning. We report bilateral low-lying soleus and FHL muscle bellies detected on MRI in a young man who presented with left medial ankle and plantar tingling, numbness and mild pain, running-related posterior ankle pain and bilateral posterior ankle swelling, and discuss their anatomical, radiological and surgical relevance.

Methods

A 25-year-old man under investigation for chronic inflammatory back pain, sacroiliitis and inflammatory arthritis presented with tingling, numbness and mild pain over the medial left ankle and the sole, posterior ankle pain that increased with running, and a sensation of posterior ankle swelling. Tinel's test over the left posterior tibial nerve was positive. MRI of both ankles was performed. Clinical, laboratory and imaging data were reviewed. Written informed consent was obtained.

Results

On MRI of both ankles the FHL and soleus muscle bellies extended lower than usual, whereas the Achilles tendon, plantar fascia, flexor tendons and peroneal tendons were normal. On the left, at the level of the distal tibiofibular joint, the abnormally low-lying and bulky FHL muscle obliterated the fat plane around the posterior tibial nerve medially and indented the nerve, and its musculotendinous junction reached the distal talus. Routine complete blood count, CRP and ESR were normal, HLA-B27 was negative, and the other laboratory tests were unremarkable

Conclusion

Low-lying soleus and FHL muscle bellies should be considered in the differential diagnosis of tarsal tunnel syndrome and posterior ankle impingement, should not be mistaken for a mass, edema or tear on MRI performed for inflammatory disease, and should be sought on MRI before FHL tendon transfer or hindfoot endoscopy.

Introduction

The flexor hallucis longus (FHL) is a strong muscle of the deep posterior compartment whose tendon passes through the posteromedial ankle, next to the tarsal tunnel. Its fibers normally give way to the tendon proximal to the malleoli. A muscle belly that extends distal to the tibia, even into the tarsal tunnel,

is termed a "low-lying" FHL. This variant has been linked to posteromedial ankle pathology, but the normative position of the muscle belly, and how it changes over life, remain poorly defined [10].

In a cadaver study, Pichler et al. described three typical FHL muscle belly patterns: a long lateral and short medial belly, equal medial and lateral bellies, and a long medial and short lateral belly. A lateral belly alone was found in very few specimens. They recommended MRI before FHL transfer and recommended that these features be considered when interpreting ultrasound and MRI [7]. Wan-ae-loh et al. classified muscle belly types, low-lying bellies and FHL–flexor digitorum longus (FDL) tendon connections, and found a low-lying lateral belly in most specimens [12]. Vega et al. emphasized that knowing the anatomical variations of the FHL tendon makes hindfoot endoscopy safer [11].

Because the tunnel has a fixed volume, a low-lying muscle belly can compress the posterior tibial nerve or its branches and cause burning, numbness, tingling and plantar pain [4]. In posterior ankle impingement, low-lying FHL fibers may be pinched against the ligament, predisposing to FHL tendon damage that can be seen on MRI [6]. Cases linking the FHL to an accessory FDL muscle belly have also been described [1]. A low-lying soleus muscle belly is similarly relevant to the area around the Achilles tendon and to hindfoot surgery. Reports of bilateral, simultaneous low-lying soleus and FHL muscle bellies are scarce; to our knowledge, the only description of the two variants together is a unilateral teaching case of tarsal tunnel syndrome [9]. We describe a bilateral case, detected on MRI.

Materials and methods

This is a single-patient report. The clinical record, laboratory results and MRI examinations of both ankles were reviewed. Written informed consent for participation and for publication of the case and its images was obtained.The field of view of the MRI examinations did not extend far enough along the leg to allow the muscle bellies to be measured, so the position of the soleus and FHL muscle bellies was assessed qualitatively against the anatomical landmarks given in Imaging findings.

MRI of both ankles was performed on a 1.5 T system (MAGNETOM Amira, Siemens Healthineers, Erlangen, Germany) using a dedicated ankle coil (1.5 T Total imaging Matrix [Tim] coil). The protocol included T1-weighted and fat-suppressed proton density-weighted sequences in the sagittal, coronal and axial planes, with a field of view of 140 × 140 mm. No contrast medium was administered. The images were evaluated by a musculoskeletal radiologist with 25 years of experience.

Results

Clinical presentation

A 25-year-old man, presented with tingling and numbness and mild pain over the medial aspect of the left ankle and the sole of the foot, posterior ankle pain that increased with running, and a sensation of swelling behind the left ankle. He also noted swelling behind the right ankle, but had no tingling or pain in the right foot or ankle. He had no history of trauma.

On examination of the left side there was mild swelling and a full appearance of the ankle and posterior foot. The patient described a sensation of catching or snagging during hallux flexion. Hallux range of motion, FHL and triceps surae strength, and the ankle joint examination were normal. In keeping with his complaints, Tinel's test was positive over the course of the posterior tibial nerve, posterior to the distal ankle.

Examination of the right ankle likewise showed mild swelling and a full appearance of the ankle and posterior foot. Hallux range of motion, FHL and triceps surae strength, and ankle joint movements were normal. Tinel's test was negative.

MRI of both ankles was requested.

Imaging findings

On right ankle MRI, the FHL muscle belly extended further distally than normal: on sagittal T1-weighted and coronal fat-suppressed proton density-weighted images it continued below the level of the distal tibia, and on axial T1-weighted images its fibers were still present at the malleolar level, next to the posterior tibial nerve (Fig. 1). The soleus muscle belly was also low-lying (Fig. 1a). The signal of both muscles was isointense to other muscles on all sequences, and no abnormal signal was seen. The included Achilles tendon, plantar fascia, extensor and peroneal tendons, and the ankle ligaments were normal.

On left ankle MRI, the FHL extended distally at the ankle beyond its usual level (Fig. 2). At the level of the distal tibiofibular joint, the abnormally low-lying and variably bulky FHL muscle obliterated the fat plane between the posterior tibial nerve and the muscle medially and indented the posterior tibial nerve (Fig. 2c–e). The medial part of the muscle and the musculotendinous junction extended distally as far as the talus (Fig. 2f). The soleus muscle belly was also low-lying. The signal of these muscles was isointense to other muscles on all sequences, and no abnormal signal was seen. The included Achilles tendon, plantar fascia, extensor and peroneal tendons, and the ankle ligaments were normal.

Position of the muscle bellies. The field of view of both examinations was not wide enough to measure the muscle bellies, so their position was judged against anatomical landmarks. For the FHL, a muscle belly is called low-lying when it extends distal to the point where the FHL tendon crosses the distal osseous tibia [12]. Because a lateral belly ending slightly below this point is common (66% of 62 cadaveric specimens, on average 13 mm beyond it [12]; mean musculotendinous junction 12–15 mm distal to the posteroinferior tibial margin on MRI [2]), we regarded as significant a belly continuing to the level of the talus and the tarsal tunnel, where muscle tissue is not expected [9]. On this basis the FHL was low-lying on both sides: on the right its fibers reached the malleolar level, and on the left the muscle and its musculotendinous junction reached the distal talus, well beyond the average positions above.

For the soleus, no consensus numerical cut-off for a low-lying belly has been published. Its musculotendinous junction, the most distal point of the muscle fibers, normally lies proximal to the

malleoli (Fig. 3a); in an MRI series the free Achilles tendon, from the junction to the calcaneal insertion, measured 0.85–7.1 cm (mean 3.85 cm), and the lowest soleus junction lay 0.8 cm from the calcaneus [3]. In both of our patient's ankles, soleus muscle fibers extended distally, posterior to the Achilles tendon, to the level of the talus and malleoli (Fig. 1a; Fig. 2c, d), toward the lower end of the reported range, and the soleus was therefore considered low-lying on both sides.

Laboratory findings, treatment and follow-up

Routine complete blood count, CRP and ESR were normal, HLA-B27 was negative, and the other laboratory tests were unremarkable. Conservative treatment with topical and oral anti-inflammatory drugs was given.

Discussion

The notable point in this case is that low-lying soleus and FHL muscle bellies were found together and on both sides. Bilateral occurrence suggests a developmental anatomical variation rather than a traumatic or acquired change.

Anatomical and embryological considerations

Descriptions of FHL muscle belly morphology (long lateral/short medial, equal, long medial/short lateral, lateral only) [7], together with classifications of low-lying muscle bellies and FHL–FDL tendon connections [5, 12], provide a framework for reporting this variation. Because the normative position of the muscle belly is still debated [10], a numerical definition tied to a fixed landmark, such as the posteroinferior margin of the distal tibia [2, 12], would make reports easier to compare. In our patient this was not possible because the field of view of the examinations was too limited for measurement, so the muscle bellies were assessed qualitatively.

The crural muscles arise from myogenic precursors that migrate into the limb bud and split into muscle masses, and the level of the musculotendinous junction is set as muscle and tendon differentiate; a low-lying belly may therefore reflect a developmental variation in how far muscle differentiation extends along the tendon [7].

Clinical significance

Because tunnel volume is fixed, FHL fibers reaching the tarsal tunnel can compress the posterior tibial nerve or its branches and produce tarsal tunnel-like symptoms [4]. In posterior ankle impingement, low-lying fibers may be pinched against the ligament and damage the FHL tendon [6]. In our patient the variation was bilateral, but the symptoms and signs were largely left-sided. On the left, the abnormally bulky, low-lying FHL obliterated the fat plane around the posterior tibial nerve and indented it, Tinel's test over the nerve was positive, and the patient reported tingling, numbness and mild pain of the medial

ankle and sole; the catching sensation during hallux flexion may reflect movement of the low-lying muscle belly within the tunnel. On the right, where the muscle bellies were also low-lying, he had only a sensation of swelling, and Tinel's test was negative. This side-by-side correspondence between nerve contact, symptoms and Tinel's sign supports a contribution of the low-lying FHL to the left-sided symptoms, while the right ankle illustrates that low-lying muscle bellies are asymptomatic in many cases. The normal signal of the FHL and other flexor tendons and the normal appearance of the Achilles tendon and plantar fascia argue against tendon pathology as the explanation. The symptoms such variants can cause are listed in the Introduction. A low-lying muscle belly should not be mistaken for a mass, edema or tear in such examinations [7].

Surgical and imaging implications

FHL tendon transfer is a preferred method for reconstructing chronic neglected Achilles tendon ruptures. Saad et al. recommended preoperative radiological assessment to show that the FHL muscle and tendon are normal, intact and suitable for transfer [8]. According to Pichler et al., if the muscle belly morphology on preoperative MRI would not allow adequate closure of the soft tissue defect, alternatives such as triceps surae augmentation, plantaris tendon interweaving or peroneus brevis tendon transfer should be considered [7]. A low-lying FHL muscle belly may help cover the defect after transfer; whether this applies to our patient cannot be judged, because no surgery was performed. In endoscopic hindfoot procedures, knowledge of FHL variations improves safety [11]. On ultrasound or MRI, these variations should not be mistaken for a pathological mass, edema or tear [7], and accompanying muscle variations such as an accessory FDL should be kept in mind in the differential diagnosis [1].

Limitations

This is a single case. Both ankles were assessed by MRI, but the field of view did not allow the position of the soleus and FHL muscle bellies to be measured, so the assessment is qualitative and lacks standardized measurement. Nerve involvement is inferred from clinical examination and MRI. Accompanying inflammatory findings may have affected image interpretation.

Conclusion

Low-lying soleus and FHL muscle bellies are a rare but clinically important anatomical variation. They should be considered in the differential diagnosis of patients with posteromedial ankle pain and tarsal tunnel-like symptoms, should not be confused with pathological findings on MRI performed for inflammatory disease, and should be evaluated on preoperative MRI in patients planned for FHL transfer or hindfoot endoscopy.

Declarations

Competing interests We declare any interests from the past three years, or state that none exist.

Funding No funding was received.

Ethics approval The approval was not required for a single case report We confirm adherence to the Declaration of Helsinki.

Consent to participate and consent to publish Written informed consent for participation and for publication of this case and its images was obtained from the patient.

Author contributions B Dirim Mete: Image analysis, manuscript writing, supervision; S Aydın: Data collection, manuscript writing, B Tankut: Data collection, manuscript writing, M Bilgin Eser: The schematic illustration.

Acknowledgments

Use of artificial intelligence During the preparation of this work, the authors used Claude (Anthropic, November 2026) to create the schematic illustration in Fig. 3, to assist with the literature search, English text editing, preparation of the figure panels and formatting of the manuscript according to the journal's guidelines. The authors reviewed and edited all output and take full responsibility for the content of the publication.

References

1. Batista JP, del Vecchio JJ, Golanó P, Vega J (2015) Flexor digitorum accessorius longus: importance of posterior ankle endoscopy. Case Rep Orthop 2015:823107. https://doi.org/10.1155/2015/823107
2. Chaclas N, Swanson ME, Patel V, Nguyen JC, Maguire KJ (2026) The effect of flexor hallucis longus morphology on os trigonum syndrome. Orthop J Sports Med 14(4):23259671261422731. https://doi.org/10.1177/23259671261422731
3. Drakonaki EE, Gataa KG, Szaro P (2021) The anatomical variant of high soleus muscle may predispose to tendinopathy: a preliminary MR study. Surg Radiol Anat 43(10):1681–1689. https://doi.org/10.1007/s00276-021-02768-9
4. Khodatars D, Gupta A, Welck M, Saifuddin A (2022) An update on imaging of tarsal tunnel syndrome. Skeletal Radiol 51:2075–2095. https://doi.org/10.1007/s00256-022-04072-y
5. Maddox MB, Mashaw SA, MacDonald EM et al (2024) Four tendinous slips of flexor hallucis longus tendon: a case report. Cureus 16(5):e59601
6. Moati JC (2024) Syndrome du carrefour postérieur de la cheville. Rev Rhum 91(2). https://doi.org/10.1016/S0246-0521(24)47849-2
7. Pichler W, Tesch NP, Grechenig W, Tanzer K, Grasslober M (2005) Anatomical variations of the flexor hallucis longus muscle and the consequences for tendon transfer. A cadaver study. Surg Radiol Anat 27:227–231. https://doi.org/10.1007/s00276-005-0314-y
8. Saad A, McLoughlin E, Hanif U, Iqbal A, James S, Botchu R (2021) [article title to be completed]. Indian J Med Sci 73(2):197–202

9. Staikidou I, Pikoulas K, Giannikouris G, Mantzikopoulos G (2014) Tarsal tunnel syndrome due to aberrant muscle. Eurorad case 11566. https://doi.org/10.1594/EURORAD/CASE.11566
10. Swanson ME, Chaclas N, Patel V, Sarkar S, Nguyen J, Maguire K (2024) How low is low? A normative study defining flexor hallucis longus anatomic location. Med Sci Sports Exerc 56(10S):424. https://doi.org/10.1249/01.mss.0001056232.64552.22
11. Vega J, Redó D, Savín G et al (2017) Anatomical variations of flexor hallucis longus tendon increase safety in hindfoot endoscopy. Knee Surg Sports Traumatol Arthrosc 25:1929–1935. https://doi.org/10.1007/s00167-017-4465-2
12. Wan-ae-loh P, Huanmanop T, Agthong S, Chentanez V (2022) Type and location of flexor hallucis longus musculotendinous junctions and its tendinous interconnections with flexor digitorum longus tendon: pertinent data for tendon harvesting and transfer. Folia Morphol 81(3):766–776
13. Batista JP, del Vecchio JJ, Golanó P, Vega J (2015) Flexor digitorum accessorius longus: importance of posterior ankle endoscopy. Case Rep Orthop 2015:823107. https://doi.org/10.1155/2015/823107
14. Chaclas N, Swanson ME, Patel V, Nguyen JC, Maguire KJ (2026) The effect of flexor hallucis longus morphology on os trigonum syndrome. Orthop J Sports Med 14(4):23259671261422731. https://doi.org/10.1177/23259671261422731
15. Drakonaki EE, Gataa KG, Szaro P (2021) The anatomical variant of high soleus muscle may predispose to tendinopathy: a preliminary MR study. Surg Radiol Anat 43(10):1681–1689. https://doi.org/10.1007/s00276-021-02768-9
16. Khodatars D, Gupta A, Welck M, Saifuddin A (2022) An update on imaging of tarsal tunnel syndrome. Skeletal Radiol 51:2075–2095. https://doi.org/10.1007/s00256-022-04072-y
17. Maddox MB, Mashaw SA, MacDonald EM, Mira AJ, Parker WJ, Fakoya AO (2024) Four tendinous slips of flexor hallucis longus tendon: a case report. Cureus 16(5):e59601 doi.org
18. Moati JC (2024) Syndrome du carrefour postérieur de la cheville. Rev Rhum 91(1). doi.org
19. Pichler W, Tesch NP, Grechenig W, Tanzer K, Grasslober M (2005) Anatomical variations of the flexor hallucis longus muscle and the consequences for tendon transfer. A cadaver study. Surg Radiol Anat 27:227–231. https://doi.org/10.1007/s00276-005-0314-y
20. Saad A, McLoughlin E, Hanif U, Iqbal A, James S, Botchu R (2021) Flexor hallucis longus augmentation for Achilles tendon–is pre-operative evaluation of flexor hallucis longus by MRI required? Indian J Med Sci 73(2):197–202
21. Staikidou I, Pikoulas K, Giannikouris G, Mantzikopoulos G (2014) Tarsal tunnel syndrome due to aberrant muscle. Eurorad Case 11566. https://doi.org/10.1594/EURORAD/CASE.11566
22. Swanson ME, Chaclas N, Patel V, Sarkar S, Nguyen J, Maguire K (2024) How low is low? A normative study defining flexor hallucis longus anatomic location. Med Sci Sports Exerc 56(10S):424. https://doi.org/10.1249/01.mss.0001056232.64552.22
23. Vega J, Redó D, Savín G, Malagelada F, Dalmau-Pastor M (2017) Anatomical variations of flexor hallucis longus tendon increase safety in hindfoot endoscopy. Knee Surg Sports Traumatol Arthrosc 25:1929–1935. https://doi.org/10.1007/s00167-017-4465-2

24. Wan-ae-loh P, Huanmanop T, Agthong S, Chentanez V (2022) Type and location of flexor hallucis longus musculotendinous junctions and its tendinous interconnections with flexor digitorum longus tendon: pertinent data for tendon harvesting and transfer. Folia Morphol 81(3):766–776 doi.org

Figures



Figure 1

Right ankle MRI. Low-lying soleus and flexor hallucis longus (FHL) muscle bellies. **a** Sagittal T1-weighted image: arrows indicate the low-lying FHL muscle belly; the open arrow indicates the low-lying soleus muscle belly. **b** Coronal fat-suppressed proton density-weighted image through the posterior distal crural region: arrows indicate the low-lying FHL muscle belly and the line arrow indicates its tendon. **c**, **d** Axial T1-weighted images from proximal (**c**) to distal (**d**): arrows indicate the low-lying FHL muscle belly and line arrows indicate the posterior tibial nerve.



Figure 2

Left ankle MRI. Distal extension of the FHL muscle belly at the ankle. **a** Coronal T1-weighted and **b** coronal fat-suppressed proton density-weighted images through the distal crural region and the posterior ankle: arrows indicate the low-lying FHL muscle belly. **c**–**e** Axial T1-weighted images from proximal to distal: the abnormally low-lying FHL muscle (arrows) obliterates the fat plane around the posterior tibial nerve (line arrows) medially and contacts it; open arrows indicate the low-lying soleus muscle (**c**, **d**). **f** Sagittal fat-suppressed proton density-weighted image through the ankle: the FHL muscle (arrows) extends as far as the posterior aspect of the talus.

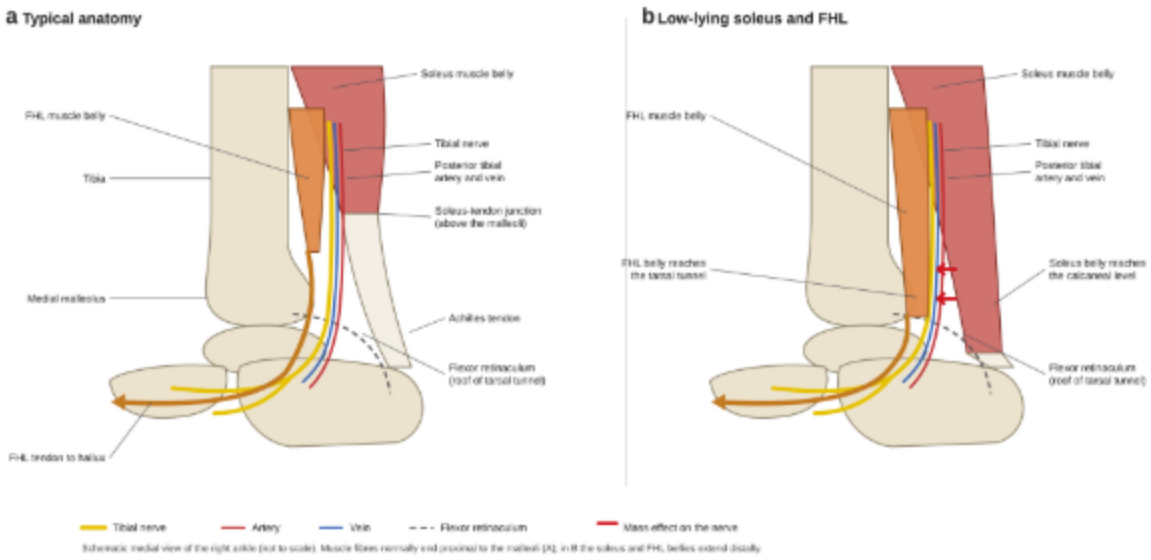

Figure 3

Schematic illustration of the relationship between low-lying soleus and flexor hallucis longus (FHL) muscle bellies and the tarsal tunnel, medial view of the right ankle, not to scale. **a** Typical anatomy: the soleus muscle belly ends at the musculotendinous junction proximal to the malleoli, and the FHL muscle belly ends above the tarsal tunnel, so that only the FHL tendon, the tibial nerve and the posterior tibial artery and vein pass beneath the flexor retinaculum. **b** Low-lying variant: the soleus belly extends to the level of the calcaneus and the FHL belly extends into the tarsal tunnel, where the additional muscle volume may compress the tibial nerve (red arrows). The vector drawing was generated with the assistance of an artificial intelligence tool (Claude, Anthropic) from the authors' anatomical description, and was reviewed and corrected by the authors.