Research Square

Preprints are preliminary reports that have not undergone peer review.
They should not be considered conclusive, used to inform clinical practice,
or referenced by the media as validated information.

# Clinical Improvement Despite Limited Strength Recovery After Independent Latissimus Dorsi and Teres Major Transfer for Irreparable Subscapularis Tears

**Chang Hee Baek**

Yeosubaek@gmail.com

Yeosu Baek Hospital

**Bo Taek Kim**

Yeosu Baek Hospital

**Jung Gon Kim**

Yeosu Baek Hospital

**Chaemoon Lim**

Yeosu Baek Hospital

**Seung Jin Kim**

Yeosu Baek Hospital

**Research Article**

**Keywords:** latissimus dorsi transfer, teres major transfer, subscapularis tear, irreparable rotator cuff tear, tendon transfer, muscle strength

**Posted Date:** November 27th, 2026

**DOI:** https://doi.org/10.21203/rs.3.rs-11757888/v1

**License:** This work is licensed under a Creative Commons Attribution 4.0 International License.
Read Full License

**Additional Declarations:** No competing interests reported.

# Abstract

**Purpose**

This study evaluated the clinical of independent anterior latissimus dorsi (LD) and teres major (TM) tendon transfer for irreparable subscapularis tears.

**Methods**

Patients with irreparable subscapularis tears who underwent independent anterior LD and TM tendon transfer between May and November 2017 were retrospectively reviewed. VAS, Constant, ASES, ROM, muscle strength, radiographic parameters, and postoperative tendon integrity were assessed preoperatively and at final follow-up. Patients lost to follow-up or incomplete data were excluded.

**Results**

After excluding 2 patients, 11 patients were included, with a mean follow-up of 104 ± 2.7 months. VAS, Constant, and ASES scores improved significantly at final follow-up (all $P < .001$). Forward elevation and internal rotation improved significantly, whereas muscle strength did not improve significantly in any direction. AHD decreased significantly ($P = .002$), while progression in Hamada grade was not significant ($P = .082$). Hamada grade progressed by 1 grade in 4 patients and 2 grades in 1 patient. Postoperative MRI revealed retears of the transferred tendons in 2 patients.

**Conclusion**

Independent anterior LD and TM tendon transfer improved pain, shoulder function, FE, and IR in patients with irreparable subscapularis tears. However, muscle strength, including IR strength, did not improve significantly despite these clinical improvements.

**Level of Evidence** IV; Therapeutic Study


# Introduction

Subscapularis deficiency disrupts the anterior component of the transverse force couple, resulting in pain, weakness, loss of internal rotation strength, and anterior instability of the humeral head.[1, 2] Among joint-preserving procedures, latissimus dorsi (LD) transfer has emerged as an alternative treatment for irreparable subscapularis tear because its anteriorly directed transfer provides a line of pull that more closely resembles that of the native subscapularis than pectoralis major (PM) transfer.[3–5] However, isolated LD transfer may not fully restore the complex force couple of the subscapularis, particularly with respect to anterior stability and humeral head depression.[4, 6, 7] To address these limitations, combined transfer of the LD and teres major (TM) tendons (LDTM) transfer has been introduced. The addition of the TM may augment the force-generating capacity of the reconstruction and contribute to restoration of anterior stability and glenohumeral kinematics. Biomechanical and clinical

studies have reported favorable results following combined anterior LDTM transfer, including improvements in pain, shoulder function, range of motion (ROM), muscle strength, and patient-reported outcomes.[7–11]

Despite these encouraging results, conventional anterior LDTM transfer involves transferring the LD and TM as a combined tendon unit.[8, 9] Although this approach allows both muscles to contribute to the reconstruction, transferring the 2 tendons together may limit the ability to independently adjust the position, tension, and direction of pull of each tendon. The LD and TM have distinct anatomic origins, muscle architectures, and functional roles, and their individual force vectors may therefore contribute differently to restoration of the deficient anterior force couple.[12, 13] Independent transfer of the LD and TM may allow each tendon to be positioned and tensioned separately, potentially providing greater flexibility in reproducing the desired force vectors and optimizing the reconstruction according to the patient's individual anatomy and pattern of cuff deficiency.[12] However, whether this theoretical advantage translates into improved clinical outcomes or recovery of shoulder strength remains unknown. In particular, it is unclear whether independent transfer of both tendons can restore internal rotation strength, which is an important functional consequence of subscapularis deficiency.

Therefore, the purpose of this study was to evaluate the clinical and structural outcomes, including muscle strength, of patients who underwent independent anterior LD and TM tendon transfers for irreparable subscapularis tears. It was hypothesized that independent transfer of the LD and TM would provide favorable clinical and structural outcomes and improve shoulder muscle strength in patients with irreparable subscapularis tears.

## Methods

This retrospective study was approved by the Institutional Review Board, and the requirement for informed consent was waived owing to the retrospective design of the study and the lack of additional harm to the patients.

# Patient Selection

This retrospective study reviewed the medical records of patients who underwent independent anterior LD and TM tendon transfers for irreparable subscapularis tears between May 2017 and November 2017. Surgical indication were persistent shoulder pain and dysfunction that significantly impaired daily activities despite 3–6 months of conservative treatment; an irreparable subscapularis tear classified as Lafosse[14] grade ≥ 4; advanced fatty infiltration of the subscapularis classified as Goutallier[15] grade ≥ 3; intact LD and TM muscle function; and absence of advanced glenohumeral arthritis, defined as Hamada[16] stage < 3. Patients were excluded if they had incomplete clinical data, or were lost to follow-up.

## Surgical Technique

All independent anterior LD and TM tendon transfers were performed by a single senior surgeon (C.H.B.). Patients were positioned in the beach-chair position. Through a deltopectoral approach, the reparability of the subscapularis tendon was assessed intraoperatively. When direct repair to the native footprint was not feasible, independent anterior LD and TM tendon transfers were performed. Tears of the long head of the biceps tendon were treated with tenotomy (n = 6).

For the transfer, the deltopectoral incision was extended distally to the inferior border of the PM tendon. When necessary, a limited release of the PM tendon was performed to expose the humeral insertions of the LD and TM. The LD and TM tendons were identified separately and harvested independently while preserving their individual tendon structures. Each tendon was prepared separately and reinforced with No. 2 nonabsorbable Krackow sutures to facilitate tendon passage, tensioning, and fixation. [Fig. 1A]

The lesser tuberosity was exposed and prepared with a burr to remove the cortical surface and create a bleeding bone bed, thereby promoting tendon-to-bone healing. [Fig. 1B] The harvested LD tendon was transferred anteriorly beneath the PM and positioned over the prepared lesser tuberosity. With the arm positioned in approximately 45° of abduction and maximal internal rotation, the TM tendon was transferred separately from the LD and positioned at the proximal humerus adjacent to the bicipital groove. [Fig. 1C] The TM tendon was independently tensioned and fixed at the proximal humerus using a double-row suture-bridge technique with suture anchors. Then, the LD tendon was tensioned and secured to the lesser tuberosity using a suture anchor. Additional fixation was performed using 2 knotless anchors to create a double-row suture-bridge construct, providing broad tendon-to-bone contact over the prepared lesser tuberosity.

The LD and TM tendons were fixed independently at separate anatomic locations, allowing independent positioning and tensioning of each tendon. [Fig. 1D] After completion of fixation, the shoulder was gently taken through a full ROM to confirm stable fixation of both transferred tendons and to ensure the absence of excessive tension, mechanical impingement, or restriction of motion.

## Postoperative Rehabilitation

Postoperatively, the shoulder was protected in a brace with the arm maintained in internal rotation for 8 weeks. During this period, shoulder motion was restricted to allow healing of the transferred LD and TM tendons. Following brace removal, passive and assisted ROM exercises were initiated and progressively advanced to active shoulder motion according to the patient's tolerance. A structured strengthening program was commenced at approximately 12 weeks after surgery and gradually intensified thereafter. Patients were generally advised to avoid heavy lifting, repetitive manual activities, and strenuous overhead use of the operated arm for the first 6 months, after which these activities were resumed based on individual clinical recovery and functional status.

## Clinical Assessment

Demographic and clinical data, including age, sex, body mass index, hand dominance, symptom duration, smoking status, relevant medical comorbidities, and history of previous rotator cuff surgery, were collected from the medical records. Clinical outcomes were assessed preoperatively and at the final follow-up. Pain was evaluated using the visual analog scale (VAS), and shoulder function was assessed using the Constant score and American Shoulder and Elbow Surgeons (ASES) score. Active ROM, including forward elevation (FE), abduction (ABD), and external rotation at the side (ER), was measured using a standardized goniometer. Internal rotation (IR) behind the back was assessed according to the highest vertebral level reached by the patient's thumb and converted to a numerical scale: 0, greater trochanter; 2, buttock; 4, lumbosacral junction; 6, L3; 8, T12; and 10, T7. Shoulder muscle strength was quantitatively assessed in kilograms-force (kgf) for FE, ABD, ER at the side, and IR at the side using a standardized strength-testing protocol. Strength measurements were obtained preoperatively and at the final follow-up using the same testing method to allow comparison of changes over time. Subscapularis specific physical examinations included the belly-press, lift-off, and bear-hug tests preoperatively and at the final follow-up.

## Radiographic Assessment

Preoperative shoulder radiographs, including anteroposterior, scapular Y, and axillary views, were assessed to evaluate degree of glenohumeral arthritis. The Hamada classification was used to grade the severity of glenohumeral arthritis and the acromiohumeral distance (AHD) was measured on standardized anteroposterior radiographs. Preoperative magnetic resonance imaging (MRI) was reviewed to assess the extent of rotator cuff tears and the degree of fatty infiltration of the rotator cuff muscles. Fatty infiltration was graded according to the Goutallier[15] classification. Postoperative structural integrity of the transferred LD and TM tendons was assessed using postoperative MRI at the final follow-up. [Fig. 2]

# Statistical Analysis

Continuous variables are presented as mean ± standard deviation, and categorical variables are presented as frequencies and percentages. Preoperative and final follow-up clinical, functional, muscle strength, and radiographic outcomes were compared using the paired t test for continuous variables and the Wilcoxon signed-rank test when the assumption of normality was not met. Categorical variables, including the results of the belly-press, lift-off, and bear-hug tests, were compared using the McNemar test. A 2-sided P value < .05 was considered statistically significant. All statistical analyses were performed using SPSS version 23.0 (IBM Corp., Armonk, NY, USA).

## Results

A total of 13 patients underwent independent anterior LD and TM tendon transfers during the study period. Two were excluded due to loss to follow-up or incomplete clinical data, leaving 11 patients for

the final analysis. The mean follow-up duration was 104 ± 2.7 months (range, 100–108 months), and the mean age at surgery was 66.4 ± 6.1 years (range, 57–75 years). Nine patients (81.8%) were male. Additional demographic and preoperative characteristics are presented in Table I.

At final follow-up, significant improvements were observed in pain and functional outcomes. VAS pain scores, Constant scores, and ASES scores all improved significantly compared with preoperative values (all P < .001). FE and IR also improved significantly, whereas changes in ABD and ER were not statistically significant (Table II). However, no significant improvement was observed in muscle strength, with FE, ABD, and ER strength remaining statistically unchanged. IR strength showed a numerical increase but did not reach statistical significance (P = .089) (Table III). The rate of positive subscapularis-specific physical examination findings decreased at final follow-up; however, changes in the belly-press, lift-off, and bear-hug tests were not statistically significant. (Table III). Radiographically, AHD decreased significantly at final follow-up (P = .002), whereas the change in Hamada grade was not statistically significant (P = .082). Four patients demonstrated a one-grade progression in the Hamada classification, and one showed radiographic progression of glenohumeral arthritis. Postoperative imaging revealed retears of the transferred tendons in 2 patients.

# Discussion

The principal finding of this study was that independent anterior transfer of the LD and TM was associated with sustained improvements in pain, shoulder function, FE, and IR at final follow-up. However, despite these improvements in clinical outcomes and ROM, muscle strength did not improve significantly, including IR strength. These findings suggest that independent transfer of the LD and TM can provide durable clinical improvement in patients with irreparable subscapularis tears, although recovery of measurable muscle strength may remain limited despite transfer of both tendons.

Anterior LD transfer has been introduced as a joint-preserving option for irreparable subscapularis tears, particularly in patients with minimal glenohumeral arthritis.[4, 6, 17, 18] However, isolated LD transfer may be insufficient to restore the multifaceted biomechanical role of the subscapularis, particularly its contribution to anterior stability and humeral head depression.[4, 6, 7] The addition of the TM to LD transfer has been proposed to augment the force-generating capacity of the reconstruction and improve shoulder stability. Biomechanical studies have suggested that combined LDTM transfer may provide a favorable line of pull for restoring IR and anterior shoulder stability.[7, 10, 11] Clinical studies have subsequently reported encouraging short- and mid-term outcomes following combined LDTM transfer.[8, 19] Baek et al.[8] reported a series of 31 patients with irreparable subscapularis tears who underwent combined LD and TM tendon transfer. At a mean follow-up of 74.7 months, significant improvements were observed in clinical scores, IR, active ROM, and IR strength. No significant progression of AHD or Hamada grade was observed, although retears at the musculotendinous junction occurred in 4 patients (12.9%), and 1 patient subsequently underwent conversion to reverse shoulder arthroplasty. More recently, Kany et al.[9] reported a fully arthroscopic series of 11 patients who underwent combined LDTM transfer for irreparable subscapularis tears. At a mean follow-up of 25.9 months, significant

improvements were observed in pain, functional scores, FE, ABD, IR, and IR strength. These findings support the potential of combined LDTM transfer to improve shoulder function and IR in patients with irreparable subscapularis deficiency.

The present technique differs from conventional combined LDTM transfer in that the LD and TM are harvested, positioned, tensioned, and fixed independently. The rationale for this approach is based on the distinct anatomic and functional characteristics of the 2 muscles. Wang et al.[13] reported that the TM has adequate tendon length, vascularity, and excursion for use as a tendon transfer, supporting its feasibility for reconstruction of the subscapularis. Lafosse et al.[20] further demonstrated that the line of pull of the TM differed from that of the native subscapularis by only approximately 9°, suggesting that the TM may provide a favorable force vector for restoration of the anterior line of pull. More recently, Lin et al.[12] described the distinct neurovascular relationships and insertional anatomy of the LD and TM, further emphasizing the anatomic differences between these 2 muscles that may allow them to be independently mobilized and transferred. Separating the 2 tendon transfers may allow their individual positions and tension to be adjusted according to the patient's anatomy and the desired direction of force, potentially providing greater technical flexibility during reconstruction. Although the current study demonstrated favorable clinical outcomes, these results do not establish that independent transfer provides superior clinical or functional outcomes compared with conventional combined LDTM transfer. In the absence of a comparative group, the potential biomechanical and technical advantages of independent transfer should therefore be considered theoretical rather than clinically established.

An important finding of this study was that muscle strength did not improve significantly despite significant improvements in pain, functional scores, FE, and IR. In particular, IR strength showed a numerical increase but did not reach statistical significance. This finding differs from the significant improvement in IR strength reported by Kany et al. [9] following combined LDTM transfer. Several factors may account for this difference. Tendon transfer does not restore the native subscapularis muscle-tendon unit but instead recruits muscles with different architecture, excursion, moment arms, and force-generating characteristics. Although Lafosse et al.[20] demonstrated that the TM has a favorable line of pull relative to the subscapularis, its functional characteristics remain different from those of the native subscapularis. In addition, chronic irreparable subscapularis tears are often associated with advanced fatty infiltration and muscle atrophy, which may limit the potential for recovery of measurable muscle strength. The functional benefit of tendon transfer may therefore result primarily from restoration of the anterior force couple and dynamic glenohumeral stability rather than restoration of native subscapularis strength. This concept is supported by the biomechanical studies,[7, 10] in which combined LDTM transfer reduced superior and anteroinferior humeral head translation and subacromial contact pressure compared with the irreparable tear condition. Thus, clinical improvement after independent LD and TM transfer may occur through restoration of shoulder mechanics even when measurable muscle strength does not substantially increase.

This study has several limitations. First, the retrospective design and small sample size of 11 patients limit the statistical power and generalizability of the findings. Second, there was no control or

comparative group, precluding direct comparison of independent LD and TM transfer with conventional combined LDTM transfer, isolated LD transfer, PM transfer, or other treatment options. Therefore, the present study cannot determine whether independent transfer provides superior clinical outcomes, strength recovery, or tendon healing compared with other transfer techniques. Third, 2 of the 13 initially identified patients were excluded because of loss to follow-up and incomplete clinical data, which may have introduced selection bias. Fourth, the small number of postoperative retears prevented meaningful analysis of the relationship between structural integrity and clinical or functional outcomes. Larger comparative studies with standardized postoperative imaging and quantitative strength assessment are needed to determine whether independent positioning and tensioning of the LD and TM provides a clinically meaningful advantage over conventional combined LDTM transfer.

## Conclusion

Independent anterior LD and TM tendon transfer improved pain, shoulder function, FE, and IR in patients with irreparable subscapularis tears. However, muscle strength, including IR strength, did not improve significantly despite these clinical improvements. Although independent transfer may offer technical flexibility by allowing separate positioning and tensioning of each tendon, its potential biomechanical and technical advantages remain theoretical and require further investigation.

## Declarations

# Author Contribution

C.H.B- Conceptualization, Methodology, Validation, Investigation, Supervision, Project AdministrationB.T.K- Conceptualization, Methodology, Validation, Formal analysis, Investigation, Writing – Original Draft, Writing – Review & Editing, VisualizationJ.G.K- Conceptualization, Methodology, Validation, Data CurationC.L- Conceptualization, Methodology, Validation, Data CurationS.J.K- Conceptualization, Methodology, Formal analysis, Visualization

# Acknowledgement

The authors would like to express gratitude to Seung Hak Choi help of collecting clinical data.

## References

1. Collin P, Matsumura N, Lädermann A, Denard PJ, Walch G (2014) Relationship between massive chronic rotator cuff tear pattern and loss of active shoulder range of motion. J Shoulder Elb Surg 23(8):1195–1202. 10.1016/j.jse.2013.11.019
2. Park HB, Gwark JY, Na JB (2022) Risk factors of chronic subscapularis tendon tear. Clin Shoulder Elb 25(4):257–264. 10.5397/cise.2021.00710

3. Luo Z, Lin J, Sun Y, Zhu K, Wang C, Chen J (2022) Outcome Comparison of Latissimus Dorsi Transfer and Pectoralis Major Transfer for Irreparable Subscapularis Tendon Tear: A Systematic Review. Am J Sports Med 50(7):2032–2041. 10.1177/03635465211018216
4. Elhassan BT, Wagner ER, Kany J (2020) Latissimus dorsi transfer for irreparable subscapularis tear. J Shoulder Elb Surg 29(10):2128–2134. 10.1016/j.jse.2020.02.019
5. Burnier M, Lafosse T (2020) Pectoralis Major and Anterior Latissimus Dorsi Transfer for Subscapularis Tears. Curr Rev Musculoskelet Med 13(6):725–733. 10.1007/s12178-020-09674-4
6. Mun SW, Kim JY, Yi SH, Baek CH (2018) Latissimus dorsi transfer for irreparable subscapularis tendon tears. J Shoulder Elb Surg 27(6):1057–1064. 10.1016/j.jse.2017.11.022
7. Baek GR, Kim JG, Kwak D, Nakla AP, Chung MS, McGarry MH, Lee TQ (2023) Biomechanical comparison of combined latissimus dorsi and teres major tendon transfer vs. latissimus dorsi tendon transfer in shoulders with irreparable anterosuperior rotator cuff tears. J Shoulder Elb Surg 32(4):703–712. 10.1016/j.jse.2022.11.007
8. Baek CH, Kim JG, Kim BT, Lim C, Kim SJ (2025) Mid-term outcomes of combined anterior latissimus dorsi and teres major tendon transfer for irreparable anterosuperior rotator cuff tears: a minimum five-year follow-up study. Bone Joint J 12107–b. 10.1302/0301-620x.107b12.Bjj-2025-0618.R1
9. Kim BT, Miranda LA, Baek CH, Kim JG, Diaz LLT, Baek GR, Kany J (2025) Clinical outcomes of full arthroscopic combined latissimus dorsi and teres major transfers for irreparable subscapularis tears. J Exp Orthop 12(2):e70226. 10.1002/jeo2.70226
10. Elhassan B, Christensen TJ, Wagner ER (2014) Feasibility of latissimus and teres major transfer to reconstruct irreparable subscapularis tendon tear: an anatomic study. J Shoulder Elb Surg 23(4):492–499. 10.1016/j.jse.2013.07.046
11. Hovsepian JM, Cartaya MA, Glaser J, Oehler N, Solovyov I, Abi Mansour C, Avila JC, Vogt S (2026) Surgical anatomy, biomechanics and clinical outcomes of latissimus dorsi transfer for irreparable rotator cuff tears: a review. J Orthop Surg Res 21(1). 10.1186/s13018-026-07200-9
12. Lin L, Liu Q, Zhao F, Wang D, Yan H (2025) Surgical anatomy of the pectoralis major, pectoralis minor, latissimus dorsi and teres major for tendon transfer in irreparable subscapularis tendon tears. J Exp Orthop 12(3):e70391. 10.1002/jeo2.70391
13. Wang AA, Strauch RJ, Flatow EL, Bigliani LU, Rosenwasser MP (1999) The teres major muscle: an anatomic study of its use as a tendon transfer. J Shoulder Elb Surg 8(4):334–338. 10.1016/s1058-2746(99)90156-8
14. Lafosse L, Jost B, Reiland Y, Audebert S, Toussaint B, Gobezie R (2007) Structural integrity and clinical outcomes after arthroscopic repair of isolated subscapularis tears. J Bone Joint Surg Am 89(6):1184–1193. 10.2106/jbjs.F.00007
15. Goutallier D, Postel JM, Bernageau J, Lavau L, Voisin MC (1994) Fatty muscle degeneration in cuff ruptures. Pre- and postoperative evaluation by CT scan. Clin Orthop Relat Res (304):78–83
16. Hamada K, Fukuda H, Mikasa M, Kobayashi Y (1990) Roentgenographic findings in massive rotator cuff tears. A long-term observation. Clin Orthop Relat Res (254):92–96

17. Kim BT, Kany J, Miranda LA, Kim JG, Lim C, Kim SJ, Baek CH (2025) Open versus arthroscopic anterior latissimus dorsi transfer for irreparable subscapularis tear: A multicentre cohort study. Knee Surg Sports Traumatol Arthrosc 33(11):3985–3993. 10.1002/ksa.70021
18. Kim BT, Miranda LA, Baek CH, Kim JG, Diaz LLT, Baek GR, Kany J (2025) Clinical Outcomes of Fully Arthroscopic Versus Arthroscopically Assisted Latissimus Dorsi Transfer for Irreparable Subscapularis Tear. Am J Sports Med 53(4):961–970. 10.1177/03635465251314057
19. Baek CH, Kim JG, Baek GR (2022) Outcomes of combined anterior latissimus dorsi and teres major tendon transfer for irreparable anterosuperior rotator cuff tears. J Shoulder Elb Surg 31(11):2298–2307. 10.1016/j.jse.2022.03.025
20. Lafosse T, Le Hanneur M, Lee J, Elhassan B (2018) Bipolar pedicled teres major transfer for irreparable subscapularis tendon tears: an anatomic feasibility study. J Shoulder Elb Surg 27(5):931–939. 10.1016/j.jse.2017.11.024

# Tables

**Table I Demographic and Clinical Characteristics of Study Subjects**

| Variables | Value (n=11) |
|---|---|
| Sex, Male/Female, n (%) | 9 (81.8) / 2 (18.2) |
| Age (year), mean ± SD (range) | 66.4 ± 6.1 (57-75) |
| Follow-up (month), mean ± SD (range) | 104 ± 2.7 (100-108) |
| Dominant arm involvement, n (%) | 10 (90.9) |
| BMI (kg/m2), mean ± SD | 23.1 ± 1.9 |
| HTN, n (%) | 5 (45.4) |
| DM, n (%) | 1 (9.1) |
| Smoking, n (%) | 1 (9.1) |
| Prior rotator cuff repair surgery, n (%) | 3 (27.3) |
| Preoperative SSC FI grade, n (%) | |
| Grade 3 | 2 (18.2) |
| Grade 4 | 9 (81.8) |
| Preoperative SSP FI grade, n (%) | |
| Grade 0 or 1 | 2 (18.2) |
| Grade 2 | 3 (27.3) |
| Grade 3 | 4 (36.3) |
| Grade 4 | 2 (18.2) |
| Preoperative ISP FI grade, n (%) | |
| Grade 0 or 1 | 5 (45.4) |
| Grade 2 | 6 (54.5 |
| Preoperative Tm FI grade, n (%) | |
| Grade 0 or 1 | 11 (100.0) |
| Grade 2 | 0 (0) |

SD, standard deviation; BMI, body mass index; HTN, hypertension; DM, diabetes mellitus; SSC, subscapularis; SSP, supraspinatus; ISP, infraspinatus; Tm, teres minor; FI, fatty infiltration

**Table II Clinical, Functional, and Radiologic Outcomes**

| Variables | Preoperative | Final follow-up | P value |
|---|---|---|---|
| VAS pain score | 5.3 ± 0.9 | 2.0 ± 1.2 | <.001* |
| Constant score | 43.7 ± 4.9 | 58.1 ± 7.9 | <.001* |
| ASES score | 49.3 ± 4.7 | 63.3 ± 7.8 | <.001* |
| Active ROM (degree) | | | |
| FE (°) | 99 ± 21 | 122 ± 24 | 0.011* |
| ABD (°) | 79 ± 19 | 94 ± 28 | 0.081 |
| ER at side (°) | 28 ± 9 | 29 ± 7 | 0.341 |
| IR at back † | 2.7 ± 1.5 | 3.8 ± 1.4 | 0.045* |
| AHD (mm) | 10.4 ± 3.5 | 7.8 ± 2.2 | 0.002* |
| Hamada grade | 1.1 ± 0.3 | 1.6 ± 1.0 | 0.082 |

VAS, visual analog scale; ASES, American Shoulder and Elbow Surgeons; ROM, range of motion; FE, forward elevation; ABD, abduction; ER, external rotation; IR, internal rotation; AHD, acromiohumeral distance. Unless otherwise noted, values are mean ± standard deviation;

* The significant P value is below .05.

† Internal rotation was measured as the level that could be reached by the thumb; 0, greater trochanter; 2, buttock; 4, lumbosacral junction; 6, L3; 8, T12; and 10, T7

**Table III Strength and Subscapularis Specific Physical Examination**

| Variables | Preoperative | Final follow-up | P value |
|---|---|---|---|
| Strength (kgf) | | | |
| FE | 14.1 ± 2.1 | 15.3 ± 2.5 | 0.122 |
| ABD | 13.5 ± 2.2 | 14.6 ± 3.0 | 0.196 |
| ER at side | 16.4 ± 1.9 | 16.9 ± 1.8 | 0.159 |
| IR at side | 12.8 ± 2.3 | 14.4 ± 3.1 | 0.089 |
| Specific Physical Examination | | | |
| Belly press | 11 (100.0) | 8 (72.7) | 0.082 |
| Lift off | 8 (72.7) | 6 (54.5) | 0.167 |
| Bear hug | 8 (72.7) | 7 (63.6) | 0.341 |

FE, forward elevation; ABD, abduction; ER, external rotation; IR, internal rotation; Unless otherwise noted, values are mean ± standard deviation

## Figures

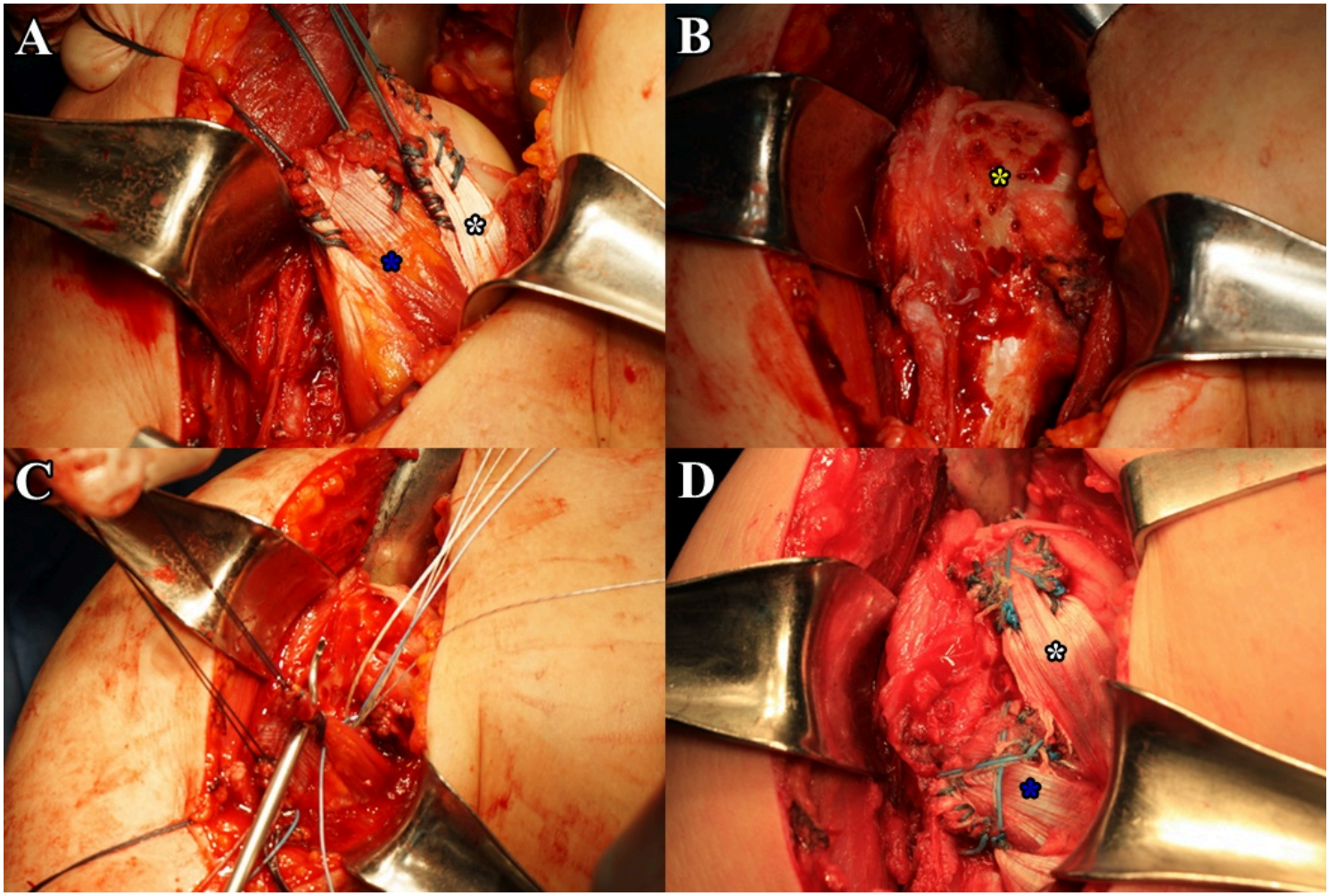


**Figure 1**

*Intraoperative images of the right shoulder.*

(a) Harvested and prepared latissimus dorsi tendon [white asterisk] and teres major tendon [blue asterisk].

(b) Prepared footprint at the lesser tuberosity of the humerus [yellow asterisk].

(c) Sutures passed through the teres major tendon.

(d) Final appearance of the independently transferred latissimus dorsi tendon [white asterisk] and teres major tendon [blue asterisk].

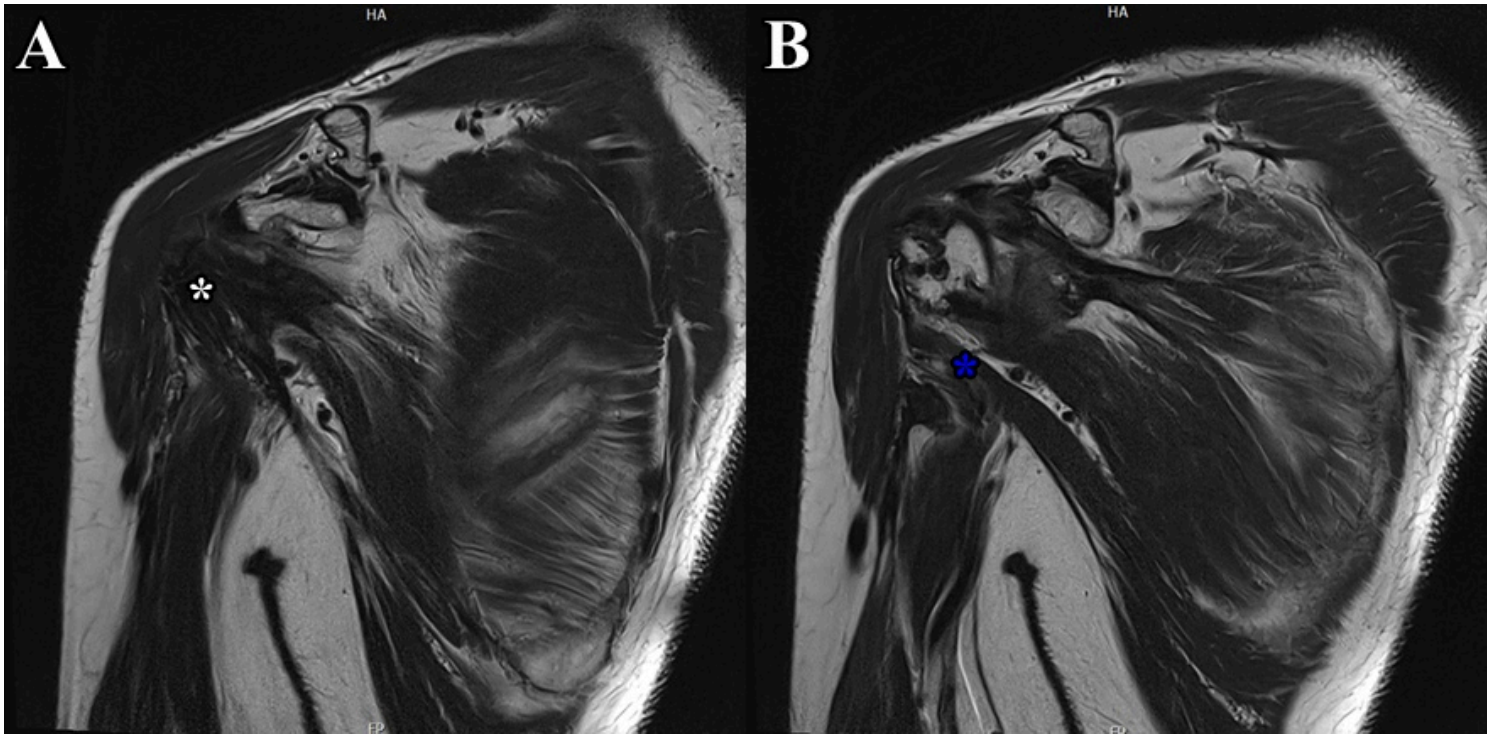


**Figure 2**

*Postoperative magnetic resonance images of the right shoulder.*

(a) Coronal view showing the transferred latissimus dorsi tendon [white asterisk].

(b) Coronal view showing the transferred teres major tendon [white asterisk].