Research Square

Preprints are preliminary reports that have not undergone peer review.
They should not be considered conclusive, used to inform clinical practice,
or referenced by the media as validated information.

Portal Shunt as a cause of false-normal IGF-1 level in a patient with acromegaly

Capucine GRAS GIRARD

capucinegir@gmail.com

Hôpital universitaire de Nantes

Clémentine FRONTEAU

Hôpital universitaire de Nantes

Philippe CHANSON

Université Paris-Saclay, Assistance Publique-Hôpitaux de Paris, Hôpital Bicêtre , Inserm

Peter WOLF

Université de médecine de Vienne

Anne-Lise RUELLAN

Hôpital universitaire de Nantes

Delphine DRUI

Hôpital universitaire de Nantes

Short Report

Keywords: Acromegaly, IGF-1, portocaval shunt, lanreotide, pharmacovigilance

Posted Date: November 25th, 2026

DOI: https://doi.org/10.21203/rs.3.rs-11754594/v1

License: This work is licensed under a Creative Commons Attribution 4.0 International License.
Read Full License

Additional Declarations: Competing interest reported. Philippe CHANSON has received unrestricted research and educational grants from Advanz, Ipsen, Pfizer, and Recordati Rare Diseases as Head of the Department of Endocrinology and Reproductive Diseases, Assistance Publique-Hôpitaux de Paris, Université Paris-Saclay. He has served as investigator (principal or coordinator) for clinical trials funded by Crinetics Pharmaceuticals, Inc., Debiopharm, Ipsen, and Pfizer; is a member of advisory boards for Crinetics Pharmaceuticals, Inc., Ipsen, Pfizer, and Recordati Rare Diseases; and has given lectures for Ipsen, Pfizer, and Recordati Rare Diseases. All the fees and honoraria are paid to his institution or research association.

Portal Shunt as a cause of false-normal IGF-1 level in a patient with acromegaly

Authors : Capucine GRAS GIRARD[1], Clémentine FRONTEAU[1], Philippe CHANSON[2], Peter WOLF[3], Anne-Lise RUELLAN[4], Delphine DRUI[5]

1 : Clinical Pharmacy Unit, Nantes University Hospital, Nantes, France

2 : Université Paris-Saclay, Inserm, Physiologie et Physiopathologie Endocriniennes, Assistance Publique-Hôpitaux de Paris, Hôpital Bicêtre, Service d'Endocrinologie et des Maladies de la Reproduction, Centre de Référence des Maladies Rares de l'Hypophyse, Le Kremlin-Bicêtre 94275, France ORCID: https://orcid.org/0000-0001-5096-5722

3 : Division of Endocrinology and Metabolism, Department of Internal Medicine III, Medical University of Vienna, 1090 Vienna, Austria

4 : Department of clinical pharmacology, regional center of pharmacovigilance, Nantes University Hospital, 44000 Nantes, France. ORCID: https://orcid.org/ 0000-0003-4036-1882

5 : Department of Endocrinology, Nantes University Hospital, 44000 Nantes, France. ORCID : https://orcid.org/0000-0002-4579-4129

Disclosures: Philippe CHANSON has received unrestricted research and educational grants from Advanz, Ipsen, Pfizer, and Recordati Rare Diseases as Head of the Department of Endocrinology and Reproductive Diseases, Assistance Publique-Hôpitaux de Paris, Université Paris-Saclay. He has served as investigator (principal or coordinator) for clinical trials funded by Crinetics Pharmaceuticals, Inc., Debiopharm, Ipsen, and Pfizer; is a member of advisory boards for Crinetics Pharmaceuticals, Inc., Ipsen, Pfizer, and Recordati Rare Diseases; and has given lectures for Ipsen, Pfizer, and Recordati Rare Diseases. All the fees and honoraria are paid to his institution or research association.

Corresponding author: Capucine GRAS GIRARD, capucinegir@gmail.com, ORCID : : https://orcid.org/0009-0007-2679-0361

Abstract ***(217 words)***

We report the case of a 59-year-old man with acromegaly secondary to a pituitary macroadenoma, who was apparently biochemically well controlled, as demonstrated by normal serum insulin-like growth factor-1 (IGF-1) under lanreotide long-acting release (120 mg every 28 days) since six years. Due to acromegaly-associated dolichomegacolon, he developed recurrent episodes of hepatic encephalopathy related to chronic hyperammonaemia. Investigations identified advanced hepatic fibrosis associated with a congenital portocaval shunt.

In November 2024, radiological embolization of the congenital portocaval shunt resulted in marked clinical and biochemical improvement, including normalization of plasma ammonia levels and resolution of hepatic encephalopathy.

From February 2025 onwards, serum IGF-1 concentrations increased, while growth hormone (GH) levels remain unchanged, despite unchanged acromegaly treatment, stable pituitary imaging, and absence of clinical worsening, unmasking resistance to first generation somatostatin receptor ligands (SRLs).

A pharmacovigilance assessment did not identify pharmacokinetic or pharmacodynamic interaction that could explain a loss of lanreotide efficacy. The temporal relationship and current pathophysiological understanding suggest that the restoration of portal blood flow may have increased hepatic exposure to portal insulin, thereby enhancing hepatic sensitivity to GH and increasing IGF-1 production.

This case highlights that IGF-1 concentrations reflect not only somatotroph activity but also hepatic responsiveness to GH stimulation. Portal haemodynamic changes may therefore represent an important confounding factor when interpreting biochemical control in acromegaly.

Keywords :

Acromegaly, IGF-1, portocaval shunt, lanreotide, pharmacovigilance

Introduction ***(168 words)***

Acromegaly is characterised by chronic growth hormone (GH) hypersecretion ,most commonly due to a somatotroph pituitary adenoma, leading to increased insulin-like growth factor-1 (IGF-1) concentrations, primarily of hepatic origin [1,2]. Treatment options include surgery, medical therapy and radiotherapy. Somatostatin receptor ligands (SRLs) are a mainstay of medical treatment when surgery is not performed or disease persists after it. Lanreotide acts mainly through somatostatin receptors subtype 2 (SSTR2)[3].

Serum IGF-1 concentration is the primary biomarker for diagnosis and follow-up. Its production depends not only on GH stimulation but also on hepatocyte responsiveness to GH, which is influenced by the hepatic metabolic environment, particularly portal insulin delivery [4–6]. Therefore, an increase in IGF-1 during treatment does not necessarily indicate disease progression or therapeutic escape. Other potential explanations include tumour progression, poor treatment adherence, pharmacological resistance and drug interactions.

To our knowledge, we report the first case of persistent IGF-11 elevation following embolization of a congenital portocaval shunt in a patient with acromegaly, without evidence of increased somatotroph tumour activity.

Case presentation: Patient (367 words)

The 59-year-old man had been followed since April 2018 for acromegaly secondary to a stable 14 mm pituitary macroadenoma.

At diagnosis (April 2018), serum IGF-1 concentrations were within the age-adjusted reference range using two assays: 180 ng/mL (reference range 70-265 ng/mL; 0.68 x ULN (upper limit of normal)) measured by radioimmunoassay (RIA) (Immunotech) and 197 ng/mL (reference range 75-222 ng/mL; 0.89 x ULN) measured by chemiluminescent immunoassay (CLIA) (Liaison XL, DiaSorin). In contrast, random GH concentration were elevated, at 7.3 ng/mL by RIA (Cisbio) and 7.1 ng/mL by CLIA (Liaison XL, DiaSorin). Biological variability and differences between IGF-1 assay methods can complicate interpretation; therefore, acromegaly should still be considered when clinical suspicion is high despite if IGF-1 concentrations within the reference range [7,8]. In this patient, GH failed to suppress during oral glucose tolerance testing, increasing paradoxically from 7.3 to 8.3 ng/mL, further supporting the diagnosis [9].

The diagnosis was prompted by hypertrophic cardiomyopathy and progressive characteristic features, including macroglossia, thickened lips and changes in dental occlusion. Other features included arthralgia, chronic constipation related to dolichomegacolon, and moderate sleep apnoea. As the patient declined surgery, treatment with lanreotide long-acting release (LAR) was initiated. Taken together, these clinical and biochemical findings supported the diagnosis of acromegaly [10].

From 2018, he also experienced recurrent episodes of dizziness due to chronic hyperammonaemia attributed to small intestinal bacterial overgrowth in the setting of dolichocomegacolon. Further investigations identified hepatic fibrosis associated with a congenital portocaval shunt, responsible for recurrent episodes of hepatic encephalopathy and portal hypertension since 2019.

In November 2024, radiological embolization of the shunt was performed because of worsening hepatic and gastrointestinal complications. This was followed by clinical and biochemical improvement, including normalisation of plasma ammonia and resolution of hepatic encephalopathy. Laxatives and rifaximin were discontinued in January 2025.

Before embolization the August 2024 endocrine assessment showed an IGF-1 concentration of 83 ng/mL (0.42 x ULN), consistent with satisfactory biochemical control. The therapeutic objective was to maintain IGF-1 within the lower half of the reference range (50-200 ng/mL).

From February 2025 onwards, IGF-1 concentrations increased persistently, reaching 200 to 300 ng/mL (1 to 1.5 x ULN), despite unchanged lanreotide treatment, good adherence, stable pituitary MRI findings and no clinical worsening.

Timeline *(85 words)*

Biochemical control has been maintained for more than six years under lanreotide, with IGF-1 concentrations ranging from 83 ng/mL (0.42 x ULN) to 162 ng/mL (0.82 x ULN). Following shunt embolization in November 2024, IGF-1 progressively increased, reaching 300 ng/mL (1.19 x ULN), despite unchanged treatment. In contrast, GH concentrations remained relatively stable through and serial pituitary MRI showed no tumor progression; the adenoma remained stable at 14 mm in its largest coronal diameter. ***Fig.1*** summarises IGF-1 and GH concentrations alongside major clinical events.

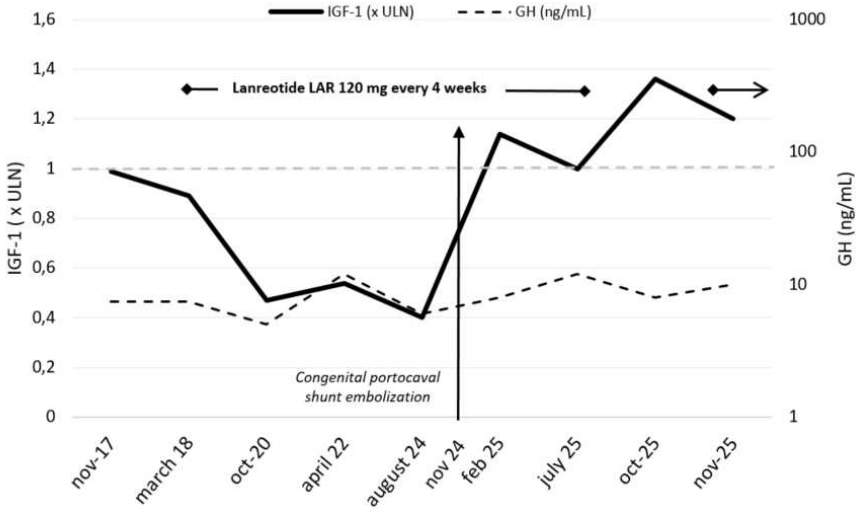

<u>Fig.1:</u> Longitudinal changes in serum IGF-1 and GH concentrations before and after embolization of the congenital portocaval shunt

IGF-1 concentrations are expressed as multiples of the age- and sex-specific upper limit of normal (ULN) and were measured using a chemiluminescent immunoassay (CLIA; Liaison XL; DiaSorin). GH concentrations are expressed in ng/mL and were measured by radioimmunoassay (RIA; Cisbio). The dashed grey line indicates the IGF-1 ULN (1 x ULN). The black horizontal arrow indicates treatment with long acting release (LAR) lanreotide (120 mg every 4 weeks); the interruption indicates temporary lanreotide withdrawal. The vertical arrow indicates the embolization of the congenital portocaval shunt in November 2024. The figure was created using Microsoft Excel and Microsoft Word (Microsoft Office).

Diagnostic assessment (*61 words)*

To investigate this apparent biochemical escape, the Regional Pharmacovigilance Center reviewed all medications prescribed during the previous seven years. No pharmacokinetic or pharmacodynamic interaction likely to explain reduced lanreotide efficacy was identified, particularly among treatments introduced after November 2024.

The temporal relationship between shunt embolization and IGF-1 elevation suggests a potential association between restoration of portal circulation and altered IGF-1 regulation.

Therapeutic intervention *(51 words)*

To explore whether the increase in IGF-1 reflected increased GH secretion or altered hepatic responsiveness to GH, GH and IGF-1 concentrations were assessed together. Increased GH secretion would be expected to raise both concentrations, whereas stable GH alongside increased IGF-1 would support a peripheral mechanism involving enhanced hepatic responsiveness to GH.

Follow-up and outcomes (*110 words)*

Three months after temporary withdrawal of lanreotide (October 2025), IGF-1 increased to 284 ng/mL (1.36 × ULN). Four months after lanreotide LAR (120 mg every 4 weeks) was restarted, IGF-1 remained elevated at 256 ng/mL (1.22 × ULN), while random GH was 8.0 ng/mL confirming the resistance to lanreotide. Lanreotide was replaced by long-acting pasireotide (60 mg every 4 weeks) in March 2026, as the patient continued to decline surgical. Five months later, IGF-1 had decreased to 119 ng/mL (0.56 x ULN) and GH improving to 2.7 ng/mL. However, new-onset diabetes prompted consideration of reducing pasireotide to 40 mg every four weeks to improve glycaemic tolerance while maintaining biochemical control.

Discussion (*241 words)*

The interaction between GH, IGF-1 and insulin is complex. IGF-1 production depends not only on GH stimulation but also on portal insulin delivery, which modulates hepatocyte responsiveness to GH [6]. Before embolization, the congenital portocaval shunt may have reduced hepatic exposure to portal insulin, limiting responsiveness to GH and contributing to relatively low IGF-1 despite persistent somatotroph activity. Thus, IGF-1 concentrations before embolization may have underestimated the biological activity of acromegaly.

After restoration of portal circulation, increased hepatic insulin exposure may have enhanced GH responsiveness and IGF-1 production. This hypothesis is supported by stable GH concentrations, the absence of tumour

progression on MRI, and the lack of clinical worsening. However, portal insulin exposure and hepatic GH signalling were not directly assessed, so causality cannot be established.

This case suggests that changes in portal haemodynamic may influence the interpretation of IGF-1 levels in acromegaly. Discrepancies between disease activity and IGF-1 concentrations have also been described in other conditions affecting hepatic or metabolic function, including uncontrolled diabetes mellitus [11] and advanced liver or renal failure [8,12]. In patients with portosystemic abnormalities, IGF-1 should therefore be interpreted in the broader physiological context before concluding that therapeutic escape or disease progression has occurred. To our knowledge, this is the first reported case of a change in GH/IGF-1 profile following embolization of a congenital portocaval shunt in a patient with acromegaly. It highlights the value of a multidisciplinary assessment when clinical and biochemical markers are discordant.

Consent (*10 words)*

Written informed consent for publication was obtained from the patient.

Funding statement *(7 words)*

No funding was required for this article

References :

1. Fleseriu M, Langlois F, Lim DST, Varlamov EV, Melmed S. Acromegaly: pathogenesis, diagnosis, and management. Lancet Diabetes Endocrinol. nov 2022;10(11):804-26. doi:10.1016/S2213-8587(22)00244-3 PubMed PMID: 36209758.

2. Sjögren K, Liu JL, Blad K, Skrtic S, Vidal O, Wallenius V, et al. Liver-derived insulin-like growth factor I (IGF-1) is the principal source of IGF-1 in blood but is not required for postnatal body growth in mice. Proc Natl Acad Sci U S A. 8 juin 1999;96(12):7088-92. doi:10.1073/pnas.96.12.7088 PubMed PMID: 10359843; PubMed Central PMCID: PMC22065.

3. Melmed S, di Filippo L, Fleseriu M, Mercado M, Karavitaki N, Gurnell M, et al. Consensus on acromegaly therapeutic outcomes: an update. Nat Rev Endocrinol. nov 2025;21(11):718-37. doi:10.1038/s41574-025-01148-2 PubMed PMID: 40804505.

4. Yuen KCJ, Hjortebjerg R, Ganeshalingam AA, Clemmons DR, Frystyk J. Growth hormone/insulin-like growth factor I axis in health and disease states: an update on the role of intra-portal insulin. Front Endocrinol. 21 nov 2024;15:1456195. doi:10.3389/fendo.2024.1456195 PubMed PMID: 39665021; PubMed Central PMCID: PMC11632222.

5. van Albada ME, Shah P, Derks TGJ, Fuchs S, Jans JJM, McLin V, et al. Abnormal glucose homeostasis and fasting intolerance in patients with congenital porto-systemic shunts. Front Endocrinol. 2023;14:1190473. doi:10.3389/fendo.2023.1190473 PubMed PMID: 37664849; PubMed Central PMCID: PMC10471981.

6. Nijenhuis-Noort EC, Berk KA, Neggers SJCMM, Lely AJ van der. The Fascinating Interplay between Growth Hormone, Insulin-Like Growth Factor-1, and Insulin. Endocrinol Metab. févr 2024;39(1):83-9. doi:10.3803/EnM.2024.101 PubMed PMID: 38192102; PubMed Central PMCID: PMC10901670.

7. Schilbach K, Strasburger CJ, Bidlingmaier M. Biochemical investigations in diagnosis and follow up of acromegaly. Pituitary. févr 2017;20(1):33-45. doi:10.1007/s11102-017-0792-z PubMed PMID: 28168377.

8. Clemmons DR, Bidlingmaier M. Interpreting growth hormone and IGF-1 results using modern assays and reference ranges for the monitoring of treatment effectiveness in acromegaly. Front Endocrinol.

2023;14:1266339. doi:10.3389/fendo.2023.1266339 PubMed PMID: 38027199; PubMed Central PMCID: PMC10656675.

9. Schilbach K, Gar C, Lechner A, Nicolay SS, Schwerdt L, Haenelt M, et al. Determinants of the growth hormone nadir during oral glucose tolerance test in adults. Eur J Endocrinol. juill 2019;181(1):55-67. doi:10.1530/EJE-19-0139 PubMed PMID: 31096183.

10. Yogi-Morren D, Chanson P. Acromegaly diagnosis. J Clin Endocrinol Metab. 29 avr 2026;111(Suppl 1):S38-50. doi:10.1210/clinem/dgag189 PubMed PMID: 42056759; PubMed Central PMCID: PMC13235963.

11. Lim DJ, Kwon HS, Cho JH, Kim SH, Choi YH, Yoon KH, et al. Acromegaly associated with type 2 diabetes showing normal IGF-1 levels under poorly controlled glycemia. Endocr J. août 2007;54(4):537-41. doi:10.1507/endocrj.k06-083 PubMed PMID: 17575366.

12. Clemmons DR, Bidlingmaier M. IGF-1 assay methods and biologic variability: evaluation of acromegaly treatment response. Eur J Endocrinol. 2 juill 2024;191(1):R1-8. doi:10.1093/ejendo/lvae065 PubMed PMID: 38916798.

***Total** : 1 093 words + 217 words for abstract*