Research Square

Preprints are preliminary reports that have not undergone peer review.
They should not be considered conclusive, used to inform clinical practice,
or referenced by the media as validated information.

# Bidirectional herniation in blunt traumatic pericardio-diaphragmatic rupture: an exceptional case of downward cardiac prolapse

**Ghazi Laamiri**

lamirighazi@gmail.com

University of Tunis El Manar

**Fatma Inched Jmal**

University of Tunis El Manar

**Houda Gazzah**

University of Tunis El Manar

**Hazem Alouani**

University of Tunis El Manar

**Sami Mahfoudhi**

University of Tunis El Manar

**Jasser Rchidi**

University of Tunis El Manar

---

**Case Report**

**Keywords:** Pericardio-diaphragmatic rupture, Cardiac herniation, Blunt trauma, Diaphragmatic hernia, Damage control surgery

**Posted Date:** November 26th, 2026

**DOI:** https://doi.org/10.21203/rs.3.rs-11749403/v1

**License:** This work is licensed under a Creative Commons Attribution 4.0 International License.
Read Full License

**Additional Declarations:** No competing interests reported.

## Abstract

# Background

Pericardio-diaphragmatic rupture is a remarkably rare and life-threatening complication of blunt trauma. The pressure gradient between the anatomical cavities classically dictates an upward herniation where abdominal viscera migrate into the pleural space or pericardial sac. Downward herniation of the heart into the abdominal cavity defies standard biomechanics and remains an exceptionally rare clinical entity.

# Case presentation:

A 32-year-old female with no prior medical history was ejected from a horse-drawn cart after a high-velocity collision with a car. She was transported to the emergency department presenting with profound respiratory and hemodynamic distress requiring immediate intubation and catecholamine support. Auscultation revealed absent breath sounds and the presence of bowel sounds in the left hemithorax. A whole-body computed tomography scan showed a 100 mm left diaphragmatic defect with intrathoracic migration of the stomach, left colic flexure and left hepatic lobe. An associated grade II splenic laceration with hemoperitoneum was also noted. The patient underwent an emergent midline laparotomy. Exploration confirmed the upward visceral herniation. Following the reduction of the abdominal organs a concomitant pericardio-diaphragmatic tear was identified revealing a highly unusual downward herniation of the heart and left lower pulmonary lobe into the abdominal cavity. The thoracic structures were repositioned and the structural defect was primarily repaired with interrupted non-absorbable sutures. The postoperative course was completely uneventful.

# Conclusions

This observation highlights a unique bidirectional herniation mechanism following blunt trauma. It underscores the danger of blind chest tube placement based solely on clinical signs and confirms that an acute midline laparotomy provides an optimal and safe approach for simultaneous visceral reduction and pericardial repair.

## Background

Diaphragmatic rupture following blunt trauma is a well-documented but uncommon entity occurring in a very small fraction of patients subjected to severe thoracoabdominal impact [1]. The concurrent rupture of the pericardium is even more exceptional and represents a marker of extreme kinetic energy transfer [2, 3]. In the scientific literature this combined injury is classically described according to two distinct structural patterns [4]. The first pattern involves individual tears of the pleural pericardium and the diaphragm leading to the herniation of the heart and abdominal organs into the pleural cavity. The

second pattern involves a direct tear of the diaphragmatic pericardium where abdominal organs herniate directly into the pericardial sac.

In both of these classical scenarios the physiological pressure gradient between the positive intra-abdominal compartment and the negative intrathoracic compartment dictates an upward migration of the local structures. Consequently downward displacement of the heart into the abdominal cavity is almost unheard of and represents a unique pathological kinetic that completely alters the expected clinical presentation. High-energy polytrauma demands decisive parallel actions within a narrow window to prevent mortality. We report an unprecedented case of blunt trauma resulting in a bidirectional displacement featuring an upward visceral herniation combined with a paradoxical downward cardiac and pulmonary herniation.

## Case presentation

A 32-year-old female patient with no notable medical history was brought to the emergency department following a high-velocity road traffic accident. She had been riding in a horse-drawn cart when she was struck by a fast-moving vehicle resulting in her violent ejection and severe blunt abdominal trauma. The patient was managed on site by the emergency medical services. Upon their arrival she exhibited severe respiratory and hemodynamic distress necessitating immediate endotracheal intubation and the initiation of catecholamine support to maintain perfusion.

On admission to the trauma bay physical examination revealed an absence of normal vesicular breath sounds on the left side coupled with the clear presence of bowel sounds within the left hemithorax. Initial laboratory investigations demonstrated a hemoglobin level of 9.0 g/dL, a white blood cell count of $13.0 \times 10^9$/L and a normal prothrombin time of 100%.

A comprehensive whole-body computed tomography scan was performed once the patient was transiently stabilized. The pleuro-parenchymal and parietal study revealed a massive 100 mm left diaphragmatic defect. Through this structural breach there was significant intrathoracic migration of the stomach, left colic flexure and left hepatic lobe (Fig. 1). The left lower pulmonary lobe exhibited a passive non-aerated partial collapse secondary to the compression by the herniated abdominal viscera. A small left hemothorax was also identified. Additionally postero-basal and right upper lobe dorsal segment consolidations populated by an air bronchogram were noted which was consistent with an early aspiration pneumonia. The abdomino-pelvic study revealed multiple parenchymal splenic lacerations and hematomas that spared the splenic hilum and showed no active contrast extravasation. The most voluminous laceration measured 15 mm in depth classifying it as an American Association for the Surgery of Trauma grade II injury. A mild to moderate perihepatic and pelvic hemoperitoneum was also evident.

Given the severity of the traumatic injuries and the persistent hemodynamic fragility the patient was immediately transferred to the operating room. An emergent midline laparotomy was performed

revealing a mild hemoperitoneum.Deep exploration of the left upper quadrant confirmed a massive defect of the left hemidiaphragm with upward herniation of the left colon, greater omentum, spleen and left hepatic lobe into the left thoracic cavity (Fig. 2).

The surgical team proceeded to carefully reduce the abdominal contents back into the peritoneal cavity. Following this initial reduction a deep and complex pericardio-diaphragmatic tear was exposed. Strikingly the surgical exploration at this stage revealed that the heart alongside the left lower pulmonary lobe had herniated downward through this deep central tear straight into the abdominal cavity (Fig. 3). The displaced heart and lung were meticulously manipulated and repositioned into the mediastinum and pleural space. Once anatomical alignment was restored the large pericardio-diaphragmatic defect was closed primarily. This was achieved using interrupted non-absorbable sutures placed meticulously along the axis of the tear to ensure a robust repair without tension (Fig. 4).

The patient tolerated the surgical procedure well. Her catecholamine requirements were rapidly weaned postoperatively as the mechanical compression on the heart and great vessels was relieved. The postoperative course was remarkably simple and the patient was discharged without any enduring cardiopulmonary or abdominal complications.

## Discussion

Blunt traumatic pericardio-diaphragmatic rupture is a catastrophic and challenging condition [5]. Our observation presents a highly atypical clinical variant characterized by a bidirectional herniation where abdominal organs migrated upward into the chest while the heart paradoxically descended into the abdominal cavity.

Regarding the rarity and pathophysiology of this injury cardiac herniation into the abdominal cavity defies the standard mechanical rules of thoracoabdominal trauma. High-energy blunt chest and abdominal trauma typically causes a sudden exponential rise in intra-abdominal pressure against a closed glottis. This creates an overwhelming shearing force that tears the central tendon of the diaphragm and the adherent pericardium. Kamiyoshihara et al. clearly defined the two classic patterns of this combined injury which both invariably result in upward herniation due to the natural pressure gradient [4]. The downward herniation of the heart observed in our patient is an extreme mechanical anomaly. It is probable that the sheer violence of the ejection and deceleration created a transient but massive negative intra-abdominal pressure during the recoil phase. Alternatively the immense size of the diaphragmatic defect may have neutralized the anatomical pressure gradient entirely allowing the raw inertia of the heart to tear the pericardial sac and drag the adjacent pulmonary lobe downward into the abdomen.

This complex anatomical derangement also highlights a significant and potentially lethal clinical trap. The initial presentation of these patients is almost exclusively dominated by acute respiratory failure and profound hemodynamic shock. The clinical finding of decreased breath sounds with bowel sounds in the chest can easily mimic a massive tension pneumothorax or hemothorax particularly in a chaotic

prehospital or emergency room environment [6]. This scenario underscores the critical danger of placing a chest tube blindly based solely on auscultatory signs. A rapid tube thoracostomy in this setting could cause catastrophic iatrogenic injury by directly perforating the herniated colon or puncturing the right ventricle of the downward-displaced heart. The reliance on advanced imaging prior to invasive procedures is paramount when the patient's physiology permits [7].

Radiological diagnosis remains the gold standard for defining the extent of polytrauma but it is heavily fraught with limitations regarding the pericardium. While modern computed tomography imaging excellently delineated the visceral herniation and the grade II splenic injury in our patient there was no clear evidence of a pericardial laceration prior to surgical exploration. As noted in the broader literature the radiological signs of pericardial rupture are notoriously non-specific and are frequently obscured by the complex dense shadows of herniated abdominal viscera, pulmonary contusions and hemothorax [8]. Consequently the definitive diagnosis of a pericardial tear with cardiac herniation is very frequently an intraoperative discovery forcing the surgical team to adapt their strategy in real time.

The choice of surgical approach depends heavily on the presence of concomitant abdominal injuries, the stability of the patient and the timing of the presentation. In the acute setting of severe polytrauma a midline laparotomy is unequivocally the preferred access route [5, 9]. It allows for the rapid evaluation of hemorrhagic solid organ injuries such as our patient's splenic laceration, enables the efficient reduction of herniated viscera and provides optimal exposure of the entire diaphragmatic dome. In our case the transabdominal approach provided excellent visualization for the simultaneous reduction of both the upward visceral herniation and the downward cardiac herniation. It also facilitated a secure primary repair using heavy non-absorbable sutures which is the standard of care to prevent recurrence and resist the constant kinetic stress of respiration. While a thoracic approach is sometimes advocated for delayed presentations to safely dissect dense adhesions between the bowel and the lung the laparotomy approach proved entirely adequate and highly safe for this acute setting [9]. Minimally invasive surgical techniques remain a valid option for stable patients with delayed isolated hernias but are strictly contraindicated in the face of decompensated hemorrhagic shock and massive acute anatomical disruption [10].

## Conclusions

Traumatic pericardio-diaphragmatic rupture with downward cardiac herniation is a uniquely rare consequence of high-velocity blunt trauma. This case demonstrates that pathophysiological displacement can occasionally defy classic pressure gradients resulting in a highly dangerous bidirectional herniation. A high index of clinical suspicion coupled with routine whole-body computed tomography imaging is essential to avoid fatal pitfalls such as the blind insertion of a chest tube into displaced vital organs. Furthermore an emergent midline laparotomy remains the most effective and versatile surgical approach in the acute phase providing comprehensive access for hemorrhage control,visceral reduction and primary structural repair.

## Declarations

# Ethics approval and consent to participate

Ethical review and approval were not required for the study on human participants in accordance with the local legislation and institutional requirements.

**Consent for publication**

Written informed consent was obtained from the patient for publication of this case report and accompanying images.

# Competing interests

The authors declare that they have no competing interests.

# Funding

This research did not receive any specific grant from funding agencies in the public, commercial, or not-for-profit sectors.

# Author Contribution

Manuscript writing: Dr Ghazi Laamiri- Study concepts: Dr Ghazi Laamiri- Helped in data interpretation and manuscript evaluation: Dr Fatma Inched Jmal, Dr Houda Gazzah and Dr Hazem Alouani- Data acquisition: Dr Jasser Rchidi- Critical revision: Dr Sami Mahfoudhi.

# Acknowledgements

Not applicable.

# Availability of data and materials

Data sharing is not applicable to this article as no datasets were generated or analysed during the current study.

## References

1. Mihos P, Potaris K, Gakidis J, Paraskevopoulos J, Varvatsoulis P, Gougoutas B, et al. Traumatic rupture of the diaphragm: experience with 65 patients. Injury. 2003;34:169–72. https://doi.org/10.1016/s0020-1383(02)00369-8.
2. Fulda G, Brathwaite CE, Rodriguez A, Turney SZ, Dunham CM, Cowley RA. Blunt traumatic rupture of the heart and pericardium: a ten-year experience (1979–1989). J Trauma. 1991;31:167–73. https://doi.org/10.1097/00005373-199102000-00003.
3. Sharma OP. Pericardio-diaphragmatic rupture: five new cases and literature review. J Emerg Med. 1999;17:963–8. https://doi.org/10.1016/s0736-4679(99)00124-9.
4. Kamiyoshihara M, Nagashima T, Ibe T, Takeyoshi I. Rupture of the diaphragm and pericardium with cardiac herniation after blunt chest trauma. Gen Thorac Cardiovasc Surg. 2010;58:291–4. https://doi.org/10.1007/s11748-009-0520-3.
5. Ye P, Zhou X, Wang S, Yang C, Yang G, Yu A. Staged management of severe polytrauma with pericardial and diaphragmatic rupture and open pelvic ring injury: a case report with literature review. Int J Surg Case Rep. 2026;138:412–8. https://doi.org/10.1097/rc9.0000000000000109.
6. Arslan E, Işik AF, Şanli M, Uluşan A, Elbeyli L. A rare complication of blunt trauma; diaphragm-pericardium rupture and cardiac herniation in a child case. Ulus Travma Acil Cerrahi Derg. 2013;19:363–5. https://doi.org/10.5505/tjtes.2013.89138.
7. Reade MC. Perspective: the top 11 priorities to improve trauma outcomes, from system to patient level. Crit Care. 2022;26:395. https://doi.org/10.1186/s13054-022-04243-2.
8. Witkowski Z, Lasek J, Wujtewicz M, Stasiak M, Marks W, Kawecka A. Pericardiodiaphragmatic rupture and cardiac herniation after multiple blunt trauma: diagnostic and therapeutic difficulties. J Thorac Cardiovasc Surg. 2005;130:1–2. https://doi.org/10.1016/j.jtcvs.2005.07.054.
9. Öz K, Onat S, Başbozkurt AK. Transpericardial diaphragmatic hernia. Kardiochir Torakochirurgia Pol. 2015;12:273–5. https://doi.org/10.1002/ams2.895.
10. Risinger WB, Smith JW. Damage control surgery in emergency general surgery: What you need to know. J Trauma Acute Care Surg. 2023;95:770–9. https://doi.org/10.1097/ta.0000000000004112.

# Figures

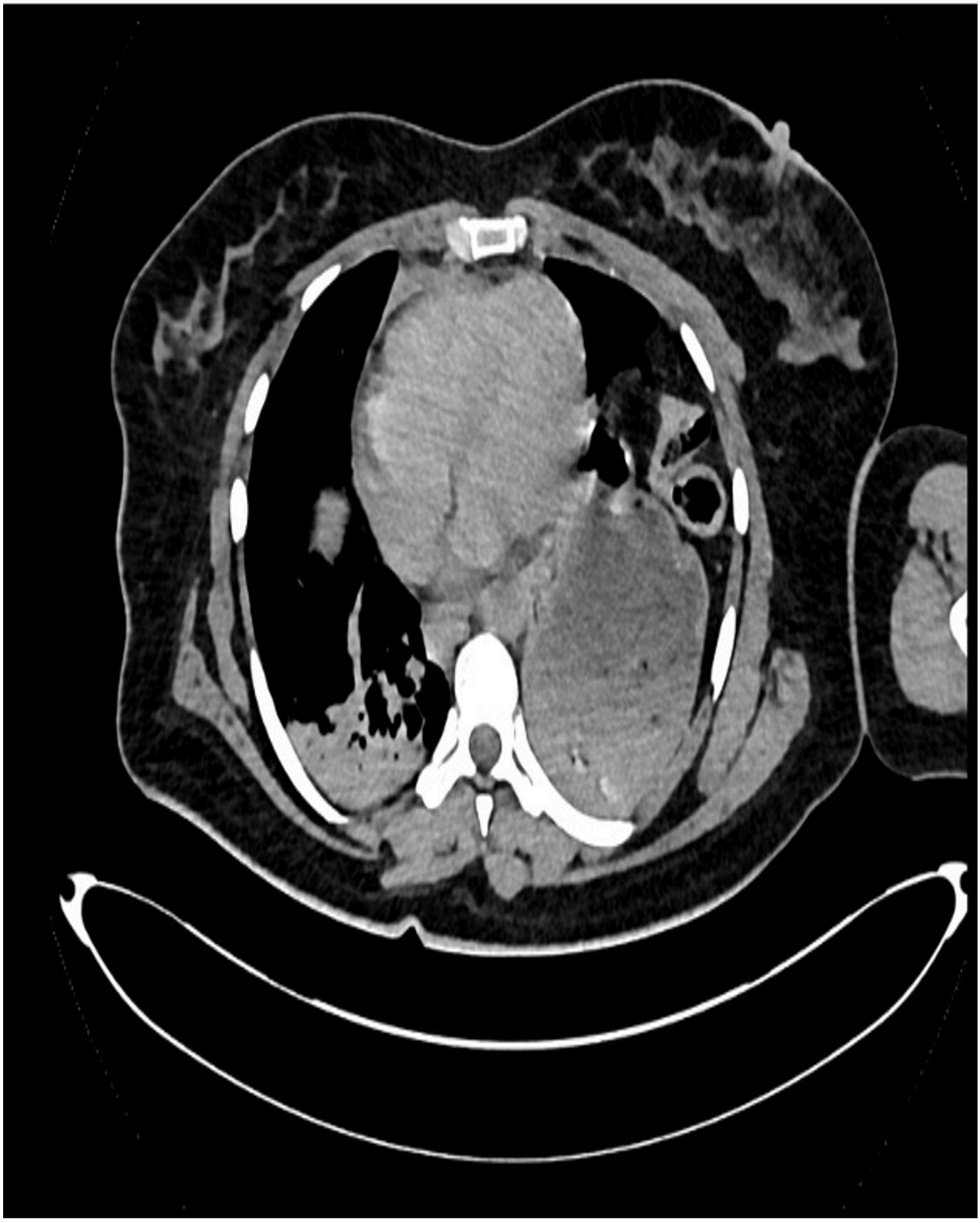

**Figure 1**

Axial computed tomography scan showing a large left diaphragmatic defect.

**Legend:** The pleuro-parenchymal study demonstrates the intrathoracic migration of the stomach, left colic flexure, and left hepatic lobe.



**Figure 2**

Intraoperative photograph showing the upward visceral herniation.

**Legend:** The view during the initial midline laparotomy illustrates the migration of the abdominal contents into the left thoracic cavity through the diaphragmatic rupture.

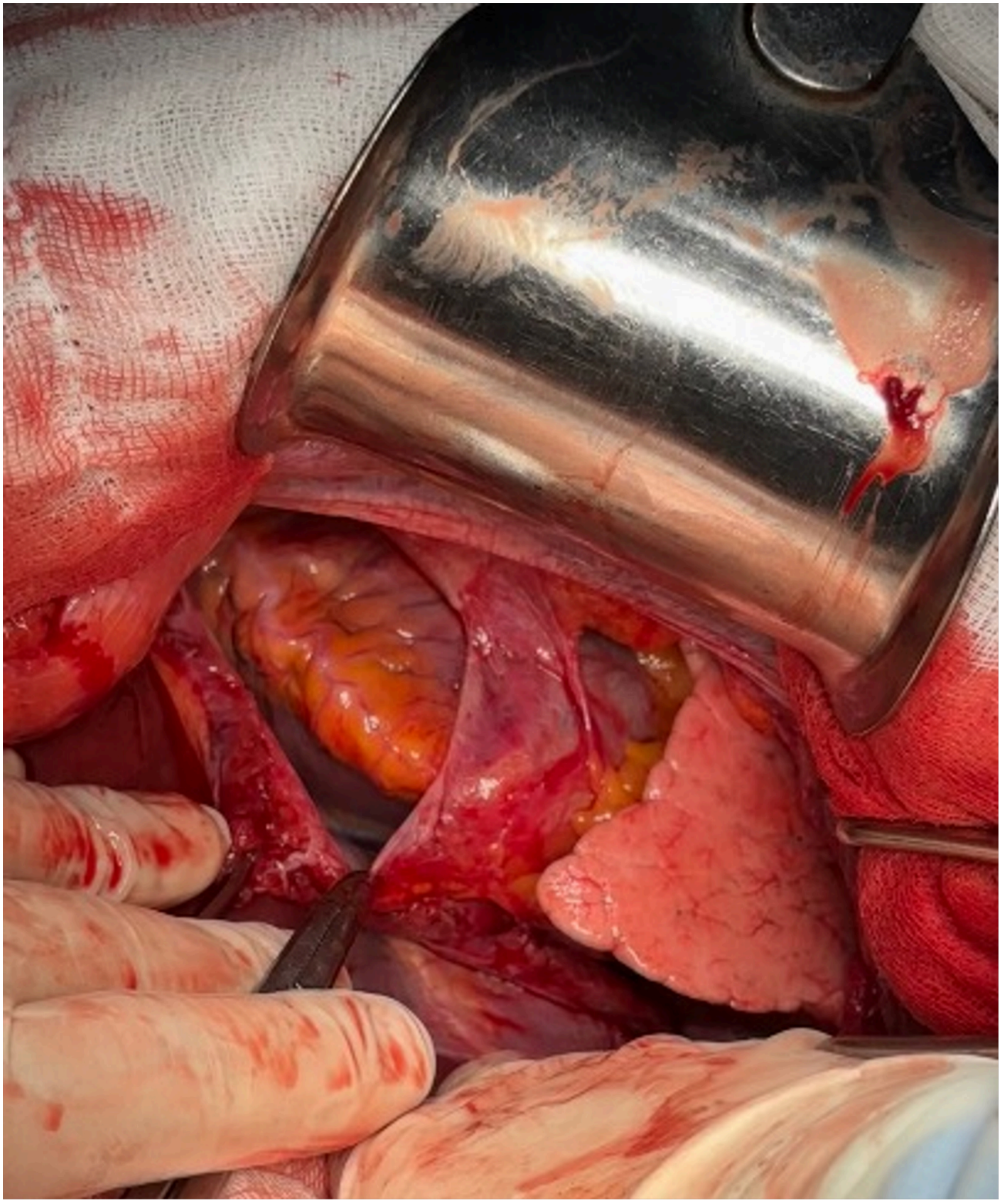

**Figure 3**

Downward herniation of the heart and left lower pulmonary lobe.

**Legend:** Intraoperative photograph following the reduction of the abdominal viscera revealing the atypical migration into the abdominal cavity through the pericardio-diaphragmatic tear.

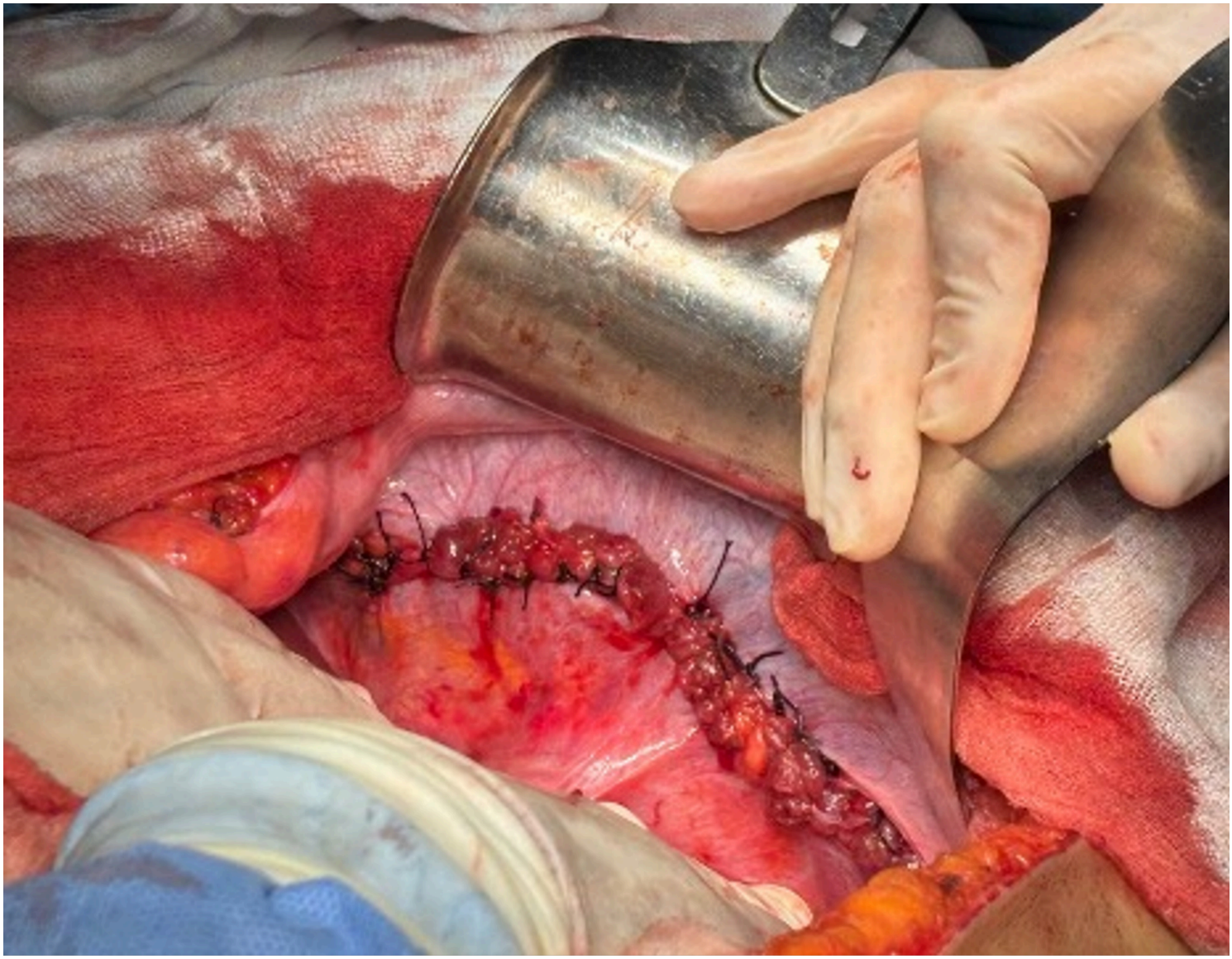

**Figure 4**

Primary repair of the pericardio-diaphragmatic defect.

**Legend:** Intraoperative photograph demonstrating the final anatomical restoration using interrupted non-absorbable sutures placed along the axis of the tear.