Research Square

Preprints are preliminary reports that have not undergone peer review.
They should not be considered conclusive, used to inform clinical practice,
or referenced by the media as validated information.

Anatomical comparison of the extended superficial circumflex iliac artery perforator and radial forearm free flaps: a cadaveric study

Carla Fouquoire
Beaujon Hospital
Jules Grégory
Beaujon Hospital
Osvaldo Berlina
Beaujon Hospital
Christian Vacher
Beaujon Hospital
Sophie Deneuve
Rouen University Hospital
Lara Nokovitch
lara.nokovitch@aphp.fr

Beaujon Hospital

Research Article

Keywords: Extended SCIP flap, superficial circumflex iliac artery, radial forearm free flap, vascular anatomy, oral cavity reconstruction, Cadaveric study

Posted Date: November 24th, 2026

DOI: https://doi.org/10.21203/rs.3.rs-11748634/v1

License: This work is licensed under a Creative Commons Attribution 4.0 International License.
Read Full License

Additional Declarations: No competing interests reported.

Abstract

Purpose

The radial forearm free flap (RFFF) is widely used for oral cavity reconstruction but is associated with donor-site morbidity. The extended superficial circumflex iliac artery perforator (eSCIP) flap offers a concealed donor site and a potentially longer pedicle than the conventional SCIP. This anatomical study aimed to compare the morphometric characteristics of the eSCIP and RFFF and assess eSCIP vascular variations to evaluate its suitability for oral cavity reconstruction.

Methods

Dissections were performed on 17 fresh anatomical subjects. Twenty-four RFFF and 20 eSCIP were measured, and 16 sides from 9 subjects allowed a paired comparison. Pedicle length, skin paddle thickness, arterial and venous diameters, and vascular variations were recorded.

Results

The median pedicle length of the eSCIP was 13.0 cm [10.8; 14.0], versus 15.0 cm [13.5; 15.2] for the RFFF (paired difference − 3.25 [− 5.00; −1.50] cm, p = 0.002) and exceeded 10 cm in 16/20 sides (80.0% [56.3–94.3]). The eSCIP skin paddle was thicker (1.50 [0.00; 2.50] mm, p = 0.014), and its pedicle of smaller caliber (− 2.50 [− 3.00; −1.50] mm, p < 0.001). Some vascular variations were recorded, mainly of the venous drainage.

Conclusion

The eSCIP provides a longer vascular pedicle than the conventional SCIP, although it remains significantly shorter and of smaller arterial caliber than the RFFF. Despite variations in arterial origin and venous drainage, the superficial and deep branches of the SCIA exhibited a relatively consistent anatomical pattern, supporting the anatomical feasibility of the eSCIP as a potential alternative for oral cavity reconstruction.

INTRODUCTION

Tissue defects of the oral cavity most commonly result from oncologic resections. Their reconstruction is challenging, as it must restore as much as possible tongue mobility, swallowing and speech [3, 11, 12]. For medium to large oral cavity defects, free flaps are a workhorse flap in the contemporary reconstructive strategy [19, 26].

The radial forearm free flap (RFFF) remains a reference option for the reconstruction of medium-sized oral cavity defects [20, 21]. Harvested on the volar side of the forearm, it is vascularized by the radial artery and has a double venous drainage: a deep system (the venae comitantes) accompanying the radial artery, and a superficial system (the cephalic vein). These two networks usually communicate around the elbow flexion crease [15]. Its thin, pliable fascio-cutaneous paddle, combined with a long vascular pedicle, makes it particularly suitable for oral cavity reconstruction [14, 25, 27]. Its main drawback is the donor-site morbidity, with the sacrifice of a major vascular axis, a conspicuous forearm scar, the frequent need of a skin graft with the risk of tendon exposure [1, 4, 8, 18, 24].

The superficial circumflex iliac artery perforator flap (SCIP) is an inguinal cutaneous flap, vascularized by the superficial and deep branches of the superficial circumflex iliac artery (SCIA). Its venous drainage relies on the venae comitantes of the SCIA and on the superficial circumflex iliac vein (SCIV). It offers the advantages of a relatively thin skin paddle and the possibility of primary donor-site closure in most cases [5, 17]. However, its use for head and neck reconstruction may be limited due to its short vascular pedicle (around 5 cm) and its anatomical variability [7, 10, 22].

To lengthen the SCIP pedicle, Fernández-Garrido *et al.* described a modified SCIP design (extended SCIP, eSCIP), vascularized only by the superficial branch of the SCIA, shifting the skin paddle laterally and cranially to the anterior superior iliac spine (ASIS), along the iliac crest [5]. However, the vascular anatomy of the eSCIP remains insufficiently described. Moreover, anatomical descriptions of the SCIP remain heterogeneous, with ambiguities regarding the SCIA branches and perforators, concerning their nomenclature, their origin, and their relationships with adjacent vascular axes [6, 22].

The aim of this anatomical study was to compare the morphometric characteristics of the eSCIP and the RFFF and to describe the vascular variations of the eSCIP, to clarify its anatomical characteristics and their potential implications for oral cavity reconstruction.

MATERIALS AND METHODS

This cadaveric anatomical study was conducted after approval by the ethics committee of the Institut d'Anatomie du Fer à Moulin (Université Paris Cité), in accordance with the French legislation concerning body donation for medical teaching and research purposes. All donors had given free and informed consent during their lifetime to the donation of their body for scientific and educational purposes. Dissections were performed at the Fer à Moulin Anatomy Laboratory in Paris between November 2024 and May 2025. When possible, an eSCIP and a RFFF were harvested bilaterally from the same specimen.

Dissection protocols

RFFF harvest

An 8 × 8 cm skin paddle was designed on the volar aspect of the forearm, centered on the distal end of the radial pedicle and the cephalic vein. An initial S-shaped incision was carried on the anterior side of

the forearm from the proximal border of the skin paddle to the elbow flexion crease. Dissection was performed in the muscular fascial plane, preserving the cephalic vein. The skin paddle was then incised and raised in the fascial plane, to the fossa between the pronator teres medially and the brachioradialis laterally, carefully preserving the superficial sensory branch of the radial nerve. The radial pedicle was identified in the fossa between the pronator teres and the brachioradialis, and ligated distal to the skin paddle, and dissected from distal to proximal up to the elbow crease. The communicating vein between the cephalic vein and the deep venae comitantes was preserved.

eSCIP harvest

The eSCIP was harvested using the modified technique previously described by Fernández-Garrido *et al.* [5]. An 8 × 7 cm fusiform skin paddle was designed along the iliac crest above the ASIS. The incision was first made in the groin region, allowing identification of the superficial branch of the SCIA and the SCIV. The arterial and venous pedicles were dissected from the proximal end of the paddle to their origin on the femoral vessels. The skin paddle was then raised, taking care to maintain the vessels attached to the paddle.

Anatomical analysis

The anatomical analysis comprised two components: a morphometric comparison of the eSCIP and the RFFF, and a descriptive assessment of the vascular variations of the eSCIP.

Comparative morphometric analysis

The morphometric characteristics of the two flaps were assessed using three variables:

- Pedicle length (cm), measured with a standardized ruler between the origin of the artery supplying the flaps and its point of entry into the skin paddle
- Skin paddle thickness (mm), measured with the same caliper for all dissections
- Vessel diameter (mm), measured with a standardized ruler, at the origin of the artery supplying the flap and the termination of the draining vein respectively. The same measurement method was applied to both flaps to ensure comparability.

Measurements were performed using an identical method for both flaps, to allow their morphometric comparison.

Study of vascular anatomical variations of the eSCIP

Variations of the arterial and venous networks of the eSCIP were assessed in comparison with previously described vascular patterns in the literature [5, 16, 23].

Regarding the arterial system, this classical configuration described a SCIA originating from the femoral artery 2.5–3 cm below the inguinal ligament and dividing quickly into two branches: a superficial branch initially ascending, exiting the superficial fascia and running laterally toward the ASIS; and a deep branch initially running laterally beneath the fascia, through the sartorius muscle, and then ascending toward the ASIS.

Regarding the venous system, the classical drainage relied on 2 networks: a deep network consisting of the venae comitantes accompanying the arterial branches of the SCIA, and the SCIV as superficial network, having an independent course from the arterial branches, and sometimes communicating with the venae comitantes in their medial portion, before draining in the femoral venous system.

Any variation in the origin, course, division, or anatomical relationships of the arterial branches, as well as the organization and drainage pathways of the venous network, was recorded and described relative to this reference configuration. The anatomical variations identified during the dissection were recorded descriptively.

Statistical analysis

Quantitative variables were described by their median, interquartile range, minimum and maximum values, as well as their mean and standard deviation. Qualitative variables were presented as counts and percentages, with exact 95% confidence intervals if relevant.

Morphometric comparisons between the eSCIP and RFFF were performed on the sides for which both flaps had been harvested from the same specimen, using the Wilcoxon signed-rank test. Differences were estimated using the Hodges-Lehmann estimator for paired data and its 95% confidence interval.

To assess the influence of possible correlation between bilateral measurements from the same specimen, a sensitivity analysis was performed by averaging the measurements of each parameter per specimen.

Analyses were performed with Python 3.12, using the NumPy, pandas, and SciPy libraries. Tests were two-sided, with the significance threshold set at $p < 0.05$.

RESULTS

A total of seventeen fresh cadaveric specimens were dissected. Some specimens had scars in the regions of interest and the RFFF and eSCIP could not always be harvested simultaneously or bilaterally. In total, 24 RFFF were harvested from 13 specimens and 20 eSCIP from 12 specimens. Both flaps were harvested 16 times on the same side, on 9 specimens, constituting the paired sample.

Comparative morphometric analysis of the eSCIP and RFFF

Vascular pedicle length

The median pedicle length was 13.0 cm [10.8–14.0] for the eSCIP and 15.0 cm [13.5–15.2] for the RFFF. In the paired sample (16 sides), the eSCIP was significantly shorter, with a paired difference estimated by the Hodges-Lehmann method of -3.25 cm (95% CI: -5.00 to -1.50; p = 0.002). This difference persisted in the sensitivity analyses performed at the level of the 9 specimens (– 2.75 cm; 95% CI: −5.25 to − 0.25; p = 0.039) (Table 1, Fig. 1).

The eSCIP pedicle length was at least 10cm in 16/20 dissections (80%), at least 12cm in 12/20 (60%) and at least 14cm in 7/20 (35%). The pedicle length of the RFFF was at least 14cm in 17/24 dissections (70,8%) (Table 1).

Paddle thickness

The median paddle thickness was 3.0 mm [2.0–5.2] for the eSCIP and 2.0 mm [2.0–3.0] for the RFFF. The paired difference was 1.50 mm (95% CI: 0.00 to 2.50; p = 0.014).

A paddle thickness of 5 mm or less was observed in 15/20 eSCIP (75,0%) and 23/24 RFFF (95,8%) (Table 1).

Vessel diameter

The median arterial diameter was 3.0 mm [3.0–3.0] for the eSCIP, versus 5.0 mm [4.0–6.0] for the RFFF, with a paired difference of -2.50 mm (95% CI: -3.00 to -1.50; p < 0.001).

The median venous diameter was 5.0 mm [4.0–6.0] for the eSCIP, versus 6.0 mm [5.0–7.0] for the RFFF, with no statistically significant difference (paired difference: -1.00 mm; 95% CI: -2.00 to 0.00; p = 0.077).

Among the 20 eSCIP, all measured arterial diameters were greater than or equal to 2mm and all venous diameters were greater than or equal to 3 mm. An arterial diameter of at least 3 mm was observed in 16/20 dissections (80%) (Table 1).

Bilateral comparison

In specimens with bilateral measurements, no significant difference in pedicle length was found between the right and left sides, for either the eSCIP (8 specimens; p = 0.812) or the RFFF (11 specimens; p = 0.164). The intraclass correlation coefficients (ICC) were 0.85 (95% CI: 0.41–0.97) and 0.70 (95% CI: 0.24–0.91) respectively.

Vascular anatomical variations of the eSCIP

Arterial variations

The SCIA originated from the common femoral artery below the inguinal ligament in 18/20 dissections (90%). In the remaining two cases (10%), the SCIA arose from a common trunk with the superficial

inferior epigastric artery (SIEA). Representative examples of the observed vascular configurations are illustrated in Fig. 2.

The superficial and deep branches of the SCIA were identified in all dissections, with a disposition and course of the superficial branch of the SCIA consistent with the reference configuration.

Venous variations

Variations in venous drainage were observed in four dissections: in one case, the SCIV could not be identified, and drainage was provided by a common trunk formed by the confluence of the two venae comitantes; in two cases, the SCIV drained into the superficial inferior epigastric vein (SIEV); and in one case, it drained into the great saphenous vein. These observations were reported descriptively, without estimation of the frequency in the general population.

Table 1
Morphometric characteristics and paired comparison of the RFFF and eSCIP

Pedicle length (cm)	**eSCIP**	**RFFF**	**Paired comparison**	**p**
	n = 20	**n = 24**	**n = 16 pairs**	
Median [Q1 ; Q3] (min–max)	13,0 [10,8 ; 14,0] (8,0–17,0)	15,0 [13,5 ; 15,2] (12,0–19,0)	−3,25 [− 5,00 ; −1,50]	0,002
Mean ± SD	12,4 ± 2,5	14,8 ± 1,7		
Paddle thickness (mm)	**n = 20**	**n = 24**	**n = 16 pairs**	
Median [Q1 ; Q3] (min–max)	3,0 [2,0 ; 5,2] (2,0–11,0)	2,0 [2,0 ; 3,0] (1,0–6,0)	1,50 [0,00 ; 2,50]	0,014
Mean ± SD	4,3 ± 2,7	2,6 ± 1,0		
Arterial diameter at its origin (mm)	**n = 20**	**n = 24**	**n = 16 pairs**	
Median [Q1 ; Q3] (min–max)	3,0 [3,0 ; 3,0] (2,0–5,0)	5,0 [4,0 ; 6,0] (3,0–8,0)	−2,50 [− 3,00 ; −1,50]	< 0,001
Mean ± SD	3,0 ± 0,7	5,1 ± 1,4		
Venous diameter at its termination (mm)	**n = 20**	**n = 24**	**n = 16 pairs**	
Median [Q1 ; Q3] (min–max)	5,0 [4,0 ; 6,0] (3,0–7,0)	6,0 [5,0 ; 7,0] (4,0–10,0)	−1,00 [− 2,00 ; 0,00]	0,077
Mean ± SD	5,0 ± 1,1	6,0 ± 1,4		

eSCIP extended superficial circumflex iliac artery perforator flap, RFFF radial forearm free flap, SD standard deviation.

Arterial diameter was measured at the origin of the superficial circumflex iliac artery (SCIA) for the eSCIP and the radial artery for the RFFF. Venous diameter was measured at the termination of the superficial circumflexiliac vein (SCIV) for the eSCIP and the cephalic vein for the RFFF. In one eSCIP dissection, where the SCIV could not be identified, the main draining vein formed by the confluence of the two venae comitantes was measured instead.

Values are presented as median (minimum–maximum) or mean ± standard deviation (SD). Paired differences are expressed as Hodges–Lehmann estimates (eSCIP − RFFF) with 95% confidence intervals. Comparisons were performed using the Wilcoxon signed-rank test on 16 paired sides.

eSCIP, extended superficial circumflex iliac artery perforator flap; RFFF, radial forearm free flap; SCIA, superficial circumflex iliac artery; SCIV, superficial circumflex iliac vein.

Comparison of (A) vascular pedicle length, (B) skin paddle thickness, (C) arterial diameter, and (D) venous diameter in 16 paired dissections from 9 cadaveric specimens. Each pair of connected points represents measurements obtained from the two flaps harvested on the same side of a specimen. Bold horizontal lines indicate median values. P values were calculated using the Wilcoxon signed-rank test.

Dashed line: approximate location of the inguinal ligament.

Figure 2.A (left side): **Reference configuration of the eSCIP**, showing the superficial circumflex iliac artery (SCIA) arising from the femoral artery and dividing into a superficial and deep branch, with the superficial circumflex iliac vein (SCIV) communicating with the venae comitantes through a common venous trunk.

Black arrow: SCIA; red arrow: superficial branch of the SCIA; brown arrow deep branch of the SCIA; light blue arrow: SCIV; deep blue arrow: common venous trunk

Figure 2.B (right side): **Variation in arterial origin**, with the superficial branch of the SCIA arising from a commom trunk with the superficial epigastric artery (SIEA).

Red arrow: superficial branch of the SCIA; pink arrow: SIEA

DISCUSSION

This comparative anatomical study highlights several morphometric differences between the eSCIP and the RFFF. The eSCIP offers a longer vascular pedicle than the conventional SCIP, although it remains shorter than that of the RFFF, with a slightly thicker skin paddle and a smaller arterial caliber. The study of the eSCIP vascular networks also showed a relative consistency regarding the course of the superficial branch of the SCIA, despite variations in arterial origin and venous drainage.

The RFFF is one of the gold standards for the reconstruction of medium-sized oral cavity defects mainly because of its thin paddle and long vascular pedicle [14, 25, 27]. The SCIP is an alternative that reduces donor-site morbidity, but its relatively short pedicle may limit its indications in head and neck

reconstruction [10]. The design modification described by Fernández-Garrido *et al.*, placing the paddle beyond the ASIS, aims to increase pedicle length by using only the superficial branch of the SCIA [5]. In our study, the median eSCIP pedicle length reached 13 cm, with a length of at least 10cm in 80% of the dissections. Although significantly shorter than that of the RFFF, this length supports the anatomical value of the extended design and could widen the choice of recipient vessels.

Paddle thickness is another important characteristic. In our series, the eSCIP paddle was significantly thicker than that of the RFFF, although a thickness of 5 mm or less was observed in 75% of dissections. Flap thickness appeared greater in specimens with a thicker lower abdominal panniculus. However, the body mass index of the specimens was not available, and the assessment of body habitus relied on a subjective clinical impression. These results should therefore be interpreted with caution and no quantitative relationship between adiposity and skin paddle thickness can be established. This nevertheless suggests that donor-site morphology may be an important factor in patient selection.

Arterial diameter was also significantly smaller for the eSCIP than for the RFFF, whereas the difference in venous diameter was not statistically significant. These results should be interpreted cautiously, as measurements were performed on non-pressurized cadaveric vessels. Therefore, the values obtained cannot be directly related to physiological luminal diameters. Nevertheless, the relative difference observed between the two flaps, measured using an identical method, suggests that the arterial pedicle of the eSCIP has a smaller caliber, which may have implications for microsurgical anastomosis. The literature also reports a SCIA diameter of 1–2 mm [9, 10, 13] and a radial artery diameter of 2–4 mm [2], and these orders of magnitude are consistent with the anatomical data of our study.

The anatomical analysis of the eSCIP also revealed several vascular variations, consistent with the complexity of inguinal vascular anatomy described in the literature. In two dissections, the SCIA arose from the SIEA rather than from the common femoral artery. These findings are consistent with those of Suh *et al.* [22] who reported a femoral origin of the SCIA in 84.8% of cases, and He *et al*. [7] who identified five distinct configurations involving the SCIA, SIEA, and deep circumflex iliac artery (DCIA). Despite these variations in arterial origin, the superficial branch of the SCIA was consistently identified and followed a course consistent with its reference anatomical configuration. Variations in venous drainage were also observed, including drainage of the SCIV into the SIEV or the great saphenous vein. Beyond these anatomical variations, inconsistencies in vascular nomenclature have been highlighted by Gentileschi *et al.* [6]. Together, these findings underscore the importance of accurately identifying the origin, course, and connections of the inguinal vessels during eSCIP harvest.

Variability in the distal course of the superficial branch of the SCIA may also have implications for the design of the eSCIP paddle. Suh *et al.* [22] described two configurations of the superficial branch distally: a direct cutaneous type, in which the branch inserts directly into the dermis before reaching the ASIS, and an axial type, in which it continues its course beyond the ASIS in the superficial plane. They also reported a higher frequency of partial necrosis in large flaps when the superficial branch of the SCIA had a direct cutaneous insertion. This observation may be particularly relevant for the eSCIP, whose design

extends beyond the territory conventionally used for the SCIP. The anatomical data of Zubler *et al*. [28] provide an additional element for this reflection, as the main perforators of the superficial branch of the SCIA were clustered around the lateral half of the inguinal ligament. Thus, depending on the anatomical configuration, extension of the paddle beyond the ASIS could exceed the cutaneous territory of the superficial branch of the SCIA. This hypothesis cannot, however, be verified in our study, as the absence of perfusion of the specimens limited the analysis of the distal configuration of the superficial branch of the SCIA.

This study has several limitations. The number of specimens was limited, and the possibility of bilateral harvest were restricted by the presence of scars at some donor sites. Measurements performed on fresh non-perfused specimens (notably those of vessel diameters), do not necessarily reflect physiological conditions. Finally, the absence of a perfusion study did not allow assessment of the vascularization of the distal portion of the eSCIP, while the cadaveric nature of the study precluded any comparison of the clinical and functional outcomes of the two flaps.

CONCLUSION

This comparative anatomical study shows that the eSCIP provides a longer vascular pedicle than the conventional SCIP, although significantly shorter and with a smaller arterial caliber, than that of the RFFF. The superficial and deep branches of the SCIA showed a consistent anatomical arrangement in our series, despite some variations in arterial origin and venous drainage. These results clarify the anatomical characteristics of the eSCIP and highlight the value of better characterizing its distal vascularization to ascertain its role in head and neck reconstruction.

Declarations

Funding: No funding was received to assist with the preparation of this manuscript.

Competing interests: The authors have no competing interests.

Ethics approval: Approved by the ethics committee of the Body Donation Center of the Institut d’Anatomie du Fer à Moulin (Université Paris Cité).

Consent to participate: Body donors provided informed consent during their lifetime for scientific and educational use, as described in the Methods.

Data availability: The datasets generated an analyzed during the current study are available from the corresponding author upon reasonable request.

Author contributions

C Fouquoire: Protocol/project development, Data collection or management, Manuscript writing/editing

J Gregory: Data analysis

O Berlina: Data analysis

C Vacher: Protocol/project development

S Deneuve: Manuscript writing/editing

L Nokovitch: Protocol/project development, Manuscript writing/editing

References

1. Brown MT, Couch ME, Huchton DM (1999) Assessment of donor-site functional morbidity from radial forearm fasciocutaneous free flap harvest. Arch Otolaryngol Head Neck Surg 125:1371–1374. https://doi.org/10.1001/archotol.125.12.1371
2. Cha YH, Nam W, Cha IH, Kim HJ (2017) Revisiting radial forearm free flap for successful venous drainage. Maxillofac Plast Reconstr Surg 39:14. https://doi.org/10.1186/s40902-017-0110-8
3. Davudov MM, Harirchi I, Arabkheradmand A, Garajei A, Mahmudzadeh H, Shirkhoda M et al (2019) Evaluation of quality of life in patients with oral cancer after mandibular resection. Med (Baltim) 98:e17431. https://doi.org/10.1097/MD.0000000000017431
4. Deneuve S, Majoufre C, Testelin S, Barry B, Louis MY, Longis J et al (2021) Donor site sequelae and patient satisfaction after head and neck reconstruction with a radial forearm free flap. Eur Arch Otorhinolaryngol 278:4051–4058. https://doi.org/10.1007/s00405-021-06649-0
5. Fernandez-Garrido M, Nunez-Villaveiran T, Zamora P, Masia J, Leon X (2022) The extended SCIP flap: An anatomical and clinical study of a new SCIP flap design. J Plast Reconstr Aesthet Surg 75:3217–3225. https://doi.org/10.1016/j.bjps.2022.06.021
6. Gentileschi S, Servillo M, De Bonis F, Albanese R, Pino V, Mangialardi ML et al (2019) Radioanatomical Study of the Pedicle of the Superficial Circumflex Iliac Perforator Flap. J Reconstr Microsurg 35:669–676. https://doi.org/10.1055/s-0039-1693144
7. He Y, Jin S, Tian Z, Fang Z, Ma C, Tao X et al (2016) Superficial circumflex iliac artery perforator flap's imaging, anatomy and clinical applications in oral maxillofacial reconstruction. J Craniomaxillofac Surg 44:242–248. https://doi.org/10.1016/j.jcms.2015.12.002
8. Ho T, Couch M, Carson K, Schimberg A, Manley K, Byrne PJ (2006) Radial forearm free flap donor site outcomes comparison by closure methods. Otolaryngol Head Neck Surg 134:309–315. https://doi.org/10.1016/j.otohns.2005.09.019
9. Hurrell MJL, Clark JR, Ch'ng S, Low TH, Nguyen KM, Elliott MS et al (2023) Comparison between the radial forearm and superficial circumflex iliac artery perforator free flaps for oral soft tissue reconstruction. Int J Oral Maxillofac Surg 52:181–187. https://doi.org/10.1016/j.ijom.2022.06.008
10. Kwon JG, Pereira N, Tonaree W, Brown E, Hong JP, Suh HP (2021) Long Pedicled Superficial Circumflex Iliac Artery Flap Based on a Medial Superficial Branch. Plast Reconstr Surg 148:615e–9e.

https://doi.org/10.1097/PRS.0000000000008388

11. Lam L, Samman N (2013) Speech and swallowing following tongue cancer surgery and free flap reconstruction – A systematic review. Oral Oncol 49:507–524. https://doi.org/10.1016/j.oraloncology.2013.03.001
12. Manrique OJ, Leland HA, Langevin CJ, Wong A, Carey JN, Ciudad P et al (2017) Optimizing Outcomes following Total and Subtotal Tongue Reconstruction: A Systematic Review of the Contemporary Literature. J Reconstr Microsurg 33:103–111. https://doi.org/10.1055/s-0036-1593772
13. Messa CA, Carney MJ, Tantillo K, Othman S, Moores C, Mirzabeigi MN et al (2021) Characteristics of the Superficial Circumflex Iliac Artery Perforator Flap in a Western Population and a Practice Approach for Free Flap Reconstruction. J Reconstr Microsurg 37:486–491. https://doi.org/10.1055/s-0040-1719051
14. Mohamed AAS, Mai L, Mashrah MA, Fan S, Wang S, Lin Z et al (2024) Medial sural artery perforator free flap versus radial forearm free flap in oral cavity reconstruction and donor site morbidity. Clin Oral Investig 28:269. https://doi.org/10.1007/s00784-024-05618-1
15. Netscher DT, Sharma S, Alford EL, Thornby J, Leibman NS (1996) Superficial versus deep: options in venous drainage of the radial forearm free flap. Ann Plast Surg 36:536–541
16. Ok F, Nteli Chatzioglou G, Karip B, Önal V, Yıldız N, Tatar BE et al (2026) Anatomical study of the superficial and deep circumflex iliac arteries: morphology, variability, and surgical relevance. Surg Radiol Anat 48:55. https://doi.org/10.1007/s00276-026-03817-x
17. Pereira N, Venegas J, Oñate V, Camacho JP, Roa R (2023) Extremity reconstruction with superficial circumflex iliac artery perforator free flap: Refinements and innovations after 101 cases. J Plast Reconstr Aesthet Surg 85:1–9. https://doi.org/10.1016/j.bjps.2023.06.048
18. Richardson D, Fisher SE, Vaughan ED, Brown JS (1997) Radial forearm flap donor-site complications and morbidity: a prospective study. Plast Reconstr Surg 99:109–115. https://doi.org/10.1097/00006534-199701000-00017
19. Sakamoto Y, Takahara T, Ota Y, Aoki T, Yamazaki H, Otsuru M et al (2014) MRI analysis of chronological changes in free-flap volume in head and neck reconstruction by volumetry. Tokai J Exp Clin Med 39:44–50
20. Smith GI, O'Brien CJ, Choy ET, Andruchow JL, Gao K (2005) Clinical outcome and technical aspects of 263 radial forearm free flaps used in reconstruction of the oral cavity. Br J Oral Maxillofac Surg 43:199–204. https://doi.org/10.1016/j.bjoms.2004.11.024
21. Soutar DS, McGregor IA (1986) The radial forearm flap in intraoral reconstruction: the experience of 60 consecutive cases. Plast Reconstr Surg 78:1–8. https://doi.org/10.1097/00006534-198607000-00001
22. Suh HSP, Jeong HH, Choi DH, Hong JP (2017) Study of the Medial Superficial Perforator of the Superficial Circumflex Iliac Artery Perforator Flap Using Computed Tomographic Angiography and

Surgical Anatomy in 142 Patients. Plast Reconstr Surg 139:738–748. https://doi.org/10.1097/PRS.0000000000003147

23. Sun JM, Yamamoto T, Goh TL (2024) Venous anatomy of the superficial circumflex iliac artery perforator flap: A cadaveric and clinical study. J Plast Reconstr Aesthet Surg 88:1–7. https://doi.org/10.1016/j.bjps.2023.10.096
24. Timmons MJ, Missotten FE, Poole MD, Davies DM (1986) Complications of radial forearm flap donor sites. Br J Plast Surg 39:176–178. https://doi.org/10.1016/0007-1226(86)90078-0
25. Urken ML, Moscoso JF (1993) Sensate cutaneous flaps in oral cavity and pharyngeal reconstruction. Oper Tech Otolaryngol Head Neck Surg 4:141–144. https://doi.org/10.1016/S1043-1810(10)80141-1
26. Yamaguchi K, Kimata Y, Onoda S, Mizukawa N, Onoda T (2012) Quantitative analysis of free flap volume changes in head and neck reconstruction. Head Neck 34:1403–1407. https://doi.org/10.1002/hed.21944
27. Yang GF, Chen PJ, Gao YZ, Liu XY, Li J, Jiang SX et al (1997) Classic reprint Forearm free skin flap transplantation: a report of 56 cases. Br J Plast Surg 50:162–165. https://doi.org/10.1016/S0007-1226(97)91363-1
28. Zubler C, Haberthür D, Hlushchuk R, Djonov V, Constantinescu MA, Olariu R (2021) The anatomical reliability of the superficial circumflex iliac artery perforator (SCIP) flap. Ann Anat 234:151624. https://doi.org/10.1016/j.aanat.2020.151624

Figures

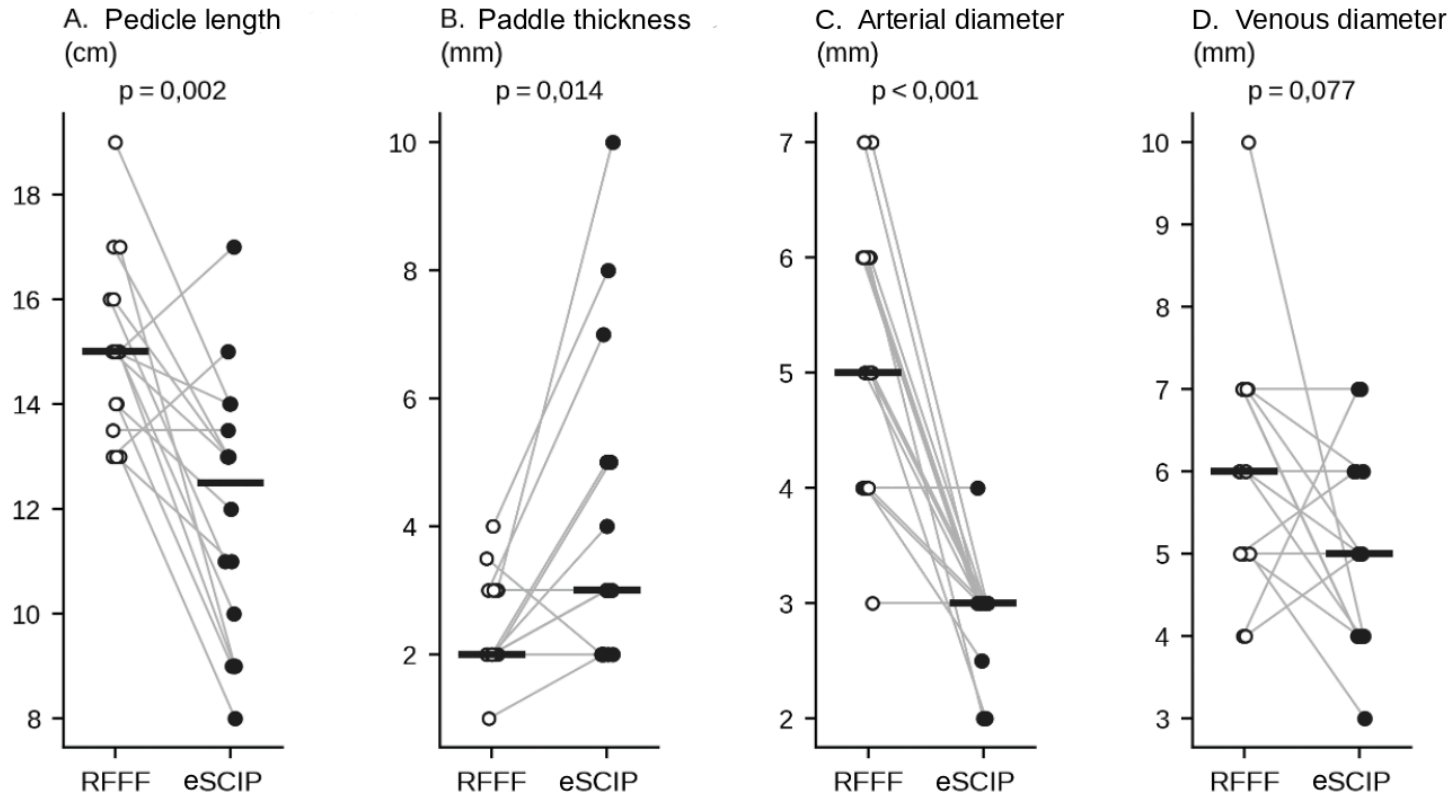

Figure 1

Paired comparison of the eSCIP and RFFF on the 16 sides where both flaps were harvested from the same specimen

Comparison of (A) vascular pedicle length, (B) skin paddle thickness, (C) arterial diameter, and (D) venous diameter in 16 paired dissections from 9 cadaveric specimens. Each pair of connected points represents measurements obtained from the two flaps harvested on the same side of a specimen. Bold horizontal lines indicate median values. P values were calculated using the Wilcoxon signed-rank test.

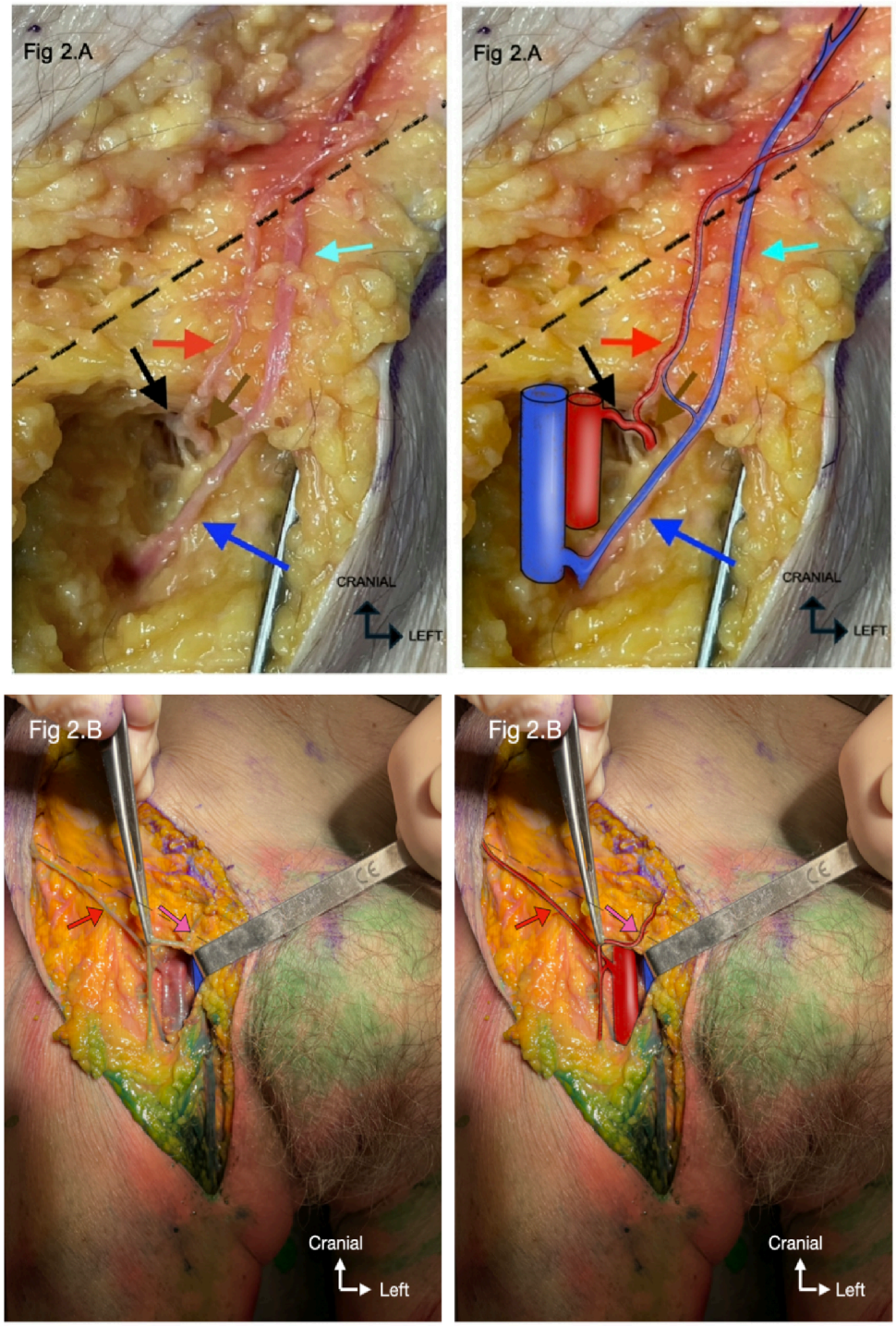

Figure 2

Examples of vascular anatomical variations observed during eSCIP dissections

Dashed line: approximate location of the inguinal ligament.

Fig 2.A (left side): **Reference configuration of the eSCIP**, showing the superficial circumflex iliac artery (SCIA) arising from the femoral artery and dividing into a superficial and deep branch, with the superficial circumflex iliac vein (SCIV) communicating with the venae comitantes through a common venous trunk.

Black arrow: SCIA; red arrow: superficial branch of the SCIA; brown arrow deep branch of the SCIA; light blue arrow: SCIV; deep blue arrow: common venous trunk

Fig 2.B (right side): **Variation in arterial origin**, with the superficial branch of the SCIA arising from a commom trunk with the superficial epigastric artery (SIEA).

Red arrow: superficial branch of the SCIA; pink arrow: SIEA