Research Square

Preprints are preliminary reports that have not undergone peer review.
They should not be considered conclusive, used to inform clinical practice,
or referenced by the media as validated information.

Small bowel infarction without abdominal tenderness despite biochemical improvement during diabetic ketoacidosis – hyperosmolar hyperglycemic state overlap: a case report

En Mei Sarah Tan

sarah.em.tan@nhghealth.com.sg

Tan Tock Seng Hospital

Case Report

Keywords: Diabetic ketoacidosis, hyperosmolar hyperglycemic state, small bowel infarction, intestinal ischaemia, pneumatosis intestinalis, portal venous gas

Posted Date: November 26th, 2026

DOI: https://doi.org/10.21203/rs.3.rs-11748616/v1

License: This work is licensed under a Creative Commons Attribution 4.0 International License.
Read Full License

Additional Declarations: No competing interests reported.

Abstract

Background.

Intestinal ischaemia is an uncommon but potentially fatal complication of hyperglycemic crises. Recognition is challenging when metabolic derangements offer an alternative explanation for clinical abnormalities and altered consciousness limits symptom reporting. We describe surgically confirmed small bowel infarction recognised through serial abdominal examination despite biochemical improvement during treatment of diabetic ketoacidosis–hyperosmolar hyperglycemic state overlap.

Case presentation.

A man in his 80s with insulin-treated type 2 diabetes presented with fever, confusion, hypotension and profound dehydration. Investigations revealed severe ketoacidosis (pH 7.06, bicarbonate 4–6 mmol/L), hyperglycemia (78.2 mmol/L), hyperosmolality (403 mOsm/kg) and elevated lactate (5.1 mmol/L). His abdomen was initially soft and non-tender. Following fluid resuscitation and insulin treatment, glucose decreased to 16.8 mmol/L, bicarbonate increased to 16 mmol/L, lactate fell to approximately 3 mmol/L and renal function improved. However, by the following morning, reassessment revealed marked, tense abdominal distension without tenderness, guarding or rigidity. Contrast-enhanced computed tomography demonstrated ileal pneumatosis and portomesenteric venous gas. Emergency laparotomy confirmed approximately 120 cm of infarcted small bowel requiring resection. Following second-look laparotomy and anastomosis, the patient recovered and was discharged home on day 13.

Conclusions.

Clinically significant intestinal ischaemia may coexist with improving biochemical markers during treatment of a hyperglycemic crisis. In patients unable to reliably report abdominal symptoms, new tense distension may be the principal warning sign even without tenderness or peritonism. Serial abdominal examination should inform decisions about urgent imaging and surgical assessment rather than relying on biochemical trends alone.

Background

Diabetic ketoacidosis (DKA) and hyperosmolar hyperglycemic state (HHS) are life-threatening metabolic emergencies characterised by severe disturbances in glucose and fluid homeostasis [1]. Abdominal symptoms and elevated lactate may accompany these conditions, potentially complicating recognition of concurrent intra-abdominal pathology. Acute mesenteric ischaemia is particularly important because delayed diagnosis can result in irreversible bowel infarction [2].

Intestinal ischaemia associated with DKA or HHS has been described previously, including cases of non-occlusive mesenteric ischaemia, bowel necrosis and portal venous gas [3–9]. Reported diagnostic triggers have included persistent abdominal pain, worsening metabolic abnormalities and clinical deterioration. However, symptom-based recognition becomes less reliable when altered consciousness limits the history and classical peritoneal signs are absent.

We report a patient with DKA–HHS overlap in whom surgically confirmed small bowel infarction was recognised following documentation of marked, tense abdominal distension despite improvement in several biochemical markers. The case illustrates the importance of serial examination when the clinical and biochemical trajectories diverge.

Case Presentation

A man in his 80s with insulin-treated type 2 diabetes mellitus, hypertension and dyslipidaemia presented on 11 August 2026 to the emergency department with confusion following one day of fever and cough. His most recent glycated haemoglobin was 9.3%.

On arrival, he was clinically dehydrated, hypotensive (85/46 mmHg) and hypoxemic, with a peripheral oxygen saturation of 87%. His abdomen was soft and non-tender. Bedside ultrasonography demonstrated a collapsed inferior vena cava without free intraperitoneal fluid.

Initial investigations revealed severe hyperglycemia (78.2 mmol/L), measured serum osmolality of 403 mOsm/kg, arterial pH of 7.06, bicarbonate of 4–6 mmol/L and β-hydroxybutyrate exceeding 8.7 mmol/L. Lactate was 5.1 mmol/L. Additional abnormalities included hyperkalemia (6.6 mmol/L) and acute kidney injury, with creatinine of 258 μmol/L compared with a baseline of approximately 60 μmol/L.

The working diagnosis was DKA–HHS overlap complicated by profound volume depletion, acute kidney injury and hyperkalemia. Infection was considered a possible precipitant given the preceding fever and cough, although chest radiography showed no consolidation.

The patient received intravenous balanced crystalloid, fixed-rate intravenous insulin, treatment for hyperkalemia and empirical antibiotics. He was subsequently transferred to the medical high-dependency unit for continued management.

By the following morning, biochemical parameters had improved substantially. At 05:25, bicarbonate had increased to 16 mmol/L, creatinine had decreased to 175 μmol/L and β-hydroxybutyrate had fallen to 1.7 mmol/L. Lactate was 3.1 mmol/L at 05:24, while capillary glucose had decreased to 16.8 mmol/L by 07:00.

Despite this biochemical improvement, marked abdominal distension was documented during the early morning high-dependency unit assessment, by approximately 07:40. The patient remained confused, limiting assessment of abdominal symptoms. Subsequent examination revealed a markedly distended, tense abdomen with sluggish bowel sounds but no tenderness, guarding or rigidity. Abdominal pressures

of 25 and 26 mmHg were documented during the morning reassessment; the exact measurement times and technique were not established.

The evolving examination raised concern for significant intra-abdominal pathology, including ileus, mechanical obstruction and intestinal ischaemia. Urgent contrast-enhanced computed tomography (CT) of the abdomen and pelvis was performed at 10:16 in the portal venous phase following administration of 80 mL of iohexol. Imaging demonstrated ileal pneumatosis intestinalis (Figure 1A), branching intrahepatic portal venous gas (Figure 1B) and gas within mesenteric venous branches accompanied by extensive mesenteric fat stranding (Figure 1C). Moderate ascites was present. The major mesenteric arterial trunks were reported to be patent. In the context of the new abdominal findings, these radiological abnormalities raised strong concern for intestinal ischaemia and prompted emergency surgical intervention.

Emergency laparotomy on 12 August 2026 revealed approximately 120 cm of infarcted small bowel, beginning 80 cm proximal to the terminal ileum. Turbid peritoneal fluid and fibrin were present. The stomach and proximal small bowel were distended, while the remaining small bowel and colon appeared viable. The infarcted segment was resected, and temporary abdominal closure was performed. At planned second-look laparotomy the following day, the remaining bowel was viable, permitting anastomosis and definitive closure.

Histopathological examination confirmed transmural infarction and necrosis. Both resection margins showed mucosal necrosis with viable submucosa and muscularis propria. No thrombus or vasculitis was identified in the examined histological sections. No gross perforation or malignancy was identified.

The temporal relationship between biochemical improvement, abdominal reassessment, imaging and surgical intervention is summarised in Figure 2.

Following postoperative intensive care, parenteral nutritional support and transition to subcutaneous insulin, the patient recovered sufficiently for discharge home on day 13.

At endocrinology review approximately two weeks after presentation, his abdomen was soft and non-tender, and a caregiver was supervising insulin administration. At surgical review approximately eight weeks after presentation, he was eating adequately, reported no abdominal or bowel symptoms and had a well-healed operative wound.

Discussion and Conclusions

This case highlights a diagnostic challenge during treatment of DKA–HHS overlap: extensive small bowel infarction was recognised despite substantial improvement in several biochemical parameters and the persistent absence of abdominal tenderness. The principal warning sign was marked, tense abdominal distension in a patient whose confusion limited symptom reporting. Serial abdominal examination, rather than biochemical deterioration or peritoneal signs, prompted further investigation.

Intestinal ischaemia complicating DKA or HHS has been described previously [3–9], including cases recognised after partial biochemical improvement. Chung and colleagues reported fulminant ischaemic colitis during severe DKA–HHS overlap, accompanied by progressive abdominal distension, rigidity and physiological deterioration [7]. Une and colleagues described an initial decline in lactate during resuscitation followed by a subsequent rise before surgery for non-occlusive mesenteric ischaemia [4]. Other reports have identified persistent abdominal pain or new symptoms following metabolic improvement as important diagnostic triggers [5, 6]. In contrast, the present patient had marked abdominal distension without tenderness, guarding or rigidity. This distinction is particularly relevant when altered consciousness limits the reliability of symptom-based assessment.

The biochemical trajectory further illustrates the limitations of relying on metabolic improvement to exclude concurrent abdominal pathology. Lactate decreased from 5.11 mmol/L on admission to 3.1 mmol/L at 05:24 and 2.2 mmol/L at 08:59, before increasing to 3.2 mmol/L at 10:43. Its initial decline may have reflected improved systemic perfusion following resuscitation without excluding persistent regional intestinal hypoperfusion. Although lactate remained abnormal, its downward trend coincided with improvements in glucose, bicarbonate and renal function. Lactate is neither sufficiently sensitive nor specific to exclude acute mesenteric ischaemia, and biochemical trends must therefore be interpreted alongside the evolving clinical examination [2].

The precise mechanism of intestinal infarction remains uncertain. Profound dehydration and initial hypotension may have compromised splanchnic perfusion, making non-occlusive mesenteric ischaemia plausible [3, 4, 6]. The major mesenteric arterial trunks were patent on portal venous phase CT, and histopathological examination identified no thrombus or vasculitis in the sampled sections. However, these findings do not exclude distal vascular pathology or establish a non-occlusive mechanism.

The recorded abdominal pressures of 25–26 mmHg raise the additional possibility that intra-abdominal hypertension impaired regional perfusion. Nevertheless, the measurement technique, duration of pressure elevation and temporal relationship to new organ dysfunction were not established. Abdominal compartment syndrome therefore cannot be diagnosed retrospectively from these measurements alone [10]. Whether elevated abdominal pressure contributed to intestinal injury or developed secondary to the evolving bowel pathology remains uncertain.

Pneumatosis intestinalis and portomesenteric venous gas are concerning radiological findings but do not invariably indicate irreversible bowel necrosis in isolation. In this patient, their coexistence with new tense abdominal distension and the preceding physiological derangements justified urgent surgical assessment. Current World Society of Emergency Surgery guidelines recommend prompt CT angiography when acute mesenteric ischaemia is suspected, including in patients with acute kidney injury [2]. Although portal venous phase CT rather than dedicated multiphase angiography was performed, the findings were sufficient to prompt emergency intervention.

An important limitation is that the onset of intestinal ischaemia cannot be determined. Bowel injury may have begun during the initial period of profound dehydration and hypotension, before clinically apparent

abdominal distension. This report therefore demonstrates the recognition of established infarction during biochemical improvement, rather than establishing that infarction developed after resuscitation.

The principal clinical lesson is the importance of serial abdominal examination during hyperglycemic crises, particularly when altered consciousness limits symptom reporting. The initially documented soft, non-tender abdomen provided a baseline against which the subsequent tense distension could be recognised. Improving metabolic parameters should not provide false reassurance when new objective abdominal abnormalities emerge. New tense abdominal distension, even without tenderness or peritonism, warrants urgent evaluation for intestinal ischaemia during DKA–HHS overlap.

Abbreviations

CT
computed tomography
DKA
diabetic ketoacidosis
HHS
hyperosmolar hyperglycemic state.

Declarations

Ethics approval and consent to participate

Ethics approval was not required for this single-patient case report. Consent to participate was not applicable.

Consent for publication

Written informed consent was obtained from the patient for publication of this case report and accompanying images.

Availability of data and materials

The clinical data underlying this case are held in the patient’s medical record and are restricted to protect patient confidentiality.

Competing interests

The author declares no competing interests.

Funding

No funding was received for this case report.

Authors' contributions

EMST prepared the case report and is responsible for the manuscript.

Acknowledgements

The author thanks the Emergency Department, high-dependency and intensive care teams, and the General Surgery and Endocrinology teams at Tan Tock Seng Hospital for their care of the patient.

References

1. Umpierrez GE, Davis GM, ElSayed NA, Fadini GP, Galindo RJ, Hirsch IB, et al. Hyperglycemic crises in adults with diabetes: a consensus report. Diabetes Care. 2024;47:1257–75. 10.2337/dci24-0032.
2. Bala M, Catena F, Kashuk J, De Simone B, Gomes CA, Weber D, et al. Acute mesenteric ischemia: updated guidelines of the World Society of Emergency Surgery. World J Emerg Surg. 2022;17:54. 10.1186/s13017-022-00443-x.
3. Takiguchi T, Arai M, Kim S, Ishii H, Ogasawara T, Shigeta K, et al. Nonocclusive mesenteric ischemia associated with a hyperosmolar hyperglycemic state: hepatic portal venous gas as an indicator of mesenteric ischemia. Acute Med Surg. 2021;8:e673. 10.1002/ams2.673.
4. Une K, Sumi Y, Kurayoshi M, Nakanuno R, Nakahara M. Nonocclusive mesenteric ischemia during treatment for ketoacidosis associated with acute-onset type 1 diabetes mellitus: a case report. Clin Case Rep. 2022;10:e05714. 10.1002/ccr3.5714.
5. Kim HI, Yoon KW, Kim HJ, Jeong D. Small bowel ischaemia—a rare complication of diabetic ketoacidosis: a case report. J Surg Case Rep. 2025;2025:rjaf498. 10.1093/jscr/rjaf498.
6. Kimura T, Kubo M, Takahashi K, Tatsumi F, Katakura Y, Shimoda M, et al. Diabetic ketoacidosis associated with non-occlusive mesenteric ischemia in a subject with type 2 diabetes mellitus. Intern Med. 2026;65:659–65. 10.2169/internalmedicine.5623-25.
7. Chung JS, Kim JS, Ju JK. Surgical abdomen masked by metabolic crisis: fulminant ischemic colitis in severe diabetic ketoacidosis – a case report and literature review. Front Endocrinol (Lausanne). 2026;17:1875153. 10.3389/fendo.2026.1875153.
8. Wan S, Wang X. Hepatic portal venous gas as an early sign of nonocclusive mesenteric ischemia in diabetic ketoacidosis. Am J Emerg Med. 2026;110:173–5. 10.1016/j.ajem.2026.08.024.
9. Yamada M, Yamaguchi H, Miyamoto H, Inazu D, Takii M, Oshima T, et al. A case of perforated ileum due to gangrenous ischemic enteritis after cardiopulmonary arrest with diabetic ketoacidosis and

hyperosmolar hyperglycemic syndrome. Gan Kagaku Ryoho. 2026;53:45–7. Japanese.

10. Kirkpatrick AW, Roberts DJ, De Waele J, Jaeschke R, Malbrain MLNG, De Keulenaer B, et al. Intra-abdominal hypertension and the abdominal compartment syndrome: updated consensus definitions and clinical practice guidelines from the World Society of the Abdominal Compartment Syndrome. Intensive Care Med. 2013;39:1190–206. 10.1007/s00134-013-2906-z.

Figures

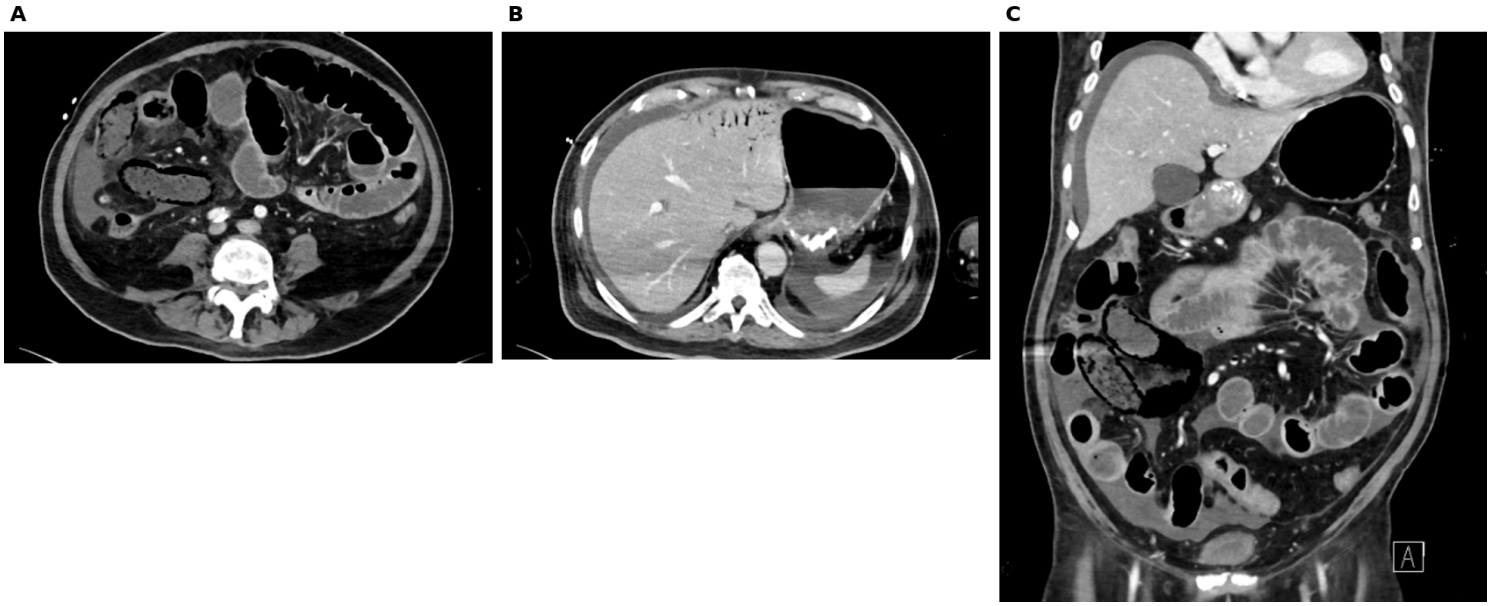

Figure 1

Portal venous phase contrast-enhanced CT of the abdomen and pelvis. (A) Axial image showing ileal pneumatosis intestinalis. (B) Axial image showing branching intrahepatic portal venous gas. (C) Coronal reconstruction showing tubular gas lucencies within mesenteric venous branches and associated mesenteric fat stranding.

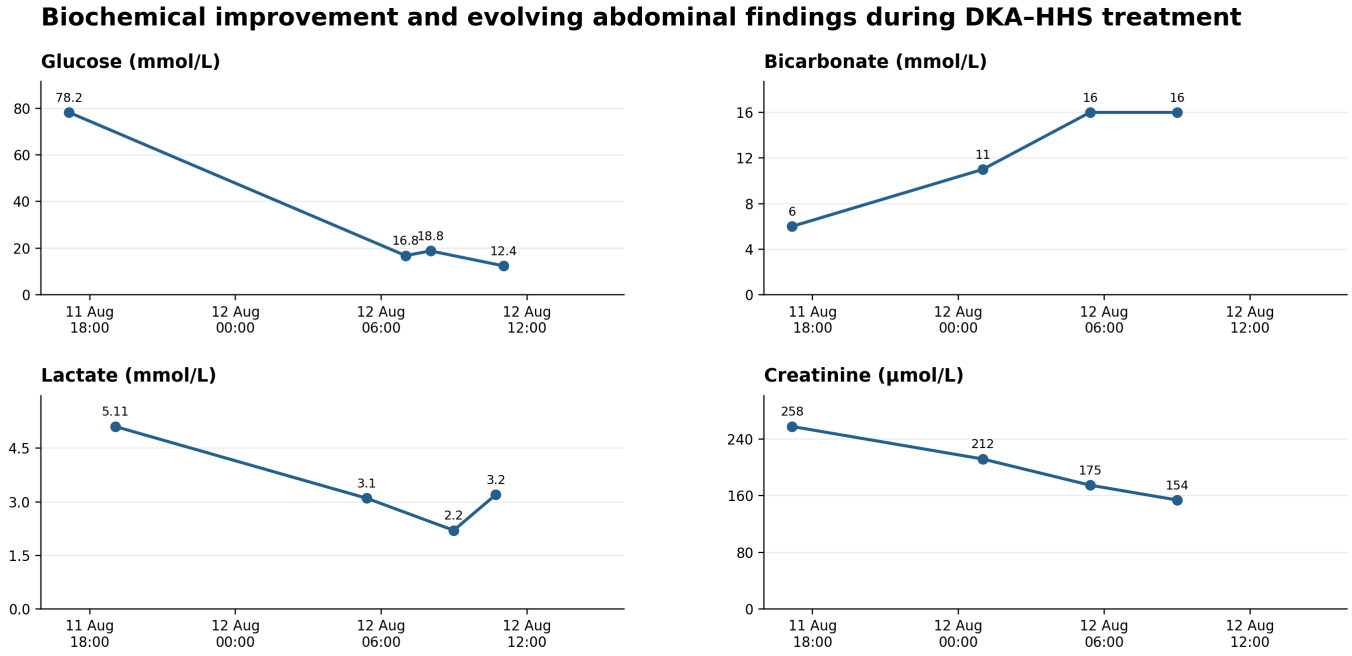

Documented clinical milestones — 12 August 2026

07:40	Marked abdominal distension documented
08:59	Abdominal pressure 25 mmHg documented (exact measurement time unknown)
09:05	Multidisciplinary review: tense, non-tender abdomen
09:47	CT abdomen/pelvis ordered
10:16	CT performed
10:38	CT report issued
14:40	Operative specimen collected (not incision time)

Notes

Abdominal pressure readings (25–26 mmHg) were recorded during morning reassessment; exact measurement times are not established.
Lines connect discrete laboratory samples and do not represent continuous measurements. CT = computed tomography.
Operative specimen collection at 14:40 is shown as a documented surgical milestone, not the time of incision.

Figure 2

Clinical and biochemical timeline. Serial glucose, bicarbonate, lactate and creatinine measurements during treatment of DKA–HHS overlap, aligned with documentation of marked abdominal distension, elevated abdominal pressure, computed tomography and emergency laparotomy. Laboratory points indicate specimen collection times; clinical milestones reflect documented assessment, order or procedure times. The timing of the onset of intestinal ischaemia is unknown.