Research Square

Preprints are preliminary reports that have not undergone peer review.
They should not be considered conclusive, used to inform clinical practice,
or referenced by the media as validated information.

Three-Dimensional Analysis of Apical Foramen Morphology in Maxillary First Premolars: A Micro-CT study in an Iraqi Subpopulation

Abdullah Mohammed Aljawhar
University of Basrah
Norliza Ibrahim
Universiti Malaya
Azwatee Abdul Aziz
Universiti Malaya
Hany Mohamed Aly Ahmed
Universiti Malaya
Noor Hayati Azami
nhayatiazami@um.edu.my
Universiti Malaya

Research Article

Keywords: Iraqi population, Maxillary first premolar, Micro-computed tomography

Posted Date: November 24th, 2026

DOI: https://doi.org/10.21203/rs.3.rs-11737780/v1

License: This work is licensed under a Creative Commons Attribution 4.0 International License.
Read Full License

Additional Declarations: No competing interests reported.

Abstract

This study aimed to investigate the apical root canal anatomy of maxillary first premolars in an Iraqi sub-population (ex *vivo*) using micro-computed tomography (micro-CT). A total of 151 extracted maxillary first premolars were collected and scanned using micro-CT with a voxel size of 25.1 μm. The patients' age and sex were unknown. Images were segmented and three-dimensionally (3D) reconstructed using Mimics software. The apical constriction (AC) for each canal was located and distances were measured from the AC to the major apical foramen (MAF), to the anatomic apex (AA) and from MAF to AA. The longest and shortest canal diameters at AC were also measured. The cross-sectional canal shape at the AC and the direction of the MAFs were determined. Qualitative data were analysed using the chi-square test while quantitative data were analysed with the Independent-Samples T-test and One-Way ANOVA with Bonferroni post hoc tests and respective non-parametric tests at a significance level of 0.05. Out of the 151 included maxillary first premolars, 82 (54.3%) were double rooted and 69 (45.7%) were single-rooted. The mean AC-MAF, AC-AA and MAF-AA distances were 0.49 mm ± 0.32 mm, 1.13 mm ± 0.56 mm and 0.74 mm ± 0.49 mm, respectively. The AC to AA and MAF to AA distances were significantly larger in the palatal canals compared to both the buccal and single canals ($P < 0.05$). The mean shortest and longest canal diameters at the AC were 0.18 mm ± 0.06 mm and 0.25 mm ± 0.1 mm, respectively, with 89.8% of the canals having oval cross-sectional shapes at AC. The two diameters were significantly smaller in the buccal canals compared to the palatal and single canals ($P < 0.05$). In 74.2% of the canals, the MAFs were deviated to one of the root sides, mostly to the palatal and distal aspects. The apical anatomy of maxillary first premolars is complex and variable in the studied Iraqi population. The majority of the canals had oval cross-sectional shapes at the AC with majority of MAFs showing deviation from the root axis.

Introduction

A crucial aspect in the success of the root canal shaping and cleaning procedures depends on understanding the anatomical characteristics of the apical part of the root canal system [1]. The complexity of the apical third anatomy has been demonstrated since the beginning of the last century [2, 3]. However, Kuttler [4] deeply analysed and investigated the morphology of the apical region of the root. He described the apical anatomy as the root canal tapering from the canal orifices to the apical constriction which refers to the part of the root canal with the smallest diameter. Beyond the apical constriction, also referred to as minor apical foramen, the canal widens as it goes out through the major apical foramen which is the end opening of the root canal on the outer root surface. The distance between the apical constriction and the major foramen is generally about 0.5–1.5 mm, with the shape described as hyperbolic, morning glory flower or funnel-shaped [5, 6].

The apical constriction has gained particular interest in anatomical studies because it is generally regarded as the reference point mostly used by dental practitioners as the apical limit for shaping, cleaning and obturation procedures [5, 7–9]. By evaluating apical and peri-radicular tissues following root canal treatment, Ricucci & Langeland [10] found that the most favourable prognosis noticed in the

procedures terminated at the apical constriction while the worst prognosis was found when working beyond the apical constriction. However, they acknowledged that it is difficult to locate the apical constriction clinically.

Normally, the major apical foramen is not located at the anatomical apex of the root, which is the morphological tip or the end of the root, but is about 0.5–3.0 mm offset [5, 6]. This discrepancy is more noticeable in teeth of older individuals as a result of cementum apposition. Studies have revealed that the major apical foramen coincides with the anatomical apex 6.7–46% of the time [11–15].

Maxillary premolars are identified as the second most common teeth requiring endodontic treatment among maxillary teeth, following the first molars [16–18]. Numerous studies have revealed significant variations in the external and internal root anatomy of maxillary first premolars [19–23]. These variations are affected by differences in race and geographic origin, as well as age and gender [24, 25]. Due to these anatomical disparities, root canal treatment of maxillary premolars poses a significant challenge for clinicians and their anatomy is required to be thoroughly investigated in different populations [26, 27].

Iraq is situated at the convergence of three significant biogeographical regions: the Mediterranean, the Arabian Peninsula, and the Iranian Plateau. The Iraqi population has been affected by various cultures and civilisations over time, including ancient Mesopotamians, Arabs, Persians, Turks, and Europeans, and has undergone an extended history of invasion, immigration, and intermarriage [28, 29]. The intermingling of the indigenous inhabitants with nearby and distant populations may have contributed to the development of the contemporary genetic composition of the Iraqi Arab population, which differs from other Arabic populations despite sharing a common ancestor [30].

Currently, micro-CT imaging modality is considered the gold standard for studying dental anatomy in *ex vivo*, providing a detailed quantitative and qualitative description of the teeth's external and internal anatomy [31–33], and overcoming the shortcomings of the other methods [34]. Even though the maxillary first premolars are thought to have one of the most complex apical anatomies [35, 5], there is little evidence examining their apical foramina using micro-CT. To the best of authors knowledge, there is no previous studies had used the micro-CT imaging to investigate the root canal apical anatomy of maxillary first premolar in Iraqi population. Therefore, this study aimed to use micro-CT and the MIMICS software to investigate the apical root canal anatomy of maxillary first premolars in an Iraqi sub-population, determining the distance of apical constriction with regard to the major apical foramen and anatomical apex, measuring the canal diameters at the apical constriction and determining the directions of major apical foramina. The null hypothesis is that there are no significant differences in the apical morphometric parameters of the different root canals of maxillary first premolar in the Iraqi sub-population obtained by using micro-CT evaluation.

Materials and methods

- Ethical approval

All methods were carried out in accordance with the Declaration of Helsinki. An informed consent was obtained from all subjects and/or their legal guardian(s), to use their extracted teeth for research purposes. The Scientific Committee of the College of Dentistry in University of Basrah as well as the Medical Ethics Committee of the Faculty of Dentistry in UNIVERSITI MALAYA had granted the approvals to conduct this study (approval no. 7/54/1706 and no. DF RD2207/0033 (L), respectively).

- Samples size calculation

The sample size of this study was calculated using an online sample size calculator (https://www.calculator.net/sample-size-calculator.html). According to the Central Statistical Organization of Iraq [36], the Iraqi population is estimated to be around 35.5 million people, with the exception of the Kurds in the Kurdistan region in the north of Iraq. The sample size was estimated to be approximately 151 teeth using an 8% margin of error and a 95% level of confidence [37]. This sample size is in line with that of several other micro-CT studies on different populations, as summarised in the following table:

Authors	Studied population	Studied tooth	Sample size
AL-Rammahi et al.[38]	Malaysian	Mandibular 1st molar	140
Wolf et al.[19]	Swiss-German	Maxillary 1st premolar	115
Wolf et al.[39]	Swiss-German	Maxillary 2nd premolar	116
Saber et al.[40]	Egyptian	Mandibular 1st molar	96
Elnour et al.[41]	Saudi Arabian	Maxillary 2nd premolar	100
Alenezi et al.[21]	Kuwaiti	Maxillary 1st premolar	100
Liu et al.[42]	Southwestern Chinese	Mandibular 1st premolars	115

- Teeth collection and inclusion and exclusion criteria

The required number of teeth was collected randomly from specialized dental centres and dental care clinics in the city of Basrah in the south of Iraq which is inhabited mainly by a population of Iraqi Arab ethnicity. The reasons for extraction were mainly for orthodontic treatments and were unrelated to this study. The patients' ages and gender were unknown [37]. After extraction, the teeth were stored in 10% formalin solution and then washed with tap water, disinfected with 5.25% sodium hypochlorite for 30 minutes and cleaned with an ultrasonic scaler to remove calculus and periodontal tissue remnants then stored in distilled water at room temperature until the scanning date. Only fully developed maxillary first premolars with intact roots were included in the study. Teeth with open apices, root fracture, root resorption or previous root canal treatment were excluded from this study [37].

- Micro-CT scanning

The collected teeth were scanned using a micro-CT system (ZEISS Xradia 520 Versa 3D X-ray microscope, Carl Zeiss, Germany, Department of Geology, Faculty of Science, Universiti Malaya) with a voxel size of 25.1 μm, at 80 kV, 88 μA, source- rotation axis (RA) distance 56.1 mm, detector-RA distance 93.5 mm, with a degree of rotation of 360° and 0.4° step. Every three teeth were included together in one scan with their longitudinal axis fixed perpendicular to the frame using modelling wax [37]. The acquired Two-dimension (2D) images were converted to DICOM format and utilized by the MIMICS software (MIMICS research 21, Materialise, Leuven, Belgium) for segmentation, Three-dimensional (3D) reconstruction and qualitative and quantitative evaluations [37].

- Investigating the Apical Anatomy

The apical part of each canal, specifically 2 mm from the major apical foramen (MAF) was evaluated to determine the location of the Apical Constriction (AC) using the centerline algorithm in the Mimics software. Initially, and after centerline fitting, the canal's cross-sectional areas were traced to determine the apical sections having the smallest sectional area. Subsequently, the circumference of these sections was checked to determine the sections with the smallest circumference, as illustrated in Fig. 1a. This process ensured that the sections with the smallest cross-sectional area and the smallest circumference were selected to represent the AC. Then, the most coronal section of AC was used as a reference for measuring distances to the MAF and anatomic apex (AA). Using the distance measurement tool in the Mimics software, the following distances were measured for each canal: from AC to MAF, AC to AA and MAF to AA (Fig. 1b).

The root was then sectioned at the level of the coronal extent of AC perpendicular to the long axis of the canal (Fig. 1c) and the shortest and longest canal diameters at the AC were measured using the ellipse measurement tool in the Mimics software (Fig. 1d). The aspect ratio, defined as the ratio of the longest to the shortest canal diameters, was then calculated and used to classify the geometric cross-sectional shape of the root canals at the AC. The canals were categorized as: round-shaped when the aspect ratio is 1, oval-shaped canal when the aspect ratio is between 1 and 2, long oval canal when the aspect ratio is between 2 and 4, and flattened canal when the aspect ratio is higher than 4 [43] (Fig. 2). Additionally, the direction of the MAF opening was determined for each canal and recorded as either centrally located or deviated to one of the root sides. A conceptual flowchart illustrating the methodology employed in the current study is presented in Fig. 3.

One observer conducted two sessions of observation, one month apart, after receiving a calibration session that involved examining 20 samples with a specialist endodontist who is an expert in using the Mimics software. Cohen's kappa coefficient was used for evaluating the intra- and inter-observer reliability.

- Statistical analysis

The data was analysed using the SPSS software version 26 (IBM SPSS Statistics, Armonk, NY, USA). The Independent-Samples T-test was used to test the differences between the buccal and palatal canals in double-rooted teeth and between the buccal and palatal canals in single with those in the double-rooted teeth regarding the canal diameters and AC-MAF, AC-AA and MAF-AA distances, and the Mann-Whitney test was used for the non-normally distributed data. One-way ANOVA test with Bonferroni post hoc test was used to test the differences in the canal diameters and AC-MAF, AC-AA and MAF-AA distances within the buccal, palatal and single canals in single-rooted teeth, and the Independent-Samples Kruskal-Wallis test was used for the non-normally distributed data. The 95% confidence interval of the mean difference was calculated as required. The Levene's test was used for normality testing. The Chi-square test was used to test the differences in the cross-sectional shape of the canals at AC and the direction of apical foramen across the different canals in maxillary first premolars. The level of significance was set at 0.05 ($P = 0.05$).

Results

A total of 151 maxillary first premolar teeth were examined in this study; 82 (54.3%) had two roots and 69 (45.7%) were single-rooted. Almost perfect agreement was shown by the overall Cohen's kappa coefficient values for inter-examiner and intra-examiner reliability, which were 0.814 and 0.926, respectively.

The mean distances from AC to MAF, AC to AA and MAF to AA were 0.49 mm ± 0.32 mm (95% CI: 0.45–0.52), 1.13 mm ± 0.56 mm (95% CI: 1.07–1.20) and 0.74 mm ± 0.49 mm (95% CI: 0.69–0.80), respectively (Table 1). Detailed results for these distances in the different canals of double and single-rooted teeth are presented in Tables 2 and 3, respectively. Statistically, there were no significant differences between the buccal and palatal canals in the double-rooted teeth ($P > 0.05$). In single-rooted teeth, the AC to MAF distance was significantly larger in the palatal canals compared to the single canals ($P < 0.05$), but not significant when compared to the buccal canals ($P > 0.05$). The AC to AA and MAF to AA distances were significantly larger in the palatal canals compared to both the buccal and single canals ($P < 0.05$) (Table 3).

Table 1
Descriptive statistics of apical foramens parameters of maxillary 1st premolars

Apical anatomy parameters	Min.	Max.	Median	Mean	Std. Deviation	95% Confidence Interval for Mean
AC shortest diameter	0.03	0.42	0.17	0.18	0.06	0.45–0.52
AC longest diameter	0.05	0.70	0.23	0.25	0.10	1.07–1.20
Distance of AC - MAF	0.00	1.83	0.39	0.49	0.32	0.69–0.80
Distance of AC -AA	0.19	3.39	1.01	1.13	0.56	0.17–0.18
Distance of MAF - AA	0.07	3.08	0.64	0.74	0.49	0.24–0.26

- (AC: Apical Constriction, MAF: Major Apical Foramen, AA: Anatomic Apex).

Table 2
Comparing means of apical foramens parameters between buccal and palatal canals in double rooted maxillary 1st premolars

Apical anatomy parameters	canal	N	Median	Mean	Std. Dev.	*P.* values [95% Confidence Interval of the Difference]
AC shortest diameter	Buccal	78	0.16	0.17	0.06	0.002[a] [-0.05, -0.01]
	Palatal	78	0.19	0.19	0.05	
AC longest diameter	Buccal	78	0.22	0.23	0.10	0.026[b] [-0.05, 0.01]
	Palatal	78	0.23	0.25	0.07	
Distance of AC-MAF	Buccal	78	0.49	0.56	0.37	0.574[a] [-0.14, 0.77]
	Palatal	78	0.53	0.59	0.32	
Distance of AC-AA	Buccal	78	0.99	1.11	0.55	0.845[a] [-0.14, 0.17]
	Palatal	78	1.02	1.09	0.45	
Distance of MAF-AA	Buccal	78	0.56	0.65	0.40	0.409[a] [-0.07, 0.17]
	Palatal	78	0.49	0.60	0.35	

[a]Independent-Samples T-test

[b]Mann-Whitney Test

-The level of significance was set at 0.05.

- (AC: Apical Constriction, MAF: Major Apical Foramen, AA: Anatomic Apex).

Table 3
Comparing means of apical foramens parameters between the different canals of single rooted maxillary 1st premolars

Apical anatomy parameters	Canal	N	Median	Mean	Std. Dev.	*P.* values [95% Confidence Interval of the Difference]
AC shortest diameter	Buccal	46	0.14	0.15	0.06	B vs. P = .030[a] [-0.07, -0.003]
	Palatal	46	0.18	0.18	0.06	B vs. S = .001[a] [-0.11, 0.02]
	Single	17	0.20	0.21	0.07	P vs. S = .292[a] [-0.07, 0.01]
	Total	109	0.16	0.17	0.07	
AC longest diameter	Buccal	46	0.21	0.22	0.08	B vs. P = .034[b] [-0.11, -0.001]
	Palatal	46	0.27	0.27	0.11	B vs. S < 0.001[b] [-0.21, -0.07]
	Single	17	0.33	0.36	0.15	P vs. S = .111[b] [-0.16, -0.02]
	Total	109	0.25	0.26	0.11	
Distance of AC - MAF	Buccal	46	0.30	0.35	0.30	B vs. P = .075[a] [-0.26, 0.01]
	Palatal	46	0.44	0.48	0.26	B vs. S = .887[a] [-0.10, 0.26]
	Single	17	0.26	0.28	0.13	P vs. S = .023[a] [0.021, 0.38]
	Total	109	0.33	0.39	0.27	
Distance of AC - AA	Buccal	46	0.89	0.91	0.42	B vs. P = 0.001[b] [-0.64, -0.16]
	Palatal	46	1.24	1.31	0.57	B vs. S = 1[b] [-0.25, 0.41]
	Single	17	0.86	0.83	0.31	P vs. S = .004[b] [0.15, 0.81]
	Total	109	0.98	1.06	0.52	
Distance of MAF - AA	Buccal	46	0.59	0.63	0.31	B vs. P = .002[b] [-0.53, -0.12]
	Palatal	46	0.86	0.95	0.50	B vs. S = 1[b] [-0.27, 0.29]
	Single	17	0.53	0.61	0.33	P vs. S = .027[b] [0.06, 0.61]
	Total	109	0.71	0.76	0.43	

[a]Bonferroni Post Hoc Test

[b]Independent-Samples Kruskal-Wallis Test

-The level of significance was set at 0.05.

- (AC: Apical Constriction, MAF: Major Apical Foramen, AA: Anatomic Apex).

The mean shortest and longest canal diameters at the apical constriction for all canals were 0.18 mm ± 0.06 mm (95% CI: 0.17–0.18) and 0.25 mm ± 0.1 mm (95% CI: 0.24–0.26), respectively (Table 1). In the double-rooted teeth, both diameters were significantly greater in the palatal canals compared with the buccal canals ($P < 0.05$) (Table 2). In single-rooted teeth, the two diameters were significantly smaller in the buccal canals compared to the palatal and single canals ($P < 0.05$), and there was no significant difference in AC diameters between the palatal and single canals ($P > 0.05$) (Table 3).

Regarding the cross-sectional shape of the root canals at the AC, the majority of the canals (89.8%) were oval-shaped at the AC and only 1.4% of the root canals had round cross-sectional shapes at AC. The Chi-square test showed no significant difference in the canals' cross-sectional shape in the different root canal types of maxillary first premolars ($P > 0.05$). However, the single canals showed a higher prevalence of long-oval and flattened canals compared to buccal and palatal canals (Table 4).

Table 4
Root canal cross-sectional shapes at the AC in the different canals of maxillary first premolars.

			Cross-sectional shape				Total
			Flattened	Long_Oval	Oval	Round	
Canal	Buccal	Count	1	10	113	1	125
		% within canal	0.8%	8.0%	90.4%	0.8%	100.0%
	Disto-Buccal	Count	0	1	7	1	9
		% within canal	0.0%	11.1%	77.8%	11.1%	100.0%
	Mesio-Buccal	Count	0	2	7	0	9
		% within canal	0.0%	22.2%	77.8%	0.0%	100.0%
	Palatal	Count	0	8	125	2	135
		% within canal	0.0%	5.9%	92.6%	1.5%	100.0%
	Single	Count	1	3	13	0	17
		% within canal	5.9%	17.6%	76.5%	0.0%	100.0%
Total		Count	2	24	265	4	295
		% of Total	0.7%	8.1%	89.8%	1.4%	100.0%

Regarding the direction of the MAF, the present data revealed that only 25.8% of the canals had centrally located foramina while in 74.2% of the cases, the foramina were deviated to one side of the root, most commonly toward the palatal and distal sides (Table 5). The Chi-square test revealed a significant difference in the direction of the apical foramen between the buccal and palatal canals in the double-rooted teeth ($P < 0.05$). The palatal canals were more likely to have centrally located foramina compared

to the buccal canals. No significant difference was found in the direction of apical foramen between the canals in the single-rooted teeth (P > 0.05).

Table 5
Directions of apical foramina in the different canals of maxillary first premolars.

Canal	Direction of MAF									
	Central	Deviated								Total
B		P	D	DB	DP	M	MB	MP		
Buccal	26	14	21	43	1	2	20	3	3	133
	19.5%	10.5%	15.8%	32.3%	0.8%	1.5%	15.0%	2.3%	2.3%	100%
Disto-Buccal	0	0	1	4	0	0	0	0	0	5
			20%	80%						100%
Mesio-Buccal	2	0	1	0	0	0	2	0	0	5
	40%		20%				40%			100%
Palatal	42	4	46	14	1	4	18	1	5	135
	31.1%	3%	34.1%	10.4%	0.7%	3%	13.3%	0.7%	3.7%	100%
Single	6	1	3	2	0	4	1	0	0	17
	35.3%	5.9%	17.6%	11.8%		23.5%	5.9%			100%
Total	76	19	72	63	2	10	41	4	8	295
	25.8%	6.4%	24.4%	21.4%	0.7%	3.4%	13.9%	1.4%	2.7%	100%
		219 (74.2%)								

- (MAF: Major Apical Foramen, B: Buccal, P: Palatal, D: Distal, DB: Disto-Buccal, DP: Disto-Palatal, M: Mesial, MB: Mesio-Buccal, MP: Mesio-Palatal).

Discussion

Apical constriction is frequently regarded to be the optimal endpoint for root canal treatment procedures, given that there is a natural narrowing of the root canal almost at its terminus. This is supposedly where an apical stop can be established and the root canal filling materials get packed [44, 45, 5].

According to the American Association Glossary of Endodontic Terms (2020), the AC has been defined as the apical portion of the root canal having the narrowest diameter; its position may vary but is usually 0.5–1.0 mm short of the centre of the major apical foramen [46]. However, it does not clarify whether the narrowest diameter should be measured from the long or short axis of the canal to determine the AC since the root canal cross-sectional shape is not round most of the time to have only one diameter and it

has been reported that the root canal cross-sectional shape in the apical thirds of maxillary first premolars is mainly oval and long oval [47]. This definition may be based on the traditional studies of apical anatomy that identified the AC by evaluating the longitudinal root canal sections that reveal only one canal diameter, which can be the buccolingual or the mesiodistal diameter [4, 44]. It has been shown that the longitudinal sections yield different forms and locations of the constriction in the same canal and therefore provide inconsistent results compared to cross-sectional analysis [48]. This suggests that a more reliable method for determining the AC involves cross-sectional analysis that accounts for both long and short canal diameters, as well as the overall sectional area and circumference. This approach provides a more accurate and comprehensive understanding of the canal morphology at the AC, which is critical for effective cleaning, shaping, and obturation in root canal therapy.

ElAyouti et al. [49] and Chang et al. [8] located the AC by comparing cross-sectional areas along the path of the canal and considering the apical cross sections having the smallest area as the narrowest part of the canal or the constriction. However, their methods diverged in terms of measurement of reference point: ElAyouti et al (2014) [49] used the most apical section of the constriction as a reference for distance measurements, while Chang et al (2022) [8] used the coronal extent of the AC to measure the distance to the MAF. On the other hand, Piasecki et al. [50] used a different approach by measuring the canal's perimeter or circumference to detect the AC using the most coronal slice as a reference for its location. Given these varying methodologies and to improve accuracy, the authors considered both the sectional area and circumference to determine the AC. The coronal section of AC was used as a reference for measuring distances to the MAF and to the AA so as not to violate the narrowest part of the canal since the rationale for using AC as the endpoint for intra-canal procedures is to preserve the narrowest zone of the canal which facilitate creating an apical stop to avoid overfilling and minimizing irritation and wound area of the periapical tissues.

The current investigation revealed that the AC is located at variable distances from the MAF (Fig. 4), with a mean distance measured at 0.49 mm, which is found to be in agreement with the results reported by Dummer et al. [44] in maxillary premolars which was 0.53 mm, and with the results reported by Kuttler [4] in the young age group which was about 0.52 mm without specifying the teeth type. However, the AC-MAF distance recorded in this study was greater than that reported by ElAyouti et al. [49] in which the measured AC-MAF distance was reported to be 0.2 mm in their micro-CT study. This discrepancy may be attributed to the different types of teeth used (maxillary first premolars vs. maxillary and mandibular molars), as well as to the different reference points used for measuring distances since ElAyouti et al. [49] used the apical extent of AC while the coronal AC extent was used in this study.

The mean distance from the AC to AA measured in the current investigation was 1.13 mm. These results were consistent with those reported by Shimizu et al. [51] in a study of maxillary first premolars from Japanese patients. A slightly shorter AC-AA distance of maxillary premolars was reported by Dummer et al. [44] with an average of 0.95 mm. Nevertheless, a consensus can be observed in the findings of different anatomic studies regarding the mean AC-AA distance to be fluctuating around 1 mm [49, 52, 53, 32], which is in accordance with the results recorded in this study.

The mean distance of MAF to AA measured in the current investigation was 0.74 mm, and this is in agreement with the findings of several studies [54, 35, 49]. For instance, Martos et al. [54] reported that the mean MAF-AA distance in maxillary premolars was 0.67 mm, however, they measured the distance from the AA to the most apical point of the MAF not to the centre of MAF as was the case in this study. Morfis et al. [35] reported that the mean distance from AA to the centre of MAF was about 0.82 mm in maxillary premolars. A mean MAF-AA distance of 0.7 mm has been reported by ElAyouti et al. [49] in a study of ninety human maxillary and mandibular molars. However, a shorter MAF to AA distance of about 0.48 mm in young patients and about 0.6 mm in older patients had been reported by Kuttler [4] and a mean MAF-AA distance of about 0.42 mm had been reported by Dummer et al. [44]. These minor differences can be partially attributed to the various approaches employed in measuring the distances as well as the likely usage of varying reference points [11]. Additionally, it has been reported that racial differences between populations may contribute to these discrepancies [55].

The current investigation revealed that in single-rooted teeth, the AC to MAF distance was significantly larger in the palatal canals compared to the single canals ($P = 0.023$), but not significant when compared to the buccal canals ($P > 0.05$). However, the AC to AA and MAF to AA distances were significantly larger in the palatal canals compared to both the buccal ($P = 0.001$ and 0.002, respectively) and single canals ($P = 0.004$ and 0.027). However, there were no previous articles in the literature that reported similar results for maxillary premolars to compare our results with.

Knowing the probable diameters of the apical constriction or the minor apical foramen can help practitioners in getting a proper apical preparation which should be performed while avoiding excessive enlargement to the constriction [56, 57]. The results of the current investigation revealed that the mean shortest or minimum diameter of the constriction was 0.18 mm and the mean longest or maximum diameter was 0.25 mm. These findings were lower than those reported by Shimizu et al. [51] and by Abarca et al. [1], while in agreement with the findings of other studies [58, 59, 53]. The most common canal cross-sectional shape at the AC was oval (89.8%), and this is in agreement with several studies [58, 1, 59]. This information can help in the decision-making process regarding the initial and final apical file size [60]. Before root canal enlargement, the initial apical file size can be estimated based on the AC minimum diameter. Since the majority of canals have an oval cross-section, the final file size should be large enough to touch every canal wall during the preparation procedures. Put another way, the size of the master apical file, which is the largest endodontic file used to the full working length, should match the longest diameter of AC to shape the canal round [58]. The results of the current investigation revealed that the difference between the longest and shortest canal diameters was equal to or less than 0.15 mm in about 90% of the canals and was equal to or less than 0.20 mm in about 95% of the examined canals. According to these data, preparing the canals to 3 and 4 instrument sizes larger than the initial apical file size will turn the apical constriction into a round shape in 90% and 95% of the cases, respectively.

When the MAF is not located at the anatomical root apex tip, it is referred to as a foramen deviation, which can be resulted from both pathological and physiological conditions [52]. The frequency of

deviated MAF in the current investigation was 74.2%; mostly to the palatal and distal sides. These results were in close agreement with those reported by Blasković-Subat et al. [52] and Sert, Bayirli [61]. Higher frequencies of deviated MAF had been reported by Algailani et al. [6] (85%), Vertucci, Gegauff [20] (88%) and by Burch, Hulen [11] (92.4%). However, lower frequencies of about 40% and 15% also had been reported by Awawdeh et al. [22] and Senan et al. [23], respectively. These discrepancies between the various studies could be the consequence of using various definitions and methodologies, as well as the different population groups that each study examined [22, 52]. The discrepancies in different reported data about the position of apical foramina may also be attributed to patient age and sample size [22]. Kuttler [4] reported that the percentage of deviated foramina in older age patients (55 years and older) was 80%, whereas the percentage in younger age patients (18–25 years) was 68%. According to Stein, Corcoran [62], there is a positive correlation between age and the deviation and diameter of the foramen opening as a result of apical cementum thickening. The results of our study, as well as those of previous studies, have revealed that the frequency of deviated MAF opening is high. This is not usually detectable on radiographic examination, especially when this deviation occurs toward the buccal or palatal root surface (Fig. 5). For this reason and in order to prevent periodontal ligament damage, clinicians should consider this when performing root canal therapy. Root canal working length is better determined by the use of the electronic foramen locaters in combination with tactile and radiographic evaluation.

The majority of contemporary electronic foramen locators can record the location where the periodontal ligament tissues commence outside the root canal. It is recommended to subtract 0.5 to 1 mm from the file length when the device indicates that the tip of the file is touching the periodontal ligament (zero reading) [63]. This does not imply that the constriction is identified; rather, it indicates that the instrument is positioned within the canal and in proximity to the periodontal ligament. It is not advisable to rely on the 0.5 to 1 mm short readings of any device, as this is likely to be inaccurate [63]. However, in cases of infected necrotic pulps and periapical disease, the cemental canal after the minor foramen may become infected and serve as a reservoir for pathogens, particularly anaerobic bacteria. Consequently, a limited degree of instrumentation beyond the minor foramen has been recommended to cleanse the cemental canal [63].

This study is among the few that have utilized the innovative micro-CT technology to investigate the apical anatomy of maxillary first premolars and the first to be held in the Iraqi population, although, this kind of teeth was reported to possess one of the most complex and variable root canal apical anatomy [35, 5]. Clinicians should benefit from knowing the anticipated location and diameters of the apical constriction in order to achieve an appropriate apical disinfection, which should be carried out without excessively enlarging this constriction. Such information would significantly contribute to the build-up of knowledge regarding this challenging part of the root canal system anatomy [1, 32]. However, the cost and technical limitations of the micro-CT technology were the main challenge for the sample size of the study, and there is a possibility that such limited sample size might not accurately represent the population in general. Micro-CT is an expensive and time- consuming diagnostic tool whose use requires a well-trained operator to acquire the images which also require well- organized, large data storage systems [33]. In addition, the micro-CT imaging cannot be used for living patients and the patients' ages

and the apical pathologic conditions of the collected teeth were unknown, and these may affect the location and size of the apical foramina. Furthermore, there is a potential risk of sample bias since a significant proportion of maxillary first premolars were extracted for orthodontic reasons, and this limits the selected sample age to teenagers and young adults. Therefore, conducting future studies taking into account the age and the pathologic history of the collected teeth would be valuable in providing a more comprehensive understanding of the apical anatomy.

Conclusion

This study revealed that the apical anatomy of maxillary first premolars is variable in the studied Iraqi population and the AC is located at variable distances from the MAF with an average distance of about 0.5 mm. The cross-sectional shape of the root canal is predominantly oval. The MAFs deviated in 74.2% of examined root canals mostly to the palatal and distal side, which underscore the importance of using the apical foramen locaters for determining the working length.

Declarations

Conflict of Interest

The authors declare that they have no conflict of interest.

Ethical approval

Ethical approval was waived by the Scientific Committee of College of Dentistry, University of Basrah (no. 7/54/1706) and by the Medical Ethics Committee of Faculty of Dentistry, UNIVERSITI MALAYA (no. DF RD2207/0033 (L)). The study was performed in accordance with the ethical standards as laid down in the 1964 Declaration of Helsinki

Funding

This study was financially supported by UNIVERSITI MALAYA DPRG grant no. UMG002E-2022.

Author Contribution

A.M.A.: design, data analysis & interpretation, writing and revision. N.H.A.: design, data analysis & interpretation writing and revision. H.M.A.A.: design, data analysis & interpretation writing and revision. N.I.: design, data analysis & interpretation and revision. A.A.A.: design, data analysis & interpretation and revision.

Acknowledgement

The authors would like to acknowledge Dr. Hijaz Kamal Hasnan, Department of Geology, Faculty of Science, University of Malaya, Malaysia for his efforts in sample scanning.

Data Availability

The datasets generated during and/or analysed during the current study are available from the corresponding author on reasonable request.

References

1. Abarca J, Zaror C, Contreras W, Jadue S, Olguin C, Steinfort K et al (2018) Morphology of the Physiological Apical Foramen of Maxillary Premolars. Int J Morphology. ;36(1)
2. Hess W (1917) Zur Anatomie der Wurzelkanäle des menschlichen Gebisses mit Berücksichtigung der feineren Verzweigungen am Foramen apicale. Berichthaus
3. Preiswerk G (1903) Lehrbuch und Atlas der Zahnheilkunde mit Einschluss der Mundkrankheiten. Lehmann
4. Kuttler Y (1955) Microscopic investigation of root apexes. J Am Dent Association 50(5):544–552
5. Vertucci FJ (2005) Root canal morphology and its relationship to endodontic procedures. Endodontic Top 10(1):3–29
6. Algailani UF, Khudid AR, Talabani RM, Saeed HMM, Dlshad D, Nawzad S et al (2025) Anatomical evaluation of the major apical foramen of extracted maxillary and mandibular human teeth in an Iraqi subpopulation: a cross-sectional study. Sci Rep 15(1):24747. 10.1038/s41598-025-09382-4
7. Wolf TG, Basmaci S, Weiberlenn SM, Donnermeyer D, Waber AL (2025) Morphology of the Physiological Foramen: A Systematic Review. Dentistry J 13(12):581
8. Chang JW, Manigandan K, Samaranayake L, NandhaKumar C, AdhityaVasun P, Diji J et al (2022) Morphotypes of the apical constriction of maxillary molars: a micro-computed tomographic evaluation. Restor Dent Endod 47(2):e19. 10.5395/rde.2022.47.e19
9. Stanev E, Yantcheva S (2024) Size of apical constriction in different types of permanent teeth. J IMAB 30(4):4
10. Ricucci D, Langeland K (1998) Apical limit of root canal instrumentation and obturation, part 2. A histological study. Int Endod J 31(6):394–409
11. Burch JG, Hulen S (1972) The relationship of the apical foramen to the anatomic apex of the tooth root. Oral Surgery, Oral Medicine. Oral Pathol 34(2):262–268
12. Vertucci FJ (1984) Root canal anatomy of the human permanent teeth. Oral surgery, oral medicine. oral Pathol 58(5):589–599

13. Green D (1973) Double canals in single roots. Oral Surgery, Oral Medicine. Oral Pathol 35(5):689–696
14. Pineda F, Kuttler Y (1972) Mesiodistal and buccolingual roentgenographic investigation of 7,275 root canals. Oral Surgery, Oral Medicine. Oral Pathol 33(1):101–110
15. Mizutani T, Ohno N, Nakamura H (1992) Anatomical study of the root apex in the maxillary anterior teeth. J Endod 18(7):344–347
16. Zaatar EI, al-Kandari AM, Alhomaidah S, al-Yasin IM (1997) Frequency of endodontic treatment in Kuwait: radiographic evaluation of 846 endodontically treated teeth. J Endod 23(7):453–456. 10.1016/s0099-2399(97)80302-0
17. Scavo R, Martinez Lalis R, Zmener O, Dipietro S, Grana D, Pameijer CH (2011) Frequency and distribution of teeth requiring endodontic therapy in an Argentine population attending a specialty clinic in endodontics. Int Dent J 61(5):257–260. 10.1111/j.1875-595X.2011.00069.x
18. Khan SQ, Khabeer A, Al Harbi F, Arrejaie AS, Moheet IA, Farooqi FA et al (2017) Frequency of Root Canal Treatment among Patients Attending a Teaching Dental Hospital in Dammam, Saudi Arabia. Saudi J Med Med Sci 5(2):145–148. 10.4103/1658-631x.204860
19. Wolf TG, Kozaczek C, Siegrist M, Betthäuser M, Paqué F, Briseño-Marroquín B (2020) An ex vivo study of root canal system configuration and morphology of 115 maxillary first premolars. J Endod 46(6):794–800
20. Vertucci FJ, Gegauff A (1939) Root canal morphology of the maxillary first premolar. Journal of the American Dental Association 1979;99(2):194-8
21. Alenezi MA, Al-Nazhan SA, Al-Omari MA (2022) Three-dimensional evaluation of root canal morphology of maxillary first premolars: Micro–computed tomographic study. Saudi Dent J 34(7):611–616
22. Awawdeh L, Abdullah H, Al-Qudah A (2008) Root form and canal morphology of Jordanian maxillary first premolars. J Endod 34(8):956–961
23. Senan EM, Alhadainy HA, Genaid TM, Madfa AA (2018) Root form and canal morphology of maxillary first premolars of a Yemeni population. BMC Oral Health 18(1):1–10
24. Gulabivala K, Ng Y (2014) Tooth organogenesis, morphology and physiology. Endodontics. Elsevier, pp 2–32
25. Ahmed H, Abbott P (2012) Accessory roots in maxillary molar teeth: a review and endodontic considerations. Aust Dent J 57(2):123–131. https://doi.org/10.1111/j.1834-7819.2012.01678.x
26. Martins JNR, Versiani MA (2024) Worldwide Assessment of the Root and Root Canal Characteristics of Maxillary Premolars - A Multi-center Cone-beam Computed Tomography Cross-sectional Study With Meta-analysis. J Endod 50(1):31–54. 10.1016/j.joen.2023.10.009
27. Ahmad IA, Alenezi MA (2016) Root and root canal morphology of maxillary first premolars: a literature review and clinical considerations. J Endod 42(6):861–872

28. Dogan S, Gurkan C, Dogan M, Balkaya HE, Tunc R, Demirdov DK et al (2017) A glimpse at the intricate mosaic of ethnicities from Mesopotamia: Paternal lineages of the Northern Iraqi Arabs, Kurds, Syriacs, Turkmens and Yazidis. PLoS ONE 12(11):e0187408. 10.1371/journal.pone.0187408
29. Ulack C (2015) Demography of Race and Ethnicity in Iraq. The International Handbook of the Demography of Race and Ethnicity. :367 – 84
30. Ali, HAh, DISTRIBUTION OF HLA POLYMORPHISM IN A SAMPLE OF IRAQI ARABS IN COMPARISON WITH THREE ARAB GULF POPULATIONS Iraqi (2009) J Sci 50(1):120–125
31. Filpo-Perez C, Bramante CM, Villas-Boas MH, Duarte MAH, Versiani MA, Ordinola-Zapata R (2015) Micro–computed tomographic analysis of the root canal morphology of the distal root of mandibular first molar. J Endod 41(2):231–236
32. Wolf TG, Paqué F, Sven Patyna M, Willershausen B, Briseño-Marroquín B (2017) Three-dimensional analysis of the physiological foramen geometry of maxillary and mandibular molars by means of micro-CT. Int J Oral Sci 9(3):151–157. 10.1038/ijos.2017.29
33. Ahmed HMA (2022) A critical analysis of laboratory and clinical research methods to study root and canal anatomy. Int Endod J 55:229–280
34. Lee K-W, Kim Y, Perinpanayagam H, Lee J-K, Yoo Y-J, Lim S-M et al (2014) Comparison of alternative image reformatting techniques in micro–computed tomography and tooth clearing for detailed canal morphology. J Endod 40(3):417–422
35. Morfis A, Sylaras S, Georgopoulou M, Kernani M, Prountzos F (1994) Study of the apices of human permanent teeth with the use of a scanning electron microscope. Oral surgery, oral medicine. oral Pathol 77(2):172–176
36. CSO (2021) Estimates of Iraq's Population by Governorates, Environment and Sex. Central statistical organization of Iraq. view=article&layout=edit&id=174&jsn_setmobile=no. https://cosit.gov.iq/ar/?option=com_content&
37. Aljawhar AM, Ibrahim N, Abdul Aziz A, Ahmed HMA, Azami NH (2025) Micro-computed tomographic evaluation of root and canal anatomy of maxillary first premolars in Iraqi sub-population. Sci Rep 15(1):10821. 10.1038/s41598-025-94590-1
38. AL-Rammahi HM, Ahmed HMA, Chai WL (2024) Microcomputed-Tomographic Analysis of the Root Canal Morphology of the Mandibular First Molars in a Malaysian Subpopulation Using Two Classification Systems. Int J Morphology 42:28–34
39. Wolf TG, Kozaczek C, Campus G, Paqué F, Wierichs RJ (2020) Root Canal Morphology of 116 Maxillary Second Premolars by Micro–Computed Tomography in a Mixed Swiss-German Population with Systematic Review. J Endod 46(11):1639–1647
40. Saber SM, Elashiry MM, Sadat SMAE, Nawar NN (2023) A microcomputed tomographic analysis of the morphological variabilities and incidence of extra canals in mandibular first molar teeth in an Egyptian subpopulation. Sci Rep 13(1):8985
41. Elnour M, Khabeer A, AlShwaimi E (2016) Evaluation of root canal morphology of maxillary second premolars in a Saudi Arabian sub-population: An in vitro microcomputed tomography study. Saudi

Dent J 28(4):162–168

42. Liu N, Li X, Liu N, Ye L, An J, Nie X et al (2013) A micro-computed tomography study of the root canal morphology of the mandibular first premolar in a population from southwestern China. Clin Oral Invest 17:999–1007
43. Ordinola-Zapata R, Versiani MA, Bramante CM (2019) Root Canal Components. In: Versiani MA, Basrani B, Sousa-Neto MD (eds) The Root Canal Anatomy in Permanent Dentition. Springer International Publishing, Cham, pp 31–46
44. Dummer PM, Mcginn JH, Rees DG (1984) The position and topography of the apical canal constriction and apical foramen. Int Endod J 17(4):192–198
45. Wu M-K, Wesselink PR, Walton RE (2000) Apical terminus location of root canal treatment procedures. Oral Surgery, Oral Medicine, Oral Pathology. Oral Radiol Endodontology 89(1):99–103
46. AAE (2020) Glossary of Endodontic Terms. Tenth Edition ed. Chicago, IL 60601. American Association of Endodontists
47. Liu X, Gao M, Ruan J, Lu Q (2019) Root canal anatomy of maxillary first premolar by microscopic computed tomography in a Chinese adolescent subpopulation. BioMed Research International. ;2019
48. Schell S, Judenhofer M, Mannheim J, Hülber-J M, Löst C, Pichler B et al (2017) Validity of longitudinal sections for determining the apical constriction. Int Endod J 50(7):706–712
49. ElAyouti A, Hülber-J M, Judenhofer MS, Connert T, Mannheim JG, Löst C et al (2014) Apical constriction: location and dimensions in molars—a micro–computed tomography study. J Endod 40(8):1095–1099
50. Piasecki L, Carneiro E, da Silva Neto UX, Westphalen VPD, Brandão CG, Gambarini G et al (2016) The use of micro–computed tomography to determine the accuracy of 2 electronic apex locators and anatomic variations affecting their precision. J Endod 42(8):1263–1267
51. Shimizu Y, Hara T, Ide Y (2004) A Morphological Study of the Apical Third of the Root Canal in the Maxillary First Premolar using Micro-CT. J Oral Biosci 46(1):1–10. https://doi.org/10.1016/S1349-0079(04)80007-0
52. Blasković-Subat V, Maricić B, Sutalo J (1992) Asymmetry of the root canal foramen. Int Endod J 25(3):158–164. 10.1111/j.1365-2591.1992.tb00779.x
53. Marroquín BB, El-Sayed MA, Willershausen-Zönnchen B (2004) Morphology of the physiological foramen: I. Maxillary and mandibular molars. J Endod 30(5):321–328. 10.1097/00004770-200405000-00005
54. Martos J, Ferrer-Luque C, González-Rodríguez M, Castro L (2009) Topographical evaluation of the major apical foramen in permanent human teeth. Int Endod J 42(4):329–334
55. Saeed MS (2023) Apical foramen position in relation to proximal root surfaces of the premolar teeth in Kurdistan region of Iraq: A retrospective CBCT assessment. Turkish Endodontic J (TEJ) 8(3):116–122

56. Schilder H (1974) Cleaning and shaping the root canal. Dental Clin N Am 18(2):269–296
57. Buchanan L (2000) The standardized-taper root canal preparation–Part 1. Concepts for variably tapered shaping instruments. Int Endod J 33(6):516–529
58. Arora S, Tewari S (2009) The morphology of the apical foramen in posterior teeth in a North Indian population. Int Endod J 42(10):930–939
59. Ayranci LB, Yeter KY, Arslan H, Kseoğlu M (2013) Morphology of apical foramen in permanent molars and premolars in a Turkish population. Acta Odontol Scand 71(5):1043–1049
60. Vanni JR, Santos R, Limongi O, Guerisoli DMZ, Capelli A, Pécora JD (2005) Influence of cervical preflaring on determination of apical file size in maxillary molars: SEM analysis. Braz Dent J 16:181–186
61. Sert S, Bayirli GS (2004) Evaluation of the root canal configurations of the mandibular and maxillary permanent teeth by gender in the Turkish population. J Endod 30(6):391–398. 10.1097/00004770-200406000-00004
62. Stein TJ, Corcoran JF (1990) Anatomy of the root apex and its histologic changes with age. Oral Surg Oral Med Oral Pathol 69(2):238–242. 10.1016/0030-4220(90)90334-o
63. Nekoofar MH (2022) Advances in Working Length Determination. Endodontic Advances and Evidence-Based Clinical Guidelines. pp. 218 – 42

Figures

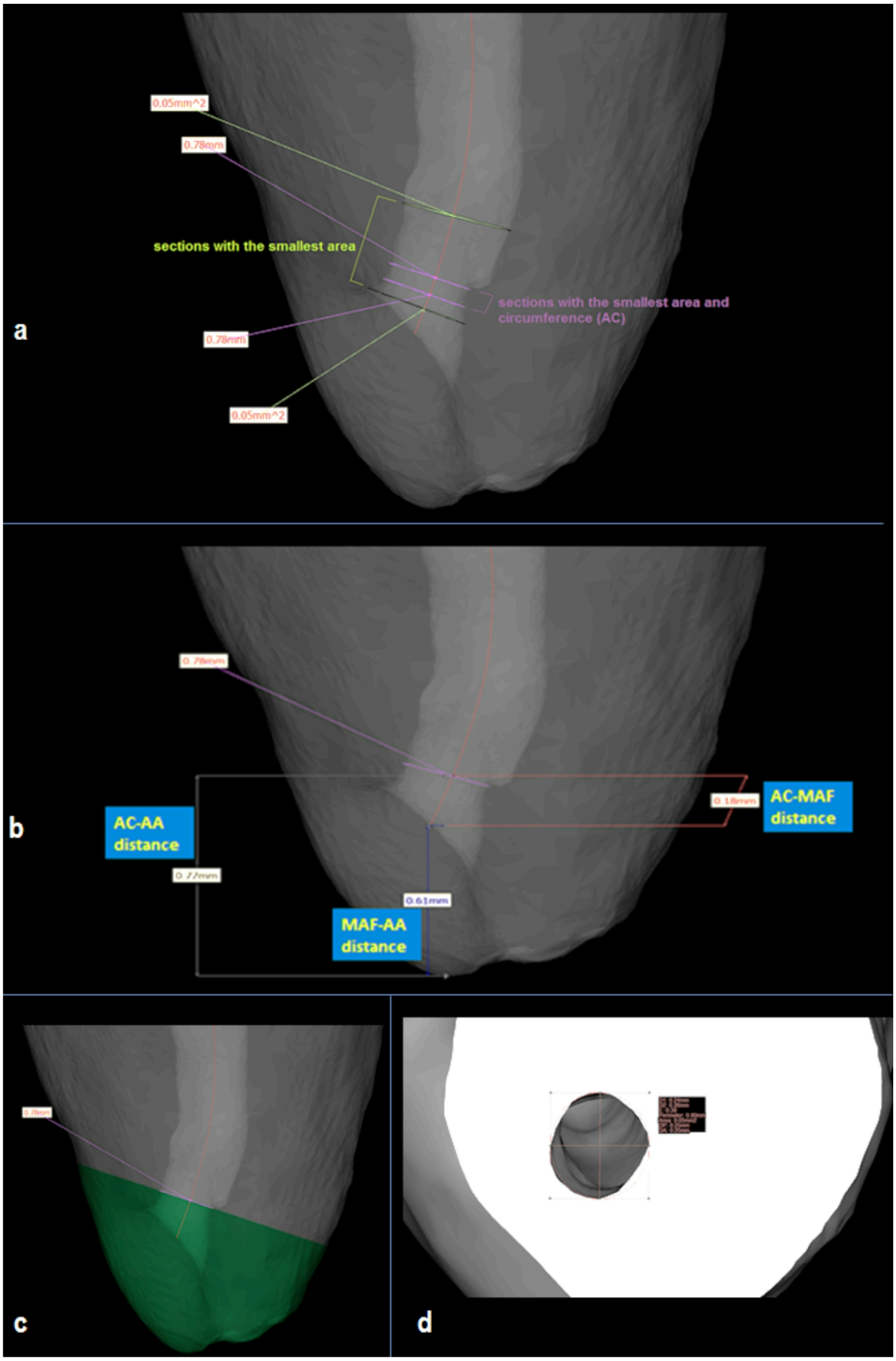

Figure 1

(a) Determining the location of apical constriction, (**b)** Measuring the distances between AC-MAF, AC-AA and MAF-AA, (**c)** Root cutting at the level of the coronal extent of AC perpendicular to the long axis of the canal, (**d)**Measuring the longest and shortest canal diameters at AC.

(AC: Apical Constriction, MAF: Major Apical Foramen, AA: Anatomic Apex).

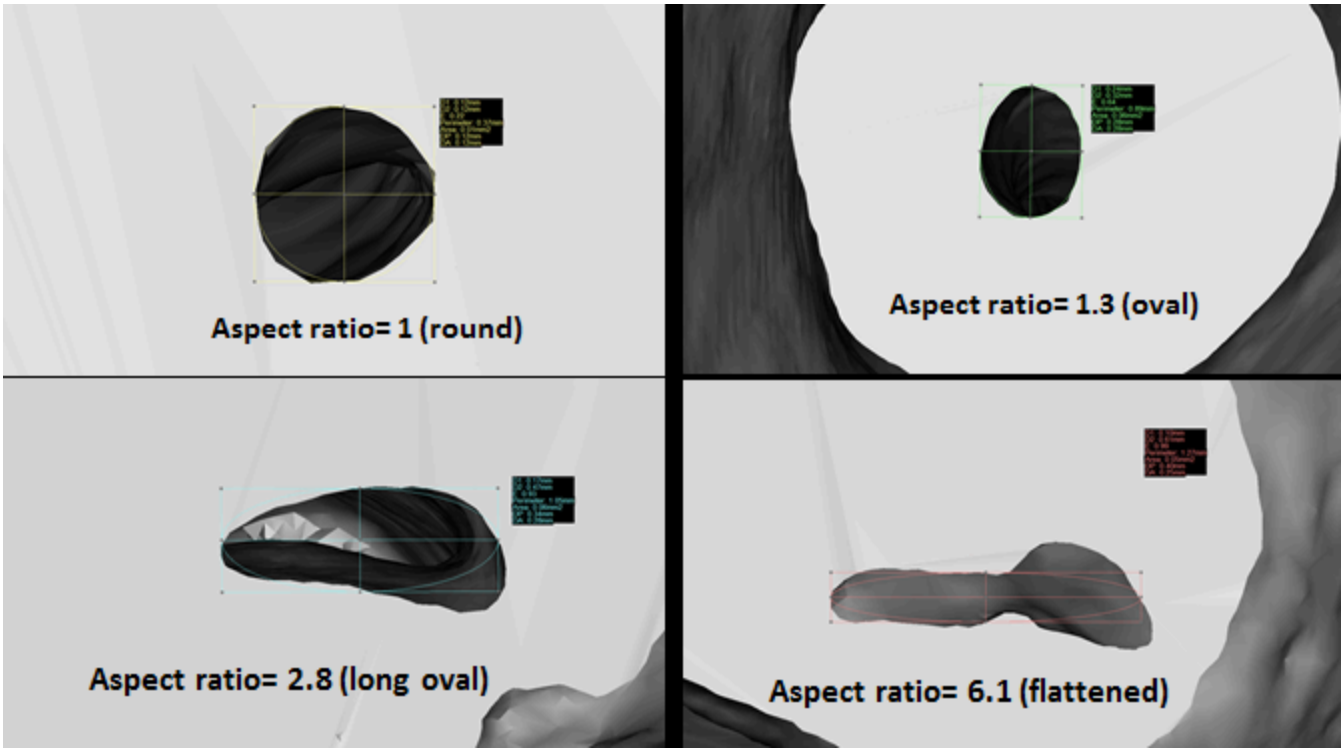

Figure 2

Sample images of root canal cross-sectional shapes at the apical constriction.

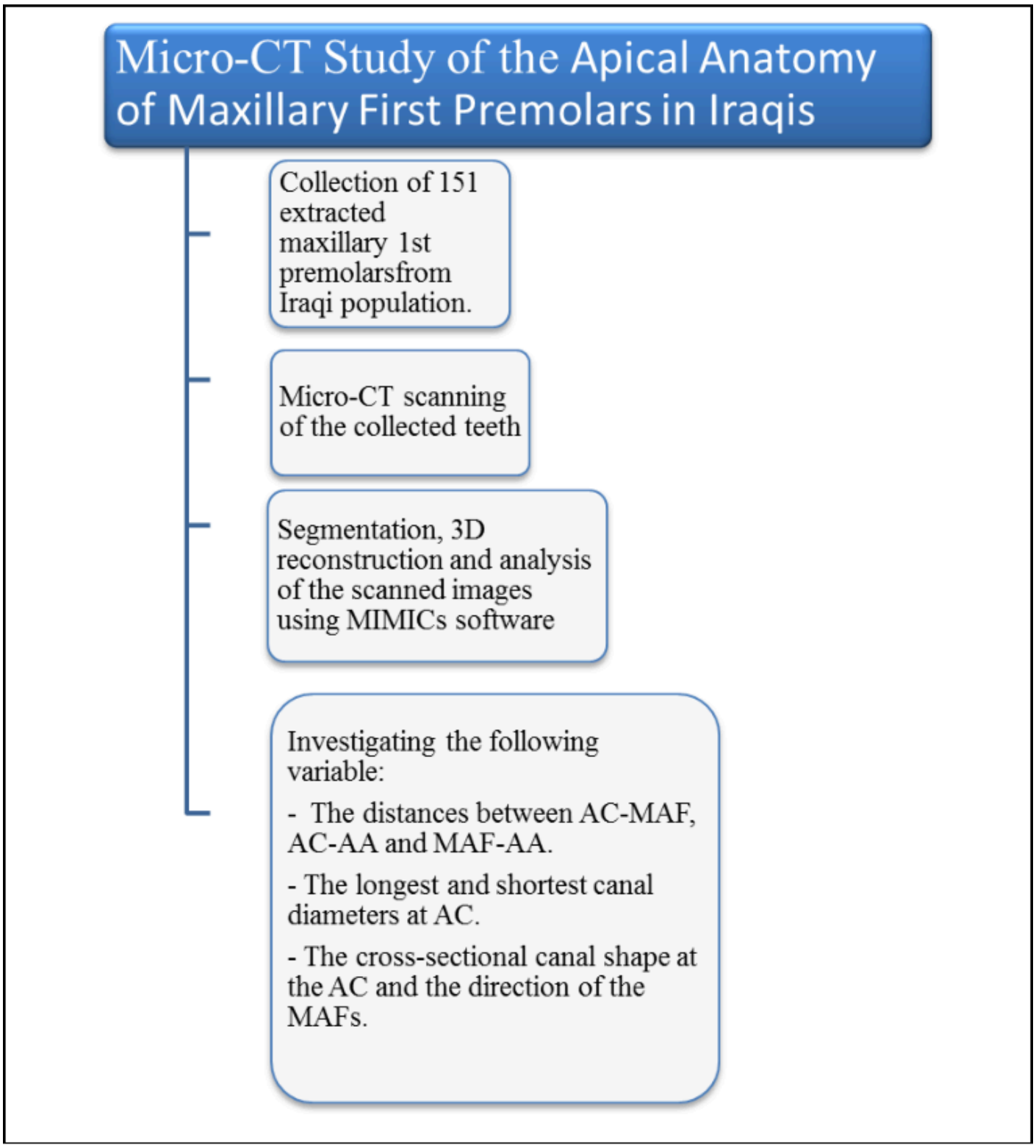

Figure 3

Conceptual flowchart illustrating the methodology employed in the current study.

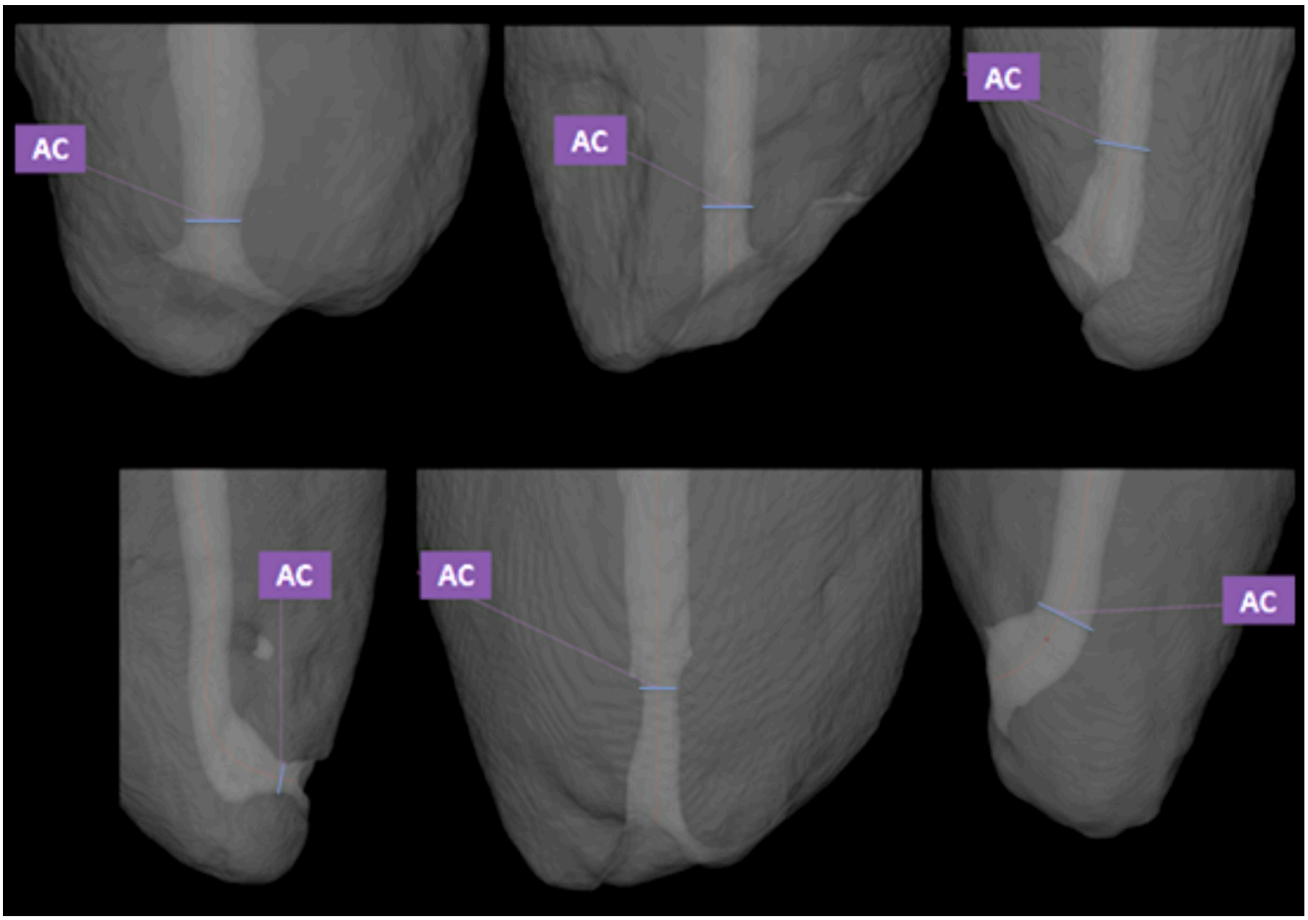

Figure 4

Various locations of AC in the different root canals of maxillary first premolars.

(AC: Apical Constriction).

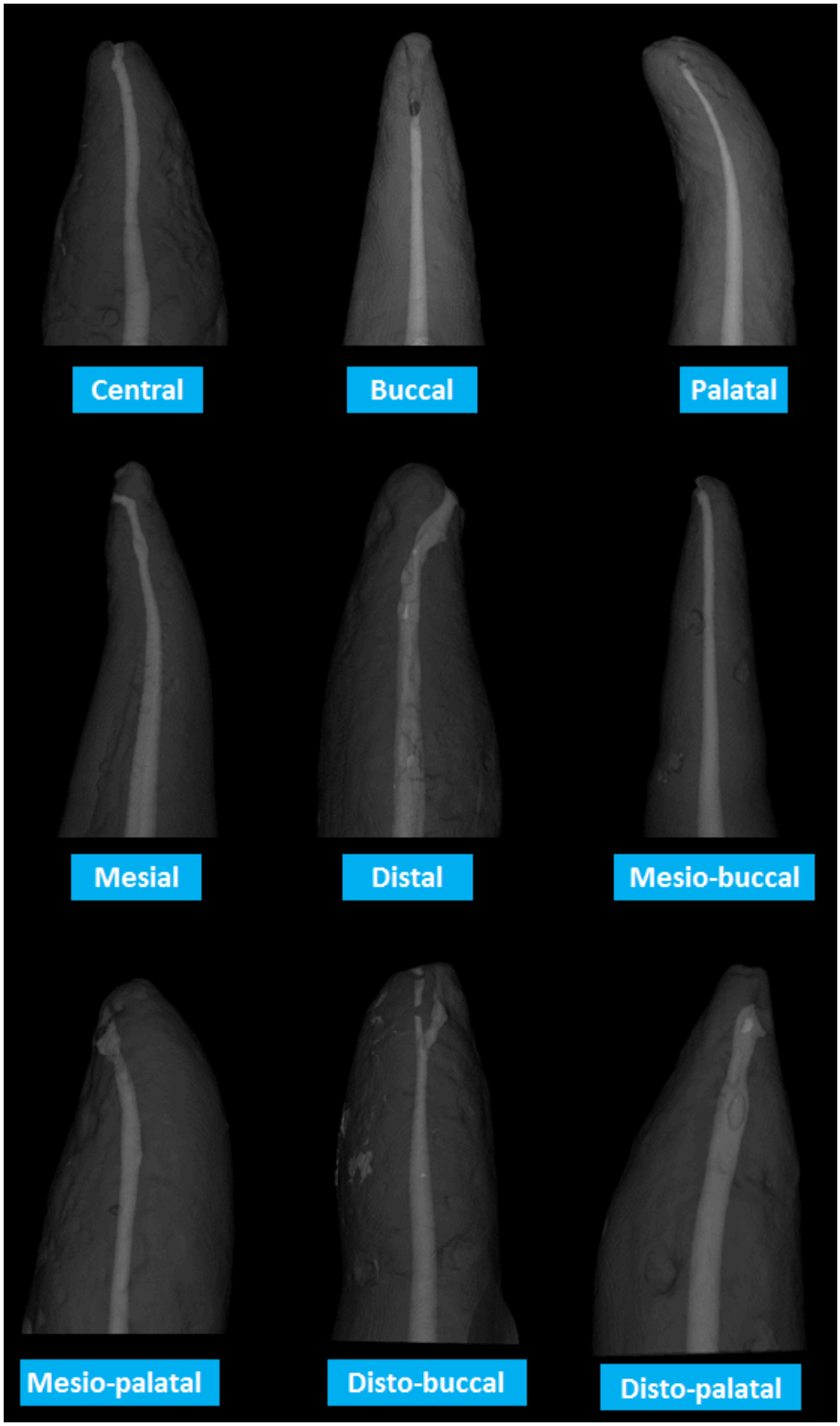

Figure 5

Different directions of the MAF as viewed from the buccal side of the roots.

(MAF: Major Apical Foramen).