Research Square

Preprints are preliminary reports that have not undergone peer review.
They should not be considered conclusive, used to inform clinical practice,
or referenced by the media as validated information.

Lessons learned from two cases of missed imported Plasmodium malariae infection: single and mixed infection

Penglei Zhang
Qingdao Public Health Clinical Center
Xiaoyan Shi
Qingdao Municipal Center for Disease Control and Prevention
Dong Xia
Qingdao Public Health Clinical Center
Lu Guo
Qingdao Public Health Clinical Center
Jing Li
m18563905717_1@163.com
Qingdao Public Health Clinical Center

Case Report

Keywords: Imported malaria, Plasmodium malariae, qPCR, RDT, microscopy, non-endemic area

Posted Date: November 23rd, 2026

DOI: https://doi.org/10.21203/rs.3.rs-11734153/v1

License: This work is licensed under a Creative Commons Attribution 4.0 International License.
Read Full License

Additional Declarations: No competing interests reported.

Title：Lessons learned from two cases of missed imported Plasmodium malariae infection: single and mixed infection

Authors:

Penglei Zhang†

Department of Infectious Diseases, Qingdao Public Health Clinical Center, No. 9 Fushun Road, Qingdao, China

Xiaoyan Shi†

Department of Clinical Laboratory, Qingdao Municipal Center for Disease Control and Prevention, No. 175 Shandong Road, Shibei District, Qingdao, China

Dong Xia

Department of Clinical Laboratory, Qingdao Public Health Clinical Center, No. 9 Fushun Road, Qingdao, China

Lu Guo

Department of Infectious Diseases, Qingdao Public Health Clinical Center, No. 9 Fushun Road, Qingdao, China

Jing Li*

Department of Clinical Laboratory, Qingdao Public Health Clinical Center, No. 9 Fushun Road, Qingdao, China

† These authors contributed equally to this work.

* Correspondence to: Jing Li. Email: m18563905717_1@163.com

In non-malaria endemic regions of China, *Plasmodium malariae* infection is highly susceptible to missed detection. It is typically characterized by low parasitemia, which frequently causes false-negative results in both rapid diagnostic tests (RDTs) and routine blood smear microscopy.

We report two consecutive recent cases of imported *P. malariae*. These are also the only two cases of *P. malariae* that the author has encountered during 15 years of clinical laboratory practice. The first patient returned from Sierra Leone, Africa, and was initially RDT-positive. Microscopy only detected Plasmodium falciparum ring forms, while low-parasitemia *P. malariae* was masked by the dominant strain and consequently missed. Real-time fluorescent quantitative polymerase chain reaction (qPCR) confirmed a dual mixed infection, and careful re-examination of the original smear finally identified mature *P. malariae schizonts*. The second patient returned from Guinea, Africa, presenting with recurrent fever. Both RDT and thick-and-thin smear microscopy yielded negative results, and *P. malariae* infection was ultimately verified by qPCR. Both patients recovered completely after standardized anti-malarial therapy.

These cases indicate that in non-endemic settings, *P. malariae* infection is easily overlooked by conventional detection methods. For febrile patients returning from malaria-endemic regions, nucleic acid testing should be performed to screen for occult, low-density *P. malariae* infection even when RDT and microscopy are negative, effectively reducing missed diagnoses and avoiding delayed anti-malarial treatment.

Keywords: Imported malaria; *Plasmodium malariae*; qPCR; RDT; microscopy; non-endemic area

Introduction

Plasmodium malariae is the causative agent of quartan malaria, widely distributed in Africa, Southeast Asia and South America. Compared with Plasmodium falciparum and *Plasmodium*

vivax, P. malariae infection is frequently overlooked. It is often characterized by low parasitemia with mild early symptoms[1]. The erythrocytic cycle of *P. malariae* lasts 72 hours, and the parasite can asymptomatically persist in the human host for years or even lifelong. Chronic infection without standard treatment may lead to persistent anemia and nephrotic syndrome[2].

China was certified malaria-free by the World Health Organization (WHO) in June 2021, but imported malaria cases still continue to occur. As a coastal port city, Qingdao mainly reports imported infections of *P. falciparum* and *P. vivax*, while *P. malariae* infection is relatively rare[3].

Rapid diagnostic tests (RDTs) and blood smear microscopy are routine screening methods for malaria, but they have limited sensitivity for low-density P*. malariae* infection. In mixed infections, low-abundance *P. malariae* can be masked by hyperproliferative *P. falciparum,* which often leads to missed diagnosis[4]. In non-malaria-endemic countries, clinicians tend to prioritize *P. falciparum* screening for febrile patients returning from endemic areas, making P. malariae infection easily overlooked[5]. Meanwhile, laboratory staff in non-endemic regions lack sufficient experience in identifying *P. malariae*. Once *P. falciparum* is detected via microscopy, comprehensive species screening is often terminated, and this further increases the risk of missed detection of low-density *P. malariae* in mixed infections[6]. In non-endemic areas, malaria nucleic acid testing is mostly available only at reference laboratories, such as centers for disease control and prevention[7].qPCR is not routinely performed for all malaria patients, and nucleic acid testing is generally reserved for specimens with unclear species identification via microscopy. This practice contributes to missed diagnosis of rare *P. malariae* infection.

Here, we report two consecutive cases of imported *P. malariae* detected in Qingdao, both of which escaped identification via conventional malaria diagnostic methods. One case was a

co-infection, in which P. malariae was masked by the presence of *P. falciparum*. The other case was a mono-infection with low-density parasitemia: routine examinations including RDT and light microscopy returned negative results, and the pathogen was only identified via quantitative PCR. These real-world clinical observations demonstrate the diagnostic pitfalls of imported quartan malaria in malaria-free regions and underscore the additional value of molecular assays for febrile patients with epidemiological risk factors, even when standard screening yields negative results[8].

Case presentation

Case 1.

A male patient in his fifties presented with a three-day history of fever after returning from Sierra Leone, West Africa-an endemic area for malaria. The fever occurred without obvious precipitating factors, and the patient's highest body temperature reached 39° C. The patient had a documented episode of malaria approximately one month before this presentation.

On hospital admission, laboratory testing showed a high-sensitivity C-reactive protein concentration of 123 mg per litre,a red blood cell count of 2.40×10^{12} per litre,a haemoglobin concentration of 77 g per litre, and a platelet count of 47×10^{9} per litre.The lymphocyte proportion was 15.8 per cent, the monocyte proportion was 11.8 per cent, and the eosinophil count was 0.01×10^{9} per litre. Serum urea measured 21.55 mmol per litre, serum creatinine was 283.1 μmol per litre, and the estimated glomerular filtration rate was 20.65 mL per minute. Additional laboratory results are summarised in Table 1.

An initial malaria rapid diagnostic test returned a positive result(Figure 1), and microscopic examination of thick-and-thin blood smears also yielded a positive result(Figure 2, Figure 3), with

Plasmodium falciparum provisionally identified. Antimalarial therapy with artesunate was thus initiated.

Three days after admission, repeat microscopic examination of blood smears no longer detected malaria parasites. Artesunate was stopped, and sequential oral treatment with dihydroartemisinin-piperaquine tablets was started. At the same time, quantitative real-time polymerase chain reaction, performed by a municipal Center for Disease Control and Prevention, confirmed an unbalanced mixed infection with *Plasmodium falciparum* and *Plasmodium malariae* (Figure 4).

Retrospective review of the original pre-treatment blood smear identified infrequent, characteristic mature schizonts of *Plasmodium malariae* (Figure 5). This finding indicated that low-density *P. malariae* parasites had been obscured by the predominating *P. falciparum* population, resulting in the initial failure to recognise the co-infection by light microscopy.

Item	Result	Reference range
High-sensitivity C-Reactive protein （CRP）	123.0 mg/L	0-10 mg/L
Red blood cell count (RBC)	2.40×10^{12}/L	$4.0\text{-}5.5\times10^{12}$/L
Hemoglobin (HGB)	77.00 g/L	120-160 g/L
Hematocrit (HCT)	22.10%	40-54%
Platelet count (PLT)	47.00×10^{9}/L	$100\text{-}300\times10^{9}$/L
Lymphocyte percentage (LYM%)	15.80%	20-40%
Monocyte percentage (MONO%)	11.80%	3-8%
Eosinophil count	0.01×10^{9}/L	$0.05\text{-}0.5\times10^{9}$/L
Erythrocyte sedimentation rate (ESR)	81 mm/H	0 – 15 mm/H

Procalcitonin (PCT)	12.81 ng/mL	≤0.05 ng/mL
Ferritin (FERR)	5528.37 ng/mL	27-375 ng/mL
Urea (BUN)	21.55mmol/L	1.7-8.3 mmol/L
Creatinine (CREA)	283.1 μ mol/L	70-115 μ mol/L
Estimated dlomerular filtration rate (eGFR)	20.65 ml/min	80-120 ml/min
Prothrombin time (PT)	19.30 s	10-14 s
Prothrombin activity P%	47.56 %	70-130 %
Activated partial thromboplastin time (APTT)	71.70 s	22-38 s
Thrombin time (TT)	23.20 s	14-21 s
D-Dimer	4.52 mg/L	0-0.5 mg/L
Aspartate aminotransferase (AST)	40.0 U/L	0-37 U/L
Lactate dehydrogenase (LDH)	511.1 U/L	135-225 U/L
α -Hydroxybutyrate (HDH)	503.0 U/L	72-182 U/L

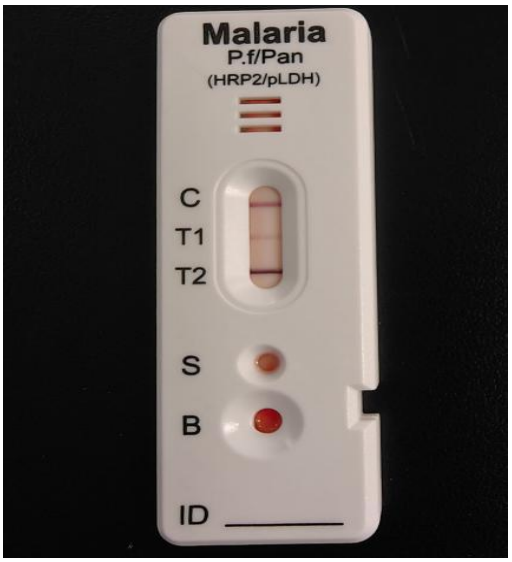

Figure 1. Malaria rapid diagnostic test (RDT) result

Figure 1 Malaria rapid diagnostic test (P.f/Pan, HRP2/pLDH) showing positive bands at control line, T1 and T2. T1 corresponds to pan-Plasmodium pLDH antigen, and T2 corresponds to *Plasmodium falciparum* HRP2 antigen. Dual positive T1 and T2 bands can be seen in either high-density mono-infection of *P. falciparum* or mixed malaria infection.

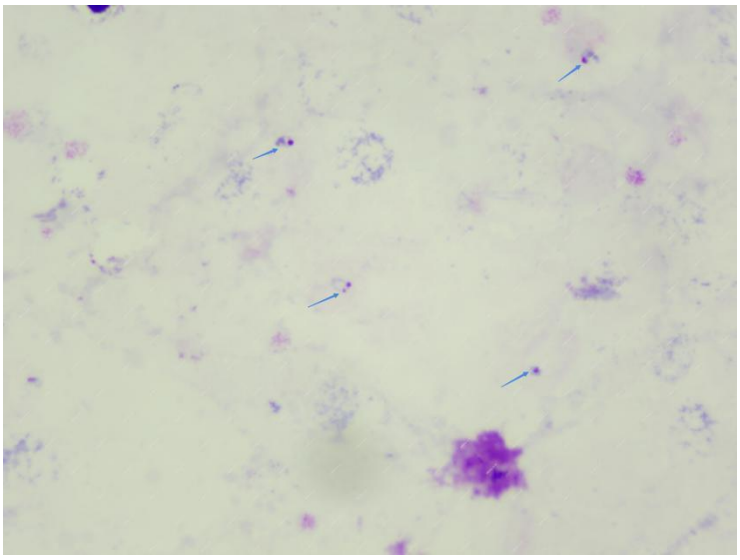

Figure 2. Giemsa-stained thick blood smear of malaria parasites (Case 1)

Figure 2 Giemsa-stained thick blood smear under oil immersion (100× objective). The blue arrows indicate ring-stage parasites with fine cytoplasm and binucleation. This morphology led to an

initial microscopic suspicion of *Plasmodium falciparum*. Combined microscopic review and molecular assay finally confirmed mixed infection of *P. falciparum* and *P. malariae*.

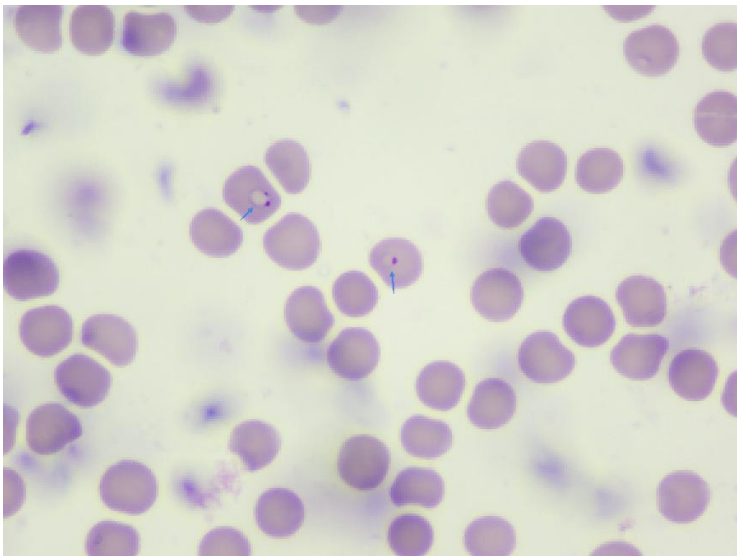

Figure 3. Giemsa-stained thin blood smear of malaria parasites (Case 1)

Figure 3 Giemsa-stained thin blood smear under oil immersion (100×objective). The blue arrows point to ring-stage parasites with delicate and binucleated nuclei.

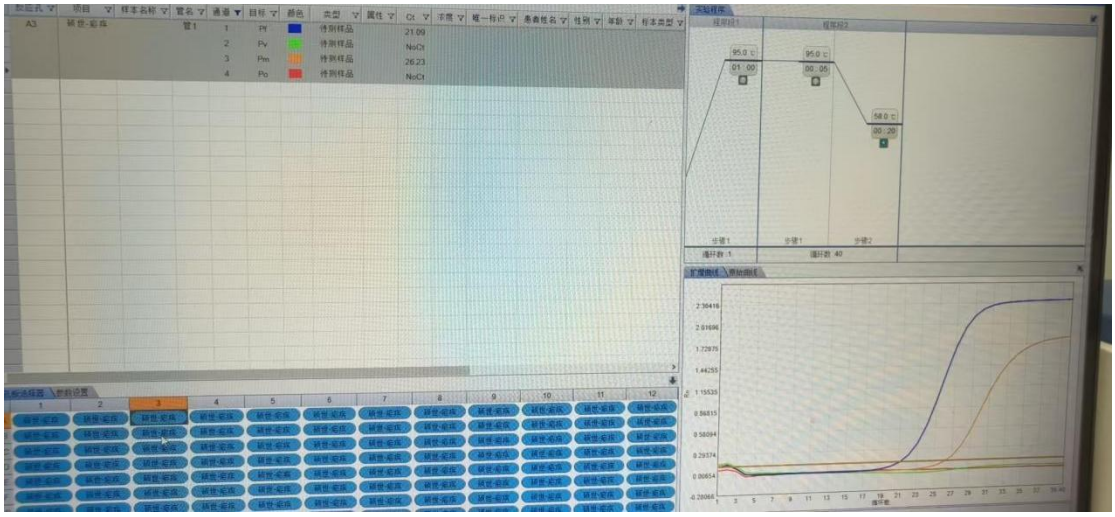

Figure 4. Real-time PCR amplification curves of malaria parasites

Figure 4 Real-time PCR amplification curves demonstrate positive signals for both *Plasmodium falciparum* and *Plasmodium malariae*, confirming mixed malaria infection.

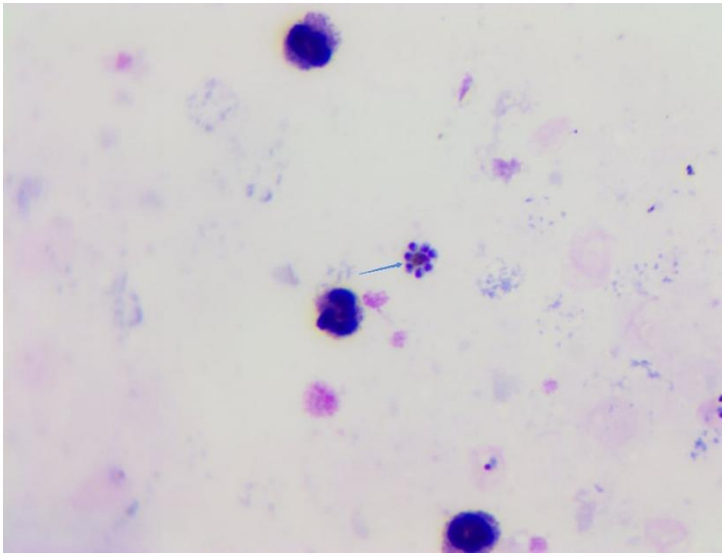

Figure 5. Giemsa-stained thick blood smear of *Plasmodium malariae* (Case 1)

Figure 5 Giemsa-stained thick blood smear under oil immersion (100× objective). The blue arrow indicates a typical rosette-shaped mature schizont of *Plasmodium malariae*, which was found on one of numerous blood smears prepared from the specimen.

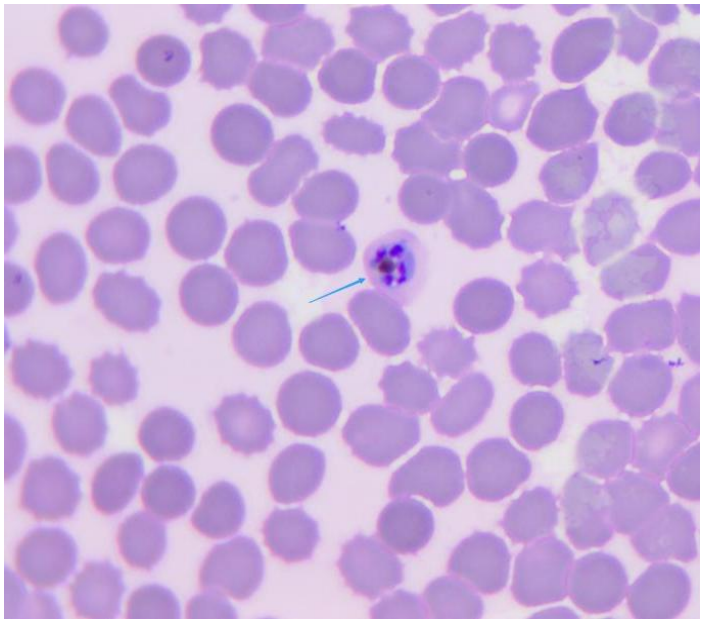

Figure 6. Giemsa-stained thin blood smear of *Plasmodium malariae* (Case 2)

Figure 6 Giemsa-stained thin blood smear under oil immersion (100× objective). The blue arrow indicates an immature schizont of *Plasmodium malariae*.

Case 2

A male patient in his sixties attended our hospital with a history of persistent fatigue lasting more than 20 days. He had returned from Guinea in West Africa, a region where malaria is endemic, approximately two weeks before his first visit. At the initial consultation, fatigue was his only reported symptom; he denied fever, chest tightness, abdominal pain or diarrhoea. Both a malaria rapid diagnostic test and microscopic examination of thick-and-thin blood smears yielded negative results. The attending clinician suggested admission for further observation, but the patient declined this recommendation.

One day after this first outpatient assessment, the patient developed fever with a maximum temperature of 38.2 °C and was subsequently admitted. Routine haematological tests showed a white blood cell count of 4.63×10^9 per litre, haemoglobin concentration of 140 g per litre and a platelet count of 182×10^9 per litre. Malaria rapid diagnostic testing and blood smear microscopy were negative. After symptomatic management, his temperature normalised, and the patient requested hospital discharge.

Three days later, he experienced a further febrile episode, with body temperature rising to 40.5 °C. His fever partially subsided after self-medication with over-the-counter cold-relief granules. He then developed generalised tiredness, reduced appetite, post-prandial abdominal distension and nausea, which prompted readmission. Laboratory investigations demonstrated a high-sensitivity C-reactive protein level of 15.24 mg per litre, lymphocyte proportion of 11.40 per cent, monocyte proportion of 11.00 per cent and eosinophil proportion of 0.20 per cent; the absolute lymphocyte count was 0.56×10^9 per litre, and procalcitonin was 0.33 ng per litre. Additional laboratory findings are presented in Table 2. A plain computed tomography scan of the chest identified scattered tiny pulmonary nodules in both lungs, some with ground-glass features,

minor fibrotic changes within the right lung and a small pericardial effusion. Malaria rapid diagnostic testing and blood smear microscopy were still negative. The working clinical impressions included fever of unknown origin, unexplained fatigue, pericardial effusion and abnormal pulmonary opacities.

After admission, a panel of investigations was arranged to exclude other common causes of persistent fever. Three days after readmission, high-grade fever peaking at 40 °C accompanied by rigours recurred. Repeated malaria rapid diagnostic tests and thick-and-thin smear microscopy remained non-diagnostic. Blood specimens were therefore sent to a municipal Centre for Disease Control and Prevention for malaria quantitative real-time polymerase chain reaction testing. The assay was positive for *Plasmodium malariae*, with a cycle threshold value of 33.98, confirming a diagnosis of quartan malaria. Treatment with artesunate was initiated, and the patient made a gradual clinical recovery.

Item	Result	Reference range
High-sensitivity C-Reactive protein （CRP）	15.24mg/L	0-10 mg/L
Lymphocyte percentage (LYM%)	11.40%	20-40%
Monocyte percentage (MONO%)	11.0%	3-8%
Lymphocyte count	0.56×10^9/L	$0.8\text{-}4\times10^9$/L
Eosinophil count	0.01×10^9/L	$0.05\text{-}0.5\times10^9$/L
Procalcitonin (PCT)	0.33ng/mL	≤0.05 ng/mL
β2-microglobulin(β2-MG)	3.78mmol/L	1-3mmol/L

Discussion

169 Malaria is a vector-borne infectious disease caused by *Plasmodium parasites*. Five species are
170 known to infect humans, including *Plasmodium falciparum, Plasmodium vivax, Plasmodium ovale,*
171 *Plasmodium malariae* and *Plasmodium knowlesi*. Compared with P*. falciparum* and *P. vivax, P.*
172 *malariae* infection usually progresses indolently with insidious manifestations and is easily
173 overlooked clinically. Although the mortality rate of its acute episode is relatively low, the
174 infection can remain latent for a long time. Failure of timely identification and standard
175 treatment may lead to chronic complications such as renal injury in the long run[9-10]. Globally,
176 quartan malaria presents a focal and sporadic distribution, and the vast majority of domestic
177 reported cases are imported from Africa. Qingdao sees mostly imported *P. falciparum* and *P. vivax*
178 infections, while quartan malaria is very rare. This is also the first case series of imported quartan
179 malaria encountered by our team in more than ten years. Clinicians and laboratory staff have
180 limited experience in identifying this parasite, which contributes to the high risk of missed
181 diagnosis[11].
182 Classic malaria is characterized by periodic chills, rigors and high fever. However, many patients
183 present with atypical manifestations, making it difficult to distinguish malaria from other febrile
184 diseases based on clinical symptoms alone. In Case 2 of this report, the patient only complained
185 of fatigue in the early stage without typical rigors and high fever. Repeated malaria screening
186 tests were negative, leading to delayed diagnosis. Malaria was suspected and nucleic acid testing
187 was arranged only after the patient developed typical rigors and high fever later in the disease
188 course. If patients never develop characteristic malaria symptoms, the risk of missed diagnosis
189 will be markedly higher.
190 Rapid diagnostic test (RDT) and thick-thin blood smear microscopy are first-line screening tools

for malaria, but their performance depends on parasite density. When the parasite density of *Plasmodium falciparum* is high, RDT often yields positive signals at both T1 and T2 lines. Therefore, the RDT band pattern cannot be used to judge the presence of mixed infection. Antigen detection by RDT serves only as an initial screening method for malaria and cannot reliably distinguish single infection from mixed infection with multiple Plasmodium species. Confirmation of mixed infection relies on careful microscopic review or molecular nucleic acid testing. In unbalanced mixed infections of *P. falciparum* and *P. malariae*, abundant *P. falciparum* dominates the microscopic field of view and masks low-density *P. malariae*. If laboratory technicians stop species identification once *P. falciparum* is found, co-infection may be missed[12,13]. For mono-infection with low-level *P. malariae*, antigen concentration may fall below the detection limit of RDT, and scarce parasites on blood smears lead to persistent false-negative results on both RDT and microscopy, as seen in Case 2. In non-endemic regions, clinicians tend to prioritize *P. falciparum* when evaluating febrile returnees from endemic areas. Combined with the atypical early manifestations of quartan malaria, missed diagnosis becomes more likely[14]. In non-endemic areas of China, malaria qPCR is mostly available in CDC reference laboratories rather than routine clinical settings. Nucleic acid testing is usually reserved only for specimens with ambiguous species identification by microscopy, which is another key factor contributing to missed *P. malariae* infection[15].

Our two cases represent two typical scenarios of missed diagnosis. Case 1 was a mixed infection where P. malariae was masked by the dominant P. falciparum. Case 2 was a low-density mono-infection with repeatedly negative RDT and microscopy results. Malaria was confirmed by qPCR only after typical malarial symptoms occurred. These cases indicate that quartan malaria

cannot be ruled out merely by negative RDT and blood smear results for patients returning from malaria-endemic areas in Africa. Specimens positive for *P. falciparum* on microscopy should be thoroughly re-screened for co-infection with other Plasmodium species. For febrile patients with exposure history highly suggestive of malaria but negative routine tests, qPCR should be arranged promptly without waiting for the emergence of typical rigors and high fever. Moreover, training should be strengthened for clinical and laboratory personnel to improve the recognition of *P. malariae*. Awareness of its low-parasitemia phenotype, chronic carriage and false-negative results of conventional assays should be emphasized. A tiered screening protocol for imported malaria is needed to reduce missed diagnosis, prevent treatment delay and avoid complications associated with chronic quartan malaria.

List of abbreviations

Plasmodium malariae：*P. malariae*

Plasmodium falciparum：*P. falciparum*

Plasmodium vivax ：*P. vivax*

Plasmodium ovale ：*P. ovale*

Plasmodium knowlesi： *P. knowlesi*

RDT: rapid diagnostic test

qPCR: quantitative real-time polymerase chain reaction

PCR: polymerase chain reaction

DNA: deoxyribonucleic acid

ALT: alanine aminotransferase

AST: aspartate aminotransferase

WBC: white blood cell

RBC: red blood cell count

HGB：Hemoglobin

PLT: platelet

CRP: C-reactive protein

HCT：Hematocrit

LYM%：Lymphocyte percentage

MONO%：Monocyte percentage

ESR：Erythrocyte sedimentation rate

PCT：Procalcitonin

BUN：Urea

FERR：Ferritin

CREA：Creatinine

eGFR：Estimated dlomerular filtration rate

PT：Prothrombin time

PTA: Prothrombin activity

APTT: Activated partial thromboplastin time

TT: Thrombin time

LDH: Lactate dehydrogenase

α-HBDH: α-Hydroxybutyrate

Declarations

Ethics approval and consent to participate

This case report was granted a waiver of ethical review by the Ethics Committee of Qingdao Public Health Clinical Center, because this study was a retrospective descriptive case report with anonymized clinical data, and no additional intervention was performed on the patient.

Consent for publication

Written informed consent for publication of the anonymized clinical data, laboratory findings and relevant images was obtained from the patient.

Availability of data and materials

The raw clinical data supporting this case report are available from the corresponding author upon reasonable request, subject to protection of patient privacy.

Competing interests

The authors declare that they have no competing interests.

Funding

This work did not receive any specific grant from funding agencies in the public, commercial, or not-for-profit sectors.

Authors' contributions

Penglei Zhang and Xiaoyan Shi conceived the case report, collected and sorted the clinical and laboratory data. Lu Guo participated in the literature review and manuscript drafting. Dong Xia performed the laboratory malaria testing and data verification. Jing Li revised the manuscript critically and was responsible for the final approval of the version to be submitted. All authors read and approved the final manuscript.

Acknowledgements

The authors thank the clinical and laboratory staff of Qingdao Public Health Clinical Center for their assistance in the diagnosis and management of this imported malaria case.

References

[1] Langford S, Douglas N M, Lampah D A, et al. Plasmodium malariae Infection Associated with a High Burden of Anemia: A Hospital-Based Surveillance Study[J]. PLOS Neglected Tropical Diseases, 2015, 9(12): e0004195.

[2] Rutledge G G, Brown J, Wang C, et al. Genomic Characterization of Recrudescent Plasmodium malariae after Treatment with Artemisinin-Based Combination Therapy[J]. Emerging Infectious Diseases, 2017, 23(8): 1308-1315.

[3] Feng J, Zhang L, Xia Z, et al. Malaria elimination in China: achievements and lessons learned[J]. Infectious Diseases of Poverty, 2022, 11(1): 74.

[4] Imirzalioglu C, Hagel S, Wellinghausen N, et al. Diagnosis of Mixed Plasmodium malariae and Plasmodium vivax Infection in a Volunteer Returning from Africa[J]. Journal of Clinical Microbiology, 2006, 44(6): 2146-2149.

[5] Yorsaeng R, Saeseu T, Chotivanich K, et al. Indigenous Plasmodium malariae Infection in an Endemic Population at the Thai – Myanmar Border[J]. The American Journal of Tropical Medicine and Hygiene, 2019, 100(5): 1164-1169.

[6] Zhou R, Li Y, Wang J, et al. Characteristics of imported Plasmodium ovale spp. and Plasmodium malariae in Hubei Province, China, 2014 – 2018[J]. The American Journal of Tropical Medicine and Hygiene, 2020, 102(3): 542-548.

[7] Meekes L M, van Hellemond J J, van Genderen P J J, et al. Malaria diagnosis in a malaria non-endemic high-resource country: high variation of diagnostic strategy in clinical laboratories in

301 the Netherlands[J]. Malaria Journal, 2021, 20(1): 286.

302 [8] Brouwer E E, van der Meer P F, van Lieshout L, et al. A case report of transfusion-transmitted

303 Plasmodium malariae from an asymptomatic non-immune traveller[J]. Malaria Journal, 2013,

304 12(1): 430.

305 [9] Zhang L, Yi BY, Zhou SS, et al. Overlooked Plasmodium malariae in the post-elimination era:

306 epidemiological characteristics of Plasmodium malariae in China[J]. Infect Dis

307 Poverty,2023,12(1):101.

308 [10] Badiane A S, Diongue K, Diallo S, et al. Acute kidney injury associated with Plasmodium

309 malariae infection[J]. Malaria Journal,2014,13(1):226.

310 [11] Wang HY, Fu T, Mu R, et al. Epidemiological analysis of imported malaria at Qingdao Port[J].

311 Chinese Journal of Frontier Health and Quarantine,2024,47(2):132-135.

312 [12] Collins W E, Jeffery G M. Plasmodium malariae: parasite and disease[J]. Clinical Microbiology

313 Reviews,2007,20(4):579-592.

314 [13] Zhu HM. Diagnostic challenges of non-Plasmodium falciparum malaria infections[J]. Tropical

315 Diseases and Parasitology,2021,19(2):115-118.

316 [14] Zhao XL, Li SH, Niu WD, et al. Laboratory diagnosis and recheck analysis of imported malaria

317 in Zhengzhou from 2018 to 2020[J]. Journal of Tropical Medicine,2021,21(5):641-644.

318 [15] Zhou SS, Zhang L. Detection challenges and prevention strategies for imported malaria in

319 China after malaria elimination[J]. Chinese Journal of Parasitology and Parasitic

320 Diseases,2022,40(3):265-270.