Research Square

Preprints are preliminary reports that have not undergone peer review.
They should not be considered conclusive, used to inform clinical practice,
or referenced by the media as validated information.

Salvage Boron Neutron Capture Therapy Combined with Bevacizumab Versus Conventional Therapies for Recurrent Diffuse Intrinsic Pontine Glioma: A Retrospective Comparative Cohort Study

Hung-Ruei Liao
National Yang Ming Chiao Tung University
Ko-Han Lin
Taipei Veterans General Hospital
Yi-Yen Lee
Taipei Veterans General Hospital
Chun-Fu Lin
Taipei Veterans General Hospital
Feng-Chi Chang
Taipei Veterans General Hospital
Chih-Chun Wu
Taipei Veterans General Hospital
Shih-Chieh Lin
Taipei Veterans General Hospital
Jia-Cheng Lee
Taipei Veterans General Hospital
Lu-Han Lai
Yuanpei University of Medical Technology
Fong-In Chou
National Tsing Hua University
Jinn-Jer Peir
National Tsing Hua University
Hiroki Tanaka
Kyoto University
Yi-Wei Chen
chen6074@gmail.com

Taipei Veterans General Hospital

Case Report

Keywords: Boron neutron capture therapy (BNCT), Diffuse intrinsic pontine glioma (DIPG), Diffuse midline glioma (DMG), Salvage therapy, recurrent

Posted Date: November 25th, 2026

DOI: https://doi.org/10.21203/rs.3.rs-11724895/v1

License: This work is licensed under a Creative Commons Attribution 4.0 International License. Read Full License

Additional Declarations: No competing interests reported.

Abstract

Purpose: Recurrent H3 K27-altered diffuse intrinsic pontine gliomas (DIPGs) carry a dismal prognosis. Boron neutron capture therapy (BNCT) is a biochemically targeted binary radiotherapeutic modality, yet its comparative clinical efficacy in recurrent or refractory DIPG remains largely unexplored.

Methods: This retrospective cohort study evaluated 34 patients with recurrent or refractory DIPG following standard therapy: 18 received BNCT and 16 received conventional non-BNCT salvage therapies (re-irradiation, chemotherapy, delayed bevacizumab, or palliative care). Kaplan–Meier (KM) analysis and Cox proportional hazards regression were used to evaluate overall survival (OS) and progression-free survival (PFS).

Results: At recurrence, median Karnofsky Performance Status (KPS) or Lansky Play Scale (LPS) score was 60 in both the BNCT (range, 50–70) and non-BNCT (range, 40–70) groups. Observed median OS was 197 days for BNCT versus 98 days for non-BNCT. In univariate Cox regression, BNCT was associated with an 81.2% reduction in mortality risk (hazard ratio [1] = 0.188, p = 0.0009), which remained independent in multivariate analysis (HR = 0.186, p = 0.004). Median PFS did not differ significantly between cohorts (76 vs. 75 days, p = 0.564).

Conclusion: Although limited by a small cohort reflecting the rarity and rapid progression of recurrent H3 K27-altered diffuse midline glioma (DMG), our findings suggest that BNCT may offer a substantial OS benefit over conventional salvage therapies without prolonging PFS.

Keypoints

Point 1: Salvage BNCT with preemptive bevacizumab was associated with significantly prolonged overall survival compared with conventional salvage regimens.

Point 2: In this DIPG cohort, 30 out of 34 patients (88%) had a definitive pathological diagnosis.

Point 3: The survival rate of the conventional salvage therapy cohort in this study is consistent with previous literature.

Introduction

Diffuse midline glioma (DMG), H3 K27-altered (including diffuse intrinsic pontine glioma, DIPG), is a highly aggressive central nervous system malignancy that primarily affects pediatric and young adult populations [2–4]. Characterized by midline anatomical localization and pathognomonic histone mutations [5], DMGs are hard to achieve gross total resection (GTR) due to their infiltrative growth within brain structures [6]. Fractionated focal external beam radiotherapy (EBRT) remains the standard frontline treatment, offering only transient symptomatic relief and temporary disease stabilization [7]. Frontline systemic therapies, including cytotoxic chemotherapies, targeted inhibitors, and immunotherapies, have

consistently failed to improve outcomes[5, 8], leaving a median overall survival (OS) of approximately 9 to 12 months from diagnosis[7, 9].

Following frontline EBRT, disease progression or recurrence is inevitable, typically occurring within six months[7]. In the recurrent setting, therapeutic options are extremely limited [8]. Standard clinical management for recurrent DMG depends on conventional salvage interventions, including re-irradiation (re-RT), systemic therapies, repeat surgical resection, and palliative care. While re-RT can extend survival by only three to six months [3, 10], it is constrained by cumulative radiation toxicity[10, 11]. Bevacizumab is frequently administered to control tumor-associated edema but has failed to demonstrate any direct cytoreductive efficacy or overall survival advantage[2, 12, 13]. Consequently, patients with recurrent DMG face an extremely poor prognosis, with a historical median OS from the time of first recurrence of only 3.7 months under salvage treatments [14]. There is a critical need for selective, highly effective therapies capable of eradicating infiltrative midline tumor cells while sparing surrounding critical brainstem parenchyma.

Boron neutron capture therapy (BNCT) is a biochemically targeted binary radiotherapeutic modality that offers a solution to this challenge. BNCT relies on the selective accumulation of a boron-10 (^{10}B) carrier [15, 16], typically L-p-boronophenylalanine (BPA), within tumor cells, followed by irradiation with low-energy thermal or epithermal neutrons. The subsequent localized capture reaction releases high-linear energy transfer (high-LET) alpha particles and lithium-7 ions [15, 16]. Because these particles have a destructive path length of only 5–9 micrometer (μm), radiation damage is selectively restricted to the boron-loaded neoplastic cells, sparing adjacent normal tissues [15, 16]. BPA uptake is mediated by the L-type amino acid transporter 1[15, 16], which is highly overexpressed in high-grade gliomas and DMGs to meet their elevated metabolic demands [5, 17]. Despite its theoretical advantages and established use in supratentorial gliomas, the clinical efficacy of BNCT in recurrent DMG remains largely unexplored, and its performance has not been directly compared to standard non-BNCT salvage therapies.

To address this gap, we retrospectively evaluated and compared the clinical outcomes of patients with recurrent DIPG treated with BNCT versus those managed with conventional non-BNCT salvage therapies. To our knowledge, this is the first study to directly compare the clinical efficacy of BNCT against standard non-BNCT regimens in the setting of recurrent DIPG. This study provides the first comparative clinical evidence supporting the therapeutic potential of BNCT as a promising salvage option for recurrent DMG and offers a novel perspective on its unique patterns of survival and progression.

Patients and Methods

2.1. Patient Selection and Cohort Definitions

This study was approved by the Institutional Review Board and conducted in accordance with the Declaration of Helsinki. Written informed consent was obtained from all patients or their legal guardians.

Medical records of consecutive 106 patients with recurrent brainstem DMG treated between January 2016 and March 2026 were retrospectively reviewed (Supplementary Fig. 1).

Eligible patients were required to meet the following inclusion criteria: either molecular or histopathological confirmation of H3 K27-alteration (via upfront biopsy or resection showing H3 K27M mutation or global loss of H3 K27me3), or a clinically and radiologically typical DIPG presentation in patients deemed ineligible for biopsy, characterized by a primary diagnostic MRI demonstrating typical features of DIPG with a pons epicenter and involvement of greater than 50% of the pons [10, 18–20]; and complete baseline clinical and neuroimaging datasets, including pre-salvage Karnofsky Performance Status (KPS, for patients ≥ 16 years) or Lansky Play Scale (LPS, for patients < 16 years).

The study cohort was divided into two salvage groups: the BNCT group (N = 18), patients who underwent BPA-mediated BNCT at our nuclear reactor facility combined with an immediate same-day preemptive bevacizumab protocol; and the non-BNCT salvage group (N = 16), which served as a concurrent and historical comparative cohort of patients who progressed under standard-of-care, non-BNCT salvage regimens, including chemotherapy alone, combined chemoradiotherapy (re-irradiation plus chemotherapy), re-surgery, or palliative supportive care.

2.2. Treatment Protocols

2.2.1. Boron Neutron Capture Therapy (BNCT) and Same-Day Bevacizumab

All patients in the BNCT group received L-p-boronophenylalanine (L-BPA) as the boron carrier. L-BPA was administered intravenously at a dose of 500 mg/kg, infused over 3 hours prior to and continuing during neutron irradiation to maintain stable blood boron concentrations. Blood boron levels were monitored dynamically during infusion. To prevent acute, life-threatening vasogenic brainstem edema precipitated by the high-LET capture reaction and subsequent massive tumor necrosis, all 18 patients in the BNCT group received an intravenous infusion of low-dose bevacizumab (5 mg/kg) on the same day. The neutron source is an epithermal neutron beam at nuclear reactor facility.

2.2.2. Non-BNCT Salvage Regimens

Patients in the non-BNCT cohort were managed according to investigator discretion and patients' preference, reflecting the lack of a standardized international salvage protocol. Treatments included chemotherapy alone (n = 9, 56.3%), consisting of cytotoxic regimens (e.g., temozolomide, irinotecan); chemoradiotherapy (n = 4, 25.0%), involving re-irradiation (typically 20–30 Gy in fractionated schedules) combined with concurrent systemic therapy; surgical resection plus adjuvant chemo-radiotherapy (n = 1, 6.3%) for rare focal exophytic recurrences; bevacizumab use (n = 14, 87.5%); and supportive palliative care alone (n = 2, 12.5%).

2.3. Outcome Measures and Response Evaluation

The primary clinical endpoint was overall survival from the date of first disease recurrence (defined as the date of radiographically confirmed recurrence or progression of tumor) to the date of death from any cause, or the date of last follow-up for censored patients. The secondary endpoint was progression free survival (PFS), measured from the date of 1st recurrence diagnosis to the date of documented clinical or radiographic progression or death from any cause.

Radiographic progression was assessed using serial contrast-enhanced brain MRI performed every 8 weeks or upon the onset of clinical symptoms. Given the generally young age of the patient cohort, routine spine MRI was not performed unless clinically indicated by relevant symptoms. Evaluation was according to the Response Assessment in Pediatric Neuro-Oncology (RAPNO) and RANO criteria [21, 22].

2.4. Statistical Analysis

Baseline demographic and clinical characteristics were compared between the BNCT and non-BNCT salvage groups using Fisher's exact test for categorical variables and the Mann-Whitney U test for continuous variables. OS and PFS distributions were estimated using the Kaplan–Meier method. Univariate Cox proportional hazards regression was performed to calculate hazard ratios (HR) and 95% confidence intervals (CI) for death and progression across key baseline covariates (age, sex, treatment group, KPS/LPS, spinal seeding, primary surgery history, and time to recurrence). To control for confounding and selection bias inherent to the retrospective design, multivariable Cox proportional hazards models were constructed. To avoid model overfitting due to the limited number of events ($n < 30$), only the three variables with the lowest p-values in the univariable analysis were included in the multivariable regression. All statistical analyses were performed using R (version 4.1.3). P-values < 0.05 were considered statistically significant.**Results**

3.1. Baseline Patient and Tumor Characteristics

A total of 34 patients with recurrent or refractory brainstem DIPG were included: 18 in the BNCT salvage group and 16 in the non-BNCT salvage group. Baseline demographics and clinical characteristics were compared between the BNCT and non-BNCT salvage groups using Fisher's exact test for categorical variables and the Mann-Whitney U test for continuous variables (Table 1).

Table 1
Baseline Characteristics of BNCT group and non-BNCT group

Characteristics	**BNCT (N = 18)**	**Non-BNCT (N = 16)**	**p-value**
Age (median)	3–31(7.5)	4–60 (11)	0.141
<18yrs, n (%)	15 (83.3)	10 (62.5)	0.250
>18yrs, n (%)	3 (16.7)	6 (37.5)	
Sex, n (%)			0.730
Male, n (%)	7 (38.9)	8 (50)	
Female, n (%)	11 (61.1)	8 (50)	
Primary DIPG treatment			0.014
Sur + Chx+RT, n (%)	4 (22.2)	11 (68.7)	
Chx + RT, n (%)	13 (72.2)	5 (31.2)	
Chx, n (%)	1 (5.6)	0 (0)	
DIPG Histological type			0.348
H3K27M (+), n (%)	15 (83.3)	13 (81.3)	
H3K27M (-) but H3K27me3 global loss, n (%)	0	2 (12.5)	
Radiologically Typical DIPG*, n (%)	3 (16.7)	1 (6.3)	
LPS/KPS at recurrence, median	50–70(60)	40–70(60)	0.792
Recurrence or Refractory tumor Affected Location			
Pons, n (%)	18 (100)	16 (100)	0.999
Cerebrum, n (%)	11 (61.1)	6 (37.5)	0.303
Cerebellum, n (%)	10 (55.6)	7 (43.8)	0.732
Medulla, n (%)	7 (38.9)	6 (37.5)	0.999
Spinal seeding, n (%)	1 (5.6)	4 (25)	0.164
Recurrent or Refractory DIPG treatment			
Sur + Chx+RT, n (%)	0 (0)	1 (6.3)	

*Disease duration of less than 3–6 months, with MRI showing the lesion epicenter in the pons, and occupying at least 50% of the pontine cross-sectional area.

**Abbreviation: BNCT = Boron neutron capture therapy; yrs =years; DIPG = Diffuse intrinsic pontine glioma; Sur = Surgery; Chx = Chemotherapy; RT = Radiotherapy; KPS = Karnofsky Performance Status; LPS = Lansky Play-Performance Scale

Characteristics	BNCT (N = 18)	Non-BNCT (N = 16)	p-value
Chx + RT, n (%)	0 (0)	4 (25)	
Chx, n (%)	0 (0)	9 (56.3)	
Bevacizumab, n (%)	18 (100)	14 (87.5)	
Palliative care, n (%)	0 (0)	2 (12.5)	
*Disease duration of less than 3–6 months, with MRI showing the lesion epicenter in the pons, and occupying at least 50% of the pontine cross-sectional area.			
**Abbreviation: BNCT = Boron neutron capture therapy; yrs =years; DIPG = Diffuse intrinsic pontine glioma; Sur = Surgery; Chx = Chemotherapy; RT = Radiotherapy; KPS = Karnofsky Performance Status; LPS = Lansky Play-Performance Scale			

The median age at recurrence was 7.5 years (range: 3–31) in the BNCT group and 11.0 years (range: 4–60) in the non-BNCT group (p = 0.141). There was no statistically significant difference in the proportion of pediatric patients (< 18 years) between the cohorts, with 15 patients (83.3%) in the BNCT group and 10 patients (62.5%) in the non-BNCT group (p = 0.250). The sex distribution was also balanced, with a female predominance in the BNCT group (61.1% vs. 50.0% in non-BNCT, p = 0.730).

A notable difference was observed in the initial, frontline primary treatment: 68.7% of patients in the non-BNCT group had undergone surgical resection combined with chemoradiotherapy (Sur + Chx+RT), whereas only 22.2% of the BNCT group received initial surgery, with the vast majority (72.2%) receiving chemoradiotherapy (Chx + RT) alone (p = 0.014), reflecting a higher proportion of typically unresectable, infiltrative brainstem tumors in the BNCT cohort.

At the time of recurrence, all 34 patients presented with active lesions in the pons. Secondary structures were also heavily involved, including the cerebrum (BNCT: 61.1% vs. non-BNCT: 37.5%), cerebellum (55.6% vs. 43.8%), and medulla (38.9% vs. 37.5%). Spinal seeding was documented in 1 patient (5.6%) in the BNCT group and 4 patients (25.0%) in the non-BNCT group.

The baseline physical performance was severely compromised in both groups: the median LPS/KPS score at recurrence was 60 (range: 50–70) for the BNCT group and 60 (range: 40–70) for the non-BNCT group, which did not show a statistically significant difference (p = 0.792), indicating poor baseline functional status in both cohorts.

3.2. Post-Recurrence Overall Survival and Risk Factor Analysis

The observed median survival was 197 days for the BNCT group versus 98 days for the non-BNCT group. To account for clinical censoring, Kaplan–Meier survival estimation was performed. The KM estimated median OS was 256 days (8.41 months, 95% CI: 5.45 to 9.72 months) in the BNCT group, compared to 104 days (3.42 months, 95% CI: 1.81 to 4.90 months) in the non-BNCT salvage group (Fig. 1, p = 0.0009).

The estimated 3-month, 6-month, and 9-month OS rates were 94.44%, 64.93%, and 48.70% in the BNCT group, compared to 60.00%, 15.56%, and 7.78% in the non-BNCT group, respectively.

To identify independent prognostic factors of overall survival, Cox proportional hazards regression analysis was performed (Table 2). In the univariate analysis, BNCT was associated with an 81.2% reduction in the risk of death compared to non-BNCT salvage therapies (HR = 0.188, 95% CI: 0.070 to 0.504, p = 0.0009). All other covariates, including age (p = 0.103), sex (p = 0.200), KPS/LPS (p = 0.503), spinal seeding (p = 0.558), and history of primary surgery (p = 0.758)—failed to show a significant association with overall survival.

Table 2
Prognostic factors of Overall survival

	Overall Survival					
	Univariate			**Multivariate**		
Factors	P value	HR	95%CI	P value	HR	95%CI
Age (continuous)	0.103	1.027	0.995–1.061	0.804	1.004	0.970–1.040
BNCT vs. non-BNCT	< 0.001	0.188	0.070–0.504	0.004	0.186	0.069–0.502
Sex	0.200	1.710	0.753–3.885	0.611	1.250	0.530–2.950
Spinal seeding	0.558	1.387	0.465–4.137			
Time to Recurrence or Progression	0.685	0.991	0.951–1.033			
LPS / KPS (continuous)	0.503	1.110	0.818–1.508			
LPS / KPS ≥ 50	0.965	1.018	0.462–2.240			
Surgery for primary tumor	0.758	1.134	0.510–2.523			

*Abbreviation list: BNCT = Boron neutron capture therapy; LPS = Lansky Performance Scale; KPS = Karnofsky Performance Status

To control for potential confounding from the younger age of the pediatric-heavy BNCT cohort and sex, a specified three-variable multivariate Cox regression model was evaluated. After adjusting for continuous age and sex, BNCT remained a highly significant, independent protective prognostic factor, associated with an HR of 0.186 (p = 0.004), translating to a 81.4% reduction in the risk of death. Neither age (HR = 1.004, p = 0.804) nor sex (HR = 1.250, p = 0.611) was significantly associated with survival in this adjusted model, suggesting a potential independent survival benefit associated with BNCT.

3.3. Progression Free Survival and Risk Factor Analysis

In contrast to the overall survival results, the median PFS did not significantly differ between the two groups (Fig. 2). The observed median PFS was 76 days (2.50 months) for the BNCT group versus 75 days (2.47 months) for the non-BNCT salvage group. Specifically, the 3-month, 6-month, and 9-month PFS rates were 40.18%, 26.79%, and 0.00% in the BNCT group, compared to 40.18%, 6.70%, and 6.70% in the non-BNCT group, respectively.

Univariate Cox proportional hazards analysis for PFS was conducted to evaluate the influence of baseline clinical and therapeutic factors (Table 3). No clinical or treatment factor was significantly associated with PFS. The hazard ratio for BNCT vs. non-BNCT was 0.805 (95% CI: 0.385 to 1.684, p = 0.564). Similarly, KPS/LPS score (p = 0.954), spinal seeding (p = 0.873), age (p = 0.926), and primary surgery (p = 0.825) had no statistical impact on the time to progression, confirming the uniform rate of radiographic progression across all clinical subgroups.

Table 3
Prognostic factors of progression free survival

	Progression free Survival		
	Univariate		
Factors	P value	HR	95%CI
Age (continuous)	0.926	0.999	0.971–1.027
BNCT vs. non-BNCT	0.564	0.805	0.385–1.684
Sex	0.775	0.898	0.431–1.872
Spinal seeding	0.873	0.916	0.316–2.662
Time to Recurrence or Progression	0.812	1.003	0.976–1.032
LPS / KPS (continuous)	0.954	0.991	0.739–1.330
LPS / KPS ≥ 50	0.860	0.935	0.441–1.978
Surgery for primary tumor	0.825	0.919	0.437–1.936
*Abbreviation list: BNCT = Boron neutron capture therapy; LPS = Lansky Performance Scale; KPS = Karnofsky Performance Status			

Due to the divergence between PFS and OS, an analysis of post-progression survival (PPS) was conducted. In the non-BNCT group, the median PPS was short, at only 23 days, showing that progression was almost immediately followed by death. Conversely, in the BNCT group, the median PPS was extended to 121 days, indicating that patients survived in a stable, progressive state for an average of 4 months after documented radiographic progression, which accounted for greater than 60% of their total

survival duration. This difference in post-progression survival accounts for the divergence between PFS and OS across the two cohorts.

Discussion

Recurrent H3 K27-altered DMG remains a formidable challenge in pediatric neuro-oncology. To our knowledge, this is the first study comparing biochemically targeted BNCT against conventional non-BNCT salvage therapies. BNCT more than doubled KM-estimated median OS (256 vs. 104 days, p = 0.0009) despite virtually identical median PFS (76 vs. 75 days, p = 0.564).

In our cohort, the median PPS was longer in the BNCT group compared to the non-BNCT group (121 days vs. 23 days). In the conventional non-BNCT salvage group, a progression event was almost always synonymous with death (PPS of only 3 weeks). Because standard cytotoxic chemotherapies or photon re-irradiation provide minimal cytoreductive efficacy within the infiltrative core of brainstem gliomas [2, 5], any radiographic progression at the pontine epicenter translates immediately into critical mass effect on the vital cardiorespiratory centers of the medulla and pons [1, 23], leading to rapid neurological symptoms.

In contrast, BNCT delivers high-LET alpha particles and lithium-7 ions that induce localized, dense double-strand DNA breaks specifically within ^{10}B-loaded tumor cells [15, 16]. This cell-selective destruction targets the critical, highly active pontine core of the tumor, effectively debulking the lesion on a microscopic cellular scale while sparing the adjacent brainstem parenchyma [15, 16]. Even after radiographic progression, sustained tumoricidal activity in boron-avid regions (Supplementary Fig. 2). likely prevented uncontrolled proliferation and fatal brainstem compression [2], with progression potentially arising from suboptimally boron-loaded subregions.

The identical PFS also reflects conventional neuroimaging limitations. BNCT-induced massive tumor necrosis and local inflammation cause blood-brain barrier (BBB) leakage and T2/FLAIR or contrast-enhancement changes on MRI [5, 24]. Without metabolic imaging (e.g., 18F-DOPA or 11C-methionine PET), such treatment-related pseudoprogression is readily misclassified as progressive disease under RAPNO/RANO criteria [20, 25], may shorten BNCT PFS.

Another highlight of our study is our same-day low-dose bevacizumab (5 mg/kg) protocol in the BNCT group. The destruction of BNCT triggers an acute, massive release of pro-inflammatory cytokines and VEGF [2], which can cause life-threatening, acute vasogenic edema in the compartment of the brainstem [12, 13]. While conventional salvage trials often utilize steroids or delayed bevacizumab after symptoms arise[1, 26], we administered bevacizumab proactively on the same day as neutron irradiation. This endothelial stabilization suppressed acute capillaritis and vasogenic brainstem swelling.

The biological rationale of BNCT in recurrent DMG is firmly rooted in the metabolic rewiring of H3 K27-altered tumors [5, 27]. L-BPA enters neoplastic cells primarily via active transport mediated by L-type amino acid transporter 1 (LAT1) [15], which must heterodimerize with CD98 (SLC3A2) to be functionally

expressed on the cell membrane[17, 28, 29]. To sustain their rapid, oncogenic proliferation and protein synthesis, malignant gliomas and DMGs markedly upregulate LAT1, while normal astrocytes and neurons express negligible levels of this transporter[17].

Pharmacokinetic studies show high LAT1 affinity for L-BPA (Km = 20.3 ± 0.8 μM) [15], corroborated by 18F-DOPA PET demonstrating higher amino acid tracer uptake in H3 K27M-mutant DMGs than in wild-type midline gliomas [5, 30], supporting favorable tumor-to-normal boron ratios.

While LAT1 provides cell-level selectivity, drug delivery across the physical blood-brain barrier (BBB) represents the primary obstacle in brainstem therapeutics. In genetic models of pediatric high-grade gliomas, brainstem/pons tumors exhibit a 67% reduction in baseline BBB permeability compared to cortical tumors [31], prior fractionated EBRT and recurrent microvascular proliferation disrupt tight junctions and the blood-tumor barrier [23, 31–33]. Pharmacokinetic microdialysis studies in gliomas reveal that pathological BBB disruption leads to a 3.6-fold increase in the peak tumor extracellular fluid (ECF) concentration and a 2.1-fold expansion of the area under the curve (AUC) of BPA[16]. Combined with active LAT1 transport, prior radiation-induced vascular permeability enables therapeutic L-BPA accumulation within infiltrative recurrent pontine tumors.

A major strength of this study is the use of univariate and multivariate Cox proportional hazards regression to validate the independent prognostic value of BNCT. In our comparative cohort, several baseline variables displayed imbalances, most notably age (median 7.5 years in BNCT vs. 11.0 years in non-BNCT) and frontline primary surgery history (22.2% in BNCT vs. 68.7% in non-BNCT). DMG in younger children is associated with more aggressive clinical courses [5], and high-grade gliomas with primary surgical resection have better outcomes [10]. These imbalances represented potential negative biases against the BNCT group.

Despite these baseline disadvantages, univariate Cox regression demonstrated that BNCT reduced the risk of death by 81.2% (HR = 0.188, p = 0.0009). In our multivariate model adjusting for continuous age and sex, BNCT remained a highly significant, independent protective prognostic factor (HR = 0.186, 95% CI: 0.069–0.502, p = 0.004). Age and sex had no independent statistical impact on survival, indicating that the observed survival advantage cannot be solely attributed to baseline age or sex differences. Furthermore, while the non-BNCT group had a higher rate of baseline spinal seeding (25% vs. 5.6%), spinal seeding was not associated with survival in our cohort (p = 0.558), and our results suggest BNCT as a possible intervention for localized pontine recurrence.

The clinical validity and lack of selection bias in our control cohort are supported by historical benchmarks in the literature. Our non-BNCT salvage cohort exhibited an observed median OS of 98 days (Kaplan–Meier estimated median OS: 104 days; approx. 3.42 months), with 3-, 6-, and 9-month overall survival rates of 60.00%, 15.56%, and 7.78%, respectively. These outcomes are highly consistent with the largest multicenter retrospective natural history study of recurrent H3 K27-altered gliomas to date by Bagley et al. (2025), which reported a median OS of only 3.7 months from first recurrence for the brainstem/DIPG subgroup [14]. Similarly, our results align closely with the prospective phase II trial by

Fangusaro et al. (2021), where patients with progressive DIPG managed with salvage pomalidomide monotherapy experienced a median OS of 3.78 months [34]. Additionally, Lassaletta et al. (2018) documented that recurrent DIPG patients managed without aggressive re-irradiation survived for a median of only 92 days (approx. 3.0 months) post-progression [35]. The congruence between our non-BNCT cohort and these major historical series indicates that the survival outcomes of our control cohort are comparable to historical data and poor prognosis of recurrent brainstem DMG under conventional management. This baseline comparability further highlights the potential benefit of L-BPA-mediated BNCT, w hich achieved a Kaplan–Meier estimated median OS of 256 days (8.41 months; observed median: 197 days), more than doubling the survival window in this uniformly fatal setting.

Study Limitations

This study is limited by its retrospective, single-center design and small sample size (N = 34), although it represents one of the largest single-center comparative cohorts for recurrent brainstem DMG. Additionally, metabolic PET imaging was not uniformly available to definitively distinguish pseudoprogression from true progression. Prospective multi-center trials incorporating PET and perfusion MRI are warranted.

Conclusions

In conclusion, while our findings are limited by a small single-center sample size, which remains a standard challenge given the extreme clinical rarity and rapid disease progression of recurrent H3 K27-altered brainstem DMG, this comparative analysis suggests that L-BPA-mediated BNCT combined with a same-day low-dose bevacizumab protocol represents a highly promising salvage option. Our exploratory findings suggest that BNCT combined with bevacizumab may offer a promising salvage option for recurrent DIPG, warranting validation in prospective multi-center trials. While the cell-selective high-LET alpha-particle destruction of the core tumor offers a therapeutic window, further multi-center prospective trials are necessary to confirm these survival benefits and validate this approach in this uniformly fatal disease.

Declarations

Funding: No funds, grants, or other support was received during the preparation of this manuscript.

Competing Interests: The authors have no relevant financial or non-financial interests to disclose.

Author Contributions: All authors contributed to the study conception and design. Material preparation, data collection, and analysis were performed by Hung-Ruei Liao, Yi-Wei Chen. The first draft of the manuscript was written by Hung-Ruei Liao and all authors commented on previous versions of the manuscript. All authors read and approved the final manuscript.

Data Availability: The datasets generated and/or analyzed during the current study are available from the corresponding author on reasonable request.

Ethical Approval: This study was conducted in accordance with the Declaration of Helsinki and was approved by the Institutional Review Board of Taipei Veterans General Hospital (No. 2024-06-005A), Approved on June 5th, 2024.

Informed Consent: Written informed consent to participate and for publication was obtained from all individual participants or their legal guardians included in the study.

References

1. Uke AD, Luharia A, Dahake S, Mishra GV, Mahakalkar C (2024) Exceptional Tumor Regression in Diffuse Intrinsic Pontine Glioma Post-Radiotherapy: A Case Study. Am J Case Rep 25:e944869
2. Damodharan S, Abbott A, Kellar K, Zhao Q, Dey M (2023) Molecular Characterization and Treatment Approaches for Pediatric H3 K27-Altered Diffuse Midline Glioma: Integrated Systematic Review of Individual Clinical Trial Participant Data. Cancers (Basel). ;15(13)
3. Østergaard DE, Embring A, Sehested A, Magelssen H, Vogelius IR, Kjærsgaard M et al (2025) REMIT: Reirradiation of Diffuse Midline Glioma Patients -A Nordic Society of Paediatric Haematology and Oncology Feasibility Study. Clin Oncol (R Coll Radiol) 37:103682
4. Arrillaga-Romany I, Lassman A, McGovern SL, Mueller S, Nabors B, van den Bent M et al (2024) ACTION: a randomized phase 3 study of ONC201 (dordaviprone) in patients with newly diagnosed H3 K27M-mutant diffuse glioma. Neuro Oncol 26(Supplement2):S173–s81
5. Lovibond S, Gewirtz AN, Pasquini L, Krebs S, Graham MS (2023) The promise of metabolic imaging in diffuse midline glioma. Neoplasia 39:100896
6. Viani GA, Gouveia AG, Arcidiacono F, Marta GN, Hamamura AC, Anselmo P et al (2024) Efficacy and safety of hypofractionated radiotherapy versus conventional fractionated radiotherapy in diffuse intrinsic pontine glioma: A systematic review and meta-analysis. Rep Pract Oncol Radiother 29(3):309–317
7. Pai Panandiker AS, Wong JK, Nedelka MA, Wu S, Gajjar A, Broniscer A (2014) Effect of time from diagnosis to start of radiotherapy on children with diffuse intrinsic pontine glioma. Pediatr Blood Cancer 61(7):1180–1183
8. Farrukh S, Habib S, Rafaqat A, Sarfraz Z, Sarfraz A, Sarfraz M et al (2023) Emerging Therapeutic Strategies for Diffuse Intrinsic Pontine Glioma: A Systematic Review. Healthc (Basel). ;11(4)
9. Mackay A, Burford A, Carvalho D, Izquierdo E, Fazal-Salom J, Taylor KR et al (2017) Integrated Molecular Meta-Analysis of 1,000 Pediatric High-Grade and Diffuse Intrinsic Pontine Glioma. Cancer Cell 32(4):520–37e5
10. Gallitto M, Lazarev S, Wasserman I, Stafford JM, Wolden SL, Terezakis SA et al (2019) Role of Radiation Therapy in the Management of Diffuse Intrinsic Pontine Glioma: A Systematic Review. Adv

Radiat Oncol 4(3):520–531

11. Bergengruen PM, Hernaíz Driever P, Budach V, Zips D, Grün A (2023) Second course of re-irradiation in pediatric diffuse intrinsic pontine glioma: A case study. Strahlenther Onkol 199(8):773–777
12. Qian X, Ning W, Yang J, Dunmall LC, Pandha HS, Shang G et al (2025) The oncolytic adenovirus Ad-TD-nsIL12 in primary or progressive pediatric IDH wild-type diffuse intrinsic pontine glioma results of two phase I clinical trials. Nat Commun 16(1):6934
13. Patay Z, Merchant TE, Nguyen R, Pierson CR, Onar-Thomas A, Broniscer A (2017) Treatment-Related Noncontiguous Radiologic Changes in Children With Diffuse Intrinsic Pontine Glioma Treated With Expanded Irradiation Fields and Antiangiogenic Therapy. Int J Radiat Oncol Biol Phys 99(5):1295–1305
14. Bagley SJ, Umemura Y, Mendez JS, Arrillaga-Romany I, Bielamowicz KJ, Butowski N et al (2025) Prognostic Features of Recurrent Midline and H3 K27M-Mutant Glioma. Cancers (Basel). ;17(13)
15. Wongthai P, Hagiwara K, Miyoshi Y, Wiriyasermkul P, Wei L, Ohgaki R et al (2015) Boronophenylalanine, a boron delivery agent for boron neutron capture therapy, is transported by ATB0,+, LAT1 and LAT2. Cancer Sci 106(3):279–286
16. Yang FY, Lin YL, Chou FI, Lin YC, Hsueh Liu YW, Chang LW et al (2014) Pharmacokinetics of BPA in gliomas with ultrasound induced blood-brain barrier disruption as measured by microdialysis. PLoS ONE 9(6):e100104
17. Nawashiro H, Otani N, Shinomiya N, Fukui S, Ooigawa H, Shima K et al (2006) L-type amino acid transporter 1 as a potential molecular target in human astrocytic tumors. Int J Cancer 119(3):484–492
18. Osorio DS, Patel N, Ji L, Sposto R, Stanek J, Gardner SL et al (2018) Pre-irradiation intensive induction and marrow-ablative consolidation chemotherapy in young children with newly diagnosed high-grade brainstem gliomas: report of the head-start I and II clinical trials. J Neurooncol 140(3):717–725
19. Ceschin R, Kocak M, Vajapeyam S, Pollack IF, Onar-Thomas A, Dunkel IJ et al (2019) Quantifying radiation therapy response using apparent diffusion coefficient (ADC) parametric mapping of pediatric diffuse intrinsic pontine glioma: a report from the pediatric brain tumor consortium. J Neurooncol 143(1):79–86
20. van Veldhuijzen SEM, El-Khouly FE, Jansen MHA, Bakker DP, Sanchez Aliaga E, Haasbeek CJA et al (2017) A phase I/II study of gemcitabine during radiotherapy in children with newly diagnosed diffuse intrinsic pontine glioma. J Neurooncol 135(2):307–315
21. Geraldo AF, Maldonado F, Severino M, Mankad K, Dahmoush H, Soares B et al (2024) Response assessment in pediatric neurooncology (RAPNO) criteria revisited: a practical navigation guide for neuroradiologists. Neuroradiology 66(12):2117–2142
22. Wen PY, Bent Mvd, Youssef G, Cloughesy TF, Ellingson BM, Weller M et al (2023) RANO 2.0: Update to the Response Assessment in Neuro-Oncology Criteria for High- and Low-Grade Gliomas in Adults. J Clin Oncol 41(33):5187–5199

23. Liang C, Gong J, Zhang B, Meng Z, Li M, Guo Y (2021) Multiple subtentorial metastasis in diffuse midline glioma receiving tumor treating fields: a case report and literature review. Ann Transl Med 9(20):1604
24. Souweidane MM, Kramer K, Pandit-Taskar N, Zhou Z, Haque S, Zanzonico P et al (2018) Convection-enhanced delivery for diffuse intrinsic pontine glioma: a single-centre, dose-escalation, phase 1 trial. Lancet Oncol 19(8):1040–1050
25. Vajapeyam S, Brown D, Billups C, Patay Z, Vezina G, Shiroishi MS et al (2020) Advanced ADC Histogram, Perfusion, and Permeability Metrics Show an Association with Survival and Pseudoprogression in Newly Diagnosed Diffuse Intrinsic Pontine Glioma: A Report from the Pediatric Brain Tumor Consortium. AJNR Am J Neuroradiol 41(4):718–724
26. Sedlacik J, Winchell A, Kocak M, Loeffler RB, Broniscer A, Hillenbrand CM (2013) MR imaging assessment of tumor perfusion and 3D segmented volume at baseline, during treatment, and at tumor progression in children with newly diagnosed diffuse intrinsic pontine glioma. AJNR Am J Neuroradiol 34(7):1450–1455
27. Golbourn BJ, Halbert ME, Halligan K, Varadharajan S, Krug B, Mbah NE et al (2022) Loss of MAT2A compromises methionine metabolism and represents a vulnerability in H3K27M mutant glioma by modulating the epigenome. Nat Cancer 3(5):629–648
28. Yanagida O, Kanai Y, Chairoungdua A, Kim DK, Segawa H, Nii T et al (2001) Human L-type amino acid transporter 1 (LAT1): characterization of function and expression in tumor cell lines. Biochim Biophys Acta 1514(2):291–302
29. Dai L, Zeng Q, Zhang T, Zhang Y, Shi Y, Li Y et al (2025) Structural basis for the substrate recognition and transport mechanism of the human y(+)LAT1-4F2hc transporter complex. Sci Adv 11(12):eadq0558
30. Piccardo A, Tortora D, Mascelli S, Severino M, Piatelli G, Consales A et al (2019) Advanced MR imaging and (18)F-DOPA PET characteristics of H3K27M-mutant and wild-type pediatric diffuse midline gliomas. Eur J Nucl Med Mol Imaging 46(8):1685–1694
31. Subashi E, Cordero FJ, Halvorson KG, Qi Y, Nouls JC, Becher OJ et al (2016) Tumor location, but not H3.3K27M, significantly influences the blood-brain-barrier permeability in a genetic mouse model of pediatric high-grade glioma. J Neurooncol 126(2):243–251
32. Conway AE, Reddick WE, Li Y, Yuan Y, Glass JO, Baker JN et al (2014) Occult post-contrast signal enhancement in pediatric diffuse intrinsic pontine glioma is the MRI marker of angiogenesis? Neuroradiology 56(5):405–412
33. van Vulpen M, Kal HB, Taphoorn MJ, El-Sharouni SY (2002) Changes in blood-brain barrier permeability induced by radiotherapy: implications for timing of chemotherapy? (Review). Oncol Rep 9(4):683–688
34. Fangusaro J, Cefalo MG, Garré ML, Marshall LV, Massimino M, Benettaib B et al (2021) Phase 2 Study of Pomalidomide (CC-4047) Monotherapy for Children and Young Adults With Recurrent or Progressive Primary Brain Tumors. Front Oncol 11:660892

35. Lassaletta A, Strother D, Laperriere N, Hukin J, Vanan MI, Goddard K et al (2018) Reirradiation in patients with diffuse intrinsic pontine gliomas: The Canadian experience. Pediatr Blood Cancer 65(6):e26988

Figures

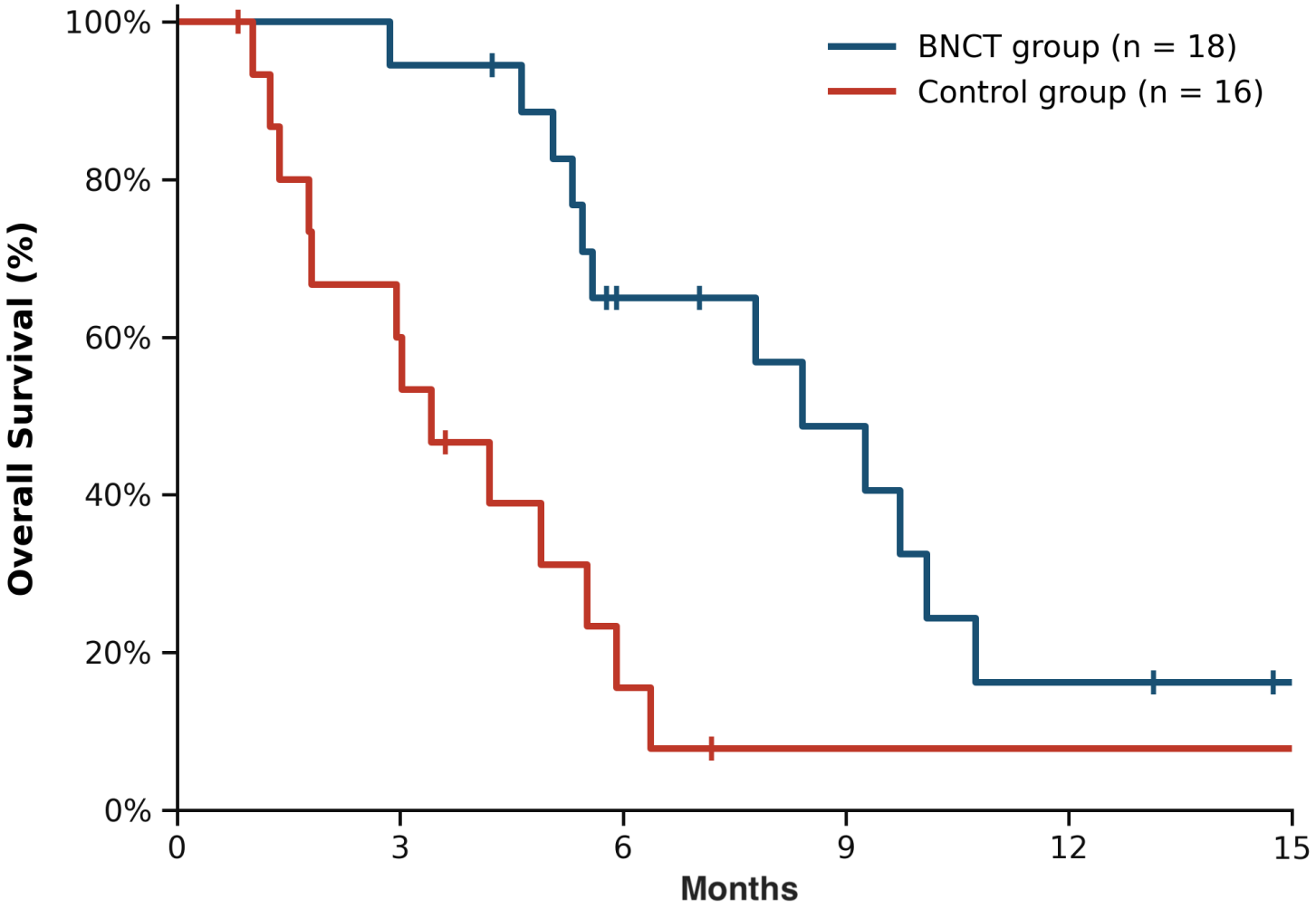

Figure 1

Post-recurrence Overall Survival (OS) of Patients with Recurrent or Refractory DIPG/DMG. Kaplan–Meier survival curves demonstrating a significant OS benefit for L-BPA-mediated Boron Neutron Capture Therapy (BNCT) (solid blue line) versus conventional non-BNCT salvage therapies (dashed red line) (p = 0.0009). KM-estimated median OS was 256 days (95% CI: 166–296 days) for BNCT versus 104 days (95% CI: 55–149 days) for non-BNCT. Tick marks indicate censored patients

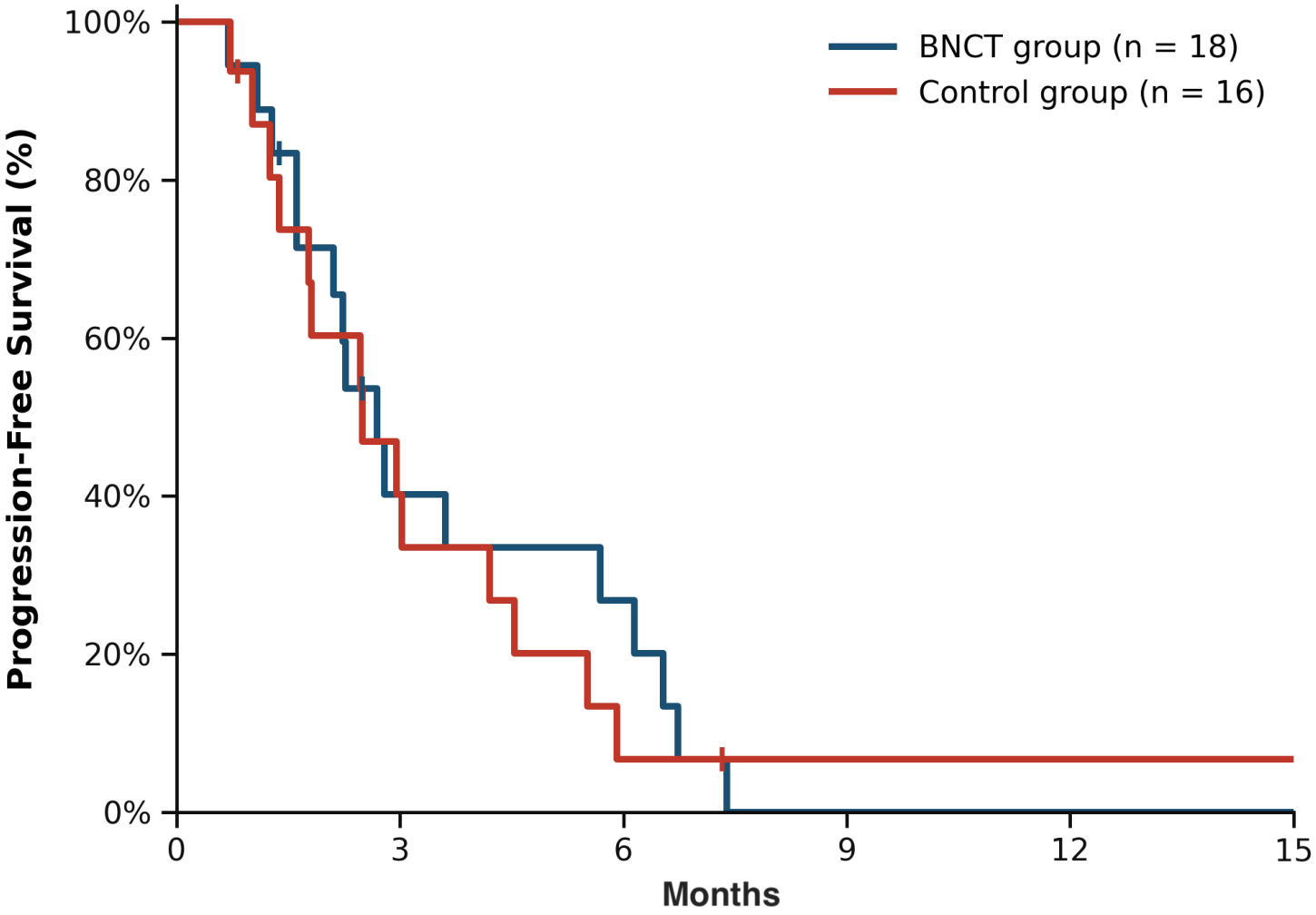

Figure 2

Post-recurrence Progression-Free Survival (PFS) of Patients with Recurrent or Refractory DIPG/DMG. Kaplan–Meier survival curves showing no statistically significant difference in PFS between the BNCT salvage cohort (solid blue line) and the conventional non-BNCT salvage cohort (dashed red line) (p = 0.564)

Supplementary Files

This is a list of supplementary files associated with this preprint. Click to download.

- SupplementaryFigure1.tiff
- SupplementaryFigure2.tiff