Research Square

Preprints are preliminary reports that have not undergone peer review.
They should not be considered conclusive, used to inform clinical practice,
or referenced by the media as validated information.

Cerebral Syphilitic Gumma as an Early Manifestation of Neurosyphilis After Recently Treated Secondary Syphilis: A Case Report

Rodrigo Carrasco Moro
Hospital Universitario Ramón y Cajal
Natalia Isabel Torres Calcines
Hospital Universitario Ramón y Cajal
Juan Salvador Martínez San-Millan
Hospital Universitario Ramón y Cajal
Lara Castellanos Crespo
Hospital Universitario Ramón y Cajal
Miguel Suárez-Robles
Hospital Universitario Ramón y Cajal
Javier Sanz-Martínez
Hospital Universitario Ramón y Cajal
Jorge Díaz-Álvarez
jolohinodam@gmail.com

Hospital Universitario Ramón y Cajal

Case Report

Keywords: Cerebral syphilitic gumma, Neurosyphilis, Treponema pallidum, Secondary syphilis, Men who have sex with men (MSM)

Posted Date: November 24th, 2026

DOI: https://doi.org/10.21203/rs.3.rs-11716999/v1

License: This work is licensed under a Creative Commons Attribution 4.0 International License.
Read Full License

Additional Declarations: No competing interests reported.

Abstract

Purpose

Cerebral syphilitic gumma is a rare manifestation of neurosyphilis, classically regarded as a late complication arising decades after infection. We describe a cerebral gumma that developed within months of treated secondary syphilis.

Methods

We report the clinical, radiological, histopathological, and molecular findings of a 35-year-old HIV-negative man who presented with a right frontal mass five months after a single dose of benzathine penicillin G for presumed secondary syphilis, with negative syphilis serology documented six months earlier.

Results

MRI showed a right frontal lesion with broad dural contact, peripheral enhancement around a necrotic core, restricted diffusion, extensive vasogenic oedema, and subfalcine herniation, precluding lumbar puncture. En bloc resection revealed necrotising granulomatous and vasculitic inflammation; immunohistochemistry demonstrated abundant spirochaetes, and tissue real-time PCR was positive for *Treponema pallidum*. The patient received intravenous penicillin G for 10 days and a tapering course of dexamethasone; at 3 months, RPR had declined from 1/32 to 1/2, and he had no neurological sequelae.

Conclusion

Cerebral gumma can be an early, rather than exclusively late, manifestation of neurosyphilis. Because benzathine penicillin does not achieve treponemicidal cerebrospinal fluid concentrations, clinicians should actively assess for central nervous system involvement in early syphilis and include gumma in the differential diagnosis of intracranial mass lesions in at-risk populations.

Introduction

The incidence of syphilis has risen steadily in Spain since the early 21st century, despite public health efforts aimed at its prevention [1]. Early haematogenous dissemination of *Treponema pallidum* to the central nervous system (CNS) is common, but clinically overt neurosyphilis — and particularly cerebral syphilitic gumma, a rare granulomatous mass lesion — is uncommon [2, 3]. Neurosyphilis can mimic conditions of entirely different aetiology and prognosis, consistent with its reputation as “the great imitator,” a term attributed to William Osler [2]. We report a rare case of cerebral gumma developing less than six months after diagnosis of presumed secondary syphilis, summarised in Table 1.

Table 1
Epidemiological, clinical, diagnostic, therapeutic, and follow-up data

Variable	Data
Age / sex	35 y/M
Primary syphilis	IgG + IgM ELISA negative and TPHA negative 6 mo prior to admission (Nov 2025), with no prior history of syphilis (prior negative serology in Jun 2025)
Secondary syphilis	5 mo prior to hospital admission. IgG + IgM ELISA (-); TPHA positive; RPR 1/16 (Dec 2025). Treatment: benzathine penicillin G 2.4 MU IM × 1 dose
Tertiary syphilis	No
Syphilitic features	None
Non-syphilitic features	Raised intracranial pressure
Serology	Pre-operative: RPR 1/32 (+); IgG/IgM ELISA 23.89 (+); TPHA (+) (Apr 2026). Post-treatment: IgG + IgM ELISA (-); TPHA positive; RPR 1/2 (Jul 2026)
CSF analysis	Not performed
Other STI screening samples	Negative NAAT screening for Neisseria gonorrhoeae and Chlamydia trachomatis (pharyngeal, urine, and rectal samples)
CT scan	Non-contrast and contrast-enhanced
MRI	T1, T1Gd, T2, FLAIR, FLAIR-Gd, SWI, DWI, MRS, perfusion
Radiological diagnosis	Syphilitic gumma
Surgery	Craniotomy and resection
Antimicrobial therapy	Aqueous penicillin G 4 MU/4h IV (24 MU/d) × 10 d followed by benzathine penicillin G 2.4 MU IM × 1 dose before discharge
Corticosteroids	Dexamethasone 2 mg/8h PO (pre-operative) + tapering course (10 d post-operative)
Histopathology	Gumma with spirochaetes (anti-T. pallidum immunohistochemistry, polyclonal, Biocare)
Microbiology	qPCR positive for Treponema pallidum
Duration	3-mo follow-up (ongoing)
Sequelae	None

CSF, cerebrospinal fluid; IM, intramuscular; IV, intravenous; MRS, MR spectroscopy; MSM, men who have sex with men; MU, million units; PO, oral; qPCR, real-time polymerase chain reaction; RPR, rapid plasma reagin; STI, sexually transmitted infection; SWI, susceptibility-weighted imaging; TPHA, Treponema pallidum haemagglutination assay.

Case report

A 35-year-old male with no relevant medical history presented with a three-week history of severe headache and dizziness. Neuroimaging demonstrated a right frontal mass suggestive of an infectious/inflammatory aetiology (Fig. 1). On focused history, he reported unprotected sexual intercourse with men and a palmar maculopapular rash five months earlier; he had been diagnosed with secondary syphilis in another clinic (RPR 1/16; IgG/IgM ELISA and TPHA positive, December 2025) and received a single dose of benzathine penicillin G 2.4 MU IM, but was lost to follow-up, with no further non-treponemal titres until the current admission. Syphilis serology had been negative on two prior occasions — a routine STI screening six months earlier and at symptom onset in November 2025— supporting a truly recent infection. At the time of the secondary-syphilis diagnosis, he reported only long-standing, non-specific headaches, without ophthalmic, otorhinolaryngological, or focal neurological features, therefore, CNS involvement was not considered.

On admission, serology showed a reactive non-treponemal test (RPR 1/32) and reactive treponemal tests (IgG/IgM ELISA 23.89; TPHA positive); HIV serology was negative. Lumbar puncture was not considered due to extensive vasogenic oedema and subfalcine herniation (Fig. 1D). After multidisciplinary discussion, craniotomy with *en bloc* resection was performed (Fig. 2A-B). Histopathology showed a necrotic core with granulomatous, lymphoplasmacytic, and vasculitic inflammation; immunohistochemistry (polyclonal anti-*T. pallidum* antibody, Biocare Medical) revealed abundant spirochaetes, and real-time PCR targeting the *polA* gene, performed on fresh tissue at the National Centre for Microbiology (Instituto de Salud Carlos III), the Spanish reference laboratory, was positive for *T. pallidum*, confirming syphilitic gumma.

The patient received intravenous aqueous penicillin G, 24 million units/day for 10 days, a tapering 10-day course of dexamethasone, and a further dose of benzathine penicillin G before discharge, with no adverse events reported. He was counselled on partner notification, and other STIs were excluded by NAAT (pharyngeal, urine, and rectal samples). At 3-month follow-up, RPR had declined from 1/32 to 1/2, with persistently reactive treponemal tests, and repeat HIV serology was negative; he remained free of neurological sequelae. PrEP was offered but declined, as he reported reduced protected sexual activity since the episode. A follow-up contrast-enhanced MRI was requested and remains pending.

Discussion

T. pallidum invades the CNS early via haematogenous spread, detectable in up to 40% of untreated individuals, most of whom remain asymptomatic [3]. This must be distinguished from clinically overt neurosyphilis and, specifically, cerebral gumma — traditionally regarded as a late/tertiary manifestation arising from a hyperimmune granulomatous reaction, possibly facilitated by strain-specific neurotropism and blood-brain-barrier disruption [2, 4, 5]. Gumma typically begins in the leptomeninges before invading brain parenchyma and adhering to the dura [4]; roughly two-thirds occur at the cerebral convexity, though virtually any site has been described [6, 7].

Before penicillin, cerebral gumma developed in 6.4% of syphilitic patients [6]; fewer than 200 cases have been published since [6, 8, 9], predominantly in young men, with men who have sex with men at particular risk [6, 8, 9]. Paradoxically, gumma is less common in HIV-positive patients, possibly reflecting impaired capacity to mount the hyperimmune response that drives its pathogenesis [10].

Unlike the classical decades-long latency, the interval here was under six months from a benzathine-penicillin-treated episode of secondary syphilis. Early cerebral gummata have occasionally been reported, including a lesion arising within five months of infection in an HIV-negative man, diagnosed on clinical, serological, and radiological grounds without tissue confirmation [11]. In contrast, our case was microbiologically confirmed within the lesion and developed despite treatment with benzathine penicillin. Benzathine penicillin does not achieve treponemicidal CSF concentrations and does not treat neurosyphilis [12]; CNS invasion and early gummatous evolution were therefore likely already underway, overlooked, at that time. This case illustrates that cerebral gumma can represent an early, rather than exclusively late, manifestation of symptomatic neurosyphilis, with pathogenesis likely reflecting an interaction of direct treponemal invasion (confirmed here by immunohistochemistry and PCR), granulomatous injury, and vasculitis, rather than a purely hyperimmune process.

Radiologically, gummata typically show a hypodense/hypointense necrotic core with intense peripheral enhancement, a “dural tail,” and disproportionate vasogenic oedema; they are usually avascular and show no diffusion restriction, an exception in the present case [2, 6, 13, 14]. Their leptomeningeal origin and dural contact can mimic meningioma-like lesions [15].

No single test is diagnostic; we favour an integrated approach combining exposure history, clinical findings, non-treponemal/treponemal serology (and CSF when safely obtainable), and compatible imaging [16]. Serology is positive in up to 83% of published cases, though testing platforms have been heterogeneous [6]. CSF-VDRL is highly specific but insensitive [5, 6, 13, 17]; tissue PCR, as used here, offers direct evidence within the lesion but is not standardised or widely available [5]. Because these histological findings are not syphilis-specific, glioma, metastasis, abscess, tuberculoma, cryptococcoma, toxoplasmosis, sarcoidosis, IgG4-related disease, and primary CNS vasculitis should also be considered; bacterial, mycobacterial, and fungal stains and cultures were negative in our patient. Diagnostic yield is further limited by the risk of an erroneous oncological work-up, the frequent contraindication of lumbar puncture, and historically low spirochaete detection rates with silver staining alone — overcome here by PCR and immunohistochemistry [6, 7, 8].

No standardised treatment protocol exists. Intravenous penicillin G is the cornerstone and, with limited mass effect, may achieve complete response without surgery [4, 5, 18, 19]. Corticosteroids can help control vasogenic oedema but are not disease-modifying and should not substitute antitreponemal therapy [19, 20]. Surgery should be reserved for significant mass effect, herniation, diagnostic uncertainty, or antimicrobial refractoriness [6]; in our patient, oedema and subfalcine herniation justified proceeding directly to resection.

Prognosis is excellent with treatment [6]. Here, the combination of surgery, antimicrobials, and corticosteroids produced a favourable outcome at 3 months, though the contribution of each cannot be individually established, and longer surveillance is needed to exclude relapse. Although single-case observations and non-standardised molecular methods limit generalisation, this case supports considering cerebral gumma in the differential diagnosis of intracranial mass lesions in patients with recent syphilis, even after stage-appropriate treatment

Declarations

Competing interests

The authors have no relevant financial or non-financial interests to disclose.

Ethics approval

This work was conducted in accordance with the ethical principles currently in force. Given its non-experimental and retrospective design, and the anonymisation of clinical and radiological data, institutional Ethics Committee approval was not required.

Consent to publish

Written informed consent for publication of clinical data and accompanying images, including the intraoperative photograph, was obtained from the patient.

Use of artificial intelligence

Claude Sonnet 5 (Anthropic) was used solely to refine the accuracy and fluency of the English language relative to the authors' native language; none of the figures or table was generated or altered with artificial intelligence.

Funding

The authors did not receive support from any organization for the submitted work.

Author Contribution

RCC, LCC and JDA redacted the first manuscript draft, obtained the listed references, and composed the figures illustrating this work. NITC provided the pathological photographs included in Figure 2 and collaborated during the redaction of the corresponding legend. JSMSM provided the radiological images that make up Figure 1 and collaborated during the elaboration of the corresponding legend. MSR, JMS

and JDA supervised the information concerning the domains of knowledge of microbiology and infectious diseases and translated the original draft to English language. All authors revised and approved the final version of the manuscript before submission.

Acknowledgments

Not applicable.

References

1. HIV, STI and, Hepatitis B, Surveillance Unit C. Epidemiological surveillance of sexually transmitted infections, 2023. Bethesda (MD): National Centre of Epidemiology, Carlos III Health Institute; 2024. https://cne.isciii.es/documents/d/cne/vigilancia_its_1995_2023-2
2. Kano S, Inoue A, Masuoka S, Aswani Y, Gaballah AH, Nakaya M, et al. Clinical and imaging features of syphilis from head to toe. Radiographics. 2025;45:e240170. https://doi.org/10.1148/rg.240170.
3. Ghanem KG, Ram S, Rice PA. The modern epidemic of syphilis. N Engl J Med. 2020;382:845–54. https://doi.org/10.1056/NEJMra1901593.
4. Chrétien F, Solom IH, Chimelli L, Sharer LR. Infections of the central nervous system. 5.1.7. Neurosyphilis. In: Anthony DC, De Girolami U, Bielle F, Seilhean D, editors. Escourolle & Poirier's manual of basic neuropathology. New York: Oxford University Press; 2025. pp. 130–2. https://doi.org/10.1093/med/9780197661307.003.0005.
5. Marra CM, Neurosyphilis. Brain. 2025;148:4222–40. https://doi.org/10.1093/brain/awaf329.
6. Fargen KM, Alvernia JE, Lin CS, Melgar M. Cerebral syphilitic gummata: a case presentation and analysis of 156 reported cases. Neurosurgery. 2009;64:568–75. https://doi.org/10.1227/01.NEU.0000337079.12137.89.
7. Faropoulos K, Zolota V, Gatzounis G. Occipital lobe gumma: a case report and review of the literature. Acta Neurochir (Wien). 2017;159:199–203. https://doi.org/10.1007/s00701-016-3015-x.
8. Kanayama S, Nagata S, Akiyama Y, Miyazato Y, Ishikane M, Inoue M, et al. Cerebral syphilitic gumma in the modern era: a report of an unusual case and brief review of recent published reports. Br J Neurosurg. 2024;38:1283–8. https://doi.org/10.1080/02688697.2022.2159923.
9. Barthel L, Hetze S, Teuber-Hanselmann S, Chapot V, Sure U. Syphilitic gummata in the central nervous system: a narrative review and case report about a noteworthy clinical manifestation. Microorganisms. 2021;9:906. https://doi.org/10.3390/microorganisms9050906.
10. Weinert LS, Scheffel RS, Zoratto G, Samios V, Jeffmann MW, Dora JM, et al. Cerebral syphilitic gumma in HIV-infected patients: case report and review. Int J STD AIDS. 2008;19:62–4. https://doi.org/10.1258/ijsa.2007.007007.
11. Kodama T, Sato H, Osa M, Fujikura Y, Kawana A. Cerebral syphilitic gumma in immunocompetent man, Japan. Emerg Infect Dis. 2018;24:395–6. https://doi.org/10.3201/eid2402.171444.

12. Polnikorn N, Witoonpanich R, Vorachit M, Vejjajiva S, Vejjajiva A. Penicillin concentrations in cerebrospinal fluid after different treatment regimens for syphilis. Br J Vener Dis. 1980;56:363–7. https://doi.org/10.1136/sti.56.6.363.
13. Ropper AH, Neurosyphilis. N Engl J Med. 2019;381:1358–63. https://doi.org/10.1056/NEJMra1906228.
14. Corrêa DG, de Souza SR, Freddi TAL, Fonseca APA, Dos Santos RQ. Hygino da Cruz LC Jr. Imaging features of neurosyphilis. J Neuroradiol. 2023;50:241–52. https://doi.org/10.1016/j.neurad.2023.01.003.
15. Chugh A, Punia P, Gotecha S, Kiyawat D, Gore C. Meningoids: lesions mimicking meningiomas. Interdiscip Neurosurg. 2021;26:101302. https://doi.org/10.1016/j.inat.2021.101302.
16. Gutiérrez ML, Carrasco-Moro R, Ruz-Caracuel I, San Millán JSM. Stroke secondary to leptomeningeal carcinomatosis with radiologic signs of arterial invasion. Surg Neurol Int. 2022;13:290. https://doi.org/10.25259/SNI_336_2022.
17. Hamill MM, Ghanem KG, Tuddenham S. State-of-the-art review: neurosyphilis. Clin Infect Dis. 2024;78:e57–68. https://doi.org/10.1093/cid/ciad437.
18. Obrador S, Martín-Rodríguez JG. Tuberculoma and syphilitic gumma. In: Youmans JR, editor. Neurological surgery. Philadelphia: W. B. Saunders Co; 1982. pp. 3445–6.
19. Workowski KA, Bachmann LH, Chan PA, Johnston CM, Muzny CA, Park I, et al. Sexually transmitted infections treatment guidelines, 2021. MMWR Recomm Rep. 2021;70:1–187. https://doi.org/10.15585/mmwr.rr7004a1.
20. Kaal ECA, Vecht CJ. The management of brain edema in brain tumors. Curr Opin Oncol. 2004;16:593–600. https://doi.org/10.1097/01.cco.0000142076.52721.b3.

Figures

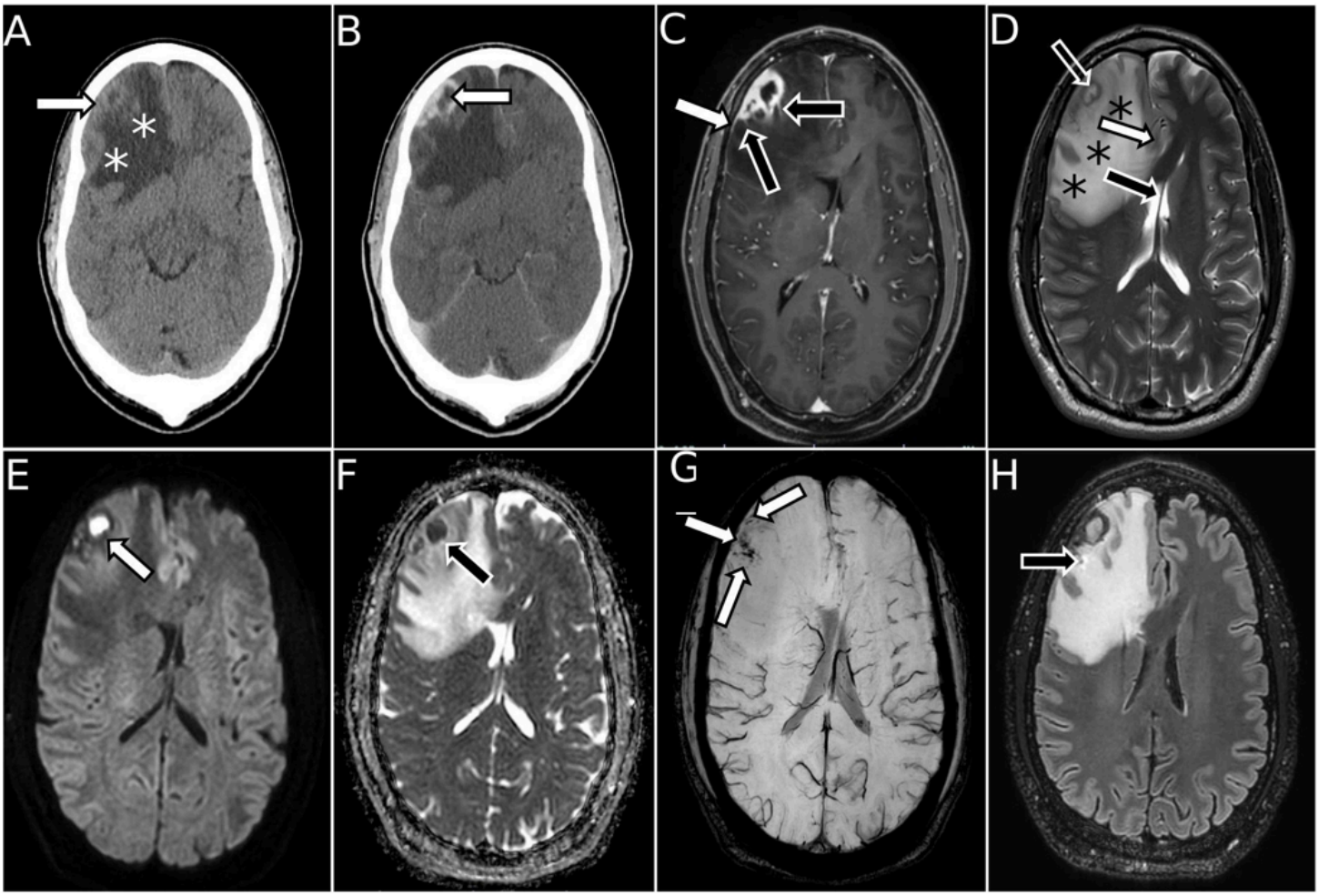

Figure 1

Neuroimaging gallery of the illustrative report. Brain CT (A-B). A) Isodense, cortico-subcortical lesion at the right frontal lobe (white arrow), which associates an extensive hypodense, peripheral digitiform area (white asterisks). B) The mass displays intense contrast uptake, with exception of a markedly hypodense intralesional area (white arrow). Brain MRI (C–H). C) Paramagnetic contrast-enhanced, T1-weighted axial slice. The lesion, measuring 3 cm. in its greatest diameter, shows a broad surface of contact with the pachymeninge. Intense contrast enhancement can be observed, except for areas that remain hypointense within the lesion. Enhancement extends, adopting linear morphology, along the frontal convexity at the posterior margin of the lesion (dural tail sign), and also affects several sulci adjacent to the innermost portion of the mass (black arrows), all these signs traducing leptomeningeal involvement. D) The area of the mass surrounding the necrotic core shows ring-shaped low signal (transparent arrow) on this T2-weighted, axial slice; together with the associated extensive vasogenic oedema (black asterisks), the lesion produces a distortion of the right frontal parenchyma, with contralateral displacement of the midline (black arrow) and signs of subfalcine herniation (white arrow). E–F) The necrotic zone of the lesion shows high signal on diffusion-weighted imaging (white arrow in E) with restricted diffusion on the ADC map (black arrow in F). G) This susceptibility-weighted axial image demonstrates areas of markedly hypointense signal (white arrows) in the periphery of the necrotic

lesion, consistent with microhaemorrhages. H) Focal enhancement of the wall of some vessels adjacent to the lesion (black arrow) becomes evident on this contrast-enhanced FLAIR axial slice, as a sign of inflammation

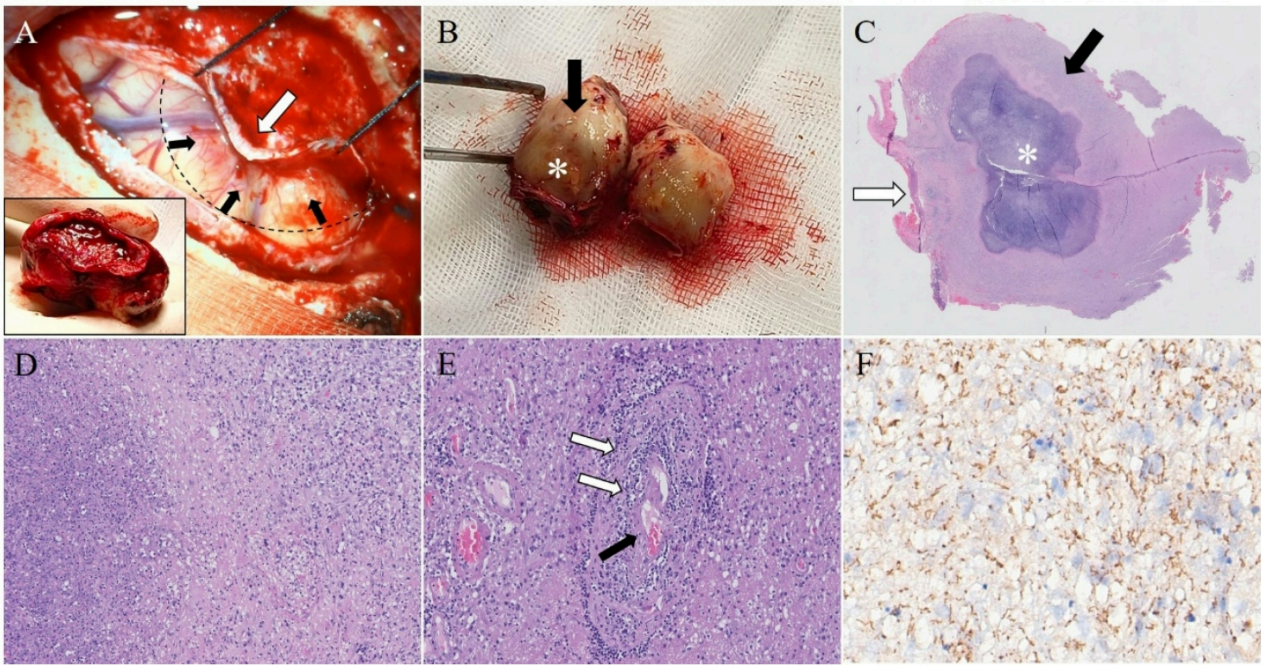

Figure 2

Surgical (A–C) and pathological (C–F) details of the cerebral gumma. A) Intraoperative microsurgical photograph showing right frontal brain parenchyma swelling with superficial vascular engorgement and foci of leptomeningeal petechial haemorrhage (black arrows). The central area demonstrates intimate adherence to the dura mater (white arrow), which has been retracted with sutures on both sides. A circumferential durotomy and corticectomy (dotted black line) allowed definition of a plane for dissection based on the rubbery, increased consistency of the lesion relative to the surrounding brain parenchyma, enabling *en bloc* resection (lower left inset). B) On bisection of the specimen, a yellowish, gelatinous central component (white asterisk) is seen alongside a firmer, beige-coloured peripheral component (black arrow). C) These components correspond microscopically to brain parenchyma with extensive inflammatory changes (black arrow) and a broad central necrotic area (asterisk). Note the dura mater adherent to the leptomeningeal surface at the left margin of the image (white arrow) (H&E). D) Detail of the necrotic margin, showing a moderate inflammatory infiltrate composed of abundant plasma cells, lymphocytes, and neutrophils (H&E). E) Vascular structure (black arrow) with luminal thrombosis and recanalisation phenomena, associated with a dense perivascular lymphoplasmacytic infiltrate (white arrows) (H&E). F) Immunohistochemical staining for *Treponema*, demonstrating abundant spirochaetes within the necrotic zone