Research Square

Preprints are preliminary reports that have not undergone peer review.
They should not be considered conclusive, used to inform clinical practice,
or referenced by the media as validated information.

Individualized revision surgery for complex mechanical instability after percutaneous vertebroplasty: a case report

Chenyang Zhao
Jining Medical University
Xutao Fan
Affiliated Hospital Of Jining Medical University
Jiehuan Wang
Affiliated Hospital Of Jining Medical University
Wen Si
Affiliated Hospital Of Jining Medical University
Pihao Gong
Affiliated Hospital Of Jining Medical University
Chunyang Meng
mengchunyang1600@mail.jnmc.edu.cn
Affiliated Hospital Of Jining Medical College

Case Report

Keywords: percutaneous vertebroplasty, mechanical instability, cement leakage, bilateral pedicle fractures, revision surgery, case report

Posted Date: November 27th, 2026

DOI: https://doi.org/10.21203/rs.3.rs-11716034/v1

License: This work is licensed under a Creative Commons Attribution 4.0 International License.
Read Full License

Additional Declarations: No competing interests reported.

Abstract

Background: Percutaneous vertebroplasty (PVP) is an important minimally invasive treatment for osteoporotic vertebral compression fractures. Complications such as recollapse of the treated vertebra, cement leakage, and abnormal cement distribution have been reported. However, when vertebral nonunion, pedicle disruption, complex cement leakage, and neural compression coexist, identifying the principal symptomatic lesions and developing a safe revision strategy remain clinically challenging.

Case presentation: An 81-year-old man underwent PVP at another institution for an L3 vertebral compression fracture, with limited postoperative pain relief. Approximately 2 months later, he developed progressive low back pain accompanied by radiating pain, numbness, and weakness in the right lower extremity. Following unsuccessful conservative treatment, he was referred to our hospital approximately 4 months after the initial procedure. Imaging revealed a chronic L3 compression fracture, bilateral pedicle fractures, predominantly left-sided intravertebral cement distribution, anterior and intradiscal cement leakage, and right-sided L3–4 foraminal disc herniation with nerve root compression. The anteriorly extravasated cement lay close to the abdominal aorta, increasing the risks associated with revision surgery. Following multidisciplinary assessment and preoperative computed tomography (CT), an individualized revision procedure was performed, comprising repeat cement augmentation of the right side of L3, bilateral L2–L4 pedicle screw fixation, and right-sided neural decompression and intervertebral treatment at L3–4. The anteriorly leaked cement was retained because it appeared stable and was not clearly associated with symptoms. Low back and leg pain improved substantially after surgery. The Oswestry Disability Index (ODI) decreased from 73.3% preoperatively to 40.0% at 1 week, 10.0% at 2 months, and 3.0% at 12 months. Postoperative imaging demonstrated stable instrumentation without appreciable displacement of the leaked cement.

Conclusions: This case suggests that revision surgery for complex instability after PVP should not be planned on the basis of a single radiographic abnormality. Instead, lesions should be prioritized according to vertebral stability, the likely source of neurological symptoms, cement location, and proximity to major vessels. In selected patients, retaining pre-existing cement that appears stable, is asymptomatic, and lies adjacent to major vascular structures, while reconstructing spinal stability, may be a reasonable individualized strategy warranting further investigation. As this is a single case report, no definitive causal relationship can be established between asymmetric cement distribution and subsequent instability.

Highlights

1. Multimodal imaging facilitated the identification of coexisting structural abnormalities and potential sources of neurological symptoms.

2. An individualized revision strategy combined repeat vertebral cement augmentation, posterior instrumentation, and targeted neural decompression.

3. Preoperative assessment of cement leakage adjacent to the abdominal aorta guided the decision to preserve the existing cement and avoid unnecessary vascular injury.

4. The combined revision procedure resulted in substantial pain relief and functional improvement, with the ODI decreasing from 73.3% to 3.0% at 12 months.

5. This case highlights the importance of symptom-guided, risk-stratified revision surgery rather than attempting to correct every radiographic abnormality.

1. Background

Percutaneous vertebroplasty (PVP) is a commonly used minimally invasive procedure for osteoporotic vertebral compression fractures. By injecting bone cement, PVP can increase vertebral strength, relieve pain, and improve local vertebral stability [1]. Nevertheless, some patients experience inadequate pain relief, fracture nonunion, progressive vertebral collapse, cement leakage, or uneven cement distribution after the procedure [2, 3]. Previous studies have examined associations between cement distribution patterns, injected volume, and contact with the vertebral endplates and outcomes such as postoperative pain, vertebral recollapse, and adjacent vertebral fractures [4, 5]. However, when several structural lesions and neural compression coexist at the same vertebral level, identifying the principal contributors to symptoms and developing a safe and effective revision strategy remain challenging [6].

In patients who develop severe nonunion of the treated vertebra, bilateral pedicle fractures, asymmetric intravertebral cement distribution, and leakage at multiple sites after PVP, both local load-bearing capacity and posterior spinal stabilizing structures may be compromised to varying degrees, further complicating revision surgery. Moreover, when cement leaks anteriorly toward major vessels such as the abdominal aorta, direct cement removal may entail additional risk of vascular injury. Surgical planning in such patients must therefore address not only restoration of vertebral stability and neural decompression but also the location and apparent stability of leaked cement and its relationship to critical surrounding anatomy, balancing anticipated benefits against operative risks on an individualized basis.

We report the case of an 81-year-old man who developed mechanical instability of the L3 vertebra after PVP for a compression fracture, with bilateral pedicle fractures, markedly asymmetric intravertebral cement distribution, cement leakage at multiple sites, and right-sided L3–4 disc herniation with nerve root compression. Notably, anteriorly leaked cement was located close to the abdominal aorta, adding to the risks of revision surgery. An individualized procedure was therefore planned, consisting of repeat right-sided L3 cement augmentation, bilateral L2–L4 pedicle screw fixation, and right-sided L3–4 neural decompression and intervertebral treatment, while retaining the relatively stable anterior cement adjacent to the aorta. This report discusses lesion prioritization, identification of symptomatic pathology, and individualized revision decision-making in complex mechanical instability after PVP, with the aim of informing the management of similar challenging cases.

2. Case presentation

2.1 Patient history and clinical findings

The patient was an 81-year-old man who had undergone PVP at a local hospital 4 months earlier for an L3 vertebral compression fracture. His low back pain improved only minimally after the procedure. Approximately 2 months postoperatively, the pain worsened without an apparent precipitating event, accompanied by radiating pain, numbness, and weakness in the right lower extremity. Symptoms were markedly aggravated by turning in bed, sitting up, and prolonged standing. Lumbar flexion was restricted, and pronounced low back and leg pain occurred after walking approximately 20 m. Bed rest did not completely relieve the symptoms, and pain intensified at night. He continued conservative management at home for approximately 2 months, but his symptoms persisted and progressively worsened, prompting presentation to our hospital. On admission, he was 1.70 m tall and weighed 82.5 kg. He had no history of smoking or alcohol consumption and no history of other fractures.

Physical examination revealed tenderness over the lower lumbar interspinous region and bilateral paraspinal muscles, radiating pain in the right lower extremity, a positive right femoral nerve stretch test, and reduced superficial sensation in the right groin and anterior thigh. Babinski signs were positive bilaterally; the patient had a history of corticospinal tract disease, and cervical and thoracic spine examinations showed no abnormalities. Lumbar magnetic resonance imaging (MRI), CT, quantitative computed tomography (QCT) bone mineral density assessment, and anteroposterior and lateral lumbar radiographs were obtained (Fig. 1A–K). Imaging demonstrated a chronic L3 vertebral fracture, bilateral L3 pedicle fractures, and cement concentrated in the left half of the L3 vertebral body without crossing the midline. Cement had leaked anteriorly to the region of the anterior longitudinal ligament, in close proximity to the abdominal aorta, and into the L2–3 disc space. A right-sided L3–4 foraminal disc herniation compressed the nerve root, with an axillary-type configuration. Clustering and compression of the cauda equina were observed at the L3 vertebral level. Images from the initial fracture 4 months earlier were unavailable. However, CT performed at our hospital 6 years earlier showed neither vertebral fracture nor bilateral pedicle disruption (Fig. 1L–M).

2.2 Surgical risk assessment

The patient had coronary artery disease and multiple neurological and respiratory comorbidities. Following multidisciplinary and anesthesiology evaluation, his American Society of Anesthesiologists (ASA) physical status was classified as II, and his New York Heart Association (NYHA) functional class was II. Although the overall perioperative risk was considered elevated, no definite contraindication to surgery was identified. Enhanced perioperative respiratory management, invasive hemodynamic monitoring, and efforts to minimize operative duration and blood loss were recommended.

Preoperative lumbar CT demonstrated cement leakage anterior to the L3 vertebral body, with some cement located along the anterior vertebral margin and near the anterior longitudinal ligament, in close

anatomical proximity to the abdominal aorta. The shortest cement-to-aorta distance was approximately 5 mm. No definite imaging evidence of cement-related vascular injury was identified. However, because early imaging after the initial PVP was unavailable, changes in the position of the anterior cement during the intervening period could not be reliably assessed. Given its proximity to the abdominal aorta, direct dissection or removal of this cement might increase the risk of local tissue damage and vascular injury. Considering the patient's advanced age, comorbidities, and predominant presenting symptoms, the surgical team prioritized treatment of mechanical instability and symptomatic neural compression, while avoiding unnecessary manipulation of anterior cement for which no clear indication for removal existed.

2.3 Preoperative planning

The patient's clinical symptoms, physical findings, and imaging suggested that his progressively worsening low back and leg pain after PVP could not be attributed to a single lesion. Instead, structural instability of the treated vertebra, symptomatic neural compression, and cement leakage at multiple sites coexisted. Because these abnormalities differed in clinical significance and operative risk, separate treatment objectives were established.

First, chronic nonunion of the L3 fracture and bilateral pedicle disruption indicated varying degrees of compromise of both the anterior load-bearing region and posterior stabilizing structures. Existing cement was concentrated primarily on the left, with relatively limited filling of the right side of the vertebral body. Neural decompression alone would not address structural instability, whereas repeat cement augmentation alone would be unlikely to adequately compensate for the damaged posterior stabilizing structures. The team therefore elected to combine repeat right-sided L3 cement augmentation with posterior L2–L4 pedicle screw fixation to improve local vertebral support and restore segmental stability.

Second, the patient reported radiating pain, numbness, and weakness in the right lower extremity. The positive right femoral nerve stretch test and imaging evidence of right-sided L3–4 disc herniation compressing the corresponding neural structures were considered clinically concordant. Accordingly, right-sided decompression and appropriate intervertebral treatment were planned in conjunction with stabilization to address symptoms potentially attributable to neural compression.

Third, pre-existing cement leakage was present anterior to L3 and within the L2–3 disc space. Although the anterior cement was adjacent to the abdominal aorta, there was no definite preoperative evidence of associated vascular injury or other clinical indication mandating its removal. Because direct removal could increase surgical risk, the team decided to retain the anterior and intradiscal cement and monitor them with postoperative imaging.

In summary, the objective of this revision procedure was not to eliminate every radiographic abnormality. Instead, treatment was tailored to the clinical relevance of each lesion: repeat localized augmentation to improve vertebral support, posterior fixation spanning adjacent levels to restore stability, targeted neural

decompression to address a likely source of symptoms, and cautious retention of pre-existing cement in a high-risk anatomical location when no clear indication for removal was present.

Table 1
Individualized revision surgery strategy

Lesion	Evidence	Treatment objective	Management decision
Instability of the treated vertebra after PVP	Vertebral nonunion and local instability	Restore local load-bearing capacity	Repeat right-sided L3 cement augmentation
Bilateral L3 pedicle fractures	Confirmed by CT	Reconstruct posterior stability	Bilateral L2–L4 pedicle screw fixation
Right-sided L3–4 disc herniation	CT/MRI findings concordant with neurological symptoms	Relieve nerve root compression	Right-sided decompression and intervertebral treatment
Anteriorly leaked cement	CT-confirmed proximity to the abdominal aorta; relatively stable after surgery	Avoid additional risk of vascular injury	Retain
Cement in the L2–3 disc space	Stable on CT, without clearly attributable symptoms	Avoid unnecessary intervention	Retain and monitor

2.4 Surgical procedure

On October 14, 2024, the patient underwent posterior lumbar decompression, bone graft fusion, internal fixation, and repeat cement augmentation under combined intravenous and inhalational general anesthesia. Following induction of anesthesia, a posterior midline incision centered over the L3 spinous process was made, and the bilateral laminae and facet joints from L2 to L4 were exposed. The L3 vertebral body was accessed through the right pedicle. A substantial intravertebral bone defect was identified, and 4.5 mL of cement at a toothpaste-like consistency was injected. Fluoroscopy demonstrated satisfactory cement distribution. One pedicle screw was then inserted at each of the following sites: the right L3 pedicle, bilateral L2 pedicles, bilateral L4 pedicles, and left L3 pedicle (six screws in total). Connecting rods were placed, and fluoroscopy confirmed satisfactory instrumentation positioning and lumbar alignment. Right-sided hemilaminotomy and decompression were performed from L2 to L4. Intraoperatively, right-sided L3–4 disc herniation, lateral recess and foraminal stenosis, and compression with congestion of the right L2–L4 nerve roots were observed. The right L3–4 disc material and hypertrophic, inward-projecting facet structures were resected, and the right lateral recesses and neural foramina at L3–4 and L2–3 were enlarged. The dural sac and right L2–L4 nerve roots were subsequently free of tension. After irrigation of the disc space, locally harvested autologous bone was grafted into the anterior portion of the L3–4 intervertebral space. The previously leaked anterior cement was neither dissected nor removed. A drain was placed, and the wound was closed. Operative time was approximately 153 min, and estimated blood loss was 150 mL.

2.5 Postoperative course and follow-up

Low back and leg pain gradually improved after revision surgery. Radiographs and CT obtained on postoperative day 5 showed satisfactory instrumentation positioning and no appreciable migration of the leaked cement. The shortest distances between cement and the abdominal aorta were 4.91 mm on axial images and 4.96 mm on sagittal images, essentially unchanged from preoperative measurements (Fig. 2A–D).

The ODI was 40.0%, 10.0%, 5.0%, and 3.0% at 1 week, 2 months, 7 months, and 12 months after surgery, respectively, compared with 73.3% preoperatively. Corresponding visual analog scale (VAS) scores are provided in Table 2. Imaging at 2 and 7 months demonstrated satisfactory fixation, no appreciable cement migration, and no obvious change in the relationship between the cement and abdominal aorta (Fig. 2E–H). The 12-month assessment was conducted by telephone; no contemporaneous imaging was obtained.

Table 2
VAS and ODI scores and imaging/clinical findings at each assessment

Time point	Visual analog scale (VAS) score	ODI	Imaging/clinical findings
Preoperative	8 (severe pain)	73.3%	Instability after PVP, bilateral pedicle fractures, cement leakage at multiple sites, and L3–4 disc herniation
Postoperative week 1	4 (moderate pain)	40.0%	Radiography and CT: satisfactory fixation, no appreciable migration of pre-existing leaked cement, and no aortic injury
Postoperative month 2	2 (mild pain)	10.0%	Radiography and CT: satisfactory fixation, essentially unchanged cement position, and no aortic injury
Postoperative month 7	1 (occasional discomfort)	5.0%	CT: satisfactory fixation, relatively stable cement position, and no aortic injury
Postoperative month 12	0 (essentially pain-free)	3.0%	Telephone follow-up; no imaging performed

3. Discussion

3.1 A complex pattern of instability rather than isolated asymmetric cement distribution

Abnormal cement distribution is not an uncommon imaging finding after PVP. The distinctive feature of this case, however, was not merely unilateral cement distribution but the coexistence of multiple structural abnormalities and neural compression, resulting in a complex pattern of mechanical instability of the treated vertebra.

After PVP at L3, the patient showed markedly asymmetric cement distribution, predominantly on the left and not crossing the vertebral midline, together with vertebral instability, fracture nonunion, and bilateral pedicle fractures. Anterior and L2–3 intradiscal cement leakage were also present, as was nerve root compression due to a right-sided L3–4 disc herniation. Together, these abnormalities constituted a complex clinical problem involving the anterior vertebral column, posterior stabilizing structures, and neural elements.

From a biomechanical perspective, asymmetric cement distribution may affect load transfer and vertebral mechanical stability [7], while bilateral pedicle disruption may further compromise local stability. In the setting of reduced bone density and vertebral nonunion, these factors may have jointly contributed to the observed mechanical instability. Importantly, complete imaging from before and immediately after the initial PVP was unavailable; therefore, the temporal sequence and causal relationship between asymmetric cement distribution and bilateral pedicle fractures could not be established. Pre-existing bone fragility and progression of the original fracture may also have contributed to the structural damage [8].

Accordingly, this case should not be interpreted simply as inadequate cement filling or an isolated complication of PVP. Rather, the combination of vertebral nonunion, pedicle disruption, abnormal cement distribution, and neural compression should be considered as an integrated pattern of complex mechanical instability. Recognizing this constellation of abnormalities was the first step in planning revision treatment.

3.2 Symptom-guided individualized revision surgery

In patients with persistent pain and multiple radiographic abnormalities after PVP, a central challenge of revision surgery is to determine the clinical significance of each lesion and select interventions addressing the principal pathological processes [9]. In this case, vertebral nonunion, bilateral pedicle fractures, asymmetric cement distribution, and right-sided nerve root compression coexisted. A single surgical maneuver might therefore have been insufficient to address both mechanical instability and neural compression.

Repeat vertebral augmentation was intended primarily to improve local support within the affected vertebra, whereas posterior fixation across adjacent levels was intended to provide additional stability to the compromised segment [10]. Because the bilateral pedicles were structurally damaged, repeat cement augmentation was not selected as the sole treatment. Moreover, the right lower-extremity symptoms were concordant with radiographic evidence of right-sided neural compression, supporting the addition of targeted decompression to address a potential neuropathic pain generator.

Fixation from L2 to L4 was selected to establish posterior stabilization above and below the affected vertebra, complementing local repeat augmentation of L3. Nevertheless, the extent of fixation and specific screw trajectories should be tailored to bone quality, pedicle integrity, and intraoperative fixation

conditions. This case alone does not establish L2–L4 fixation as the optimal approach for all comparable patients.

Postoperative VAS and ODI scores improved progressively, suggesting a favorable clinical response to the combined revision procedure in this patient. However, because repeat augmentation, posterior instrumentation, and neural decompression were performed concurrently, the separate contribution of each component to symptom improvement cannot be quantified. Furthermore, a single case report cannot demonstrate superiority of this combined procedure over fixation alone, repeat augmentation alone, or other revision techniques. Its principal clinical contribution is to illustrate how treatment may be individualized according to structural instability, the likely source of neurological symptoms, and local anatomical risks when several complex lesions coexist.

3.3 Risk-based management of cement adjacent to the abdominal aorta

Cement leakage is an important potential complication of PVP. Its clinical significance depends not only on the extent of leakage but also on its location, proximity to critical anatomical structures, and whether it causes relevant symptoms [11, 12]. When cement lies anterior to the vertebral body near a major vessel such as the abdominal aorta, revision planning must balance potential cement-related complications against the additional injury that may result from attempting direct removal [13, 14].

In this case, preoperative CT demonstrated anterior cement leakage from L3 adjacent to the abdominal aorta, with minimum cement-to-aorta distances of approximately 4.94 mm on axial images and 4.96 mm on sagittal images. There was no definite radiographic evidence of cement-related vascular injury, and no clinical symptoms could clearly be attributed to the anterior leakage. Meanwhile, vertebral nonunion, bilateral pedicle fractures, and nerve root compression warranted treatment. Following comprehensive assessment, the team judged that direct removal of the anterior cement could increase operative trauma and the potential risk of vascular injury, while its expected benefit was uncertain. The pre-existing anterior cement was therefore retained, and the revision focused on reconstruction of stability and decompression of symptomatic neural structures.

Imaging on postoperative day 5 and at 2 and 7 months revealed no appreciable displacement of the retained anterior cement or change in its anatomical relationship to the abdominal aorta. The patient's low back and leg pain and functional disability improved progressively, and no definite cement-related vascular complication was documented during follow-up. These findings suggest that, under the specific clinical circumstances of this case, avoiding direct removal of anteriorly leaked cement was feasible over the short to intermediate term.

Nevertheless, this outcome does not establish that all leaked cement adjacent to major vessels can be safely retained. A clear vascular injury, attributable symptoms, or a change in cement position would warrant reassessment of the treatment strategy. Moreover, early imaging after the initial PVP was unavailable, preventing a complete assessment of cement migration before revision. The 12-month

follow-up was conducted only by telephone, without corresponding imaging. The long-term stability of the retained cement and its vascular safety therefore remain uncertain and require further observation.

4. Conclusion

Revision of complex complications after PVP should follow a symptom-guided, risk-stratified approach, seeking to restore spinal stability and relieve neural compression without adding unnecessary operative risks merely to correct radiographic abnormalities. This case suggests that, following careful risk assessment, cautious retention of apparently stable cement adjacent to the abdominal aorta in the absence of definite vascular complications, together with regular imaging surveillance, may be a feasible individualized option. The indications for this approach and its long-term safety require further investigation.

Abbreviations

PVP, percutaneous vertebroplasty; CT, computed tomography; MRI, magnetic resonance imaging; QCT, quantitative computed tomography; ASA, American Society of Anesthesiologists; NYHA, New York Heart Association; VAS, visual analog scale; ODI, Oswestry Disability Index.

Declarations

Acknowledgements

The author would like to thank the patients and their family members for their help and informed consent.

Author contributions

Zhao CY and Fan XT contributed to the conceptualization of the study, clinical data collection, and manuscript writing. Fan XT, Si W, and Gong PH participated in clinical management, literature review, and analysis. Wang JH contributed to data collection and imaging analysis. Meng CY was responsible for manuscript review and editing, as well as study supervision. All authors read and approved the final version of the manuscript.

Availability of data and materials

All the data supporting our findings are contained within the manuscript.

Ethics approval and consent to participate

Ethical approval was not required for this single case report, in accordance with the institutional/national policy.

Consent for publication

Informed written consent was obtained from the patient for publication of this report and any accompanying images. A copy of the written consent is available for review by the Editor of this journal.

Competing interests

The authors declare that they have no competing interests.

Clinical trial number: not applicable.

References

1. Hulme PA, Krebs J, Ferguson SJ, Berlemann U. Vertebroplasty and kyphoplasty: a systematic review of 69 clinical studies. Spine (Phila Pa 1976). 2006;31(17):1983–2001.
2. Laredo JD, Hamze B. Complications of percutaneous vertebroplasty and their prevention. Semin Ultrasound CT MR. 2005;26(2):65–80.
3. Yu W, Xu W, Jiang X, Liang D, Jian W. Risk Factors for Recollapse of the Augmented Vertebrae After Percutaneous Vertebral Augmentation: A Systematic Review and Meta-Analysis. World Neurosurg. 2018;111:119–29.
4. Tan L, Wen B, Guo Z, Chen Z. The effect of bone cement distribution on the outcome of percutaneous vertebroplasty: a case cohort study. BMC Musculoskelet Disord. 2020;21:541.
5. Zhou C, Liao Y, Huang S, et al. Effect of cement distribution type on clinical outcome after percutaneous vertebroplasty for osteoporotic vertebral compression fractures in the aging population. Front Surg. 2022;9:975832.
6. Yang SC, Chen WJ, Yu SW, Tu YK, Kao YH, Chung KC. Revision strategies for complications and failure of vertebroplasties. Eur Spine J. 2008;17(7):982–8.
7. Liebschner MA, Rosenberg WS, Keaveny TM. Effects of bone cement volume and distribution on vertebral stiffness after vertebroplasty. Spine (Phila Pa 1976). 2001;26(14):1547–54.
8. Ishiyama M, Fuwa S, Numaguchi Y, Kobayashi N, Saida Y. Pedicle involvement on MR imaging is common in osteoporotic compression fractures. AJNR Am J Neuroradiol. 2010;31(4):668–73.
9. Ha KY, Kim KW, Kim YH, Oh IS, Park SW. Revision surgery after vertebroplasty or kyphoplasty. Clin Orthop Surg. 2010;2(4):203–8.
10. Yasuda T, Kawaguchi Y, Suzuki K, et al. Five-year follow up results of posterior decompression and fixation surgery for delayed neural disorder associated with osteoporotic vertebral fracture. Med (Baltim). 2017;96(51):e9395.
11. Venmans A, Klazen CA, van Rooij WJ, de Vries J, Mali WP, Lohle PN. Postprocedural CT for perivertebral cement leakage in percutaneous vertebroplasty is not necessary–results from VERTOS II. Neuroradiology. 2011;53(1):19–22.
12. Rose LD, Bateman G, Ahmed A. Clinical significance of cement leakage in kyphoplasty and vertebroplasty: a systematic review. Eur Spine J. 2024.

13. Umeda A, Saeki N, Matsumoto C, Nakao M, Kawamoto M. Abdominal aortic injury during vertebroplasty. Spine (Phila Pa 1976). 2015;40(7):E439–41.
14. Abergel JN, Mustroph C, Huang J. Delayed anterior cement and SpineJack device dislodgement after kyphoplasty. J Neurointerv Surg Published online April 16, 2026.

Figures

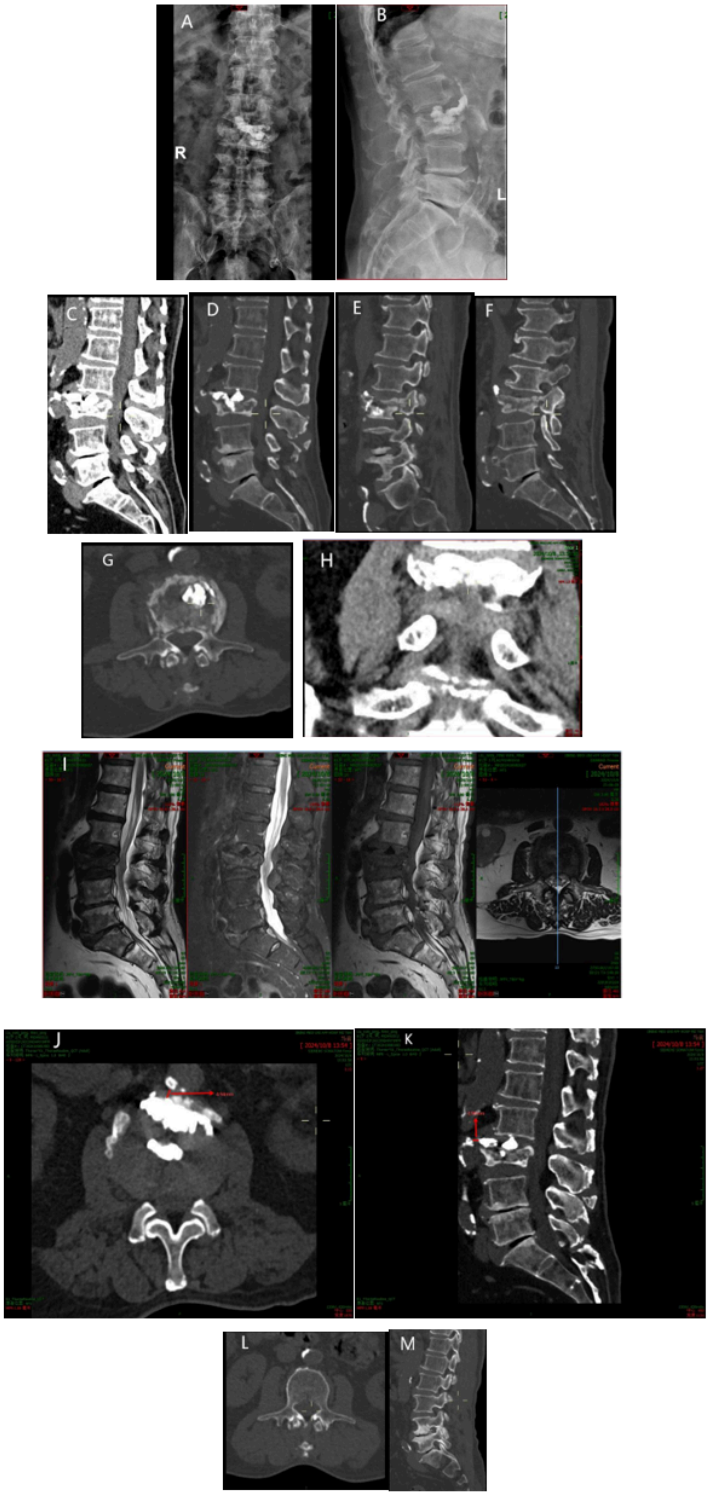

Figure 1

Preoperative imaging findings. (A–B) Anteroposterior and lateral lumbar radiographs show cement concentrated in the left side of the L3 vertebral body, with extensive anterior leakage extending beyond the anterior longitudinal ligament toward the abdominal aorta. (C–F) Sagittal lumbar CT images demonstrate cement extravasation into the L2–3 disc space and anterior to L3, adjacent to the abdominal aorta, together with bilateral L3 pedicle fractures and local vertebral instability. QCT showed bone mineral density values of 88.3 mg/cm³ at L1 and 97.8 mg/cm³ at L2 (mean, 93.0 mg/cm³), within the range of 80–120 mg/cm³. (G–H) Axial and coronal CT images demonstrate left-sided cement distribution that does not cross the midline, as well as disruption of the annulus fibrosus and nucleus pulposus extrusion in the right L3–4 foraminal region, compressing the nerve root (axillary-type herniation). (I) Lumbar MRI demonstrates chronic nonunion of the L3 fracture after PVP, with clustering and compression of the cauda equina at the corresponding level. (J–K) Axial and sagittal CT images show the anterior tip of the leaked cement close to the abdominal aorta, without evident aortic injury; the minimum distances were 4.94 mm on axial imaging and 4.96 mm on sagittal imaging (mean measurements obtained independently by two radiologists). (L–M) Axial and sagittal lumbar CT images obtained more than 6 years earlier show intact bilateral L3 pedicles.



Figure 2

Postoperative imaging and follow-up. (A–D) Anteroposterior and lateral lumbar radiographs and CT obtained on postoperative day 5 show more balanced intravertebral cement distribution, unchanged positioning of the pre-existing leaked cement, L2–L4 pedicle screw fixation, and restoration of local L3 stability. No abdominal aortic injury was evident. The shortest cement-to-aorta distances were 4.91 mm on axial images and 4.96 mm on sagittal images, essentially unchanged from preoperative

measurements. (E–F) Radiographs and CT obtained 2 months postoperatively show no appreciable changes in cement distribution compared with postoperative day 5, or in the morphology and position of the abdominal aorta compared with the pre-revision examination. (G–H) CT at 7 months demonstrates stable local anatomy and minimal, if any, cement displacement. No aortic injury was evident, and the shortest cement-to-aorta distances remained approximately 4.91 mm axially and 4.96 mm sagittally. Measurements represent the means of measurements by two radiologists.

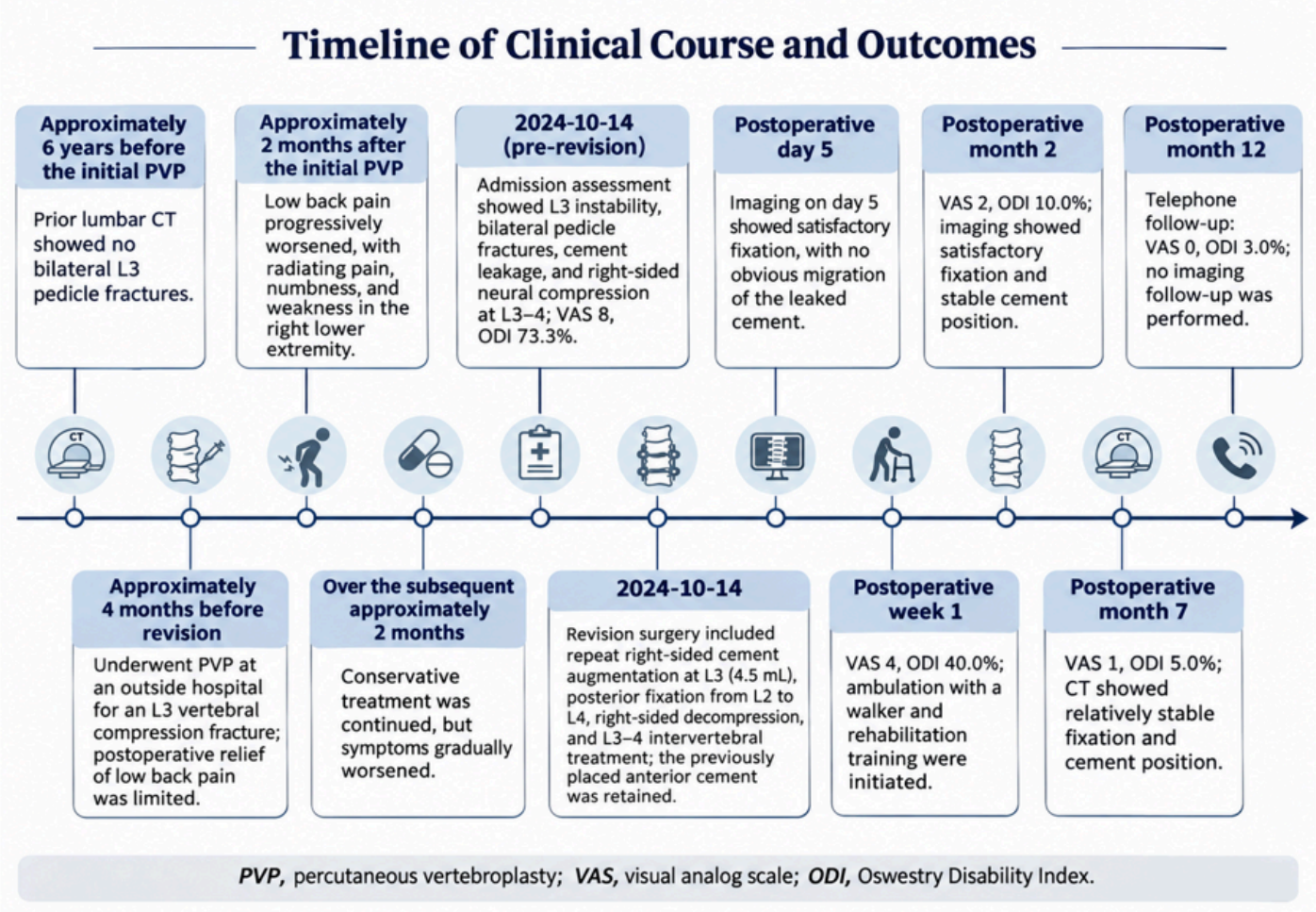

Figure 3

Timeline of major clinical events

Note: Relative intervals are used for the initial PVP and subsequent symptom changes; exact dates were not inferred. The 12-month postoperative follow-up was conducted by telephone.