Research Square

Preprints are preliminary reports that have not undergone peer review.
They should not be considered conclusive, used to inform clinical practice,
or referenced by the media as validated information.

Atypical Presentation of Spontaneous uterine rupture during pregnancy: A case report

Mihiretu Tesfamariam Goshu

michotesfu1@gmail.com

Hawassa University

Ephrem Kedir

Hawassa University

Case Report

Keywords: Spontaneous uterine rupture, Atypical Presentation, Cesarean section, Hemoperitoneum, Hysterectomy

Posted Date: November 23rd, 2026

DOI: https://doi.org/10.21203/rs.3.rs-11707960/v1

License: This work is licensed under a Creative Commons Attribution 4.0 International License.
Read Full License

Additional Declarations: No competing interests reported.

Abstract

Spontaneous uterine rupture is a rare but catastrophic obstetric complication, strongly associated with previous cesarean section. On rare occasions, spontaneous uterine rupture may present with nonspecific symptoms such as unexplained anemia, tachycardia, or signs of intra-abdominal bleeding without a classical presentation. We report a 28-year-old gravida 3 para 2 at 8 months of amenorrhea who presented with nonspecific symptoms and severe anemia without fetal distress or vaginal bleeding. Ultrasound showed a live fetus with significant hemoperitoneum but no visible uterine defect. Emergency laparotomy confirmed a full-thickness defect involving the serosal layer at the previous cesarean scar, covered by organized clot and intact membranes. A hysterectomy was performed due to her hemodynamic instability. This case highlights an atypical presentation of uterine rupture and the importance of early suspicion in high-risk patients.

Introduction

Spontaneous uterine rupture is a rare but catastrophic obstetric complication associated with significant maternal and perinatal morbidity and mortality. It is defined as a complete tear of the uterine wall, including the serosal layer (1). Although the incidence of uterine rupture varies throughout the world, it is significantly higher in low-resource settings and among women with a history of uterine surgery (2, 3). With the rising rate of cesarean sections worldwide, uterine rupture continues to be a major obstetric challenge (4).

The most important risk factors for uterine rupture include a previous cesarean section, trial of labor after cesarean, short interpregnancy intervals, classical uterine scars, uterine overdistension, and uterine trauma. Patients with uterine rupture typically present with sudden-onset abdominal pain, vaginal bleeding, cessation of uterine contractions, and fetal distress (5). On rare occasions, spontaneous uterine rupture may present with nonspecific symptoms such as unexplained anemia, tachycardia, or signs of intra-abdominal bleeding. Maternal and fetal risks increase as a result of this atypical presentation due to delayed diagnosis and intervention (6). The true incidence of spontaneous uterine rupture is difficult to ascertain due to frequent lack of symptoms and incidental discovery during surgery, with one study suggesting the diagnosis was underreported by 35% in the electronic patient record system (7).

The management of uterine rupture necessitates immediate resuscitation and emergency laparotomy, with delivery of the fetus followed by uterine repair if feasible or hysterectomy in cases of extensive damage or uncontrolled hemorrhage (5). Early diagnosis and management in such cases are challenging for physicians. This case highlights the atypical presentation of uterine rupture, manifesting primarily as hemoperitoneum, and reveals the importance of maintaining a high index of suspicion in high-risk patients.

Case report

A 28-year-old gravida 3 para 2 woman at 8 months of amenorrhea presented with a one-week history of easy fatigability, tinnitus, vertigo, and light-headedness. She denied vaginal bleeding, pushing down pain, or trauma. Her obstetric history includes a lower uterine segment cesarean section for arrest of descent in her first pregnancy, followed by a successful vaginal delivery 16 months before the current pregnancy. Her antenatal course was uneventful.

On examination, she had paper-white conjunctiva, a blood pressure of 95/60 mmHg, and tachycardia of 124 beats/min. Abdominal examination revealed a 32-week-sized uterus with clinical signs of intra-abdominal fluid collection, mild suprapubic tenderness, fetal heartbeat of 128 beats/min, and no uterine contractions in 10 minutes. Laboratory evaluation showed a hematocrit of 12.4%, which subsequently decreased to 11% during serial monitoring, with AST (36 U/L) and ALT (35 U/L). Ultrasound showed a 1.3 kg live fetus with a reassuring biophysical profile and a significant hemoperitoneum extending into Morrison's pouch. However, solid organs appeared intact, and no obvious uterine defect was identified. The absence of classical features of uterine rupture, including vaginal bleeding, uterine contractions, and fetal distress, together with the inconclusive ultrasound findings, resulted in diagnostic uncertainty. Following initial assessment, the patient was resuscitated with intravenous crystalloids and closely reassessed. During observation, she developed worsening tachycardia (138 beats/min), hypotension (90/50 mmHg), and a further decline in hematocrit from 12.4% to 11%. Following preparation of cross-matched blood, emergency laparotomy was performed approximately five hours after presentation. Intraoperatively, general anesthesia was administered, and a midline incision was made; approximately two liters of hemoperitoneum were suctioned out (Fig. 1). The abdominal organs were intact. After adhesiolysis, a 10 cm transverse full-thickness defect involving the serosal layer was identified at the previous cesarean section scar site, covered by organized clots (Fig. 2). After clot removal, intact fetal membranes were visible through the defect, confirming uterine rupture. An alive 1.4 kg male neonate was delivered with Apgar scores of 5 and 7 in the first and fifth minutes, respectively. The neonate was assessed by the neonatology team and subsequently admitted to the neonatal intensive care unit with a diagnosis of preterm birth with respiratory distress syndrome. The neonate developed early-onset neonatal sepsis on the fourth day and died on the fifth day. The placenta was expelled by simple traction. A hysterectomy was performed due to her hemodynamic instability. The patient was hypotensive intraoperatively and received four units of blood. Postoperatively, the patient was managed with an indwelling catheter, antibiotics, and analgesia. She recovered well and was discharged in stable condition after one week.

Discussion

Spontaneous uterine rupture is a rare but catastrophic obstetric complication, strongly associated with previous cesarean section and carrying substantial risks of maternal and perinatal morbidity and mortality(1, 5). Classically, uterine rupture presents with acute abdominal pain, vaginal bleeding, and fetal compromise, prompting rapid clinical suspicion (5). This case, on the other hand, presented atypically, characterized by progressive anemia, tachycardia, hypotension, and hemoperitoneum without classic symptoms, which obscured early diagnosis. Recent case reports describe similar clinical

presentations in which uterine rupture was diagnosed intraoperatively or after nonspecific symptoms before the onset of labor (8, 9). This case underscores the importance of maintaining a high index of suspicion for uterine rupture in patients with prior cesarean deliveries, even in the absence of symptoms.

Despite having two liters of hemoperitoneum, our patient's uterine defect was covered by an organized clot and intact membranes, which temporarily exerted pressure on the surrounding structures and masked clinical signs and delayed diagnosis. In such cases, rupture may remain clinically undetected due to the temporary containment of bleeding by surrounding structures (8). The patient's mild symptoms at presentation highlight how concealed bleeding can delay recognition until significant hemodynamic compromise develops.

The patient’s obstetric history significantly contributed to her risk profile for uterine rupture. Previous cesarean delivery is still one of the most important predisposing factors. Even though she had a successful vaginal birth after cesarean delivery, the risk of uterine rupture in subsequent pregnancies was reduced but not eliminated. In addition, interpregnancy interval of 16 months may have contributed to incomplete healing of the scar site (5).

Management involves fast resuscitation and immediate surgical intervention. Emergency laparotomy with delivery of the fetus, followed by uterine repair or hysterectomy, depending on the extent of rupture and maternal clinical condition (5). In our case, due to her hemodynamic instability, a hysterectomy was performed. Although uterine repair may be possible in carefully selected cases, controlling hemorrhage and ensuring maternal survival remain the primary priorities. This case is notable for its absence of classic symptoms, early third-trimester presentation, absence of labor, and presence of massive hemoperitoneum with initially reassuring fetal status. It highlights the need for a high index of suspicion in pregnant women with past cesarean delivery presenting with unexplained anemia or hemodynamic instability, even in the absence of fetal distress or vaginal bleeding.

Conclusion

Spontaneous uterine rupture can present in an atypical manner and lead to delayed diagnosis. Diagnosing silent uterine rupture in pregnant women without uterine contractions is challenging, so a high index of suspicion is important. Rapid resuscitation and timely surgical intervention are essential to improve maternal outcomes.

Abbreviations

ALT Alanine Transaminase

Apgar Appearance Pulse Grimace Activity and Respiration

AST Aspartate Aminotransferase

ICU Intensive Care Unit

Declarations

Ethics approval and consent to participate: Because this case report presents a retrospective case of routine clinical care and does not involve any experimental intervention or identifiable patient data beyond those required for diagnosis and treatment, the need for ethics approval was waived by the Department of Obstetrics and Gynecology Clinical Research Ethics Committee, Hawassa University Comprehensive Specialized Hospital. The study was performed in accordance with the Declaration of Helsinki. Written informed consent was obtained from the patient for participation in the case study.

Consent for publication: Verbal and written consent were obtained from the patient for the publication of this case report and any accompanying images.

Data availability: All data generated or analysed during this study are included in this published article.

Conflicts of Interest: The authors declare that they have no conflicts of interest related to this case report.

Funding: The authors did not receive support from any organization for the submitted work.

Author contributions: E.K. and M.G. both wrote the main manuscript text. E.K prepared the figures. M.G and E.K reviewed the case report.

References

1. Cwm Taf Morgannwg University Health Board. Guideline for the management of uterine rupture. Version 2. Wales: Cwm Taf Morgannwg University Health Board. 2024. Available from: https://wisdom.nhs.wales/health-board-guidelines/cwm-taf-maternity-file/uterine-rupture-management-guideline/
2. Prabhu M, Eckert LO, Belfort M, Babarinsa I, Ananth CV, Silver RM, et al. Antenatal bleeding: Case definition and guidelines for data collection, analysis, and presentation of immunization safety data. Vaccine. 2017;35(48Part A):6529–37. 10.1016/j.vaccine.2017.01.081 . PubMed PMID: 29150058; PubMed Central PMCID: PMC5710989.
3. Motomura K, Ganchimeg T, Nagata C, Ota E, Vogel JP, Betran AP, et al. Incidence and outcomes of uterine rupture among women with prior caesarean section: WHO Multicountry Survey on Maternal and Newborn Health. Sci Rep. 2017;7:44093. 10.1038/srep44093 . PubMed PMID: 28281576; PubMed Central PMCID: PMC5345021.
4. Royal College of Obstetricians and Gynaecologists. Birth after Previous Caesarean Birth. Green-top Guideline No. 45. London: RCOG. 2015. [cited 2026 Apr 12]. Available from: https://www.rcog.org.uk/media/kpkjwd5h/gtg_45.pdf
5. Cunningham FG, Leveno KJ, Bloom SL et al. Williams Obstetrics, 26e | AccessMedicine | McGraw Hill Medical [Internet]. [cited 2026 Apr 12]. Available from:

https://accessmedicine.mhmedical.com/book.aspx?bookid=2977

6. Cheng IN, Lai TH. Risk factors and diagnostic challenges in a nullipara with spontaneous uterine rupture during vaginal delivery. Taiwan J Obstet Gynecol. 2026;65(1):119–22. 10.1016/j.tjog.2025.07.029.
7. Fogelberg M, Baranov A, Herbst A, Vikhareva O. Underreporting of complete uterine rupture and uterine dehiscence in women with previous cesarean section. J Matern-Fetal Neonatal Med Off J Eur Assoc Perinat Med Fed Asia Ocean Perinat Soc Int Soc Perinat Obstet. 2017;30(17):2058–61. 10.1080/14767058.2016.1236249 . PubMed PMID: 27899049.
8. Hock SVD, Hancock E, Dhupar N. Silent complete uterine dehiscence at repeat caesarean section: a case report. Int J Reprod Contracept Obstet Gynecol. 2025;14(8):2754–6. 10.18203/2320-1770.ijrcog20252355.
9. Chen L, Li H, Peng J, Li M, Wang Y, Zhao K, et al. Silent uterine rupture in the term pregnancy: Three case reports. Med (Baltim). 2024;103(10):e37071. 10.1097/MD.0000000000037071 . PubMed PMID: 38457586; PubMed Central PMCID: PMC10919461.

Figures

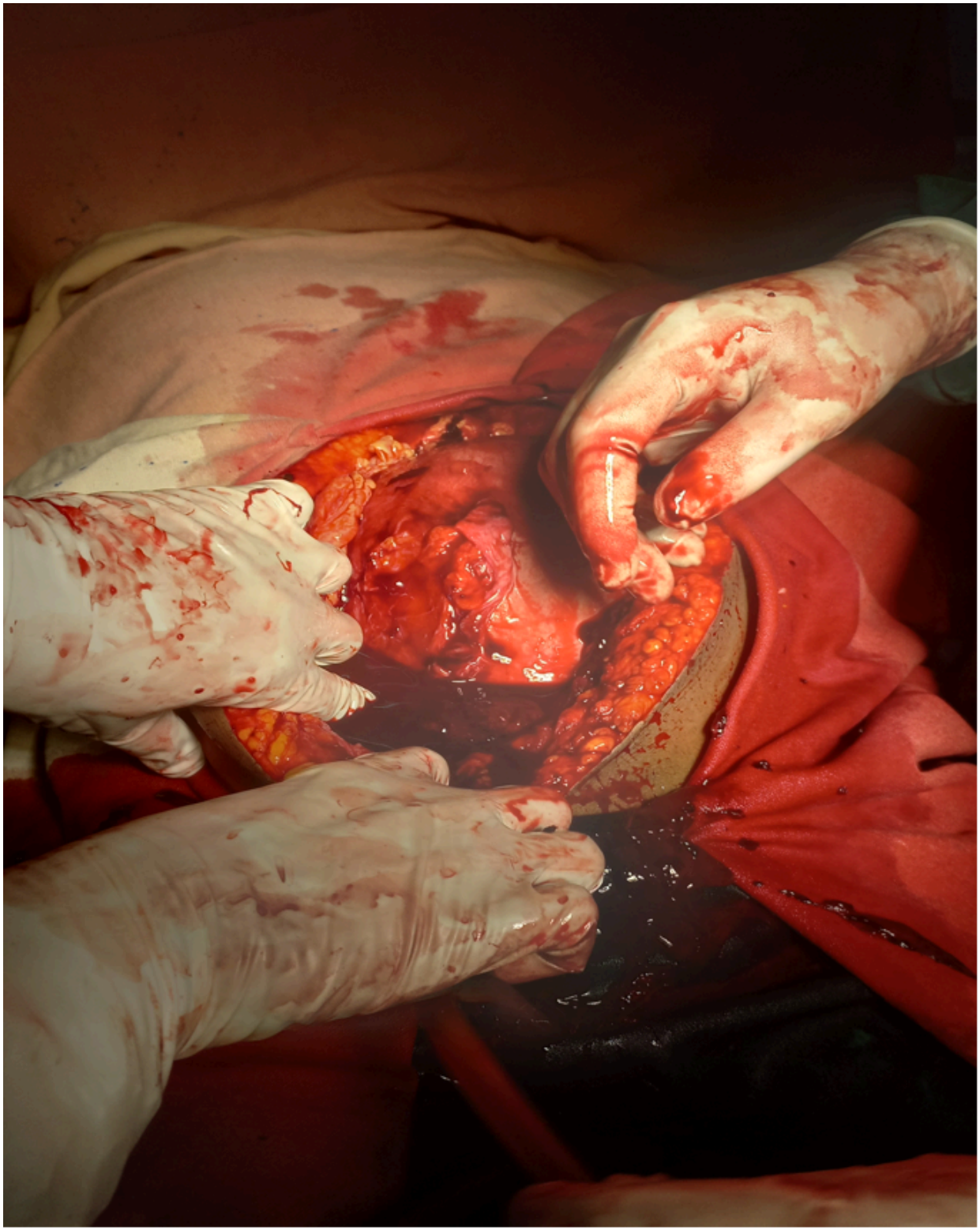

Figure 1

Intraoperative image showing massive hemoperitoneum



Figure 2

Intraoperative image showing a transverse defect at the previous cesarean section scar site, which is covered by organized clot