Research Square

Preprints are preliminary reports that have not undergone peer review.
They should not be considered conclusive, used to inform clinical practice,
or referenced by the media as validated information.

IgG4-related Disease presenting with Bilateral Orbital Apex Syndrome, Optic Neuropathy and Cavernous Sinus involvement despite normal-range serum IgG4: a case report

Piyumi Anuradha
piyumi.anu.tharu@gmail.com
National Hospital of Sri Lanka
Asitha Goonetilleke
National Hospital of Sri Lanka
Ann Velayini Marshall
National Hospital of Sri Lanka
Sandini Apsara Gunaratne
Lady Ridgeway Hospital for Children
Chameera Bandara
National Eye Hospital of Sri Lanka
Dulmini Weerathunga
National Hospital of Sri Lanka
Gamini Pathirana
National Hospital of Sri Lanka

Case Report

Keywords: IgG4-related disease, Orbital apex syndrome, Cavernous sinus syndrome, Optic atrophy, Ophthalmoplegia, Storiform fibrosis, Pseudotumor, Sri Lanka.

Posted Date: November 25th, 2026

DOI: https://doi.org/10.21203/rs.3.rs-11690781/v1

License: This work is licensed under a Creative Commons Attribution 4.0 International License.
Read Full License

Additional Declarations: No competing interests reported.

IgG4-related Disease presenting with Bilateral Orbital Apex Syndrome, Optic Neuropathy and Cavernous Sinus involvement despite normal-range serum IgG4: a case report

Authors: Piyumi Anuradha[1], Asitha Goonetilleke[2], Ann Velayini Marshall[3], Sandini Apsara Gunaratne[4], Chameera Bandara[5], Dulmini Weerathunga[6], Gamini Pathirana[7]

Affiliations: [1,2,3,6,7]Neurology Unit 3, National Hospital of Sri Lanka, Colombo, Sri Lanka
[4]Histopathology Unit, Lady Ridgeway Hospital for Children, Colombo, Sri Lanka

[5]Ophthalmology Unit, National Eye Hospital, Colombo, Sri Lanka

Corresponding Author: Piyumi Anuradha
Neurology Unit 3, National Hospital of Sri Lanka, Colombo, Sri Lanka.
Email:piyumi.anu.tharu@gmail.com Phone: +94710966503

Abstract

Background: Immunoglobulin G4-related disease (IgG4-RD) is a systemic fibroinflammatory condition characterized by lymphoplasmacytic infiltration and storiform fibrosis. While orbital involvement is well-recognized, bilateral orbital apex syndrome (OAS) combined with cavernous sinus involvement and optic nerve compression is exceedingly rare. This case highlights the diagnostic challenge of IgG4-RD when it presents as an aggressive, bilateral "pseudotumor" mimicking neoplastic processes, particularly in the presence of normal serum IgG4 levels.

Case presentation: A 42-year-old Sri Lankan male with poorly controlled diabetes and hypertension presented with a 6-month history of progressive right eye ptosis, proptosis, and monocular vision loss. This was followed by left eye involvement over 3 months, resulting in bilateral complete ophthalmoplegia and profound visual impairment (There was no perception of light in the right eye, while visual acuity was 6/36 in the left eye). Clinical examination revealed bilateral complete ptosis, proptosis, and optic disc atrophy. Imaging (contrast-enhanced MRI brain with orbits) demonstrated extensive pan-sinus mucosal disease extending into the bilateral orbits and bilateral cavernous sinuses, appearing as an abnormal, T2-hypointense, contrast-enhancing soft-tissue mass. Laboratory investigations showed elevated serum IgE (570 IU/mL), while ANA, ANCA, and serum IgG4 levels (1.9 g/L) were within normal limits. An orbital tissue biopsy was definitive, showing dense storiform fibrosis and a predominant IgG4-positive plasma cell infiltrate (>100 per high-power field). The patient was treated with intravenous methylprednisolone followed by a short tapering course of oral prednisolone and azathioprine, leading to significant clinical improvement and stabilization of vision in the left eye, though right-sided optic atrophy persisted.

Conclusions: This case underscores that IgG4-RD can present as a devastating bilateral orbital apex syndrome even with normal serum IgG4 levels. The aggressive "pseudotumor" appearance and bilateral cavernous sinus involvement are rare manifestations that necessitate a high index of suspicion. Histopathological confirmation remains the gold standard, and early recognition followed by aggressive immunosuppressive therapy is critical to preventing irreversible neurological deficits and permanent blindness.

Keywords

IgG4-related disease, Orbital apex syndrome, Cavernous sinus syndrome, Optic atrophy, Ophthalmoplegia, Storiform fibrosis, Pseudotumor, Sri Lanka.

Background

Immunoglobulin G4-related disease (IgG4-RD) is a multi-organ immune-mediated condition that can affect almost any organ system, most commonly the pancreas, salivary glands, and lymph nodes [1]. In the head and neck, IgG4-related ophthalmic disease (IgG4-ROD) typically

presents as dacryoadenitis or orbital myositis [2, 3]. However, involvement of the orbital apex and cavernous sinus is rare and can lead to orbital apex syndrome (OAS), characterized by dysfunction of the optic nerve (II) and the third, fourth, and sixth cranial nerves, along with the ophthalmic division of the trigeminal nerve (V1) [3].

Bilateral presentation of OAS due to IgG4-RD is particularly uncommon and gives rise to a significant diagnostic dilemma, as it must be differentiated from other inflammatory conditions like granulomatosis with polyangiitis (GPA), sarcoidosis, and Tolosa-Hunt syndrome, as well as malignancies and infections [4]. Furthermore, IgG4-RD can present as an inflammatory "pseudotumor"—a mass-like lesion that mimics neoplastic growth. While dacryoadenitis is often bilateral, the aggressive extension into the cavernous sinuses and the resulting bilateral vision loss seen in this case represent a rare and severe phenotype. We report a case of a 42-year-old Sri Lankan male who presented with bilateral OAS and cavernous sinus syndrome, ultimately diagnosed as IgG4-RD through histopathology despite normal serum IgG4 levels.

Case presentation

A 42-year-old Sri Lankan male, employed as a hotel chef, presented to the National Hospital of Sri Lanka (NHSL) with a 6-month history of gradual onset painless right eye ptosis and proptosis, accompanied by progressive monocular visual acuity loss. Three months prior to admission, he developed similar symptoms in the left eye, which worsened significantly over the 3 weeks leading up to his hospitalization. During the first week of admission, he also complained of gradual onset right hemifacial numbness.

His medical history included recently diagnosed poorly controlled diabetes mellitus and well-controlled hypertension. He reported a 2-year history of allergic rhinitis and occasional epistaxis, and a 2-month history of loss of appetite and unintentional weight loss but denied fever, chronic cough, or contact with tuberculosis. There were no features suggestive of connective tissue disease, chronic pancreatitis, or cholecystitis. He was unmarried and denied high-risk sexual behavior or substance abuse.

On examination, the patient appeared ill. Ocular assessment revealed right eye complete ptosis, proptosis, and chemosis. Visual acuity was impaired as no perception of light in the right eye, while visual acuity was 6/36 in the left eye. Pupils were fixed and dilated (6 mm) on the right, while the left pupil was 3 mm and reactive, with a positive relative afferent pupillary defect (RAPD) in the right eye. Fundoscopy showed bilateral optic disc atrophy. There was painless bilateral complete ophthalmoplegia. Sensory testing revealed impaired corneal reflexes and sensory loss in the V1 and V2 distributions on the right side. Other cranial nerves were intact, and the remainder of the neurological and systemic examinations, including assessments for lymphadenopathy and organomegaly, were unremarkable.

The clinical diagnosis was progressive bilateral orbital apex syndrome with right-sided cavernous sinus involvement. Contrast-enhanced MRI brain (Figure 01) revealed an abnormal, T2-hypointense, contrast-enhancing soft-tissue mass in the medial extraconal space of the right orbit, extending up to the orbital apex which displaces the right optic nerve and medial rectus laterally. Right orbital apex crowding and early involvement of the left orbit were seen with lesions extending into bilateral cavernous sinuses. There was widespread involvement of the paranasal sinuses. These lesions were not diffusion-restricted. MR venogram was normal.

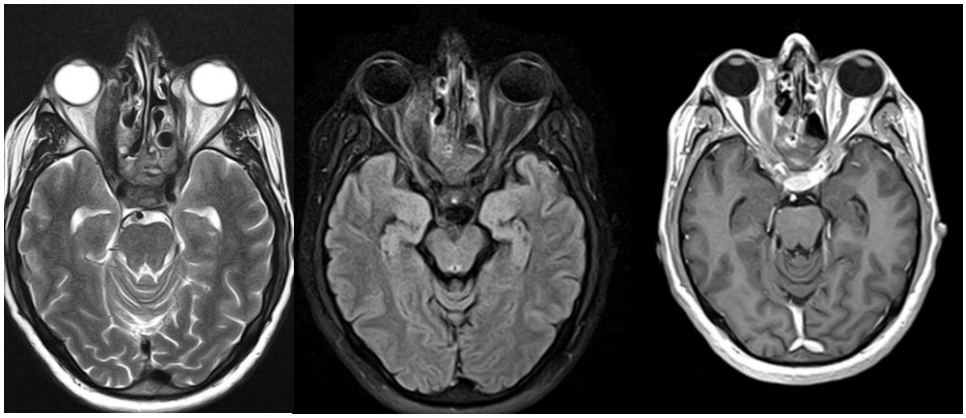

A B C

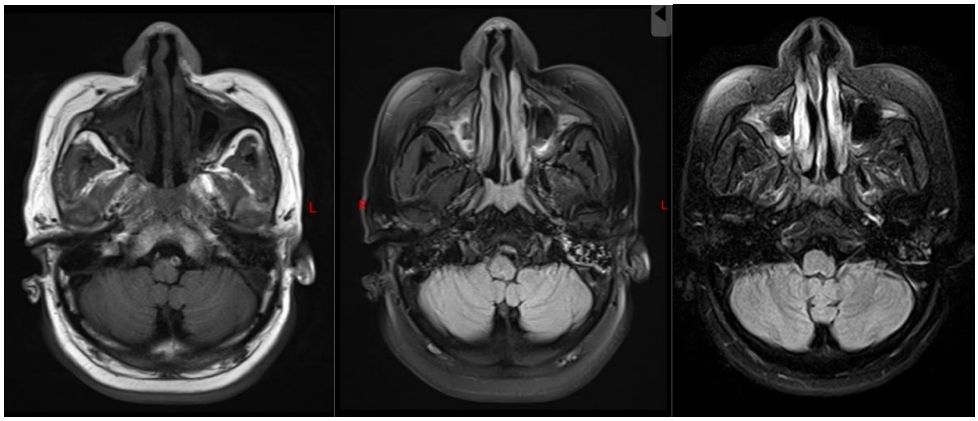

D E F

Figure 01. Contrast-enhanced MRI brain and orbits and maxillary sinuses (A,D- T2 weighted MRI axial cut, B,E- T2 weighted FLAIR axial cut, C,F- T1 post contrast axial cut)

Abnormal T2-hypointense, contrast-enhancing soft-tissue mass in the medial extraconal space of the right orbit, extending up to the orbital apex which displaces the right optic nerve and medial rectus laterally. Right orbital apex crowding and early involvement of the left orbit was seen with lesions extending into bilateral cavernous sinuses. There was widespread involvement of the paranasal sinuses.

Laboratory investigations (Table 1) showed a normal white cell count (6,000/μL), hemoglobin (14 g/dL), and ESR (30 mm/1st hour). C-reactive protein (CRP) was low (7 mg/L). Serum IgG4 was 1.9 g/L (normal range: 0.03–2.0 g/L), and serum ACE and calcium levels were normal. ANA and ANCA (C and P) were negative. Notably, the IgE level was elevated at 570 IU/mL. Mantoux test and chest radiograph were negative for tuberculosis. Imaging of the chest, abdomen, and pelvis (CECT CAP) was normal. Blood picture did not reveal atypical cells. LDH was 126 U/L. TSH was 1.9 mlU/L (normal range: 0.4 – 5.0 mlU/L) and TPO antibody was negative.

Investigation	Result	Reference Range
Hemoglobin	14 g/dL	13.5–17.5 g/dL
White Blood Cells	6,000/µL	4,000–11,000/µL
Platelets	354,000/µL	150,000–450,000/µL
ESR	30 mm/1st hr	<15 mm/1st hr
CRP	7 mg/L	<5 mg/L
Serum IgG4	1.9 g/L	0.03–2.0 g/L
Serum IgE	570 IU/mL	<100 IU/mL
ANA / ANCA	Negative	Negative
Serum ACE	6 U/L	8–52 U/L

Table 1: Summary of laboratory investigations.

Given the suspicion of a granulomatous or inflammatory process, a right orbital tissue biopsy was performed. Histopathology and immunohistochemistry revealed dense fibrosis with a predominant IgG4-positive plasma cell infiltrate and lymphocyte infiltration. The plasma cells showed positivity for IgG4 with a maximum count of 138 per high-power field (HPF) with IgG4/IgG ratio of 80%. The stroma exhibited storiform-like concentric fibrosis and foci of obliterative phlebitis, confirming the diagnosis of IgG4-related disease (Figure 02). TB gene Xpert, fungal culture and pyogenic culture of the biopsy sample were negative.

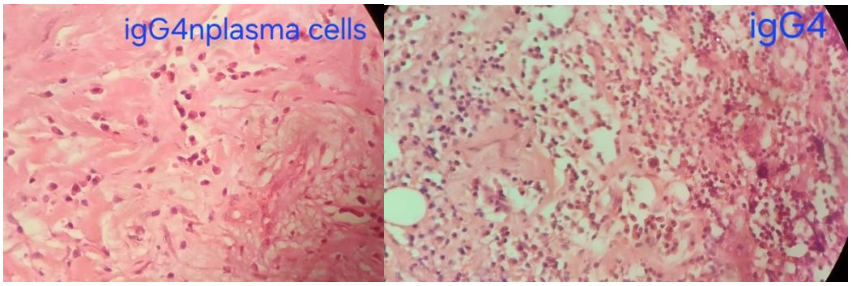

A B

Figure 02. Biopsy immunohistochemistry of right medial orbitotomy

Histopathology and immunohistochemistry revealed dense fibrosis with a predominant IgG4-positive plasma cell infiltrate and lymphocyte infiltration (A). The plasma cells showed positivity for IgG4 with a maximum count of 138 per high-power field (hpf), IgG4/IgG ratio of 80% (B). The stroma exhibited storiform-like concentric fibrosis and foci of obliterative phlebitis, confirming the diagnosis of IgG4-related disease.

The patient was treated with pulse intravenous methylprednisolone (1 g daily for 5 days), followed by a tapering dose of oral prednisolone over 6 weeks. Azathioprine (50 mg twice daily) was initiated as a steroid-sparing agent. He showed marked clinical improvement during the steroid pulses. A follow-up MRI after 3 months demonstrated improving lesions. While the right eye remained blind due to residual optic atrophy, the left eye's vision stabilized and the ophthalmoplegia completely improved.

Discussion and Conclusions

The presented case illustrates an aggressive and atypical manifestation of Immunoglobulin G4-related disease (IgG4-RD), characterized by extensive bilateral orbital, paranasal sinus, and cavernous sinus involvement, ultimately leading to irreversible optic atrophy. This clinical presentation highlights several diagnostic and management challenges, particularly the overlap with other granulomatous and neoplastic processes and the importance of timely histopathological confirmation.

A striking feature of this case is the aggressive "pseudotumor" appearance. IgG4-RD frequently presents as mass-like lesions that can be mistaken for malignancies [5]. While orbital pseudotumors (idiopathic orbital inflammatory syndrome) are well-documented, their classification as IgG4-RD requires specific histologic evidence. In our patient, the mass-like infiltration was not confined to the orbit but extended into the cavernous sinuses and paranasal sinuses. Such extensive, destructive-appearing involvement is rare for IgG4-RD and often leads clinicians toward a diagnosis of lymphoma or GPA [6, 7]. The "pseudotumor" in this case was characterized by T2-hypointense signal on MRI, a hallmark of the dense storiform fibrosis that defines the condition [4].

Bilateral involvement is reported in approximately 40-60% of IgG4-ROD cases, but it usually manifests as dacryoadenitis or extraocular muscle enlargement [3]. Bilateral orbital apex syndrome (OAS) is significantly rarer. The progression from unilateral to bilateral involvement over several months, as seen in our patient, underscores the systemic and progressive nature of the disease. Furthermore, optic nerve involvement is a sight-threatening complication that occurs in less than 20% of IgG4-ROD cases [8]. It can occur via direct infiltration of the nerve

sheath or, more commonly, through compression at the orbital apex by enlarged extraocular muscles or inflammatory masses [8, 9]. In our patient, the rapid progression to bilateral optic atrophy highlights the devastating potential of compressive optic neuropathy in IgG4-RD and the need for urgent treatment to relieve optic nerve compression and prevent irreversible visual loss.

The diagnosis of IgG4-RD has been significantly refined by the 2019 American College of Rheumatology (ACR)/European League Against Rheumatism (EULAR) classification criteria [1]. Our patient met the entry criteria and scored significantly (29 points/ more than 20 points) primarily through the histopathology and immunostaining domain. Histopathology counts 13 points from dense lymphocytic cell infiltrate, storiform fibrosis with obliterative phlebitis and immunostaining counts for 16 points for IgG4/IgG ratio of 80%, plasma cells showed positivity for IgG4 with a maximum count of 138 per high-power field (hpf). Crucially, the patient maintained a near-normal serum IgG4 level (1.9 g/L), a finding observed in approximately 30–40% of biopsy-proven IgG4-RD cases [10, 11]. This underscores that a normal serum IgG4 concentration does not exclude the diagnosis, especially when suggestive histopathology of dense lymphocytic infiltrate, storiform fibrosis, and obliterative phlebitis is present. The elevated serum IgE (570 IU/mL) in our patient is a common but non-specific finding in IgG4-RD, often associated with atopy or multi-organ involvement [12].

This case is particularly important compared to other reported cases of IgG4-ROD because of the combination of three rare features: (1) bilateral OAS with cavernous sinus invasion, (2) a pseudotumor appearance mimicking an aggressive malignancy, and (3) histologically confirmed disease despite normal serum IgG4 levels. Most reported cases of IgG4-related cavernous sinus syndrome are unilateral or associated with pachymeningitis [13, 14]. Our case demonstrates that IgG4-RD can be as aggressive as GPA or lymphoma, rapidly crossing anatomical boundaries to cause permanent neurological damage.

Conclusions

In conclusion, IgG4-RD should be considered in the differential diagnosis of any patient presenting with bilateral orbital apex or cavernous sinus syndromes, even in the absence of elevated serum IgG4 or multi-organ involvement. A high index of suspicion and early biopsy are paramount to preventing permanent neurological damage. Early intervention with high-dose corticosteroids is the standard of care, but the high rate of relapse often necessitates steroid-sparing agents like azathioprine or B-cell depletion therapy with rituximab [15, 16]. This case serves as a reminder that timely diagnosis can be the difference between sight and permanent blindness.

List of abbreviations

- **ACE:** Angiotensin-Converting Enzyme
- **ANA:** Antinuclear Antibody
- **ANCA:** Antineutrophil Cytoplasmic Antibody
- **CRP:** C-Reactive Protein
- **ESR:** Erythrocyte Sedimentation Rate

- **GPA:** Granulomatosis with Polyangiitis
- **HPF:** High-Power Field
- **IgG4-RD:** Immunoglobulin G4-Related Disease
- **IgG4-ROD:** Immunoglobulin G4-Related Ophthalmic Disease
- **LDH:** Lactate Dehydrogenase
- **MRI:** Magnetic Resonance Imaging
- **NHSL:** National Hospital of Sri Lanka
- **OAS:** Orbital Apex Syndrome
- **RAPD:** Relative Afferent Pupillary Defect
- **TSH:** Thyroid Stimulating Hormone
- **TPO:** Thyroid Peroxidase

Declarations

Ethics approval and consent to participate Not applicable. This is a case report and does not report on a clinical trial or experimental study.

Consent for publication Written informed consent was obtained from the patient for publication of this case report and any accompanying images.

Availability of data and materials All data generated or analysed during this study are included in this published article.

Competing interests The authors declare that they have no competing interests.

Funding No funding was received for this study.

Authors' contributions PA, AG AVM and CB were involved in the clinical management and drafting of the manuscript. DW contributed to data collection and literature review. SAG performed the histopathological analysis. GP provided overall supervision. All authors read and approved the final manuscript.

Acknowledgements We would like to thank the staff of the Neurology Unit 3 at NHSL for their support in patient care.

References

1 Wallace ZS, Naden RP, Chari S, et al. The 2019 American College of Rheumatology/European League Against Rheumatism Classification Criteria for IgG4-Related Disease. Arthritis Rheumatol. 2020;72(1):7-19. https://pubmed.ncbi.nlm.nih.gov/31793250/

2 Deshpande V, Zen Y, Chan JK, et al. Consensus statement on the pathology of IgG4-related disease. Mod Pathol. 2012;25(9):1181-1192. https://doi.org/10.1038/modpathol.2012.72

3 Wallace ZS, Deshpande V, Stone JH. Ophthalmic manifestations of IgG4-related disease: Single-center experience and literature review. Semin Arthritis Rheum. 2014;43(6):806-817. https://pubmed.ncbi.nlm.nih.gov/24513111/

4 Fujita A, Buch K, Li B, et al. IgG4-Related Disease of the Head and Neck: CT and MR Imaging Manifestations. Radiographics. 2016;36(7):2174-2191. https://pubmed.ncbi.nlm.nih.gov/23150850/

5 Vercauteren L, et al. IgG4-related pseudotumours: a series of 12 cases and a review of the literature. Pathology. 2022;54(4):450-458. https://pubmed.ncbi.nlm.nih.gov/35221040/

6 Priego G, Majos C, Climent F, et al. Orbital lymphoma: imaging features and differential diagnosis. Insights Imaging. 2012;3(4):337-344. https://pubmed.ncbi.nlm.nih.gov/22695946/

7 Ryu G, et al. Clinical significance of IgG4 in sinonasal and skull base inflammatory pseudotumor. Eur Arch Otorhinolaryngol. 2019;276(8):2251-2258. https://pubmed.ncbi.nlm.nih.gov/31203383/

8 Zhang W, Shao J, Wu J, et al. Optic nerve involvement in immunoglobulin G4-related disease. Exp Ther Med. 2016;12(1):245-250. https://pubmed.ncbi.nlm.nih.gov/27347025/

9 Margo CE, et al. Ophthalmologic Disease in IgG4-Related Disease. In: IgG4-Related Disease. 2024. https://doi.org/10.1007/s10384-024-01072-4

10 Carruthers MN, Khosroshahi A, Augustin T, et al. The diagnostic utility of serum IgG4 concentrations in IgG4-related disease. Ann Rheum Dis. 2015;74(1):14-18. https://pubmed.ncbi.nlm.nih.gov/24651618/

11 Yu X, et al. Serum IgG4 levels in patients with IgG4-related disease: a systematic review and meta-analysis. Rheumatology. 2021;60(11):5020-5030. https://pmc.ncbi.nlm.nih.gov/articles/PMC10729036/

12 Della-Torre E, et al. Prevalence and clinical significance of elevated serum IgE levels in IgG4-related disease. Clin Exp Rheumatol. 2014;32(4):540-545. https://pubmed.ncbi.nlm.nih.gov/24266692/

13 Mayeku J, et al. Immunoglobulin G4-related disease of the cavernous sinus with orbit invasion–A case report. Surg Neurol Int. 2021;12:554. https://pubmed.ncbi.nlm.nih.gov/34877043/

14 Marinelli JP, et al. Manifestations of Skull Base IgG4-Related Disease: A Multi-Institutional Study. Laryngoscope. 2020;130(11):2574-2581. https://pubmed.ncbi.nlm.nih.gov/31841234/

15 Khosroshahi A, Wallace ZS, Choi HK, et al. International Consensus Guidance Statement on the Management and Treatment of IgG4-Related Disease. Arthritis Rheumatol. 2015;67(7):1688-1699. https://pubmed.ncbi.nlm.nih.gov/25809420/

16 Carruthers MN, Topazian MD, Khosroshahi A, et al. Rituximab for IgG4-related disease: a prospective, open-label trial. Ann Rheum Dis. 2015;74(6):1171-1177. https://pubmed.ncbi.nlm.nih.gov/25667206/