Research Square

Preprints are preliminary reports that have not undergone peer review.
They should not be considered conclusive, used to inform clinical practice,
or referenced by the media as validated information.

Dynamic MRI-measured extension-position dorsal CSF space and long-term neurological outcomes after posterior cervical decompression for cervical spondylotic myelopathy: A retrospective cohort study

Shichang Yang
Guangxi University of Chinese Medicine
Guancheng Wang
Guangxi University of Chinese Medicine
Haoran Sun
Guangxi University of Chinese Medicine
Yuanming Zhong
Guangxi University of Chinese Medicine
Bin Yang
yang332203210163.com
Chishui Sub-district Community Health Service Center

Research Article

Keywords: cervical spondylotic myelopathy, dynamic MRI, dorsal cerebrospinal fluid space, positional spinal cord compression

Posted Date: November 26th, 2026

DOI: https://doi.org/10.21203/rs.3.rs-11677890/v1

License: This work is licensed under a Creative Commons Attribution 4.0 International License.
Read Full License

Additional Declarations: No competing interests reported.

Dynamic MRI-measured extension-position dorsal CSF space and long-term neurological outcomes after posterior cervical decompression for cervical spondylotic myelopathy: A retrospective cohort study

Shichang Yang [a], Guancheng Wang [a], Haoran Sun [a], Yuanming Zhong [a], Bin Yang [b,*]

a Guangxi University of Chinese Medicine, Nanning 530001, P. R. China

b Chishui Sub-district Community Health Service Center, Jianyang 641400, Sichuan Province, China

*Corresponding author at: Bin Yang, Chishui Sub-district Community Health Service Center, Jianyang 641400, Sichuan Province, China. E-mail address: yang33220321@163.com

Abstract

Objective: To examine whether hyperextension position dCSF predicts 12-month neurological recovery after CSM posterior decompression and assess the prognostic value of postoperative occult positional cord compression.

Methods: This retrospective single-center cohort included 109 CSM patients receiving posterior cervical decompression. postoperative 3-month neutral and hyperextension dynamic MRI and 12-month clinical follow-up were performed, with dCSF measured at the target level. The primary outcome was mJOA recovery rate; secondary outcomes were NDI and subjective improvement. To eliminate confounding from static compression, analyses focused on the subgroup with neutral dCSF > 2 mm (n = 94), stratified into occult compression (hyperextension dCSF < 1 mm) and non-occult compression groups. Multivariable linear regression was used to identify independent predictors, and sensitivity analysis using absolute mJOA change confirmed the robustness.

Results: Extension dCSF (1.36 ± 0.47 mm) was significantly lower than neutral dCSF (2.71 ± 0.58 mm, $P < 0.001$). Extension dCSF correlated more strongly with the 12-month mJOA recovery rate; extension dCSF and preoperative disease duration were identified as independent predictors. The occult compression group (n = 17) exhibited poorer mJOA improvement ($P < 0.01$), with comparable NDI scores. Patients with occult compression had a longer preoperative disease duration. Sensitivity analysis confirmed stable findings.

Conclusion: Substantial dorsal CSF space loss may occur during neck extension even when satisfactory neutral-position decompression is achieved. Extension dCSF outperforms neutral dCSF for predicting neurological prognosis. Occult dynamic positional compression impairs long-term neurological recovery, which supports the clinical value of dynamic MRI for assessing the functional reserve of the spinal canal.

Keywords: cervical spondylotic myelopathy; dynamic MRI; dorsal cerebrospinal fluid space; positional spinal cord compression

Introduction

Cervical spondylotic myelopathy (CSM) is a neurodegenerative disorder caused by cervical degeneration-induced spinal cord compression, which leads to motor, sensory, and bowel/bladder dysfunction. The condition progresses insidiously, and its incidence rises with advancing age, making early intervention critical[1, 2]. For multilevel CSM, posterior cervical decompression, including laminoplasty and laminectomy with fusion, represents the mainstay of clinical treatment[3]. This procedure indirectly achieves multilevel spinal cord decompression by expanding the sagittal diameter and total volume of the spinal canal to facilitate posterior drift of the cervical spinal cord[4].

However, substantial interindividual variation in long-term postoperative outcomes has been observed in clinical practice, even among patients receiving identical surgical procedures with adequate decompression demonstrated on neutral-position cervical MRI. Some patients suffer from residual neck pain and unsatisfactory neurological recovery, and their symptoms are exacerbated during neck extension [5, 6]. This observation suggests that while posterior decompression relieves primary osseous compression, it may introduce new position-dependent compressive contributors, including epidural scar adhesion, intraspinal soft-tissue herniation, abnormal cervical sagittal alignment, and adjacent segment instability[7, 8]. When the cervical spine is placed in extension, these pathological alterations can occupy the dorsal spinal canal space and cause dynamic loss of the dorsal cerebrospinal fluid (dCSF) space. Accordingly, conventional static neutral-position MRI alone may underestimate occult residual spinal cord compression induced by postural changes.

Dynamic MRI (flexion-extension scanning) acquires sequential images of the cervical spine during flexion and extension, enabling the detection of dynamic compression secondary to postural changes [9]. Previous studies have confirmed that preoperative dynamic MRI can identify positional spinal cord compression and has predictive value for postoperative neurological recovery [5]. However, most existing

literature has focused on the diagnostic performance of preoperative dynamic MRI. Systematic studies applying dynamic MRI to evaluate postoperative decompression quality and delineate the relationship between position-dependent compression and long-term outcomes after posterior cervical decompression remain scarce [5, 10, 11]. It remains unclear whether postoperative extension-position dorsal cerebrospinal fluid space (dCSF) can independently predict neurological recovery compared with conventional neutral-position imaging parameters. Furthermore, it has not been elucidated whether extension-provoked occult positional spinal cord compression confers adverse long-term neurological outcomes even in patients with satisfactory static decompression.

The present study aimed to investigate the predictive effect of extension-position dCSF on 12-month neurological recovery in patients with CSM after posterior cervical decompression, and to analyze the clinical significance of occult positional spinal cord compression for long-term prognosis when adequate decompression was achieved in the neutral position.

Methods

This study was performed in accordance with the principles of the Declaration of Helsinki[12]. Ethical approval was obtained from the Medical Ethics Committee of the First Affiliated Hospital of Guangxi University of Chinese Medicine on 2025-12-18 (Approval No. 2025-080-KY-01). The requirement for informed consent was waived by the Ethics Committee due to the retrospective nature of this study.

Study participants

This study retrospectively collected clinical and imaging data of patients diagnosed with cervical spondylotic myelopathy (CSM) who underwent posterior cervical decompression surgery in our hospital between January 1, 2022, and December 31, 2024. Data were retrieved from the hospital's HIS and PACS systems.

All patients who met the preliminary screening criteria within this period were reviewed. Cases that failed to satisfy the eligibility criteria were excluded stepwise, and a total of 109 patients were finally included. The selection process is shown in Figure 1.

Inclusion criteria were as follows: age ≥ 18 years; diagnosis of CSM confirmed by clinical symptoms, physical signs, and MRI; patients underwent single-door or double-door laminoplasty, or laminectomy with fusion without concomitant anterior decompression; and follow-up cervical MRI in neutral and hyperextension positions was performed at approximately 3 months after surgery.

Exclusion criteria were as follows: acute spinal cord compression secondary to trauma, intraspinal tumors, spinal infection or intraspinal hemorrhage; prior cervical spine surgery; unavailable follow-up dynamic cervical MRI (neutral plus hyperextension views) at approximately 3 months postoperatively; and incomplete key follow-up data with inaccessible neurological function and pain outcome scores.

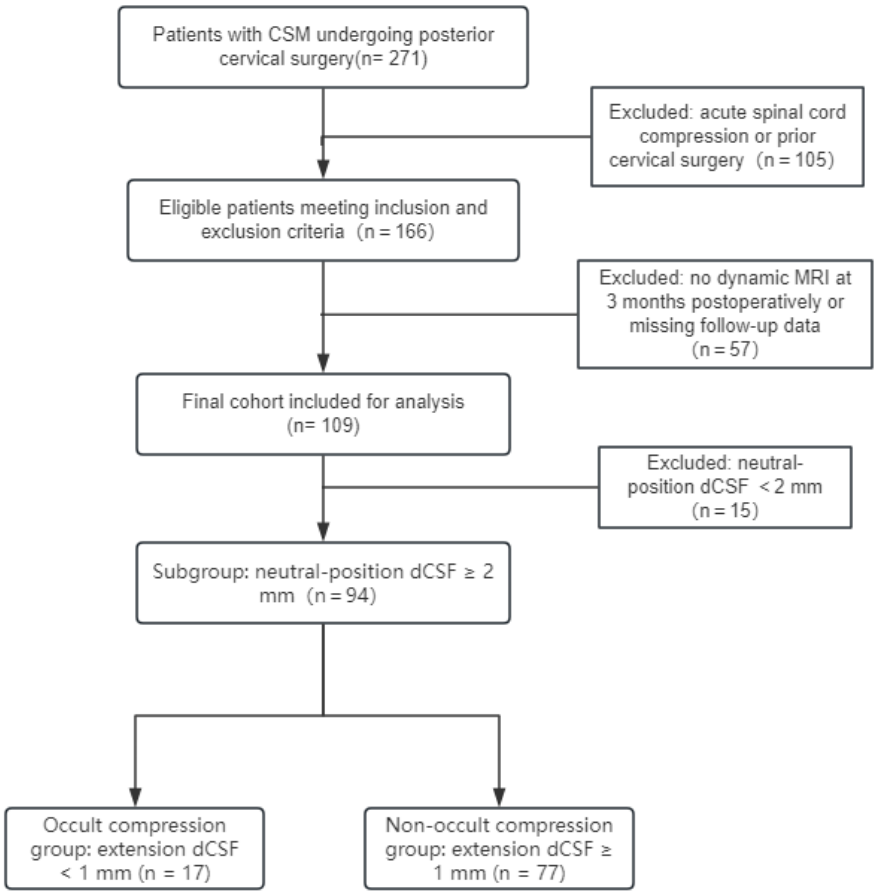

Figure 1. Flowchart of patient selection.

Study design and MRI protocol

All patients underwent preoperative routine 3.0T cervical MRI in the neutral position for preoperative stenosis assessment. Approximately 3 months after surgery, dynamic mid-sagittal T2WI sequences at three positions were acquired, including the neutral position and the maximum hyperextension position within the patient's pain-free range. All positional maneuvers were supervised by radiology technicians to prevent excessive movement that might trigger neurological irritation. Preliminary analyses of our cohort showed that the preflexion dCSF was not significantly associated with clinical outcomes; therefore, only the findings from the neutral and hyperextension positions are reported herein, and preflexion data are not presented in this study[11]. Preoperative axial neutral T2-weighted MRI was used for slice-wise quantitative measurement of the minimal total cerebrospinal fluid space (mtCSF) at each disc level. For patients with multilevel cervical degenerative myelopathy, the target compressed level was defined as the disc level with the smallest mtCSF that correlated with the patient's neurological symptoms, rather than the level with the most severe radiological stenosis[5, 11]. All radiological parameters were measured and analyzed at this target level. Follow-up evaluations including the mJOA score, Neck Disability Index (NDI), subjective clinical improvement, and residual symptoms were performed at 3 and 12 months after surgery.

Outcome measures

The primary outcome was neurological improvement assessed by the recovery rate (RR) of the modified Japanese Orthopaedic Association (mJOA) score at the 12-month postoperative follow-up[13]. An mJOA recovery rate ≥ 50% was defined as achievement of the minimal clinically important difference (MCID)[13]. The mJOA scale evaluates upper extremity motor function, lower extremity motor function, sensation of the extremities and trunk, and bowel and bladder function, with a total

score ranging from 0 to 18. The formula for calculating the mJOA recovery rate was as follows: RR = (postoperative mJOA − preoperative mJOA) / (18 − preoperative mJOA) × 100%[14].

The secondary outcomes included the Neck Disability Index (NDI) and patient-rated subjective clinical improvement[15, 16]. Subjective improvement was graded using a 4-point ordinal scale adapted from previous myelopathy literature: 1 = no improvement, 2 = mild improvement, 3 = marked improvement, 4 = substantial improvement[17]. The 12-month time point was selected for follow-up because neurological function generally plateaus at approximately 1 year after cervical decompression surgery[18].

Imaging examination protocol

All MRI measurements were performed on the picture archiving and communication system (PACS) by two independent observers (a senior spine surgeon and a junior spine surgeon), who were blinded to the clinical outcomes. Inter-observer agreement was assessed using the intraclass correlation coefficient (ICC).

The following parameters were measured on the mid-sagittal T2-weighted images of the target level in the postoperative neutral and hyperextension positions, respectively: dorsal cerebrospinal fluid space (dCSF), defined as the shortest vertical distance from the dorsal surface of the spinal cord to the inner margin of the lamina/ligamentum flavum (or posterior dura mater); ΔdCSF, calculated as postoperative neutral dCSF minus postoperative hyperextension dCSF[11, 19]. ΔdCSF represents the positional change of the subarachnoid cerebrospinal fluid space between the neutral and hyperextension positions. This derived index was proposed in the present study to quantify hyperextension-dependent dynamic dorsal spinal cord compression.Representative neutral and hyperextension MRI scans illustrating the measurement of dorsal CSF space are shown in Fig. 2.

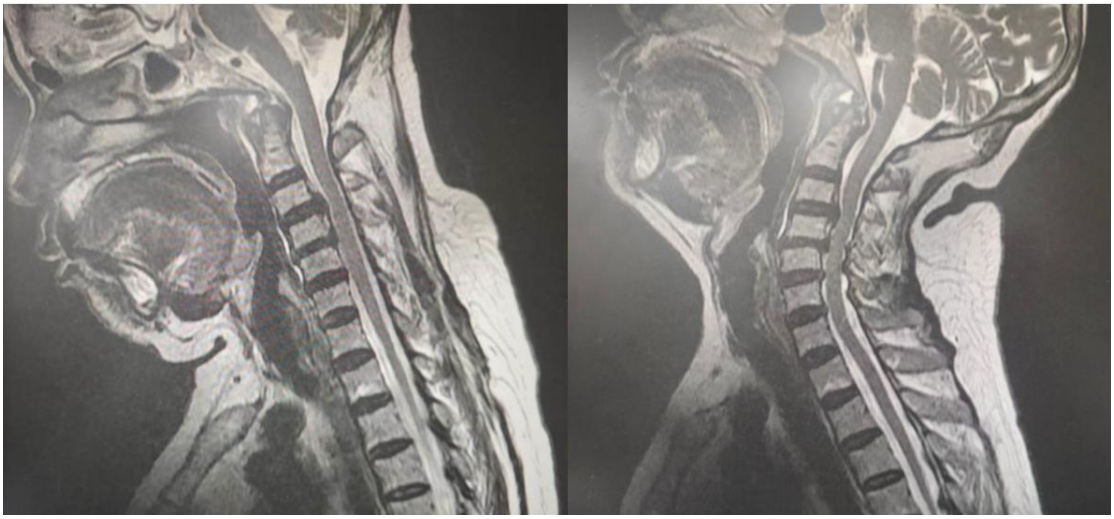

Figure 2. Representative sagittal T2-weighted dynamic MRI of a patient with occult positional compression. Left panel: neutral neck position; right panel: neck extension position. The dorsal cerebrospinal fluid space (dCSF) was measured at the C4–5 index level. Neutral dCSF = 2.7 mm; extension dCSF = 0.2 mm. A marked collapse of the dorsal CSF space was observed during neck extension.

Subgroup analysis

The morphological evaluation concept for subarachnoid stenosis based on the Muhle classification was adopted as the theoretical framework in this study. However, the quantitative dCSF cut-off value used herein was not directly derived from the Muhle classification criteria[20]. Combined with previous literature regarding cervical cerebrospinal fluid space and the preliminary findings of this cohort, a neutral-position dCSF > 2 mm was predefined as the screening threshold for adequate static decompression. This subgroup was selected to eliminate the confounding effect caused by persistent static dorsal spinal cord compression[11, 20].

Within this subgroup, occult positional spinal cord compression was defined as a neutral-position dCSF > 2 mm (indicating adequate decompression and absence of persistent static spinal cord compression on static MRI) accompanied by a hyperextension-position dCSF < 1 mm, which suggests the presence of position-dependent dynamic dorsal spinal cord compression. Patients in this subgroup were divided into an occult compression group and a non-occult compression group

according to the above criteria. Baseline characteristics, radiological parameters, and 12-month postoperative clinical outcomes were compared between the two groups.

Statistical analysis

Statistical analyses were performed with SPSS 26.0. Continuous variables were assessed for normality and summarized as mean ± standard deviation (normal distribution) or median (interquartile range) (non-normal distribution). Between-group comparisons of continuous variables were carried out using the independent samples t-test or Mann-Whitney U test, and paired t-tests were used for paired data. Categorical variables were reported as n (%), with between-group comparisons by χ^2 test or Fisher's exact test. Inter-observer agreement for radiological measurements was evaluated using the intraclass correlation coefficient (ICC). Pearson or Spearman correlation was used for correlation analyses. Multiple linear regression was built with the 12-month mJOA recovery rate as the outcome. After multicollinearity checking, backward stepwise regression ($P > 0.10$ for variable removal) was used for exploratory predictor selection. Sensitivity analysis was performed to reduce inherent bias and confirm result robustness. All tests were two-tailed, and $P < 0.05$ indicated statistical significance. This was an observational retrospective cohort study. No propensity weighting or matching was used; confounders were adjusted via multivariable regression, with disease duration (an imbalanced baseline factor) included in the primary model. Thus, these findings only support associative inference rather than causal conclusions.

Results

Baseline demographic characteristics

A total of 109 patients with complete clinical and imaging data who met the inclusion and exclusion criteria were enrolled in this study. The median age was 57.00 years (interquartile range [IQR], 47.00-66.00 years), including 47 males (43.1%) and 62 females (56.9%). Body mass index (BMI) was normally distributed with a

mean value of 24.51 ± 3.26 kg/m². Pre-operative disease duration showed a skewed distribution, with a median of 20.00 months (IQR, 15.00-25.00 months). The median pre-operative modified Japanese Orthopaedic Association (mJOA) score was 13.00 (IQR, 13.00-14.00), indicating moderate neurological impairment in most patients at baseline. The median pre-operative C2-C7 Cobb angle was 15.00° (IQR, 9.00-22.00°), reflecting substantial inter-individual variability in cervical sagittal alignment. Regarding surgical procedures, 76 patients (69.7%) underwent single-door laminoplasty, 22 patients (20.2%) received double-door laminoplasty, and 11 patients (10.1%) were treated with laminectomy and fusion. The most frequently involved index segment was C5/6 (n = 50, 45.9%), followed by C4/5 (n = 26, 23.9%) and C6/7 (n = 24, 22.0%). C3/4 and C7/T1 were less commonly affected, accounting for 6.4% and 1.8% of cases, respectively. Baseline demographic, clinical, and radiological characteristics, as well as index-segment distribution for the overall cohort, are summarized in Table 1.

Table 1. Overview of Baseline Data of Patients and Distribution of Target Segments

Variable	Total cohort	Occult-compression group	Non-occult-compression group	*P*-value
	(n = 109)	**(n = 17)**	**(n = 77)**	
Age, median (IQR), years	57.00 (47.00-66.00)	58.00 (48.00-67.00)	56.00 (46.00-65.00)	0.612
Sex, n (%)				0.747
Male	47 (43.1)	8 (47.1)	32 (41.6)	
Female	62 (56.9)	9 (52.9)	45 (58.4)	
BMI, mean ± SD, kg/m²	24.51 ± 3.26	24.72 ± 3.41	24.43 ± 3.18	0.741
Pre-operative disease duration, median (IQR), months	20.00 (15.00-25.00)	27.00 (22.00-29.00)	18.00 (13.00-22.00)	**< 0.001**
Pre-operative mJOA score, median (IQR)	13.00 (13.00-14.00)	13.00 (12.00-14.00)	13.00 (13.00-14.00)	0.226
C2-C7 Cobb angle, median (IQR), °	15.00 (9.00-22.00)	16.00 (10.00-23.00)	14.00 (8.00-21.00)	0.473
Index segment, n (%)				0.834
C3/4	7 (6.4)	2 (11.8)	4 (5.2)	
C4/5	26 (23.9)	4 (23.5)	18 (23.4)	
C5/6	50 (45.9)	8 (47.1)	37 (48.1)	
C6/7	24 (22.0)	3 (17.6)	16 (20.8)	
C7/T1	2 (1.8)	0 (0.0)	2 (2.6)	

postoperative dCSF measurements

All 109 patients completed dynamic cervical MRI examinations in neutral and hyperextension positions at 3 months after surgery. Two independent observers blinded to clinical outcomes identified the target level for each patient, and inter-observer agreement for target level selection was assessed using Cohen's Kappa coefficient (Kappa = 0.71). After reaching consensus on the target level, the two observers independently measured the dorsal cerebrospinal fluid space (dCSF) at postoperative neutral and hyperextension positions on mid-sagittal T2WI images at the target level. Inter-observer reliability for dCSF measurements was calculated using the two-way random-effects intraclass correlation coefficient (ICC = 0.87, 95% CI: 0.78–0.93). Inter-observer agreement was good for both target level selection and dCSF quantification. ΔdCSF, calculated as neutral-position dCSF minus hyperextension-position dCSF, was computed to quantify the reduction of dorsal cerebrospinal fluid space during neck hyperextension.

The postoperative neutral dCSF was 2.71 ± 0.58 mm [median 2.70 (2.40–3.00) mm], hyperextension dCSF was 1.36 ± 0.47 mm [median 1.40 (1.10–1.70) mm], and ΔdCSF was 1.35 ± 0.55 mm [median 1.40 (1.00–1.70) mm], ranging from −0.1 to 2.6 mm. The paired t-test showed that hyperextension dCSF was significantly lower than neutral dCSF ($t = 25.55$, $P < 0.001$; mean difference = 1.35 mm, 95% CI: 1.25–1.45 mm). These findings indicated that even with satisfactory static decompression on MRI after posterior cervical decompression, neck hyperextension could induce variable narrowing of the dorsal cerebrospinal fluid space, and some patients were at risk of position-dependent occult dorsal spinal cord compression.The distribution of dorsal CSF space in neutral and hyperextension positions across the cohort is presented in Fig. 3.

Within the subgroup with neutral dCSF > 2 mm, comparisons were performed between the occult compression group and the non-occult compression group. The ΔdCSF was 1.88 ± 0.40 mm in the occult compression group and 1.38 ± 0.43 mm in the non-occult compression group. ΔdCSF was significantly higher in the occult

compression group (t = 4.38, P < 0.001, Cohen's d = 1.17), indicating that patients in this group had not only reduced absolute hyperextension dCSF values but also a greater magnitude of positional cerebrospinal fluid space loss.

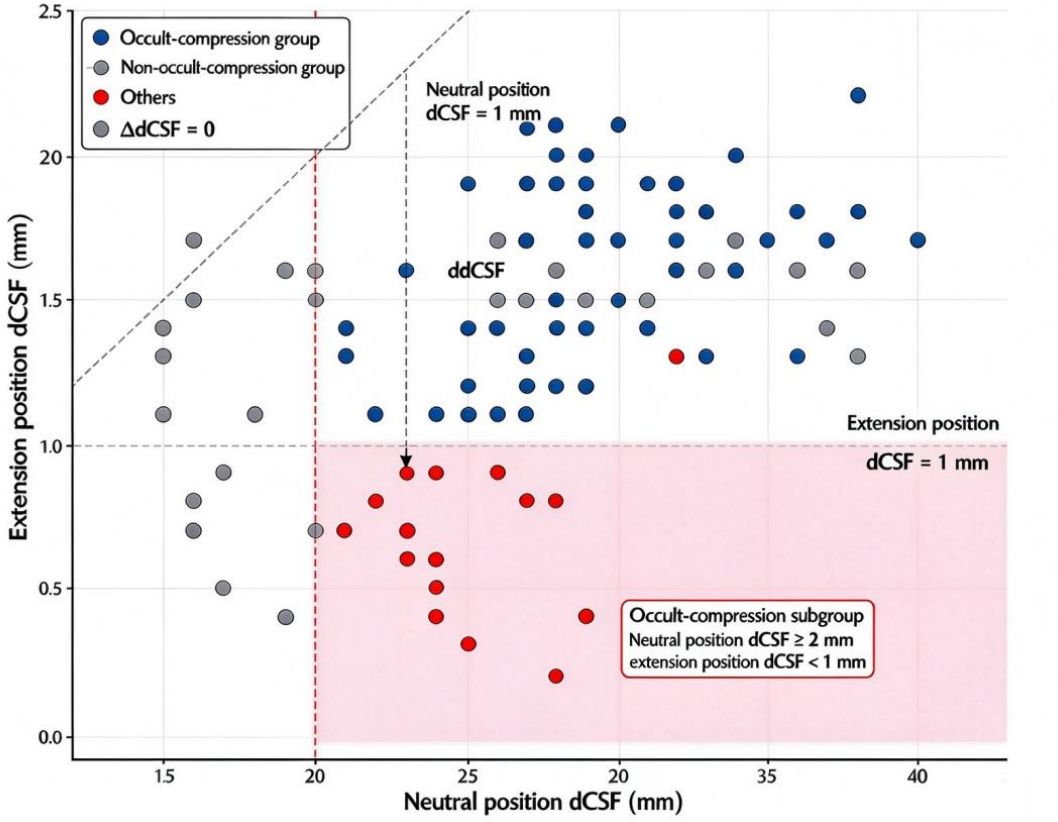

Figure 3. Scatter plot of neutral- and extension-position dCSF on 3-month-postoperative dynamic MRI after posterior cervical decompression for cervical spondylotic myelopathy.

Vertical red dashed line: neutral position dCSF = 2 mm; horizontal blue dashed line: extension-position dCSF = 1 mm. Red shaded area denotes the occult-compression subgroup (neutral position dCSF > 2 mm, extension-position dCSF < 1 mm). Gray diagonal dashed line: ΔdCSF = 0; distance from this diagonal indicates the magnitude of extension-provoked dCSF loss. dCSF, dorsal cerebrospinal fluid space.

Neurological improvement

All three primary outcome measures demonstrated significant postoperative

improvement. For neurological function, the mean preoperative mJOA score was 13.08 ± 1.12, which increased to 15.42 ± 1.14 at 3 months postoperatively and 16.33 ± 1.35 at 12 months postoperatively (preoperative vs 3 months: $t = -14.224$, $P < 0.001$; preoperative vs 12 months: $t = -18.773$, $P < 0.001$; 3 months vs 12 months: $t = -6.751$, $P < 0.001$). The mean mJOA recovery rate at 12 months was 64.02 ± 29.54%, and 86 patients (79.6%) achieved the MCID (recovery rate ≥ 50%).

Regarding neck-related disability, the mean NDI was 19.14 ± 5.01% at 3 months postoperatively and decreased to 12.76 ± 3.62% at 12 months postoperatively (3 months vs 12 months: $t = 12.794$, $P < 0.001$), indicating sustained improvement in neck function.

Statistical testing was not performed for subjective clinical improvement; only frequency distribution was described. Among the 109 patients with complete 12-month follow-up data, 28 (25.7%) reported substantial improvement (score 4), 57 (52.3%) marked improvement (score 3), 20 (18.3%) mild improvement (score 2), and only 4 (3.7%) no improvement (score 1). No patient reported symptom deterioration.

Univariate correlation analysis revealed that neutral-position dCSF was positively correlated with the 12-month mJOA recovery rate ($R = 0.340$, $P < 0.001$, Fig. 4A). Hyperextension-position dCSF also showed a significant positive correlation with the mJOA recovery rate ($R = 0.360$, $P < 0.001$, Fig. 4B). No significant correlations were observed between dCSF (in either position) and NDI (neutral: $R = -0.025$, $P = 0.798$; hyperextension: $R = 0.126$, $P = 0.192$) or subjective improvement (neutral: $\rho = -0.115$, $P = 0.234$; hyperextension: $\rho = -0.037$, $P = 0.704$).

Comparison of regression slopes for mJOA recovery rate showed that the correlation coefficient and regression slope were slightly greater for hyperextension dCSF. After adjustment for confounders in multivariable regression, only hyperextension dCSF remained an independent predictor, suggesting its superior prognostic value.

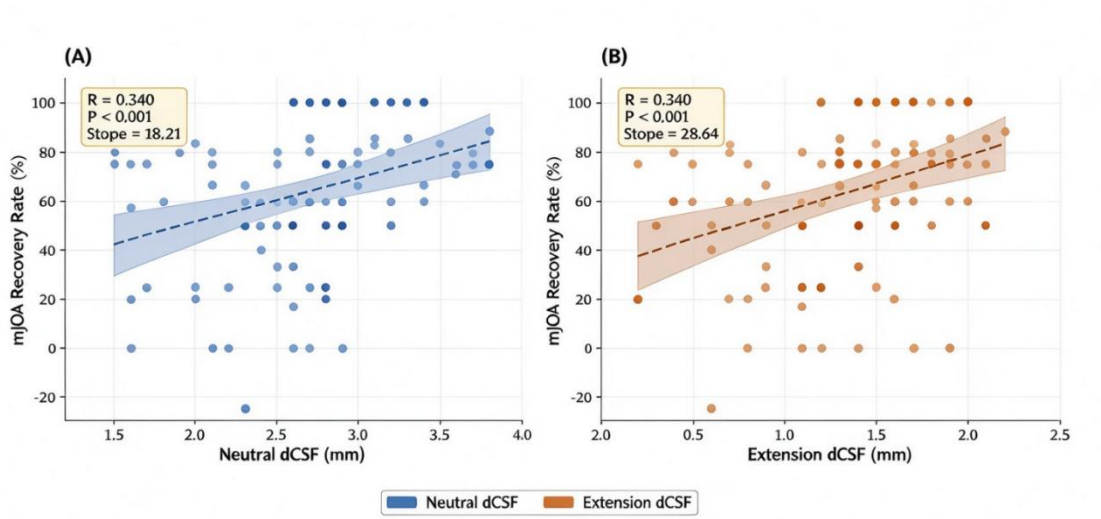

Figure 4. Correlations between postoperative dorsal cerebrospinal fluid space (dCSF) and the 12-month mJOA recovery rate. (A) Neutral-position dCSF; (B) hyperextension-position dCSF. The dashed line represents the linear regression fit within the 95% confidence interval (shaded area).

Factors associated with neurological prognosis

Backward stepwise regression was used for exploratory variable selection. This approach was applied solely to identify associated factors, and no clinical prediction model was constructed in this study. To identify independent predictors of the 12-month postoperative mJOA recovery rate, candidate independent variables were predefined based on prior literature and pathophysiological mechanisms. Age, sex, BMI, C2–C7 Cobb angle, hyperextension-position dCSF, and preoperative disease duration were entered into the multiple linear regression model, with backward stepwise selection (removal criterion: $P > 0.10$)[14]. All predefined candidates were included in the initial model. Multicollinearity testing showed VIF < 1.5 for all variables, indicating no substantial multicollinearity. After adjustment for confounders, exploratory backward stepwise analysis revealed that hyperextension-position dCSF was independently and positively associated with the 12-month mJOA recovery rate, whereas disease duration was independently and negatively associated with this outcome (Table 2). Each 1-mm increment in hyperextension-position dCSF

corresponded to an average increase of 14.26 percentage points in the mJOA recovery rate; each additional month of disease duration was associated with an average decrease of 1.17 percentage points in the mJOA recovery rate.

Table 2. Multivariable linear regression analysis for the 12-month postoperative mJOA recovery rate

Variable	Regression coefficient (B)	Standard error (SE)	Standardized coefficient (β)	95% CI for B	P value
Constant	1.724	0.491	—	0.752–2.696	< 0.001
Hyperextension-position dCSF	0.919	0.389	0.238	0.150–1.688	0.02
Disease duration (months)	−0.078	0.029	−0.276	−0.135–−0.022	0.007

Sensitivity analysis

Sensitivity analysis was performed to verify the robustness of the primary findings. The outcome was replaced with the absolute mJOA change (ΔmJOA = 12-month postoperative mJOA − preoperative mJOA), and the preoperative mJOA score was excluded from the refitted regression model to eliminate potential bias from mathematical coupling. The sensitivity analysis demonstrated a significant positive correlation between hyperextension-position dCSF and ΔmJOA ($r = 0.378$, $P < 0.001$). After removing mathematical coupling by using ΔmJOA as the outcome, the direction and statistical significance of the associations for hyperextension-position dCSF and disease duration remained consistent with the primary analysis (Table 3), supporting the robustness of the main results.

Table 3. Multivariable linear regression with absolute mJOA change as the outcome

Variable	Unstandardized B	SE	Standardized β	95% CI for B	P
Constant	3.606	0.975	—	1.673 ~ 5.539	<0.001
Disease duration (months)	−0.078	0.028	−0.276	−0.135 ~ −0.022	0.007
Extension dCSF (mm)	0.919	0.388	0.238	0.150 ~ 1.688	0.02

Subgroup analysis

A subgroup of patients with neutral-position dCSF > 2 mm was selected from the overall cohort (n = 94), and 15 patients with neutral-position dCSF ≤ 2 mm were excluded from this subgroup. Patients with hyperextension-position dCSF < 1 mm were classified into the occult positional spinal cord compression group, while those with hyperextension-position dCSF ≥ 1 mm were assigned to the non-occult compression group. This subgroup consisted of 77 patients in the non-occult compression group and 17 patients in the occult compression group.

Baseline characteristics including age, sex distribution, body mass index (BMI), preoperative modified Japanese Orthopaedic Association (mJOA) score, and C2–C7 Cobb angle were comparable between the two groups (all P > 0.05)(Table 1). Patients in the occult compression group exhibited a longer disease duration than those in the non-occult compression group (median, 27.0 months vs 18.0 months, P < 0.001). Significant intergroup differences were also observed in neutral-position dCSF and ΔdCSF (both P < 0.001). Given the imbalance in preoperative disease duration at baseline, which represents a potential source of observational bias, caution should be exercised when interpreting subgroup prognostic differences; such outcomes cannot be fully attributed to occult positional compression.

Within the restricted subgroup with neutral-position dCSF > 2 mm (n = 94), patients were divided into the occult compression group (n = 17) and the non-occult compression group (n = 77). There were no significant between-group differences in age, sex, BMI, preoperative mJOA score, or C2–C7 Cobb angle (all P > 0.05, Table 1). The occult compression group had a longer preoperative disease duration (median, 27.0 months vs 18.0 months, P < 0.001) and a larger ΔdCSF (P < 0.001). At 12 months after surgery, the occult compression group showed lower mJOA score, ΔmJOA, and mJOA recovery rate than the non-occult compression group (all P < 0.01, Table 4). No significant differences were detected in the 12-month NDI score or NDI improvement between the two groups (all P > 0.05, Table 4).

Table 4. Comparison of 12-month postoperative outcome measures between the

occult compression group and the non-occult compression group

Outcome	Occult compression (n=17)	Non-occult compression (n=77)	Z	P
12-month mJOA score	16 (14–16)	17 (16–18)	−3.65	0.0002
ΔmJOA (absolute improvement)	3 (2–3)	3 (2–5)	−2.69	0.006
mJOA recovery rate (%)	50 (33–60)	75 (50–100)	−3.42	0.0005
12-month NDI score	10 (8–14)	12 (11–15)	−1.57	0.116

Discussion

Posterior decompression enlarges the sagittal diameter and total volume of the spinal canal to allow posterior drift of the spinal cord and indirectly relieve ventral cord compression. However, this procedure cannot eliminate position-dependent compressive factors. This study showed that the mean postoperative neutral-position dCSF was 2.71 mm, indicating adequate static cerebrospinal fluid reserve within the canal. Nevertheless, the hyperextension-position dCSF decreased markedly to 1.36 mm, with a mean positional space loss of 1.35 mm (approximately 50% reduction). The paired t-test confirmed a highly significant difference in dCSF between the two positions. These findings indicate that neck hyperextension induces secondary reduction of effective canal volume. Dynamic herniation of intraspinal soft tissues, dural scar adhesion and folding, abnormal cervical sagittal alignment, and adjacent segment instability may occupy the dorsal canal space during hyperextension, leading to positional loss of cerebrospinal fluid space. This observation supports that radiographically adequate decompression on static MRI does not guarantee functionally adequate decompression. Static neutral imaging alone is insufficient for comprehensive evaluation of postoperative decompression quality, whereas dynamic MRI better reflects the true functional reserve of the spinal canal. Endo et al.[21] previously reported that the cervical spinal cord and cerebrospinal fluid space change substantially with cervical positioning, with the most prominent reduction of the dorsal CSF space in hyperextension. Their findings are consistent with ours and further suggest that evaluation solely based on postoperative neutral MRI carries a risk of overestimating the actual functional reserve of the spinal canal. Li et al.[22]

also noted paraspinal muscle-mediated dynamic spinal cord compression after laminectomy, which worsens during flexion and extension. Incorporating dynamic MRI into assessment protocols and optimizing decompression strategies may improve patient outcomes. Distinct from those studies focusing mainly on preoperative evaluation, the present study extended dynamic MRI assessment to postoperative follow-up. By focusing on postoperative hyperextension dCSF and quantitatively characterizing position-related CSF space loss after posterior decompression, this work provides objective evidence for the clinical application of postoperative dynamic imaging assessment.

Correlation analyses showed that the correlation coefficient between hyperextension-position dCSF and the 12-month mJOA recovery rate (R = 0.360) was slightly higher than that for neutral-position dCSF (R = 0.348). Meanwhile, the regression slope for hyperextension-position dCSF (22.64) was larger than that for neutral-position dCSF (18.21), indicating that each unit change in hyperextension-position dCSF exerted a stronger predictive effect on postoperative neurological recovery. After adjusting for confounders including sex, age, disease duration, BMI and C2–C7 Cobb angle, hyperextension-position dCSF was retained as an independent predictor of neurological recovery in the multivariable linear regression model, while neutral-position dCSF was removed during stepwise selection. Most previous studies of posterior cervical decompression evaluated postoperative decompression quality and predicted neurological outcomes based on neutral-position dCSF. Some reported correlations between neutral-position dCSF and postoperative mJOA improvement, whereas others suggested limited prognostic performance of static neutral imaging parameters, leading to heterogeneous conclusions across studies[23-25]. A plausible explanation is that the neutral position only reflects the anatomical canal space at rest and cannot capture dynamic compressive effects induced by positional changes during daily activities[5, 26, 27]. By comparing the predictive performance of dCSF measured at the two positions, the present study found that only hyperextension-position dCSF remained an independent predictor in multivariable regression. This finding aligns with reports from Shin, Baram and

colleagues, which demonstrated that position-dependent compression identified by dynamic imaging offers superior prognostic discrimination compared with static radiological indices[5, 11]. Sensitivity analysis using absolute ΔmJOA as the outcome was performed to exclude mathematical coupling bias inherent to the mJOA recovery rate formula. The positive predictive association between hyperextension-position dCSF and neurological recovery persisted, further supporting the robustness of our main findings.

To eliminate confounding effects from static dorsal compression, a restricted subgroup analysis was performed among patients with postoperative neutral position dCSF > 2 mm from the overall cohort, focusing on the clinical implications of position-dependent occult dynamic compression. The occult compression subgroup (hyperextension position dCSF < 1 mm) comprised 17 patients, accounting for 18.1% of this subgroup. Compared with the non-occult compression group, the occult compression group showed not only lower absolute hyperextension dCSF values but also a substantially greater magnitude of positional CSF space loss (ΔdCSF, 1.88 mm vs 1.38 mm; Cohen's d = 1.17, indicating a large effect size). In terms of 12-month postoperative outcomes, the occult compression group exhibited significantly worse mJOA scores, ΔmJOA values, and mJOA recovery rates relative to the non-occult compression group.

Subgroup analysis indicated that dCSF measured on neutral-position MRI alone was insufficient for complete evaluation of postoperative spinal cord compression. Even when patients maintained satisfactory CSF space at the neutral-position (dCSF > 2 mm), collapse of the CSF space during neck hyperextension with occult positional compression was associated with markedly limited neurological recovery. This pattern was observed only for the neurological metric mJOA; no intergroup difference was found for neck-related disability (NDI), suggesting that this occult compression predominantly affects long-tract spinal cord function rather than cervical pain. Previous clinical studies have also noted discordance between objective neurological recovery and symptomatic improvement under dynamic cervical compression[5]. Notably, disease duration was imbalanced at baseline between the two subgroups.

Although disease duration was adjusted for in multivariable regression, this finding only supports an associative relationship and cannot establish causality between occult positional compression and poor neurological recovery.

Both multivariable regression and sensitivity analysis consistently demonstrated that disease duration was an independent negative predictor of postoperative neurological recovery; longer duration was associated with less favourable neurological improvement. Subgroup analysis further showed that the median preoperative disease duration was 27 months in the occult compression group, which was significantly longer than 18 months in the non-occult compression group. Prior studies have also reported that prolonged preoperative disease duration correlates with poor neurological recovery after CSM surgery, mainly attributed to parenchymal spinal cord injury induced by chronic compression[14]. A long disease course indicates sustained exposure of the spinal cord to chronic compression and an ischaemic and hypoxic microenvironment, which may trigger irreversible grey and white matter injury and exhaust intrinsic neurological reserve[28]. Nevertheless, whether preoperative disease duration increases the risk of postoperative dynamic compression by promoting pathological remodelling of intraspinal soft tissues has not been previously investigated[26]. Chronic compression can trigger secondary intraspinal pathological changes, including epidural fibrosis, scar proliferation and ligamentum flavum hypertrophy. These lesions may occupy the effective canal space during cervical motion and raise the risk of position-dependent dynamic compression[26]. Our findings suggest that early surgical intervention may not only preserve the recovery potential of the spinal cord but also reduce the risk of postoperative occult dynamic compression.

This study has several limitations. First, as a retrospective cohort study, it can only reveal associations between variables rather than establish definitive causality, and some unmeasured confounders may inevitably exist. Second, this was a single-center study with a limited source of participants; therefore, the generalizability of the findings is restricted, and further validation in large multicenter cohorts is warranted. Third, the occult compression subgroup included only 17 patients, which

yielded low statistical power. Conclusions regarding this subgroup should be interpreted cautiously. Fourth, dynamic cervical MRI performed at 3 months after surgery was used to characterize the postoperative spinal canal status in this study. Whether imaging findings at this time point represent long-term dynamic canal features remains unclear, and longer longitudinal follow-up is required to clarify the temporal changes in dCSF over time.

Conclusion

This study demonstrated that after posterior cervical decompression, neck hyperextension can significantly reduce the dorsal cerebrospinal fluid space even when neutral-position MRI shows adequate decompression. postoperative hyperextension-position dCSF was an independent predictor of neurological recovery, with better prognostic performance than neutral-position dCSF. Early identification and management of occult positional compression may help improve long-term neurological outcomes in patients with CSM.

Ethics approval and consent to participate

This retrospective cohort study was approved by the Medical Ethics Committee of the First Affiliated Hospital of Guangxi University of Chinese Medicine on 2025-12-18 (Approval No. 2025-080-KY-01). The requirement for written informed consent was waived owing to the retrospective study design using de-identified clinical data.

Funding

This work was supported by the Regional Science Fund of National Natural Science Foundation of China (Grant No. 82260942).

Data Availability

The datasets used and/or analyzed during the current study are available from the

corresponding author on reasonable request.

Publication Consent

Not applicable.

Conflicts of Interest

The authors declare no conflicts of interest.

Author Contributions

S.Y. and Y.Z. conceived and designed the study. S.Y., G.W., and H.S. collected and analyzed the data. S.Y. drafted the manuscript. Y.Z. critically revised the manuscript. All authors read and approved the final manuscript.

References

1. Horak T, Horakova M, Kerkovsky M, Dostal M, Hlustik P, Valosek J, et al. Evidence-based commentary on the diagnosis, management, and further research of degenerative cervical spinal cord compression in the absence of clinical symptoms of myelopathy. Front Neurol. 2024;15:1341371. Epub 20240510. doi: 10.3389/fneur.2024.1341371. PubMed PMID: 38798708; PubMed Central PMCID: PMCPMC11116587.
2. Nouri A, Tessitore E, Molliqaj G, Meling T, Schaller K, Nakashima H, et al. Degenerative Cervical Myelopathy: Development and Natural History [AO Spine RECODE-DCM Research Priority Number 2]. Global Spine J. 2022;12(1_suppl):39s–54s. doi: 10.1177/21925682211036071. PubMed PMID: 35174726; PubMed Central PMCID: PMCPMC8859703.
3. Weinberg DS, Rhee JM. Cervical laminoplasty: indication, technique, complications. J Spine Surg. 2020;6(1):290–301. doi: 10.21037/jss.2020.01.05. PubMed PMID: 32309667; PubMed Central PMCID: PMCPMC7154346.
4. Lu CB, Yang XJ, Wu JC, Lin YZ, Sang HX. Clinical Investigation of the Association of Opening Size with Sagittal Canal Diameter Based on Single-Door Cervical Laminoplasty. Med Sci Monit. 2019;25:7370–5. Epub 20191001. doi: 10.12659/msm.919485. PubMed PMID: 31571675; PubMed Central PMCID: PMCPMC6788323.
5. Baram A, El Choueiri J, Brembilla C, Pellicanò F, Rossi L, Cosmo LD, et al. Dynamic MRI in Degenerative Cervical Myelopathy: A Systematic Review of Radiological Markers, Correlations, and Outcomes. J Clin Med. 2025;15(1). Epub 20251229. doi:

10.3390/jcm15010265. PubMed PMID: 41517513; PubMed Central PMCID: PMCPMC12787212.
6. Bhalla A, Rolfe KW. Inadequate Surgical Decompression in Patients with Cervical Myelopathy: A Retrospective Review. Global Spine J. 2016;6(6):542–7. Epub 20151201. doi: 10.1055/s-0035-1569463. PubMed PMID: 27555995; PubMed Central PMCID: PMCPMC4993611.
7. Evans LT, Lollis SS. Dynamic Compression of the Spinal Cord by Paraspinal Muscles following Cervical Laminectomy: Diagnosis Using Flexion-Extension MRI. Case Rep Radiol. 2015;2015:275623. Epub 20150423. doi: 10.1155/2015/275623. PubMed PMID: 25984378; PubMed Central PMCID: PMCPMC4423003.
8. Kuraishi K, Hanakita J, Takahashi T, Minami M, Mori M, Watanabe M. Remarkable epidural scar formation compressing the cervical cord after osteoplastic laminoplasty with hydroxyapatite spacer. J Neurosurg Spine. 2011;15(5):497–501. Epub 20110812. doi: 10.3171/2011.6.Spine10930. PubMed PMID: 21838513.
9. Walter WR, Alizai H, Bruno M, Portugal S, Burke CJ. Real-time dynamic 3-T MRI assessment of spine kinematics: a feasibility study utilizing three different fast pulse sequences. Acta Radiol. 2021;62(1):58–66. Epub 20200331. doi: 10.1177/0284185120913000. PubMed PMID: 32233646.
10. Dave BR, Anil A, Agrawal S, Sagar M, Dave MB, Panthackel M, et al. Prospective Analysis of Day-One postoperative MRI Following Cervical Decompression for Cervical Myelopathy: Insights into Residual Compression and Signal Changes. Cureus. 2025;17(9):e92699. Epub 20250919. doi: 10.7759/cureus.92699. PubMed PMID: 41122617; PubMed Central PMCID: PMCPMC12536379.
11. Shin JJ, Yoo SJ, Kim TW, So JY, Jeong WJ, Lee MH, et al. Radiological and Clinical Significance of Cervical Dynamic Magnetic Resonance Imaging for Cervical Spondylotic Myelopathy. Neurospine. 2024;21(2):443–54. Epub 20240630. doi: 10.14245/ns.2448166.083. PubMed PMID: 38955522; PubMed Central PMCID: PMCPMC11224733.
12. World Medical Association Declaration of Helsinki: ethical principles for medical research involving human subjects. Jama. 2013;310(20):2191–4. doi: 10.1001/jama.2013.281053. PubMed PMID: 24141714.
13. Chen G, Lin C, Zhu Z, Tong K, Li S, Chen H, et al. Increased blood flow of spinal cord lesion after decompression improves neurological recovery of degenerative cervical myelopathy: an intraoperative ultrasonography-based prospective cohort study. Int J Surg. 2023;109(5):1149–57. Epub 20230501. doi: 10.1097/js9.0000000000000361. PubMed PMID: 36999826; PubMed Central PMCID: PMCPMC10389533.
14. Guo S, Lin T, Wu R, Wang Z, Chen G, Liu W. The Pre-Operative Duration of Symptoms: The Most Important Predictor of postoperative Efficacy in Patients with Degenerative Cervical Myelopathy. Brain Sci. 2022;12(8). Epub 20220817. doi: 10.3390/brainsci12081088. PubMed PMID: 36009151; PubMed Central PMCID: PMCPMC9405785.
15. Kalsi-Ryan S, Singh A, Massicotte EM, Arnold PM, Brodke DS, Norvell DC, et al. Ancillary outcome measures for assessment of individuals with cervical spondylotic

myelopathy. Spine (Phila Pa 1976). 2013;38(22 Suppl 1):S111–22. doi: 10.1097/BRS.0b013e3182a7f499. PubMed PMID: 23963009.
16. Tamai K, Terai H, Terakawa M, Takahashi S, Suzuki A, Nakamura H. Open-Door Cervical Laminoplasty Using Instrumentation of Every Level Versus Alternate Levels: A Multicenter, Randomized Controlled Trial. J Bone Joint Surg Am. 2025;107(2):144–51. Epub 20241121. doi: 10.2106/jbjs.24.00245. PubMed PMID: 39812723.
17. Noufal Y, Richter M, Hartung P, Schmitz F, Fröhlich M, Drees P, et al. In Cervical Myelopathy: Clinical Effect of the Posterior Myelon Shifting After Dorsal Decompression and Instrumentation. J Clin Med. 2025;14(12). Epub 20250617. doi: 10.3390/jcm14124319. PubMed PMID: 40566066; PubMed Central PMCID: PMCPMC12194487.
18. Yamamoto T, Nagoshi N, Yamane J, Okubo T, Ago K, Fukuda K, et al. Recovery Trajectories After Surgery for Degenerative Cervical Myelopathy: Results of a Multicenter Prospective Study. J Orthop Sci. 2026. Epub 20260630. doi: 10.1016/j.jos.2026.06.007. PubMed PMID: 42379939.
19. Muhle C, Metzner J, Weinert D, Falliner A, Brinkmann G, Mehdorn MH, et al. Classification system based on kinematic MR imaging in cervical spondylitic myelopathy. AJNR Am J Neuroradiol. 1998;19(9):1763–71. PubMed PMID: 9802503; PubMed Central PMCID: PMCPMC8337474.
20. Rodríguez-Fonseca JR, Reyes-Navarro DA, Ruiz-Treviño AS, Miranda González A, Chávez-Bejar JO, Altamirano Carrizoza AA, et al. Clinical and Radiological Characterization of Cervical Spinal Stenosis Using Muhle Grading on Flexion-Extension Dynamic MRI: Correlation With mJOA in an Institutional Cohort. Global Spine J. 2026:21925682261464620. Epub 20260704. doi: 10.1177/21925682261464620. PubMed PMID: 42400433; PubMed Central PMCID: PMCPMC13332944.
21. Endo K, Suzuki H, Nishimura H, Tanaka H, Shishido T, Yamamoto K. Kinematic analysis of the cervical cord and cervical canal by dynamic neck motion. Asian Spine J. 2014;8(6):747–52. Epub 20141217. doi: 10.4184/asj.2014.8.6.747. PubMed PMID: 25558316; PubMed Central PMCID: PMCPMC4278979.
22. Li AY, Dai JB, Post AF, Choudhri TF. Dynamic Cervical Cord Compression Post-laminectomy Visualized by Flexion-extension Magnetic Resonance Imaging: Case Report. Cureus. 2019;11(1):e3878. Epub 20190114. doi: 10.7759/cureus.3878. PubMed PMID: 30899629; PubMed Central PMCID: PMCPMC6420335.
23. Chen H, Pan J, Nisar M, Zeng HB, Dai LF, Lou C, et al. The value of preoperative magnetic resonance imaging in predicting postoperative recovery in patients with cervical spondylosis myelopathy: a meta-analysis. Clinics (Sao Paulo). 2016;71(3):179–84. doi: 10.6061/clinics/2016(03)10. PubMed PMID: 27074180; PubMed Central PMCID: PMCPMC4785856.
24. Firempong GK, Sheppard WL, Gelfand Y, Ellingson BM, Holly LT. Spinal Cord Signal Intensity Predicts Functional Outcomes in the Operative Management of Degenerative Cervical Myelopathy. Clin Spine Surg. 2023;36(10):438–43. Epub 20230619. doi: 10.1097/bsd.0000000000001479. PubMed PMID: 38031316; PubMed Central PMCID: PMCPMC10691530.

25. Takeuchi K, Yokoyama T, Wada KI, Kudo H. Relationship between Enlargement of the Cross-Sectional Area of the Dural Sac and Neurological Improvements after Cervical Laminoplasty: Differences between Cervical Spondylotic Myelopathy and Ossification of the Posterior Longitudinal Ligament. Spine Surg Relat Res. 2019;3(1):27–36. Epub 20180629. doi: 10.22603/ssrr.2018-0008. PubMed PMID: 31435548; PubMed Central PMCID: PMCPMC6690118.
26. Joaquim AF, Baum GR, Tan LA, Riew KD. Dynamic Cord Compression Causing Cervical Myelopathy. Neurospine. 2019;16(3):448–53. Epub 20190724. doi: 10.14245/ns.1938020.101. PubMed PMID: 31607076; PubMed Central PMCID: PMCPMC6790743.
27. Verderame J, Arslan MS, Mukhtar F, Abbas Z. Weight-bearing MRI of the cervical spine: A scoping review of clinical utility and emerging applications. Eur J Radiol Open. 2025;15:100694. Epub 20251008. doi: 10.1016/j.ejro.2025.100694. PubMed PMID: 41127038; PubMed Central PMCID: PMCPMC12539231.
28. Zhou Z, Su Y, Shao Y, Liu J, Wu X, Gao P, et al. A Study on Prognostic Risk Factors of Cervical Spondylotic Myelopathy. J Korean Neurosurg Soc. 2025;68(6):694–705. Epub 20250520. doi: 10.3340/jkns.2025.0021. PubMed PMID: 40390532; PubMed Central PMCID: PMCPMC12582883.