Research Square

Preprints are preliminary reports that have not undergone peer review.
They should not be considered conclusive, used to inform clinical practice,
or referenced by the media as validated information.

Safety and efficacy of transarterial infusion chemotherapy combined with lipiodol chemoembolization for elderly patients with advanced Gastric Cancer

Jiajia Zhang
the First Affiliated Hospital of Zhengzhou University
Zhouding Yang
the First Affiliated Hospital of Zhengzhou University
Yishu Ma
the First Affiliated Hospital of Zhengzhou University
Yaozhen Ma
the First Affiliated Hospital of Zhengzhou University
ChunXia Li
the First Affiliated Hospital of Zhengzhou University
Wei He
the First Affiliated Hospital of Zhengzhou University
Weilong Chang
the First Affiliated Hospital of Zhengzhou University
Gang Wu
wuganghenan2004@zzu.edu.cn

the First Affiliated Hospital of Zhengzhou University

Research Article

Keywords: Elderly patients, Gastric cancer, Perfusion chemotherapy、Lipiodol、Chemoembolization、Interventional treatment

Posted Date: November 27th, 2026

DOI: https://doi.org/10.21203/rs.3.rs-11675931/v1

License: This work is licensed under a Creative Commons Attribution 4.0 International License.
Read Full License

Additional Declarations: No competing interests reported.

Abstract

Background

Gastric cancer (GC) is a common global malignancy. Advanced cases have numerous complications, and systemic chemotherapy works poorly. Advanced gastric cancer in elderly patients presents significant clinical challenges due to poor tolerance to standard systemic chemotherapy. This study aimed to evaluate the efficacy and safety of transarterial infusion chemotherapy combined with lipiodol chemoembolization (TAI-LCE) for the treatment of this vulnerable patient population.

Methods

Elderly patients (aged ≥ 65 years) with advanced gastric cancer (n = 72) received TAI + LCE once a month were retrospectively analyzed. Clinical response was assessed using RECIST 1.1, and adverse events were evaluated according to the NCI-CTCAE. Overall survival (OS) was estimated by Kaplan–Meier analysis.

Results

Technical success was achieved in all 72 patients without serious complications. Following treatment, 4/72 (5.6%) patients achieved complete remission, 54 (75.0%) achieved partial remission, 6/72 (8.3%) had stable disease, and another 8/72 (11.1%) developed progressive disease (PD). The overall disease control rate and objective response rate were 79.2% and 52.8%, respectively. A total of 6 patients with preoperative dysphagia of varying severity experienced symptomatic relief after treatment. In addition, gastrointestinal bleeding was resolved in 18 patients with preoperative hemorrhage. 31 patients survived, 41 died, and the median overall survival was 11.0 months.

Conclusions

Transarterial chemotherapy combined with lipiodol chemoembolization is safe and efficacious against advanced gastric cancer, and well-tolerated palliative treatment for elderly patients with advanced gastric cancer.

Introduction

Gastric cancer (GC) ranks fifth in global malignancy incidence and third in cancer-related mortality [1]. Most patients are diagnosed at locally advanced or metastatic stages with severe complications, with fewer than 60% eligible for radical gastrectomy and a merely 20% 5-year postoperative survival rate [2–4]. Systemic intravenous chemotherapy (SIC), the first-line treatment for advanced gastric cancer, often causes severe systemic toxic reactions and poor tolerance [5]. Elderly patients (≥ 65 years) with organ

function decline, multiple comorbidities and impaired bone marrow reserve poorly tolerate standard-dose SIC, which is frequently discontinued due to severe toxicity [6]. Thus, minimally invasive local interventions are urgently needed to control tumors, relieve symptoms and reduce systemic adverse effects.

Transarterial infusion chemotherapy combined with lipiodol chemoembolization (TAI-LCE) offers a novel approach to address this clinical challenge. Transarterial chemoembolization (TACE) directly infuses high-dose chemotherapeutic drugs into tumor-feeding vessels, and subsequent vascular embolization leads to cellular cytotoxicity and ischemic necrosis in tumor tissues [7]. As both a sustained-release carrier and embolic agent, lipiodol reduces systemic toxicity and alleviates symptoms such as malignant obstruction and hemorrhage [8]. Lipiodol-based TACE has been widely applied for unresectable hepatocellular carcinoma and liver metastases from colorectal cancer [9, 10], with reliable efficacy and safety demonstrated in multiple malignancies [11, 12]. Nevertheless, few systematic studies have explored its value in elderly patients with advanced gastric cancer [13, 14]. Accordingly, this retrospective study analyzed the clinical response rate, survival benefits and safety of transarterial infusion chemotherapy plus lipiodol chemoembolization in such patients, aiming to support the individualized palliative management of elderly patients with advanced gastric cancer.

Materials and methods

Patients

This single-center retrospective study reviewed the clinical records of elderly patients (≥ 65 years) with advanced gastric cancer who received TAI-LCE at our hospital between May 2023, and September 2025. Pathological examination confirmed advanced gastric cancer in all patients. The collected data consisted of clinical documents, imaging findings, interventional operation records and follow-up outcomes.

Collected variables covered demographic features, comorbidities, tumor location, metastasis, pathological stage and pre-interventional treatments including surgery, radiotherapy and chemotherapy. Intraoperative vascular embolization details and complications were documented as well. All patients received 1 to 3 cycles of monthly TAI combined with lipiodol chemoembolization. Treatment efficacy was assessed blindly by two experienced radiologists based on Response Evaluation Criteria in Solid Tumors (RECIST) guidelines, and post-treatment overall survival (OS) was analyzed thereafter.

Inclusion criteria: (1) Patients aged ≥ 65 years; (2) Patients with a preoperative diagnosis of advanced GC according to pathology unsuitable for radical surgery, or those suffering postoperative recurrence or progression following first-line, second-line or neoadjuvant chemoradiotherapy; (3) Patients receiving combined TAI and lipiodol chemoembolization; (4) Patients with an Eastern Cooperative Oncology Group (ECOG) performance status of 0–2; (5) Patients with an expected survival > 3 months; (6) Providing written informed consent for interventional therapy.

Exclusion criteria: (1) Incomplete clinical and follow-up data; (2) Patients with other serious systemic diseases; (3) Patients eligible for radical resection; (4) Patients received gastric artery embolization using gelatin sponges and polyvinyl alcohol (PVA) particles. All enrolled participants gave written consent before treatment. The study complied with the Declaration of Helsinki and was approved by the First Affiliated Hospital of Zhengzhou University ethics committee (No. 2021-KY-0911-001).

Preoperative Preparation

All patients maintained preoperative fasting. Gastric mucosal protectants, parenteral nutrition and prophylactic antibiotics were given preoperatively. Routine blood tests, liver and renal function, electrolytes, coagulation profiles, tumor markers, electrocardiography (ECG) and contrast-enhanced abdominal CT were performed for full preoperative evaluation to assess general health, nutrition and bleeding risk.

Interventional procedure

Femoral artery cannulation was performed via the modified Seldinger technique. Digital subtraction angiography of the celiac trunk, common hepatic artery, left gastric artery, gastroduodenal artery and left inferior phrenic artery was routinely conducted with a Siemens Artis Zee III system to identify tumor feeding vessels. Under coaxial guidance, a 2.7-F ProGreat microcatheter (Terumo, Tokyo, Japan) was advanced through the outer catheter to achieve superselective catheterization of the tumor feeding arteries (Fig. 1).

Chemotherapy regimens and dosages were individualized based on patients' age, physical condition and body surface area. The administered drugs consisted of oxaliplatin (100 mg) in 150 mL of 5% glucose solution, and raltitrexed (2–4 mg) dissolved in 150 mL of 0.9% sodium chloride solution according to the improved anti-tumor ECF protocol. Elderly patients presenting with poor general condition and ECOG performance status 2 received half of the standard dose. The mixed solution was given via continuous perfusion at 10 mL/min. Following completion of chemotherapy infusion, an emulsion consisting of 10 mg pirarubicin (THP) mixed with 10 mL lipiodol was injected into the tumor-feeding arteries until marked stasis of antegrade blood flow was achieved (Fig. 1). Catheters were removed and the puncture site compressed for hemostasis. Proton pump inhibitors, antiemetics and sufficient fluids were given perioperatively post superselective intra-arterial chemotherapy.

Postoperative Management

Following the procedure, patients received antiemetics, acid suppressants, nutritional support and fluid therapy. Laboratory tests including complete blood count, liver and renal function, serum electrolytes and coagulation profiles were rechecked on postoperative days 3 and 7. Appropriate hematopoietic therapies were applied for patients with leukopenia or thrombocytopenia. 1 month postoperatively, contrast-

enhanced abdominal CT was conducted to assess treatment efficacy according to Response Evaluation Criteria in Solid Tumors (RECIST) 1.1 criteria [15]. Additional cycles of combined TAI-LCE intervention were available as required, with a 4-week interval between treatments (Fig. 2).

Efficacy evaluation and Follow-up

Tumor responses were assessed by abdominal CT at 30 days post treatment based on RECIST 1.1, focusing on alterations of primary lesions, regional lymph node metastasis and distant metastasis. Patients with complete remission (CR) would receive alternative treatments including surgical resection, radiotherapy, SIC or targeted therapy. Those with partial remission (PR) or stable disease (SD) underwent additional cycles. For cases of progressive disease (PD), only comprehensive supportive care (CB) was administered without further TAI-LCE intervention to repeat. All adverse events and complications were fully documented, such as post-embolization syndrome (fever, abdominal pain, nausea, vomiting), myelosuppression and hepatic/renal dysfunction. Special attention was paid to severe local complications including gastric hemorrhage and gastric perforation. Adverse event severity was evaluated using the National Cancer Institute Common Terminology Criteria for Adverse Events (CTCAE version 5.0).

Patients were followed up via telephone consultation, outpatient review and in-hospital reexamination. Follow-up continued until death or March 2026. During the period, bleeding complications were monitored, and tumor lesions were evaluated by abdominal computed tomography. Overall survival (OS) was defined as the time from the first interventional therapy to death or the final follow-up (Fig. 3).

Statistical analyses

All statistical analyses were carried out with IBM SPSS 26.0. Continuous variables were reported as mean ± SD, and categorical data were described with case numbers and percentages. Differences between categorical groups were assessed by the chi-square test. The Kaplan-Meier approach was used for survival curve plotting and median OS calculation. $P < 0.05$ was defined as statistically significant.

Results

Baseline Patient Characteristics

72 patients (56 males and 16 females; 65–88 years) were included in this cohort. All patients completed TAI combined with LCE targeting the tumor feeding arteries successfully. The primary tumor locations of the 72 enrolled subjects were distributed as follows: 9 cases (9/72, 12.5%) at the esophagogastric junction, 31 cases (31/72, 43.1%) with cardia-fundus gastric carcinoma, 25 cases (25/72, 34.7%) in the gastric body, 5 cases (5/72, 6.9%) in the gastric antrum, 1 case (1/72, 1.4%) in the gastric angle, and 1 case (1/72, 1.4%) at the pylorus. Pathological examination confirmed all cases were diagnosed with adenocarcinoma. 38 patients presented with metastatic lesions, including 14 cases of liver metastasis, 5

lung metastasis, 2 pancreatic metastasis, 2 colonic metastases, 20 lymph node metastases, 5 bone metastases and 1 brain metastases. Based on Stooler dysphagia grading, there were 1 case of grade 1, 2 of grade 2, 2 of grade 3 and 1 of grade 4. 18 patients had a history of hematemesis or melena, and 3 patients with cardiofundal gastric carcinoma were hospitalized urgently for intractable gastrointestinal bleeding.

Among the 72 enrolled patients, 31 patients received the therapy once, 36 patients twice, and 5 patients three times, with a total of 118 interventional operations. The main involved arteries were the left gastric artery (110 times), right gastric artery (12 times), proper esophageal artery (7 times), gastroduodenal artery (4 times), inferior phrenic artery (2 time) and right gastroepiploic artery (1 time). The mean lipiodol dose was 1.5 mL (0.6-3.5mL), which was titrated until antegrade blood flow slowed or stopped after embolization. Patients with liver metastasis also received TAI combined with LCE targeting the blood supply of metastatic lesions. Among them, 11 cases were treated via the left hepatic artery and 7 via the right hepatic artery. Table 1 presents the patients’baseline clinical profiles.

Table 1
Characteristics of patients(N = 72)

Sex	n (percentage)	Mean/median value
Male	56 (77.8%)	
Female	16 (22.2%)	
Age (years)		74.4 ± 13.8
Preoperative clinical symptoms		
Abdominal discomfort	27(58.7%)	
Dysphagia	6 (8.3%)	
Hemorrhage	18 (25%)	
Distant metastasis		
Liver	14(19.4%)	
Lung	5(6.9%)	
Pancreatic	2(2.8%)	
Colonic	2(2.8%)	
Multiple lymph nodes	20(27.8%)	
Bone	5(6.9%)	
Brain	1(1.4%)	
Preoperative treatment		
Radical surgery	5(6.9%)	
Chemotherapy	43(59.7%)	
Times of interventional operations		1.64 ± 1.17

Perioperative adverse events

A 2.7F microcatheter was applied for superselective intubation in all cases to protect blood vessels and prevent drug reflux and ectopic embolism. No severe complications linked to TAI + LCE were observed. Chemotherapy-related adverse events (AEs) were graded per NCI-CTCAE version 3.0. Grade I to IV postoperative AEs were noted, and all symptoms subsided rapidly. The most frequent reactions included abdominal pain, nausea, vomiting, reduced hemoglobin, leukopenia, thrombocytopenia and fever (Table 2).

Table 2
Adverse Events and treatment after interventional treatment

Adverse events	No. of Pts.	Treatment	Clinical outcome
Abdominal pain	72 (100%)	Analgesia(23 Case)	Remission
Nausea	64 (88.9%)	Antiemetic	Remission
Fever	19 (26.4%)	Antiemetic	Remission
Thrombocytopenia	31 (43.1%)	Platelet elevation therapy	Remission
Leukocytopenia	14 (19.4%)	leukocyte-boosting therapy	Remission

Evaluation of clinical efficacy

All 72 participants were treated with TAI combined with LCE. The size of primary tumors and peripheral metastatic lymph nodes shrank to different extents in most patients. According to RECIST Version 1.0, there were 4 cases of CR, 54 of PR, 6 of SD and 8 of PD. The overall disease control rate and objective response rate were 79.2% (57/72) and 52.8% (38/72), respectively. Dysphagia was relieved in 6 patients after intervention. Notably, 1 patient with grade 4 dysphagia regained the ability of oral feeding. Radiography revealed smoother passage of contrast medium through the cardia compared with pre-treatment status. None of the 18 patients with prior hematemesis or melena experienced recurrent gastrointestinal bleeding.

Follow-up and survival

Complete follow-up data were obtained for all patients. By the end of the follow-up period, 31 patients were still alive with a mean survival time of 17.1 months (range, 6–43 months), and 41 patients died, with a mean survival of 13.3 months (range, 1–51 months). In total, 66 patients (91.6%) survived more than 6 months, 35 (48.6%) over 12 months, and 10 (13.9%) over 24 months. The median overall survival was 11.0 months. At the final follow-up, 19 living patients had an ECOG performance status of 0 to 1. Among the 41 deceased patients, 25 died of tumor recurrence and associated cachexia, and 16 died of multiple organ failure.

Discussion

For elderly patients with advanced gastric cancer, treatment prioritizes effective tumor control while maintaining their nutritional status and quality of life. Conventional systemic chemotherapy frequently causes severe myelosuppression and gastrointestinal adverse reactions, which tend to worsen physical decline in seniors [16, 17]. Our findings strongly corroborate the hypothesis that TAI combined with LCE is a highly viable, safe, and effective alternative that successfully bypasses these physiological limitations.

TACE delivers extremely high local drug concentrations. Previous research demonstrated that superselective intra-arterial chemotherapy (SIC) yielded nearly 10-fold higher drug levels in abdominal

organs than conventional administration routes [18]. That enhances chemotherapeutic efficacy, suppresses tumor cell growth and alleviates systemic toxicity [19, 20]. Subsequent lipiodol chemoembolization plays two key roles: iodized oil microembolizes tumor terminal capillaries to trigger severe hypoxia and stops chemotherapeutic drugs from flowing back into the systemic venous system. Such synergistic effects promote extensive tumor cell apoptosis and antigen exposure, while well preserving the physical tolerance of elderly patients.

This study aimed to evaluate the real-world efficacy and safety of TACE in elderly patients with advanced gastric cancer, particularly those with impaired organ function and multiple comorbidities who are intolerant to conventional chemotherapy or ineligible for surgery. A total of 72 enrolled patients received low-dose NCCN-recommended first-line TAI combined with LCE. This minimally invasive regimen, which has been proven superior to systemic intravenous chemotherapy [5], achieves effective local tumor control, yields an objective response rate of 52.8% and a median survival time of 11.0 months, and significantly relieves tumor-related symptoms including dysphagia, hematemesis and melena via reliable hemostasis and tumor progression inhibition. Moreover, the combination regimen exhibits a favorable safety profile, with only mild grade I–II reversible adverse events and no severe complications such as gastric perforation or massive hemorrhage.

Despite these positive clinical outcomes, our study acknowledges several methodological limitations. Additionally, variations in individual chemotherapeutic dosing and tumor biology among elderly patients warrant further investigation. Furthermore, as a single-center, retrospective single-arm study, this work is limited by inherent selection bias and the absence of randomized controlled trial (RCT) comparisons. Nevertheless, conducting RCTs is difficult in elderly patients with multiple comorbidities due to ethical concerns and recruitment difficulties. Our real-world data still holds important clinical reference value. TACE yields satisfactory efficacy, promising survival outcomes and controllable complications for elderly patients with advanced gastric cancer. Further multicenter, large-sample real-world studies are required to validate our findings and refine treatment regimens.

For elderly patients with advanced gastric cancer, transarterial infusion combined with lipiodol chemoembolization achieves favorable efficacy with a satisfactory safety profile. This therapy offers a viable treatment option for those inoperable patients or individuals with disease progression following prior interventions. It stands as a crucial therapeutic option that profoundly improves the survival and quality of life for this vulnerable population.

Declarations

Acknowledgments

The authors thank their colleagues in the interventional operating room.

Author’s contribution

J.Z. and D.Y. wrote the manuscript text (J.Z. was the main drafter of this manuscript). J.Z., D.Y., Y.M., Y.M., W.C., W.H. and C.W. were involved in collecting data. G.W. revised the manuscript. G.W. designed study and completed the operation. All authors approved the final manuscript.

Funding

This study was supported by the training project for young and middle-aged health science and technology innovation leaders in Henan Province in 2020 (YXKC2020018).

Data availability

Research data are not publicly available on legal or ethical grounds. The datasets used and/or analyzed during the current study available from the corresponding author on reasonable request.

Clinical trial number

Not applicable.

Ethical approval

All research was conducted in accordance with both the Declarations of Helsinki and Istanbul. Ethical approval was granted by the First Affiliated Hospital of Zhengzhou University Ethics Committee.

Consent to participate

Patients' informed consent was waived or not required by the First Affiliated Hospital of Zhengzhou University Ethics Committee, as this is a retrospective study, and the analysis used anonymous clinical data that were obtained after the patient or their guardians had agreed to treatment with written consent.

Consent to publish

All authors have read and agreed the contents of the manuscript and consent to its publication.

Competing interests

The authors declare that they have no competing interests.

References

1. Torre LA, Bray F, Siegel RL, Ferlay J, Lortet-Tieulent J, Jemal A. Global cancer statistics, 2012. CA Cancer J Clin. 2015;65:87–108.
2. Wilkinson NW, Howe J, Gay G, Patel-Parekh L, Scott-Conner C, Donohue J. Differences in the pattern of presentation and treatment of proximal and distal gastric cancer: results of the 2001 gastric patient care evaluation. Ann Surg Oncol. 2008;15:1644–50.

3. Wenner J, Zilling T, Bladstrom A, Alvegard TA. The influence of surgical volume on hospital mortality and 5-year survival for carcinoma of the oesophagus and gastric cardia. Anticancer Res. 2005;25:419–24.
4. Liu JF, Wang QZ, Hou J. Surgical treatment for cancer of the oesophagus and gastric cardia in Hebei, China. Br J Surg. 2004;91:90–8.
5. Guimbaud R, Louvet C, Ries P, Ychou M, Maillard E, Andre T, Gornet JM, Aparicio T, Nguyen S, Azzedine A, Etienne PL, Boucher E, Rebischung C, Hammel P, Rougier P, Bedenne L, Bouche O. Prospective, randomized, multicenter, phase III study of fluorouracil, leucovorin, and irinotecan versus epirubicin, cisplatin, and capecitabine in advanced gastric adenocarcinoma: a French intergroup (Federation Francophone de Cancerologie Digestive, Federation Nationale des Centres de Lutte Contre le Cancer, and Groupe Cooperateur Multidisciplinaire en Oncologie) study. J Clin Oncol. 2014;32:3520–6.
6. Narita Y, Muro K. Systemic therapy strategies for elderly patients with gastric cancer. Ther Adv Med Oncol. 2025;17:17588359251363057.
7. Zhang J, Zhou G, Yin M, Ma Y, He W, Bi Y, Wu G. Transcatheter arterial infusion chemotherapy combined with lipiodol chemoembolization for advanced gastric fundus and cardia cancer with obstruction. J Cancer Res Clin Oncol. 2025;151:183.
8. Zhang J, Li X, Yin M, Zhou G, Ma Y, Bi Y, Wu G. Transarterial infusion chemotherapy combined with iodinated oil chemoembolization for the treatment of primary colorectal cancer. J Cancer Res Ther. 2025;21:1221–6.
9. de Baere T, Dufaux J, Roche A, Counnord JL, Berthault MF, Denys A, Pappas P. Circulatory alterations induced by intra-arterial injection of iodized oil and emulsions of iodized oil and doxorubicin: experimental study. Radiology. 1995;194:165–70.
10. Pillai K, Ke K, Mekkawy A, Akhter J, Morris DL. Enhancement of treatment efficacy of hepatic tumours using Trans-arterial-chemoembolization. Am J Cancer Res. 2023;13:1623–39.
11. Novell JR, Parbhoo SP, Dawson K, Dick R, Kelleher SM. Targeted therapy for recurrent breast carcinoma with regional 'Lipiodol'/epirubicin infusion. Lancet. 1990;336:1383.
12. Ozono S, Okajima E, Hirao Y, Babaya K, Komada S, Matsuki H, Takahashi S, Ohishi H, Yoshioka T. Transcatheter arterial embolization of vesical artery in the treatment of invasive bladder cancer. Eur Urol. 1988;15:176–9.
13. Min L, Liu Z, Zhou B, Zhou P, Luo R, Ding Y, Cui Y, Shi Z, Gu Y, Sun Y, Tang Z, Wang X. Transarterial Infusion Chemotherapy and Embolization for Patients With Unresectable Advanced Cancer of Stomach or Gastroesophageal Junction: A Retrospective Study. Cancer Med. 2024;13:e70396.
14. Li N, Wang G, Duan G, Li Z, Zheng Y, Wang Z, Li G. Clinical observation of transcatheter arterial chemoembolization in super-aged patients with advanced gastric cancer. Support Care Cancer. 2022;30:1441–50.
15. Eisenhauer EA, Therasse P, Bogaerts J, Schwartz LH, Sargent D, Ford R, Dancey J, Arbuck S, Gwyther S, Mooney M, Rubinstein L, Shankar L, Dodd L, Kaplan R, Lacombe D, Verweij J. New response

evaluation criteria in solid tumours: revised RECIST guideline (version 1.1). Eur J Cancer. 2009;45:228–47.

16. Chan WL, Liu X, Wong CK, Wong MS, Wong IY, Lam KO, Yun BH, Cheung EE, Tse RP, Chan F, Law S, Kwong D. Adjuvant Chemotherapy in Older Patients with Gastric Cancer: A Population-Based Cohort Study. Cancers (Basel), 15(2023).
17. Nakazawa N, Kuriyama K, Kumakura Y, Kimura A, Sano A, Sakai M, Shirabe K, Saeki H. Real-world survival benefit of chemotherapy in elderly patients with advanced gastric cancer: a population-based SEER analysis. Sci Rep, (2026).
18. Tokairin Y, Maruyama M, Baba H, Yoshida T, Kure N, Nagahama T, Ebuchi M. [Pharmacokinetics of subselective arterial infusion chemotherapy]. Gan Kagaku Ryoho. 2001;28:1795–8.
19. Imano M, Itoh T, Satou T, Sogo Y, Hirai H, Kato H, Yasuda A, Peng YF, Shinkai M, Yasuda T, Imamoto H, Okuno K, Shiozaki H, Ohyanagi H. Prospective randomized trial of short-term neoadjuvant chemotherapy for advanced gastric cancer. Eur J Surg Oncol. 2010;36:963–8.
20. Wu ZF, Cao QH, Wu XY, Chen C, Xu Z, Li WS, Yao XQ, Liu FK. Regional Arterial Infusion Chemotherapy improves the Pathological Response rate for advanced gastric cancer with Short-term Neoadjuvant Chemotherapy. Sci Rep. 2015;5:17516.

Figures

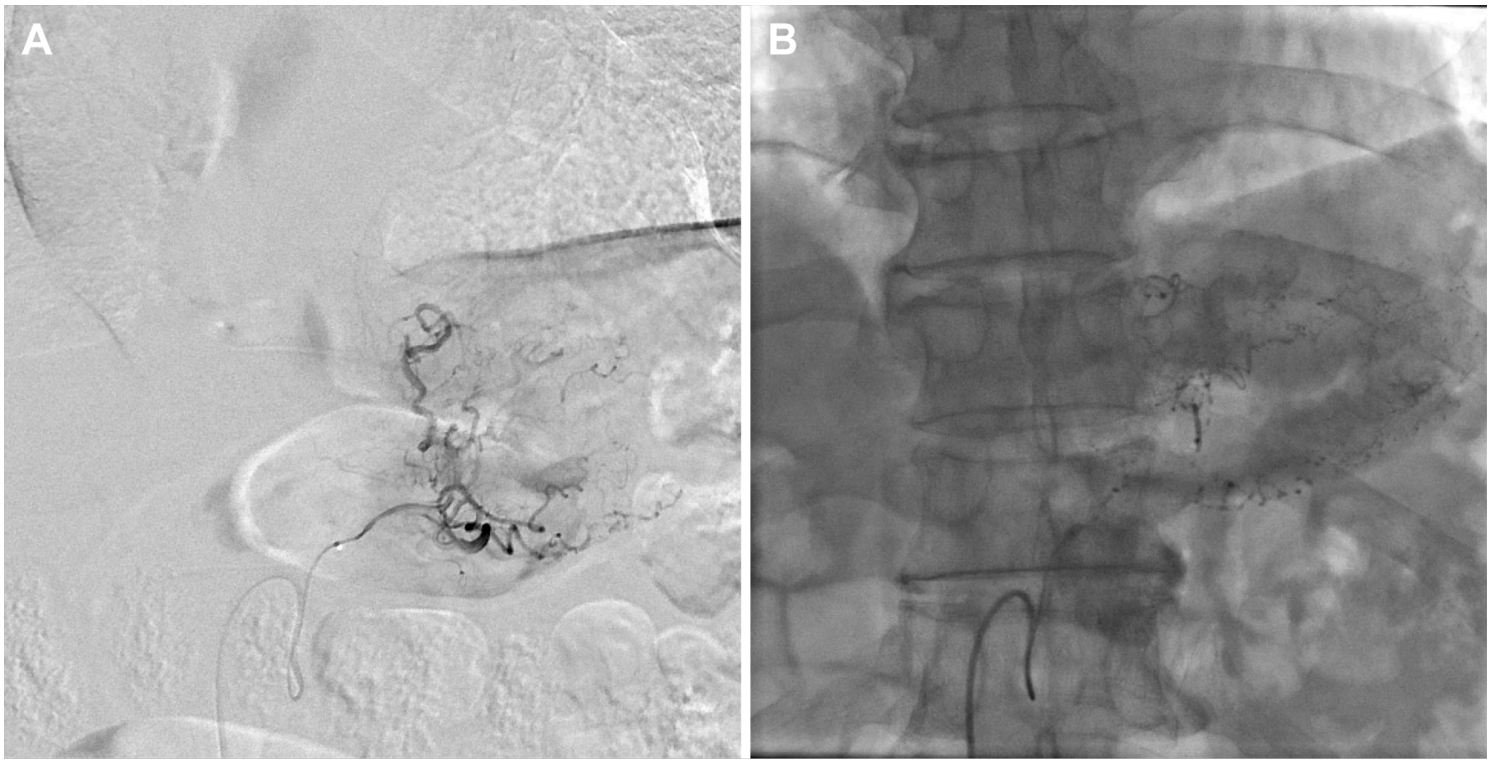

Figure 1

Interventional Treatment Procedure. Microcatheter selectively advanced into the left gastric artery, with angiography showing arterial hypertrophy with tortuos and increased branching, indicative of tumor-like staining (A). Images depict the subsequent deposition of lipiodol following embolization (B) .

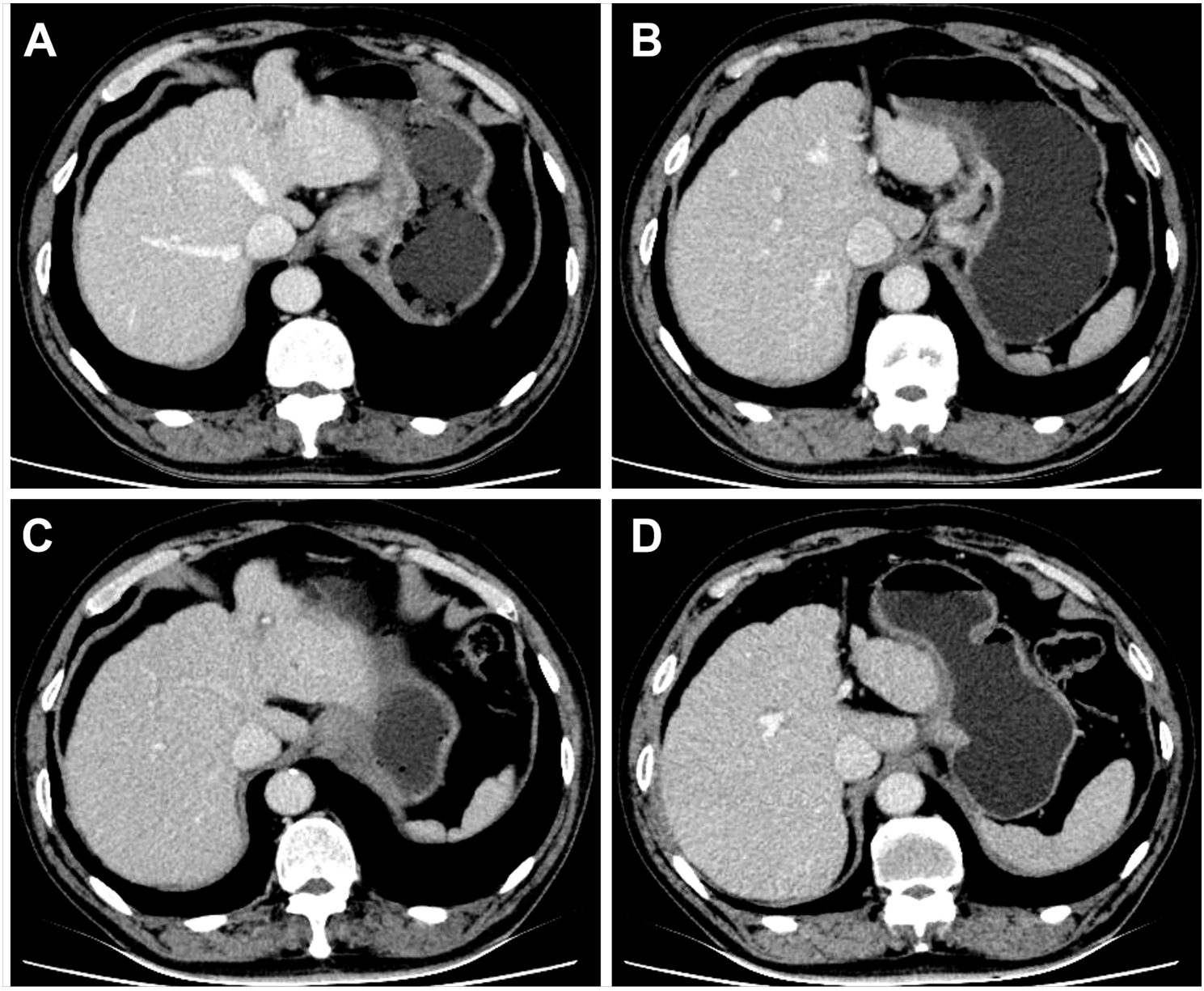

Figure 2

The enhanced CT obtained before interventional therapy revealed marked thickening and enhancement of the gastric wall in the cardia, accompanied by significantly enlarged perigastric lymph nodes (A–B). Enhanced CT showed that the thickness of the gastric wall improved in the same patient one month after interventional therapy, with no remarkable enlargement of perigastric lymph nodes (C–D).

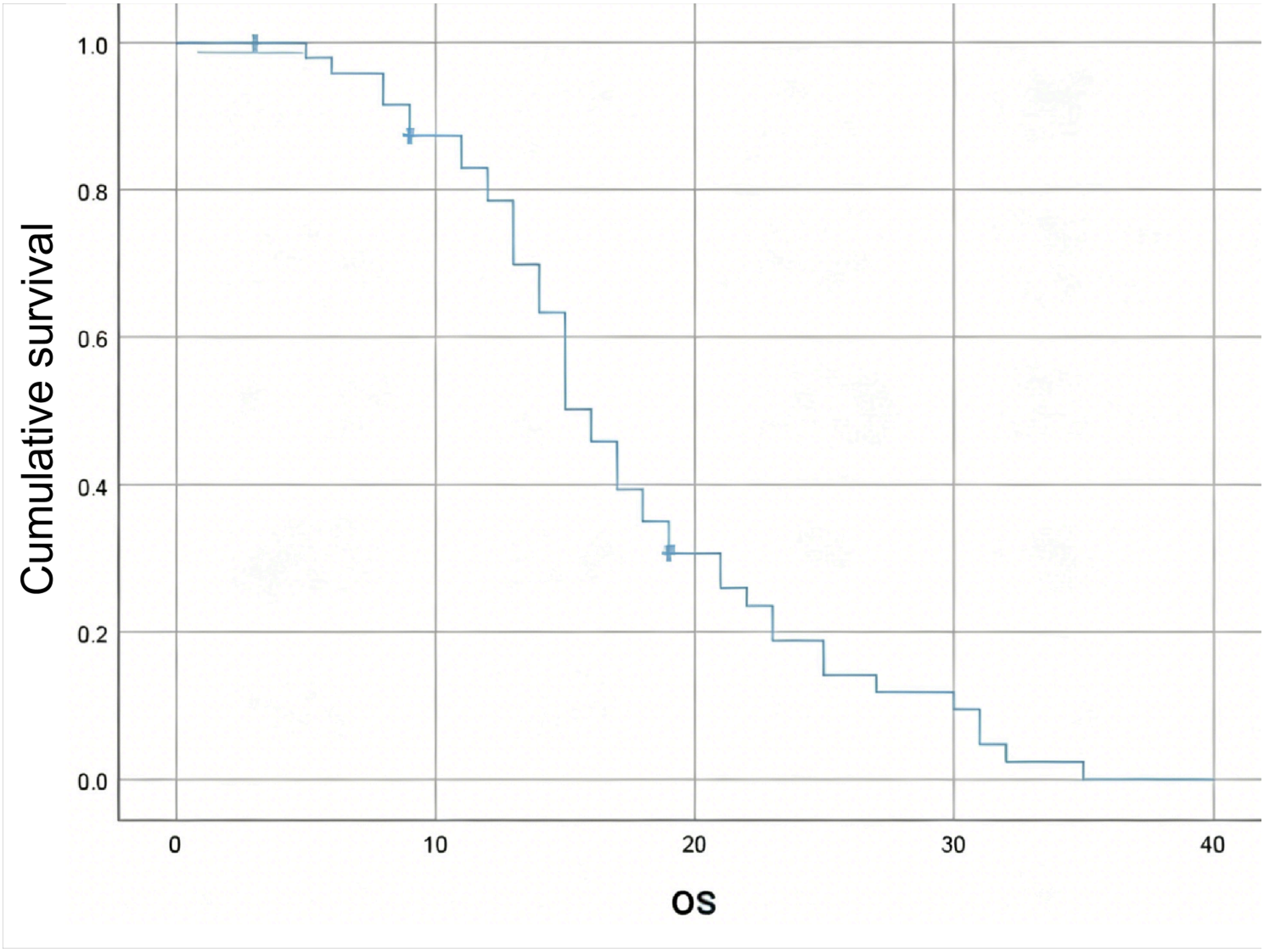

Figure 3

Survival curve for overall survival.