Research Square

Preprints are preliminary reports that have not undergone peer review.
They should not be considered conclusive, used to inform clinical practice,
or referenced by the media as validated information.

SCN4A p.Thr704Met-associated periodic paralysis with normal-range potassium measurements and tubular aggregates: a case report

Juxiang Song
Anhui University of Chinese Medicine
Yongzhi Ni
Anhui University of Chinese Medicine
Binyan Wan
Anhui University of Chinese Medicine
Jie Shao
Anhui University of Chinese Medicine
Tian Gao
Anhui University of Chinese Medicine
Xu'en Yu
yuxuen@ahtcm.edu.cn
Anhui University of Chinese Medicine

Case Report

Keywords: SCN4A, periodic paralysis, tubular aggregates, acetazolamide, case report

Posted Date: November 27th, 2026

DOI: https://doi.org/10.21203/rs.3.rs-11673120/v1

License: This work is licensed under a Creative Commons Attribution 4.0 International License.
Read Full License

Additional Declarations: No competing interests reported.

SCN4A p.Thr704Met-associated periodic paralysis with normal-range potassium measurements and tubular aggregates: a case report

Juxiang Song[1], Yongzhi Ni[1], Binyan Wan[1], Jie Shao[1,2], Tian Gao[1,2], Xu'en Yu[1,2]*

[1] Anhui University of Chinese Medicine, Hefei, China

[2] Hospital Affiliated to Institute of Neurology, Anhui University of Chinese Medicine, Hefei, China

* Correspondence: Xu'en Yu, yuxuen@ahtcm.edu.cn

Abstract

Background: SCN4A-related periodic paralysis may present with potassium measurements within the laboratory reference interval. Interpretation requires attention to sampling time, treatment status, and the broader clinical phenotype.

Case presentation: A 21-year-old Chinese man presented with recurrent limb weakness beginning in childhood and a paternal family history of similar symptoms. He reported fasting and rest after exercise as triggers. Serum potassium was 4.54 mmol/L at an earlier assessment of undocumented attack status and 5.09 mmol/L during mild leg weakness before treatment; both were within the reported local reference interval of 3.50–5.10 mmol/L. Clinical genetic testing identified heterozygous SCN4A c.2111C>T (p.Thr704Met). Muscle biopsy showed vacuolar changes and tubular aggregates confirmed by transmission electron microscopy. Thigh magnetic resonance imaging showed bilateral muscle signal abnormalities. Oral potassium chloride and spironolactone produced no appreciable improvement during hospitalization. After discharge, acetazolamide 250 mg twice daily was associated with fewer attacks and symptomatic improvement at the 1-month follow-up, although post-treatment attack counts were unavailable.

Conclusions: Recurrent childhood-onset weakness and a compatible family history should prompt consideration of a skeletal muscle channelopathy even when available potassium measurements are within the reference interval. Integrating genetic testing with clinical and pathological findings can support diagnosis. Biochemical subclassification requires appropriately timed potassium measurements, and tubular aggregates are not a variant-specific marker.

Keywords: SCN4A; periodic paralysis; tubular aggregates; acetazolamide; case report

Background

Primary periodic paralyses are skeletal muscle channelopathies characterized by episodic weakness, sometimes accompanied by myotonia or persistent myopathic changes. Serum potassium contributes to phenotypic classification, but its interpretation depends on sampling time relative to weakness and treatment [1]. Normal-range measurements do not exclude SCN4A-related disease, and normokalemic presentations may overlap with the hyperkalemic periodic paralysis spectrum [2].

The SCN4A p.Thr704Met variant has previously been associated with periodic paralysis, tubular aggregates, and muscle imaging abnormalities [3, 4]. We describe a patient with this variant, recurrent childhood-onset weakness, normal-range potassium measurements, and tubular aggregates confirmed by electron microscopy. The case illustrates how clinical, biochemical, genetic, and pathological findings can support diagnosis while leaving the biochemical classification of individual attacks uncertain.

Recent reviews describe the clinical and genetic heterogeneity of periodic paralysis and the complementary roles of clinical assessment and genetic testing [5–8]. Family studies and reports of normokalemic presentations further demonstrate variability within SCN4A-associated disease [9–12].

Case presentation

Patient information and clinical course

A 21-year-old Chinese man was admitted in March 2026 with recurrent limb weakness for approximately 13 years. His family recalled transient generalized weakness at about 2 years of age, whereas recurrent, recognizable attacks began at age 8. Episodes initially affected the legs, impaired walking and stair climbing, lasted several hours to 1–2 days, and resolved spontaneously. Before treatment, he reported approximately one or two attacks per month. Strength generally recovered between episodes, although mild persistent fatigue had developed in recent years.

His father, younger sister, paternal grandfather, and paternal great-uncle reportedly had similar symptoms; his mother did not. This history suggested familial disease with possible autosomal dominant inheritance. Genetic testing of relatives was not documented, and segregation of the variant was therefore not established. The pedigree and the proband's sequencing trace are shown in Fig. 1.

Reported triggers included fasting, sleep, prolonged sitting or standing, and temperature extremes. Gentle walking sometimes

partially relieved weakness, whereas subsequent rest was associated with worsening. The relative severity of weakness in the two legs varied without a consistently predominant side. He also described intermittent difficulty moving his fingers and difficulty opening his eyes during cold exposure in childhood. These symptoms suggested possible stiffness, but myotonia was not objectively demonstrated. During severe historical attacks, he recalled generalized immobility and a weak cough; respiratory function was not measured. Consumption of bananas or coconut water had no consistent reported effect.

Clinical findings

At admission, the patient reported mild lower-limb weakness. The discharge record described normal upper-limb and distal lower-limb strength and near-normal proximal lower-limb strength with slight weakness. Patellar and Achilles reflexes were absent, whereas brachioradialis reflexes were present. Muscle atrophy, percussion myotonia, and pathological plantar responses were not documented. The interval between strength testing and potassium sampling was unavailable; the examination did not document a severe paralytic attack.

Diagnostic assessment

Serum potassium was 4.54 mmol/L on October 15, 2025 (reference interval, 3.50–5.10 mmol/L); attack and treatment status at sampling were undocumented. At admission on March 23, 2026, serum potassium was 5.09 mmol/L. According to the treating clinician, this sample was obtained during mild leg weakness before medication, and the local reference interval was 3.50–5.10 mmol/L. The value was therefore within the reported interval, close to its upper limit. The exact interval from symptom onset to sampling was unavailable. Earlier attacks were reportedly associated with normal potassium measurements, but individual results and sampling times were unavailable.

A 24-hour urine collection on March 24, 2026, reported on March 25, showed potassium excretion of 80.14 mmol/day (reference interval, 25.00–100.00 mmol/day). Creatine kinase was 441 U/L and was flagged as elevated in the discharge record. Thyroid-stimulating hormone and electrocardiography were reported as normal. Routine repetitive nerve stimulation reportedly showed neither decrement nor increment. A standardized long exercise test result was unavailable.

Thigh magnetic resonance imaging (MRI), dated March 26, 2026, showed bilateral, asymmetric muscle signal abnormalities, including changes in the posterior thigh musculature (Fig. 2).

Biopsy of the left biceps brachii showed variation in muscle fiber size, scattered sarcoplasmic vacuoles, occasional mildly hypertrophic or atrophic fibers, and mild interstitial connective tissue proliferation. No obvious fiber necrosis or macrophage infiltration was observed (Fig. 3A). Periodic acid–Schiff staining showed no glycogen accumulation within the vacuoles (Fig. 3C). Nicotinamide adenine dinucleotide–tetrazolium reductase staining showed reduced activity and disruption of the reticular architecture in vacuolated areas, together with intensely stained tubular aggregates (Fig. 3B, F). Modified Gomori trichrome staining demonstrated red-stained tubular aggregates without ragged red fibers (Fig. 3E). Succinate dehydrogenase staining showed a uniform mitochondrial distribution (Fig. 3D). Transmission electron microscopy confirmed aggregates of tightly packed, parallel tubules of uniform diameter (Fig. 3G).

Clinical genetic testing identified a heterozygous SCN4A c.2111C>T (p.Thr704Met) variant (Fig. 1B); the result was dated February 26, 2026, in the discharge record. The reported classification was likely pathogenic according to American College of Medical Genetics and Genomics criteria. This previously described variant supported the diagnosis of SCN4A-related periodic paralysis [3, 4].

The childhood onset, episodic recovery, compatible family history, and genetic finding supported SCN4A-related periodic paralysis. Normal thyroid testing argued against thyrotoxic periodic paralysis, while a fixed myopathy alone would not explain the recurrent, reversible weakness. Reported stiffness suggested a possible overlapping sodium channel myotonia phenotype, but electrophysiological confirmation was unavailable. Because serial untreated potassium measurements during well-documented attacks were lacking, the available results did not establish a consistently normokalemic subtype. Table 1 summarizes the clinical timeline.

Treatment, follow-up, and outcomes

During hospitalization, oral potassium chloride and spironolactone produced no appreciable reported improvement. After discharge on March 31, 2026, the patient began oral acetazolamide 250 mg twice daily. At the 1-month follow-up, he reported fewer attacks and symptomatic improvement. Post-treatment attack counts, objective changes in strength, and adverse-event monitoring results were unavailable.

Discussion and conclusions

This case illustrates the diagnostic contribution of combining a characteristic episodic history with genetic testing and muscle pathology when available potassium measurements fall within the laboratory reference interval. The p.Thr704Met variant and associated tubular aggregates have been described previously [3, 4]. The clinical contribution of this report is therefore the integration of these findings and the interpretation of incomplete attack-related biochemical data.

Fasting and rest after exertion are recognized triggers of periodic paralysis, and mild activity can modify an attack [1, 13]. The patient's account of partial improvement during gentle walking followed by worsening at rest is compatible with this spectrum. Reported asymmetry was not quantified during a severe attack. Similarly, cold-related eyelid and finger symptoms suggest possible stiffness but do not establish myotonia. Targeted clinical examination and electrophysiological assessment would help characterize a potential overlapping phenotype.

The potassium results require interpretation in their sampling context. The admission value of 5.09 mmol/L was within the reported local interval but near its upper boundary, whereas the earlier value of 4.54 mmol/L was not linked to a documented attack. Neither result establishes potassium dynamics during severe weakness. Previous reports describe overlapping potassium phenotypes in periodic paralysis, including p.Thr704Met-associated presentations [2, 14, 15]. Serial samples during spontaneous attacks, with symptom timing and treatment status recorded, would improve biochemical characterization. Urinary potassium excretion does not substitute for contemporaneous serum measurements.

Tubular aggregates supported the morphological characterization of the muscle changes but are not specific to this variant. Their occurrence with p.Thr704Met has already been reported [3], and muscle imaging abnormalities have also been described in affected patients [4]. These findings should be interpreted together with the episodic history and genetic result; they do not independently establish the biochemical subtype or a mechanism of muscle injury.

Acetazolamide is used in selected patients with periodic paralysis, and response varies between individuals and genotypes [1]. The patient reported improvement after treatment, but the short follow-up and absence of quantified post-treatment attack counts limit assessment of efficacy. Spontaneous fluctuation,

changes in triggers, and recall may have influenced the reported outcome.

Recognition of lifestyle and dietary triggers is relevant to counseling [16]. Tubular aggregates have also been reported in CACNA1S-associated myopathy [17], while p.Thr704Met has been associated with overlapping periodic paralysis and paramyotonia [18]. Studies of acetazolamide response in hypokalemic periodic paralysis and permanent weakness in hyperkalemic periodic paralysis provide broader treatment context [19, 20], but their findings cannot be directly extrapolated to this individual patient.

The main strengths of this report are the combined clinical, genetic, histochemical, and ultrastructural observations. Limitations include incomplete potassium sampling during attacks, imprecise alignment of biochemical and strength assessments, lack of familial segregation testing, absence of a standardized long exercise test result, and short, unquantified follow-up. These limitations restrict biochemical subclassification and assessment of treatment response.

In conclusion, SCN4A-related periodic paralysis should be considered in patients with recurrent childhood-onset weakness and a compatible family history despite normal-range potassium measurements. Genetic and pathological findings can support diagnosis, while the biochemical classification of attacks depends on sampling context. This case highlights the value of documenting symptom timing, potassium measurements, and treatment exposure together.

Patient perspective

In his written account, the patient identified hunger and sleep as prominent triggers. He described partial relief during movement, worsening during subsequent rest, and variable differences in weakness between the legs. Severe episodes interfered with movement and forceful coughing. At the 1-month follow-up, he reported fewer attacks and symptomatic improvement. This account is paraphrased from the patient's description.

Abbreviations

LOVD: Leiden Open Variation Database; MRI: Magnetic resonance imaging.

Declarations

Ethics approval and consent to participate

This is a retrospective case report. According to local institutional ethics requirements, formal ethical approval was waived. All procedures were performed in accordance with the Declaration of Helsinki. Written informed consent was obtained from the patient.

Consent for publication

Written informed consent was obtained from the patient for publication of this case report and any accompanying images. A copy of the written consent is available for review by the Editor-in-Chief of this journal.

Availability of data and materials

The variant entry is available in the Leiden Open Variation Database (LOVD): https://databases.lovd.nl/shared/individuals/00487748.

Competing interests

The authors declare that they have no competing interests.

Funding

Not applicable.

Authors' contributions

Juxiang Song contributed to conceptualization, data curation, and drafting the manuscript. Yongzhi Ni and Binyan Wan contributed to data curation. Jie Shao and Tian Gao collected the clinical data. Xu’en Yu supervised the work and reviewed and edited the manuscript. All authors read and approved the final manuscript.

Acknowledgements

Not applicable.

References

1. Statland JM, Fontaine B, Hanna MG, et al. Review of the diagnosis and treatment of periodic paralysis. Muscle Nerve. 2018;57(4):522–30.

2. Song YW, Kim SJ, Heo TH, et al. Normokalemic periodic paralysis is not a distinct disease. Muscle Nerve. 2012;46(6):908–13.

3. Luan X, Chen B, Liu Y, et al. Tubular aggregates in paralysis periodica paramyotonica with T704M mutation of SCN4A. Neuropathology. 2009;29(5):579–84.

4. Jeong HN, Yi JS, Lee YH, et al. Lower-extremity magnetic resonance imaging in patients with hyperkalemic periodic paralysis carrying the SCN4A mutation T704M: 30-month follow-up of seven patients. Neuromuscul Disord. 2018;28(10):837–45.

5. Luo M, Liu B, Xu J, et al. Clinical features and advances in the genetics of periodic paralysis. PeerJ. 2026;14:e20840.

6. Cannon SC. Periodic paralysis. Handb Clin Neurol. 2024;203:39–58.

7. Vicino A, Brugnoni R, Maggi L. Diagnostics in skeletal muscle channelopathies. Expert Rev Mol Diagn. 2023;23(12):1175–93.

8. Sekhon DS, Vaqar S, Gupta V. Hyperkalemic periodic paralysis. In: StatPearls. Treasure Island (FL): StatPearls Publishing; 2026.

9. Wang Q, Zhao Z, Shen H, et al. The clinical and genetic heterogeneity analysis of five families with primary periodic paralysis. Channels (Austin). 2021;15(1):20–30.

10. Fu C, Wang Z, Wang L, et al. Familial normokalemic periodic paralysis associated with mutation in the SCN4A p.M1592V. Front Neurol. 2018;9:430.

11. Xiuhai G, Weiping W, Ke Z, et al. Mutations of sodium channel alpha-subunit genes in Chinese patients with normokalemic periodic paralysis. Cell Mol Neurobiol. 2008;28(5):653–61.

12. Tan X, Hu S, Xie Z, et al. Identification of a SCN4A mutation in a large Chinese family with atypical normokalemic periodic paralysis using whole-exome sequencing. J Int Med Res. 2020;48(9):300060520953643.

13. Welland NL, Hæstad H, Fossmo HL, et al. The role of nutrition and physical activity as trigger factors of paralytic attacks in primary periodic paralysis. J Neuromuscul Dis. 2021;8(4):457–68.

14. Gun Bilgic D, Aydin Gumus A, Gerik Celebi HB, et al. A new clinical entity in T704M mutation in periodic paralysis. J Clin Neurosci. 2020;78:203–6.

15. Akaba Y, Takahashi S, Sasaki Y, et al. Successful treatment of normokalemic periodic paralysis with hydrochlorothiazide. Brain Dev. 2018;40(9):833–6.

16. Politano L. Lifestyle and dietary measures in periodic paralyses. Acta Myol. 2026;45(1):9–13.

17. Bisciglia M, Kadhim H, Lecomte S, et al. Early-onset autosomal dominant myopathy with vacuolated fibers and tubular aggregates but no periodic paralysis, in a patient with the c.1583G>A (p.R528H) mutation in the CACNA1S gene. J Neuromuscul Dis. 2024;11(4):871–5.

18. Brancati F, Valente EM, Davies NP, et al. Severe infantile hyperkalaemic periodic paralysis and paramyotonia congenita: broadening the clinical spectrum associated with the T704M mutation in SCN4A. J Neurol Neurosurg Psychiatry. 2003;74(9):1339–41.

19. Matthews E, Portaro S, Ke Q, et al. Acetazolamide efficacy in hypokalemic periodic paralysis and the predictive role of genotype. Neurology. 2011;77(22):1960–4.

20. Dejthevaporn C, Papsing C, Phakdeekitcharoen B, et al. Long-term effectiveness of acetazolamide on permanent weakness in hyperkalemic periodic paralysis. Neuromuscul Disord. 2013;23(5):445–9.

Table 1. Clinical timeline and available diagnostic information

Time	Available event or finding
About age 2 / age 8	Family recalls early transient weakness; recurrent recognizable attacks from age 8.
October 15, 2025	Serum potassium 4.54 mmol/L (reference interval, 3.50–5.10 mmol/L); attack and treatment status undocumented.
February 26, 2026	Genetic result dated in discharge record: heterozygous SCN4A c.2111C>T (p.Thr704Met).
March 23, 2026	Admission with mild leg weakness; potassium 5.09 mmol/L before medication according to treating clinician (reported local interval, 3.50–5.10 mmol/L); time from symptom onset unavailable.
March 24–25, 2026	24-hour urine collection/report: potassium 80.14 mmol/day (reference interval, 25.00–100.00 mmol/day).
March 26 / March 31, 2026	Thigh MRI dated March 26; discharge March 31. Muscle biopsy showed vacuolar changes and tubular aggregates; biopsy date unavailable.
During hospitalization and 1 month after discharge	No appreciable improvement reported with inpatient oral potassium chloride and spironolactone. After discharge, oral acetazolamide 250 mg twice daily; fewer attacks and symptomatic improvement reported at 1 month, without quantified post-treatment attack counts.

Figure legends

Fig. 1 Pedigree and proband sequencing trace. A Reported family history. The arrow identifies the proband; the asterisk denotes the reported SCN4A c.2111C>T (p.Thr704Met) finding in the proband. Filled symbols indicate reported symptoms, not molecular confirmation in relatives. Diagonal lines indicate deceased individuals. B Proband sequencing trace with the laboratory's original arrow marking the reported variant position. The laboratory sample identifier has been masked. The variant was reported as likely pathogenic.

Fig. 2 Axial magnetic resonance images of the thighs. A, B Representative images showing bilateral differences in muscle signal. Arrows indicate regions of altered signal in the posterior thigh musculature.

Fig. 3 Histopathology and ultrastructure of the left biceps brachii. A Hematoxylin and eosin staining shows fiber-size variation, vacuoles, and mild interstitial connective tissue proliferation. B Nicotinamide adenine dinucleotide–tetrazolium reductase staining. C Periodic acid–Schiff staining shows no glycogen accumulation within vacuoles. D Succinate dehydrogenase staining shows uniform mitochondrial distribution. E Modified Gomori trichrome staining demonstrates red-stained tubular aggregates without ragged red fibers. F Nicotinamide adenine dinucleotide–tetrazolium reductase staining shows reduced activity in vacuolated areas (solid arrows) and intensely stained tubular aggregates (hollow arrows). Asterisks indicate interstitial connective tissue proliferation where marked. Scale bars: 100 µm in A–E; 50 µm in F. G Transmission electron microscopy shows aggregates of tightly packed, parallel tubules (arrows). Original magnification, ×20,000; scale bar, 1.0 µm.

373 **Figure 1**

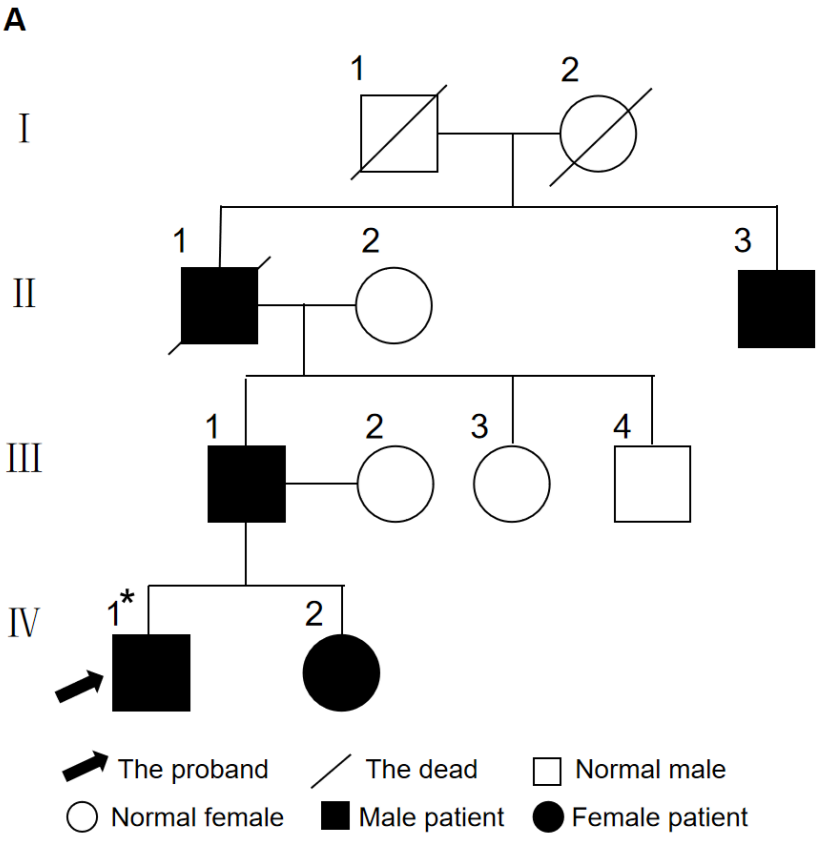
A
I
1
2
II
1
2
3
III
1
2
3
4
IV
1*
2
The proband
The dead
Normal male
Normal female
Male patient
Female patient

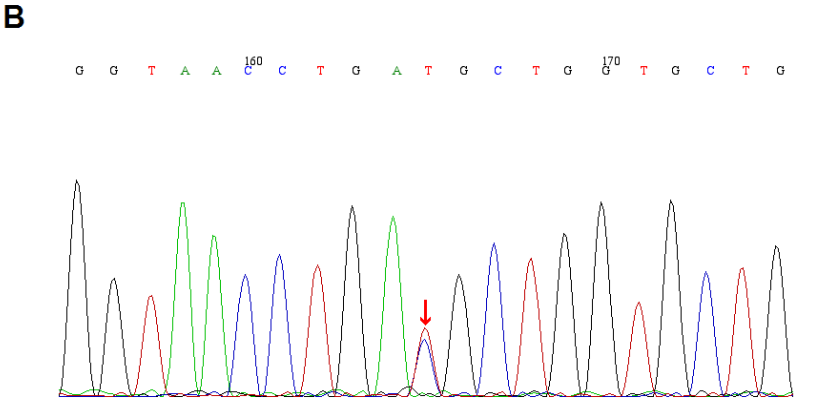
B
G G T A A C C T G A T G C T G G T G C T G
160
170

374 **Figure 2**

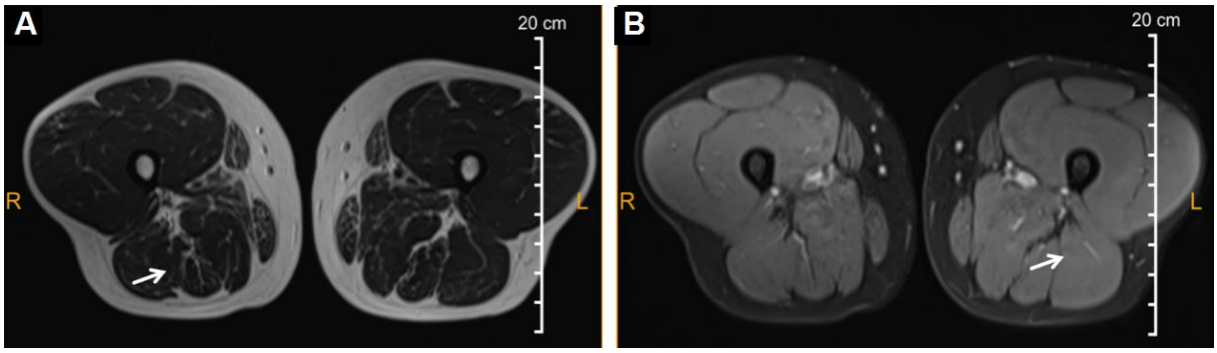

375 **Figure 3**

