Research Square

Preprints are preliminary reports that have not undergone peer review.
They should not be considered conclusive, used to inform clinical practice,
or referenced by the media as validated information.

Laparoscopic appendectomy for uncomplicated acute appendicitis in Gabon: a retrospective single-center study of 189 patients

Crépin OLLENDE[1]
Hôpital d'instruction des armées d'Akanda
Jerry Christopher LESSIMAMBOU JOHNSON ANANI
Hôpital d'instruction des armées d'Akanda
Sergina IPOUKA DOUSSIEMOU
Centre Hospitalier universitaire de Libreville
SP NGUELE NDJOTA
nguelendjota@yahoo.fr

Centre Hospitalier universitaire de Libreville
Kevin DYATTA MAYOMBO
Centre Hospitalier universitaire de Libreville
François ONDO NDONG
Centre Hospitalier universitaire de Libreville

Research Article

Keywords: Acute appendicitis, appendectomy, laparoscopy, postoperative follow-up, Gabon

Posted Date: November 24th, 2026

DOI: https://doi.org/10.21203/rs.3.rs-11673030/v1

License: This work is licensed under a Creative Commons Attribution 4.0 International License.
Read Full License

Additional Declarations: No competing interests reported.

Abstract

Background

We describe operative and short-term postoperative outcomes of laparoscopic appendectomy for uncomplicated acute appendicitis at Akanda Military Teaching Hospital in Gabon.

Methods

This retrospective descriptive study included patients who underwent laparoscopic appendectomy for uncomplicated acute appendicitis between January 2021 and December 2024. We reviewed all patients at one and three months after surgery.

Results

The series comprised 189 of 478 patients (39.5%) who underwent an initial laparoscopic approach for a non-traumatic digestive emergency. The cohort included 107 males (56.6%) and 82 females (43.4%). Mean age was 32 ± 14 years (range, 10–88). Mean operative time was 40 ± 12 minutes. Mean hospital stay was two days (range, 1–5). No postoperative complications or deaths were recorded.

Conclusions

Laparoscopic appendectomy was feasible in this selected series, with a short hospital stay and no recorded postoperative complications through three months. The design precludes comparison with open appendectomy.

Background

Laparoscopic appendectomy is widely used for acute appendicitis. Comparative studies have reported benefits in postoperative recovery and length of stay [1, 2]. Access to laparoscopy varies across African settings, where equipment, staffing, and other resources influence implementation [3, 4]. We describe operative outcomes and three-month follow-up after laparoscopic appendectomy for uncomplicated acute appendicitis at Akanda Military Teaching Hospital.

Methods

We conducted a retrospective, descriptive, single-center study in the digestive, visceral, and oncological surgery department from January 2021 to December 2024. We included patients admitted with uncomplicated acute appendicitis who were managed laparoscopically. Patients referred from other institutions for reoperation and those undergoing primary laparotomy were excluded.

We collected data from medical records using an individual extraction form and analyzed them descriptively in Microsoft Excel 2016. We recorded age, sex, operative time, length of stay, and postoperative outcomes. Quantitative variables are summarized as means with standard deviations or ranges, as available. Categorical variables are reported as counts and percentages. We reviewed patients at one and three months after surgery.

Results

Of the 478 patients managed with an initial laparoscopic approach for a non-traumatic digestive emergency, 189 (39.5%) had uncomplicated acute appendicitis. The series included 107 male patients and 82 female patients (Fig. 1). Mean age was 32 ± 14 years (range, 10–88). Mean operative time was 40 ± 12 minutes. We removed the appendix in a sterile glove used as a retrieval bag in all cases after ligation of the appendiceal base (Figs. 2 and 3). Mean hospital stay was two days (range, 1–5). All patients attended both postoperative visits. No postoperative complications or deaths were recorded. Table 1 summarizes operative time and length of stay.

Table 1
Operative time and length of hospital stay in the 189 patients.

Parameter	Value
Patients, n	189
Mean operative time	40 ± 12 minutes
Mean hospital stay	2 days
Range of hospital stay	1–5 days

Discussion

This series documents the use of laparoscopic appendectomy for uncomplicated acute appendicitis in a single Gabonese surgical unit. Complete follow-up at one and three months describes short-term outcomes in the selected patients.

The Cochrane review by Jaschinski et al. reported less first-day pain, fewer wound infections, shorter hospital stays, and earlier return to usual activity after laparoscopy in adults, alongside a higher risk of intra-abdominal abscess in the adult trials analyzed and variable certainty across outcomes [5]. In rural Kenya, Otoki et al. reported a two-day hospital stay after laparoscopic appendectomy versus four days after open surgery, with fewer superficial wound infections. Its retrospective design leaves room for selection bias [2].

Local implementation depends on surgical and anesthesia training, equipment availability, and maintenance. The Cesena guidelines support an initial laparoscopic approach in stable patients when

appropriate expertise and resources are available [6]. Conversion should remain available if safe exposure, dissection, or source control cannot be achieved. The use of a sterile glove illustrates an adaptation to available equipment. This study did not assess its equivalence to a commercial retrieval bag.

Limitations include retrospective data collection, selection of patients treated laparoscopically, the single-center setting, absence of a comparator, and follow-up limited to three months. The study did not assess pain, time to return to activity, or costs.

Conclusions

Laparoscopic appendectomy for uncomplicated acute appendicitis was feasible in this setting. The observed outcomes describe selected patients with complete short-term follow-up.

Declarations

Ethics approval and consent to participate.

The Ethics Committee of Akanda Military Teaching Hospital (HIAA), Gabon, approved this study. Patient data were anonymized. Informed consent to participate was obtained from all participants. The study was conducted in accordance with applicable ethical guidelines and regulations. No interventions or analyses of human tissue samples were performed for research purposes.

Consent for publication

The manuscript contains no identifiable patient information or images.

Availability of data and materials

The data supporting the findings of this study are available from the corresponding author upon reasonable request, subject to institutional approval and patient confidentiality requirements.

Competing interests

The authors declare no competing interests.

Funding

This study received no funding.

Authors' contributions

All authors contributed to the study, critically revised the manuscript for important intellectual content, and approved the final version for submission.

Acknowledgements

Not applicable.

Declaration of generative AI use

The authors used ChatGPT (OpenAI) to assist with English translation and language editing. They reviewed and edited the resulting text and take full responsibility for the final manuscript.

Related manuscript

The 189 patients with uncomplicated acute appendicitis included in this study are a subgroup of the 478 patients with non-traumatic digestive emergencies described in a manuscript submitted to the *Pan African Medical Journal* (submission no. 56151). This study focuses on operative outcomes and postoperative follow-up at one and three months in this subgroup.

References

1. Abass MO, Abdullah YA, Elssayed EO, Mhammed AB, Alfaki MS. Clinical outcomes of laparoscopic versus open appendectomy for acute appendicitis in a resource-limited setting. Ann Afr Surg. 2021;18(4):225–9.
2. Otoki K, Simel I, Moenga D, Chesang P, Parker RK. Laparoscopic appendectomy improves outcomes and reduces costs in rural Kenya. Surg Endosc. 2025;39(4):2191–7. 10.1007/s00464-025-11589-5.
3. Yankunze Y, Mwachiro MM, Lando JO, et al. Laparoscopy experience in East, Central, and Southern Africa: insights from operative case volume analysis. Surg Endosc. 2024;38:4415–21.
4. Naidoo M, Thirayan V, Kong V, et al. Trends in adoption of laparoscopic appendicectomy in a developing country: closing the gap. World J Surg. 2022;46(5):1015–21.
5. Jaschinski T, Mosch CG, Eikermann M, Neugebauer EAM, Sauerland S. Laparoscopic versus open surgery for suspected appendicitis. Cochrane Database Syst Rev. 2018;11(11):CD001546. 10.1002/14651858.CD001546.pub4.
6. Sermonesi G, Tian BWCA, Vallicelli C, Abu-Zidan FM, Damaskos D, Kelly MD, et al. Cesena guidelines: WSES consensus statement on laparoscopic-first approach to general surgery emergencies and abdominal trauma. World J Emerg Surg. 2023;18(1):57. 10.1186/s13017-023-00520-9.

Figures

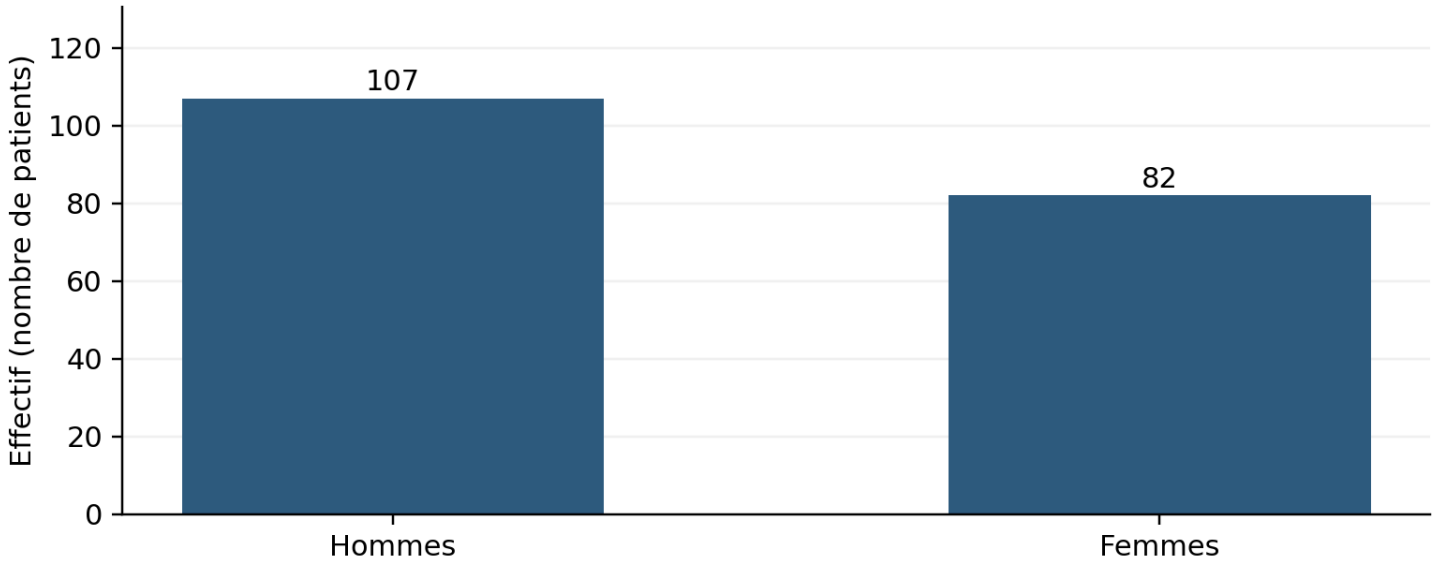

Figure 1

Distribution of the 189 patients by sex.

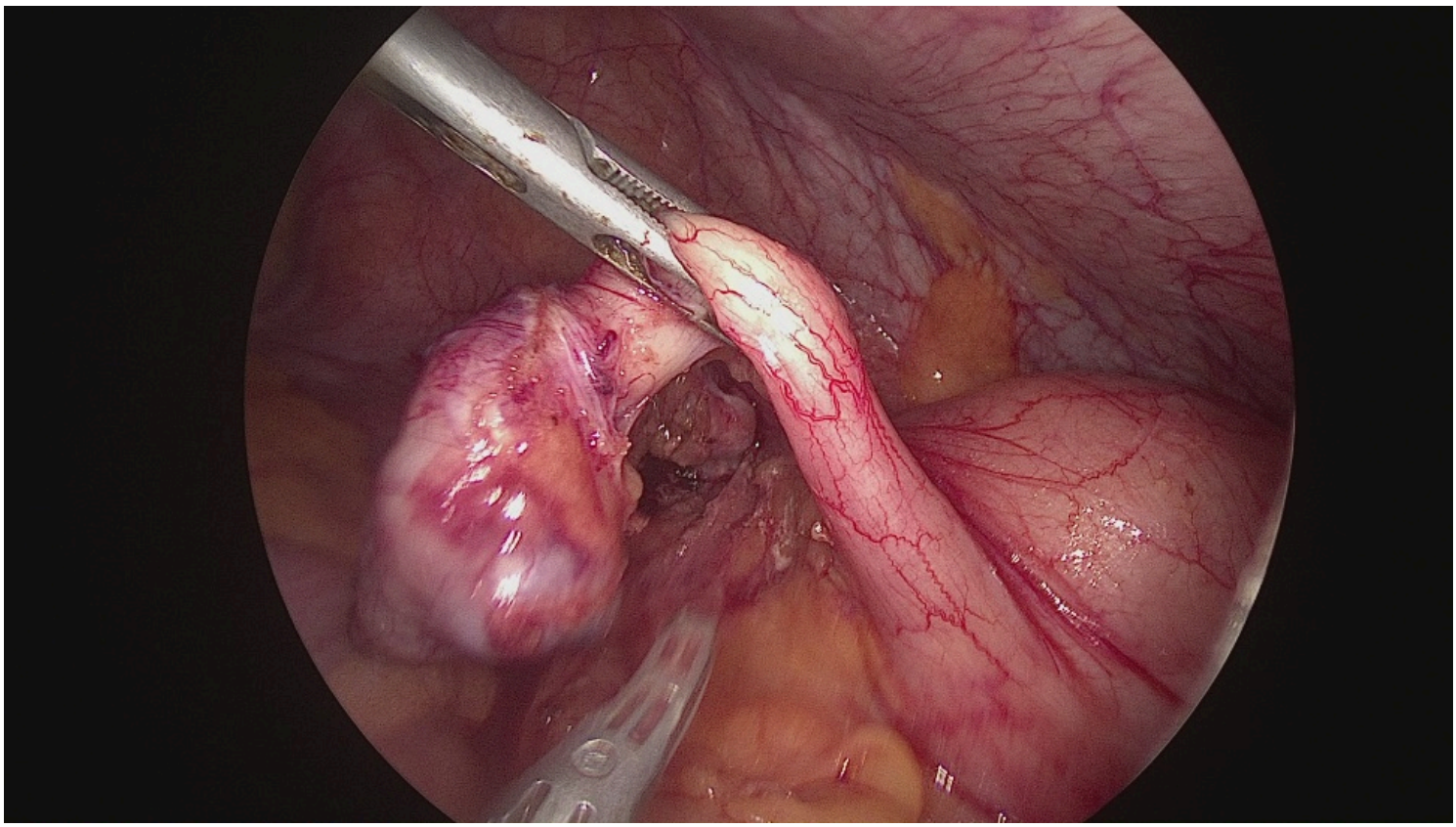

Figure 2

Laparoscopic view of acute appendicitis—source: Akanda Military Teaching Hospital.

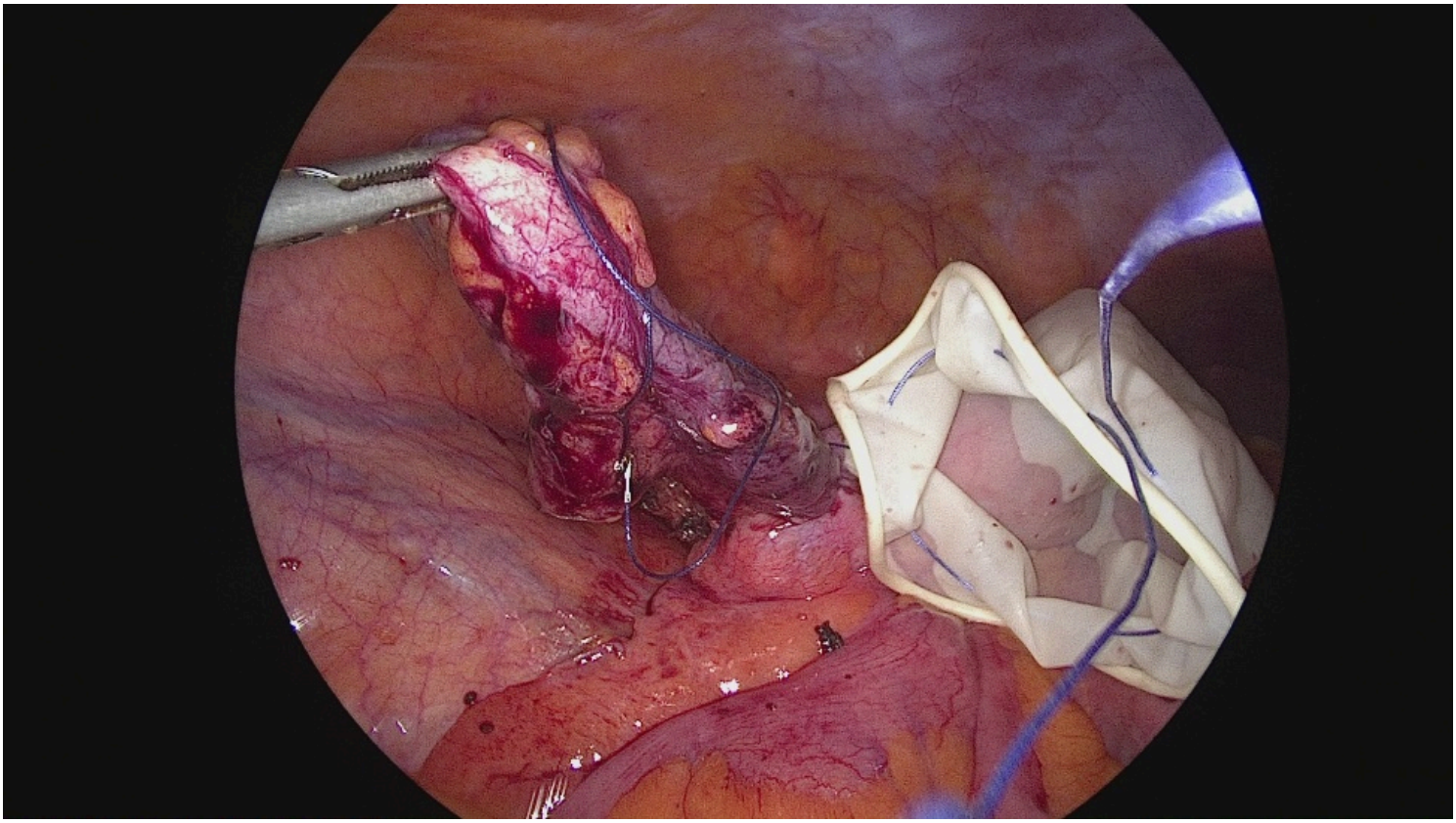

Figure 3

Appendectomy after ligation of the appendiceal base and specimen retrieval using a sterile glove. Source: Akanda Military Teaching Hospital.