Research Square

Preprints are preliminary reports that have not undergone peer review.
They should not be considered conclusive, used to inform clinical practice,
or referenced by the media as validated information.

Braided fully covered metal stents are associated with a higher risk of stent migration than plastic stents after endoscopic ultrasound-guided hepaticogastrostomy

Yu Honda
Yokohama City University Hospital
Yusuke Kurita
kuritay@yokohama-cu.ac.jp

Yokohama City University Hospital
Tomoki Ogata
Yokohama City University Hospital
Shin Yagi
Yokohama City University Hospital
Takamitsu Sato
Yokohama City University Hospital
Takayuki Oda
Yokohama City University Hospital
Takeshi Iizuka
Yokohama City University Hospital
Sho Hasegawa
Yokohama City University Hospital
Kensuke Kubota
Yokohama City University Hospital
Masato Yoneda
Yokohama City University Hospital

Research Article

Keywords: Endoscopic ultrasound-guided hepaticogastrostomy, fully covered self-expandable metal stent, plastic stent, recurrent biliary obstruction, stent migration

Posted Date: November 23rd, 2026

DOI: https://doi.org/10.21203/rs.3.rs-11670735/v1

License: This work is licensed under a Creative Commons Attribution 4.0 International License.
Read Full License

Additional Declarations: No competing interests reported.

Abstract

Background

Endoscopic ultrasound-guided hepaticogastrostomy (EUS-HGS) is an established biliary drainage procedure when transpapillary access is difficult; however, stent migration can occur. This study compared stent migration between plastic stents (PS) and fully covered self-expandable metal stents (FCSEMS) after EUS-HGS.

Methods

This single-center retrospective cohort study included patients who underwent initial EUS-HGS with PS alone or FCSEMS alone between July 2014 and March 2025. The primary endpoint was stent migration. Secondary endpoints included technical and clinical success, recurrent biliary obstruction (RBO), time to RBO (TRBO), adverse events, and factors associated with migration.

Results

Of 116 patients, 107 were analyzed: 48 in the PS group and 59 in the FCSEMS group. All FCSEMS were braided-type stents. Technical success (95.8% vs. 98.3%, $P = 0.586$) and clinical success (95.7% vs. 94.8%, $P = 1.000$) were comparable. Adverse event rates did not differ significantly between the groups. Stent migration was significantly more frequent in the FCSEMS group than in the PS group (34.5% vs. 4.3%, $P < 0.001$), whereas stent occlusion was less frequent (1.7% vs. 15.2%, $P = 0.021$). TRBO did not differ significantly (179 vs. 106 days; hazard ratio [HR], 1.78; 95% confidence interval [CI], 0.81–3.89; $P = 0.142$). Multivariate analysis identified FCSEMS placement as a factor associated with stent migration (HR, 8.52; 95% CI, 1.98–36.71; $P = 0.004$).

Conclusions

Braided-type FCSEMS were associated with a significantly higher risk of stent migration than PS after EUS-HGS. Therefore, the increased risk of stent migration should be carefully considered when selecting braided-type FCSEMS.

Introduction

Endoscopic retrograde cholangiopancreatography (ERCP) is the standard procedure for biliary drainage in patients with biliary obstruction [1]. However, ERCP may be difficult or unsuccessful in patients with duodenal obstruction, surgically altered anatomy, tumor invasion of the papilla, or hilar biliary strictures. In such cases, endoscopic ultrasound-guided biliary drainage (EUS-BD) has emerged as an alternative drainage approach [2, 3], and endoscopic ultrasound-guided hepaticogastrostomy (EUS-HGS) is

increasingly used when transpapillary biliary access is not feasible. Although EUS-HGS has shown high technical and clinical success rates, it is still associated with serious adverse events, such as bile leakage, bile peritonitis, bleeding, and stent-related complications [4–6].

Stent migration is one of the most clinically important adverse events after EUS-HGS because it can lead to recurrent biliary obstruction (RBO), bile leakage, peritonitis, and the need for urgent endoscopic or surgical reintervention [7–11]. Although self-expandable metal stents (SEMS) and plastic stents (PS) are commonly used for EUS-HGS, evidence remains limited regarding whether the risk of stent migration differs by stent type. In particular, it is unclear whether this risk differs between fully covered self-expandable metal stents (FCSEMS) and PS. Furthermore, risk factors for stent migration after EUS-HGS remain unclear. Therefore, we conducted a single-center retrospective cohort study to compare stent migration of PS and FCSEMS in EUS-HGS, including efficacy and safety. We also aimed to identify factors associated with stent migration after EUS-HGS.

Methods

Patients

This single-center retrospective cohort study included patients who underwent initial EUS-HGS at Yokohama City University Hospital between July 2014 and March 2025. Eligible patients were those who underwent EUS-HGS with either PS alone or FCSEMS alone. Patients who received a partially covered metal stent or underwent simultaneous placement of PS and FCSEMS were excluded.

The study protocol was approved by the institutional review board of Yokohama City University Hospital [B200600003]. The requirement for written informed consent was waived because of the retrospective nature of the study, and an opt-out approach was used.

EUS-HGS procedure

EUS-HGS was performed using an endoscopic ultrasound system (EU-ME2 and GF-UCT260; Olympus, Tokyo, Japan). The dilated intrahepatic bile duct was visualized from the stomach, and the B2 or B3 bile duct was selected as the puncture site according to bile duct dilatation, anatomical accessibility, and the absence of intervening vessels. The target bile duct was punctured using a 19-gauge or 22-gauge needle (Sono Tip Pro Control; Medi-Globe GmbH, Rosenheim, Germany; Expect; Boston Scientific, Boston, MA, USA; or EZ shot 3 plus; Olympus, Tokyo, Japan) under endoscopic ultrasound guidance with color Doppler imaging. After bile aspiration, cholangiography was performed to confirm the bile duct anatomy.

A guidewire was then inserted into the bile duct. A 0.025-inch guidewire, either VisiGlide 2 (Olympus, Tokyo, Japan) or Fielder 25 (Asahi Intec, Aichi, Japan), was used after puncture with a 19-gauge needle, whereas a 0.018-inch guidewire (Fielder 18; Asahi Intec, Aichi, Japan) was used after puncture with a 22-gauge needle. After guidewire placement, the fistula was initially dilated using a bougie dilator (ES

Dilator; Zeon Medical, Tokyo, Japan) or a drill dilator (Tornus ES; Olympus, Tokyo, Japan). If the stent delivery system could not pass through the fistula, additional dilation was performed using balloon dilator (REN; KANEKA, Osaka, Japan), and/or cautery dilator (Fine025; Medico's Hirata Inc., Tokyo, Japan) at the discretion of the endoscopist. Finally, either a PS or a FCSEMS was deployed from the left intrahepatic bile duct to the stomach.

The PS used in this study included Through & Pass Type IT (single pigtail type; Gadelius Medical, Tokyo, Japan), Through & Pass Straight (straight type; Gadelius Medical, Tokyo, Japan), Flexima Biliary Stent (straight type; Boston Scientific, Tokyo, Japan), and Suzaku Biliary Plastic Stent (straight type; KANEKA, Osaka, Japan). The PS were 7 Fr in diameter and 10, 12, 14, or 15 cm in length. The FCSEMS used in this study included the Niti-S S-type biliary stent (Taewoong Medical, Seoul, Korea), EGIS Biliary Full Cover Stent (SB-KAWASUMI Laboratories, Kanagawa, Japan), HANAROSTENT biliary Full Cover Benefit (Boston Scientific, Tokyo, Japan), and WallFlex biliary full-covered stent (Boston Scientific, Tokyo, Japan). All FCSEMS were braided type and 6 or 8 mm in diameter and 10 or 12 cm in length. The final selection of the stent type and device was determined by the endoscopist based on clinical judgment.

Endpoints and definitions

The primary endpoint was the rate of stent migration after EUS-HGS. Secondary endpoints were technical success, clinical success, recurrent biliary obstruction (RBO), time to recurrent biliary obstruction (TRBO), adverse events, and factors associated with stent migration.

Technical success was defined as successful placement of a PS or an FCSEMS at the intended site in the bile duct. Clinical success was evaluated in patients with technical success and was defined as a decrease in the serum total bilirubin level of at least 50% or normalization of the serum total bilirubin level within 14 days after EUS-HGS.

RBO was evaluated in patients with technical success and was defined as a composite endpoint that included stent occlusion or stent migration resulting in recurrent biliary obstruction, or any other condition requiring biliary drainage or stent removal. TRBO was defined as the interval from EUS-HGS stent placement to the occurrence of RBO.

Stent migration was also evaluated in patients with technical success and was defined as a dislocation of a stent on endoscopic findings or imaging studies that is assumed to be a cause of recurrent biliary obstruction (Fig. 1). Stent occlusion was defined as biliary obstruction caused by sludge, food impaction, reactive mucosal hyperplasia, hemobilia, tumor ingrowth, tumor overgrowth, or others.

Adverse events were defined as procedure-related complications after EUS-HGS and included bile peritonitis, bleeding, and other clinically relevant complications. The severity of adverse events was graded according to the American Society for Gastrointestinal Endoscopy lexicon [12].

Factors evaluated for their association with stent migration included age, sex, disease type (malignant or benign), presence of ascites, concomitant systemic anticancer therapy, puncture site (B2 or B3), bile duct diameter, needle size (19G or 22G), dilation device, and stent type (PS or FCSEMS).

Statistical analysis

Continuous variables are presented as medians with ranges and were compared using the Mann–Whitney U test. Categorical variables are presented as numbers and percentages and were compared using the chi-square test or Fisher's exact test, as appropriate.

TRBO and time to stent migration were estimated using the Kaplan–Meier method, and differences between the PS and FCSEMS groups were evaluated using the log-rank test. Hazard ratios (HRs) and 95% confidence intervals (CIs) were estimated using univariable Cox proportional hazards regression analysis. Patients without RBO or stent migration were censored at the last follow-up or death for the respective analyses. Factors associated with stent migration were evaluated using Cox proportional hazards regression analysis. Variables with a *P* value < 0.05 in the univariate analysis were included in the multivariate analysis.

All statistical tests were two-sided, and a *P* value < 0.05 was considered statistically significant. All statistical analyses were performed using SPSS Statistics version 30.0 (IBM Corp., Armonk, NY, USA).

Results

Patient characteristics

A total of 116 patients underwent initial EUS-HGS during the study period. Nine patients were excluded because they received a partially covered metal stent (n = 7) or underwent simultaneous placement of PS and FCSEMS (n = 2). Finally, 107 patients were included in the analysis, comprising 48 patients in the PS group and 59 patients in the FCSEMS group (Fig. 2).

The baseline characteristics are shown in Table 1. There were no statistically significant differences between the PS and FCSEMS groups in age, sex, primary disease, indication for EUS-HGS, presence of ascites, or concomitant systemic anticancer therapy.

Table 1
Patient characteristics

Age (years), median (range)	**All patients**	**PS group**	**FCSEMS group**	***P*-value**
	n = 107	**n = 48**	**n = 59**	
	71 (36–91)	**69 (36–88)**	**72 (36–91)**	**0.112**
Sex, male (%)	62 (57.9)	29 (60.4)	33 (55.9)	0.696
Primary disease (%)				0.058
Pancreatobiliary cancer	75 (70.1)	29 (60.4)	46 (78.0)	
Others	32 (29.9)	19 (39.6)	13 (22.0)	
Indication for EUS-HGS (%)				0.148
Gastrointestinal stenosis	34 (31.8)	13 (27.1)	21 (35.6)	
Hilar stenosis	32 (29.9)	14 (29.2)	18 (30.5)	
Surgically altered anatomy	25 (23.4)	15 (31.3)	10 (16.9)	
Not completed or failed ERCP	14 (13.1)	4 (8.3)	10 (16.9)	
Others	2 (1.9)	2 (4.2)	0 (0.0)	
Ascites (%)	24 (22.4)	9 (18.8)	15 (25.4)	0.410
Concomitant systemic anticancer therapy (%)	39 (36.4)	16 (33.3)	23 (39.0)	0.546

ERCP, Endoscopic retrograde cholangiopancreatography; EUS-HGS, Endoscopic ultrasound-guided hepaticogastrostomy; FCSEMS, Fully covered self-expandable metal stent; PS, Plastic stent

Procedure details

The procedure details are shown in Table 2. The puncture site, bile duct diameter, needle size, and procedure time did not differ significantly between the PS and FCSEMS groups. Balloon dilation was performed more frequently in the FCSEMS group than in the PS group (49.2% vs. 27.1%, $P = 0.028$), whereas drill dilation was performed more frequently in the PS group than in the FCSEMS group (16.7% vs. 1.7%, $P = 0.010$).

Table 2
Procedure details

Puncture site (%)	**All patients**	**PS group**	**FCSEMS group**	***P*-value**
	n = 107	**n = 48**	**n = 59**	
				0.174
B2	26 (24.3)	15 (31.3)	11 (18.6)	
B3	81 (75.7)	33 (68.8)	48 (81.4)	
Bile duct diameter (mm), median (range)	5.60 (2.5–15)	5.35 (2.5–15)	5.80 (3.0–15)	0.431
Needle (%)				1.000
19G	92 (86.0)	41 (85.4)	51 (86.4)	
22G	15 (14.0)	7 (14.6)	8 (13.6)	
Fistula dilation				
Balloon dilator (%) [a]	42 (39.3)	13 (27.1)	29 (49.2)	0.028
Drill dilator (%) [a]	9 (8.4)	8 (16.7)	1 (1.7)	0.010
Bougie dilator (%) [a]	101 (94.4)	45 (93.8)	56 (94.9)	0.728
Cautery dilator (%) [a]	6 (5.6)	1 (2.1)	5 (8.5)	0.221
Plastic stent (%)				
Single pigtail type		30 (62.5)		
Straight type		18 (37.5)		
Stent length 10/12/14/15 cm		1/3/40/4		
Stent diameter 7 Fr		48 (100)		
Fully covered metal stent (%)				
Braided type			59 (100)	
Stent length 10/12 cm			12/47	
Stent diameter 6/8 mm			56/3	

B2, Bile duct of segment 2 of the liver; B3, Bile duct of segment 3 of the liver; FCSEMS, Fully covered self-expandable metal stent; PS, Plastic stent

[a] Duplicated number

Puncture site (%)	All patients n = 107	PS group n = 48	FCSEMS group n = 59	*P*-value
				0.174
Procedure time (min), median (range)	35 (14–271)	38 (14–271)	33 (16–89)	0.182
B2, Bile duct of segment 2 of the liver; B3, Bile duct of segment 3 of the liver; FCSEMS, Fully covered self-expandable metal stent; PS, Plastic stent				
[a] Duplicated number				

Clinical outcomes and stent migration

The clinical outcomes are shown in Table 3. Technical success was achieved in 46 patients (95.8%) in the PS group and 58 patients (98.3%) in the FCSEMS group (*P* = 0.586). Clinical success was achieved in 44 patients (95.7%) in the PS group and 55 patients (94.8%) in the FCSEMS group (*P* = 1.000). The rates of bile peritonitis and bleeding did not differ significantly between the two groups.

Table 3
Clinical outcomes

Technical success (%)	**All patients**	**PS group**	**FCSEMS group**	***P*-value**
	104/107 (97.2)	**46/48 (95.8)**	**58/59 (98.3)**	**0.586**
Clinical success (%)	99/104 (95.2)	44/46 (95.7)	55/58 (94.8)	1.000
Adverse event				
Bile peritonitis (%)	9/107 (8.4)	3/48 (6.3)	6/59 (10.2)	0.728
Bleeding (%)	1/107 (0.9)	0/48 (0.0)	1/59 (1.7)	1.000
RBO	30/104 (28.8)	9/46 (19.6)	21/58 (36.2)	0.082
Stent occlusion (%)	8/104 (7.7)	7/46 (15.2)	1/58 (1.7)	0.021
Stent migration (%)	22/104 (21.2)	2/46 (4.3)	20/58 (34.5)	< 0.001
Stent migration rate at 2 months (%) [a]	17.0 (9/53)	0.0 (0/19)	26.5 (9/34)	0.019
Stent migration rate at 3 months (%) [a]	42.1 (16/38)	0.0 (0/9)	55.2 (16/29)	0.005
Time to migration (days), median (95% CI)	179 (132–226)	Not reached	106 (60–152)	0.001
TRBO (days), median (95% CI)	153 (87–219)	179 (147–211)	106 (66–146)	0.142
Follow-up duration after EUS-HGS (days), median (range)	50 (2–787)	50 (7–274)	50 (2–787)	0.960

CI, Confidence interval; EUS-HGS, Endoscopic ultrasound-guided hepaticogastrostomy; FCSEMS, Fully covered self-expandable metal stent; PS, Plastic stent; RBO, Recurrent biliary obstruction; TRBO, Time to recurrent biliary obstruction

[a] Values in parentheses indicate the number of patients with stent migration divided by the number of evaluable patients at each time point

Stent occlusion was more frequent in the PS group than in the FCSEMS group (15.2% vs. 1.7%, P = 0.021). Stent migration occurred in 22 patients overall, and the migration rate was significantly higher in the FCSEMS group than in the PS group (34.5% [20/58] vs. 4.3% [2/46], P < 0.001). Stent migration at 2 months was observed in 9 of 34 evaluable patients (26.5%) in the FCSEMS group and in none of 19 evaluable patients (0.0%) in the PS group (P = 0.019). At 3 months, stent migration was observed in 16 of 29 evaluable patients (55.2%) in the FCSEMS group and in none of 9 evaluable patients (0.0%) in the PS group (P = 0.005). The median time to stent migration was not reached in the PS group and was 106

days in the FCSEMS group. Time to stent migration was significantly shorter in the FCSEMS group than in the PS group (HR 7.59; 95% CI, 1.77–32.51; log-rank *P* = 0.001) (Fig. 3a).

Overall RBO occurred in 9 patients (19.6%) in the PS group and 21 patients (36.2%) in the FCSEMS group, with no statistically significant difference between the two groups (*P* = 0.082). The median TRBO was 179 days in the PS group and 106 days in the FCSEMS group. TRBO did not differ significantly between the two groups (HR 1.78; 95% CI, 0.81–3.89; log-rank *P* = 0.142) (Fig. 3b).

Factors associated with stent migration

Factors associated with stent migration are shown in Table 4. In the univariate analysis, female sex and FCSEMS placement were significantly associated with stent migration. In the multivariate analysis, FCSEMS placement was associated with a higher risk of stent migration (HR 8.52; 95% CI, 1.98–36.71; *P* = 0.004). Female sex was also associated with a higher risk of stent migration (HR 3.12; 95% CI, 1.29–7.45; *P* = 0.011).

Table 4
Factors associated with stent migration

Age (≥ 75 years)	**Univariate analysis; HR (95% CI)**	***P*-value**	**Multivariate analysis; HR (95% CI)**	***P*-value**
	0.61 (0.25–1.50)	**0.280**		
Sex, female	2.64 (1.12–6.21)	0.027	3.12 (1.29–7.45)	0.011
Malignancy	1.25 (0.29–5.40)	0.761		
Ascites	0.38 (0.09–1.63)	0.192		
Concomitant systemic anticancer therapy	1.99 (0.85–4.65)	0.111		
Puncture site, B3	1.70 (0.57–5.03)	0.339		
Bile duct diameter (≥ 5 mm)	0.78 (0.34–1.82)	0.572		
Needle, 22G	0.62 (0.18–2.11)	0.442		
Balloon dilator	1.39 (0.60–3.22)	0.448		
Bougie dilator	0.46 (0.11–2.03)	0.306		
Drill dilator	1.10 (0.15–8.31)	0.926		
Cautery dilator	0.04 (0.00–32.70)	0.352		
FCSEMS	7.59 (1.77–32.51)	0.006	8.52 (1.98–36.71)	0.004

B3, Bile duct of segment 3 of the liver; CI, confidence interval; FCSEMS, Fully covered self-expandable metal stent; HR, Hazard ratio

Discussion

In this single-center retrospective cohort study, FCSEMS were associated with a significantly higher risk of stent migration than PS after EUS-HGS. Technical and clinical success rates were comparable between the two groups, whereas multivariate analysis identified FCSEMS placement as a factor associated with stent migration. These findings suggest that the risk of stent migration, in addition to stent patency, should be carefully considered when selecting a stent for EUS-HGS.

Several factors may explain the higher migration risk observed in the FCSEMS group. A previous study using partially covered SEMS reported that a longer distance between the stomach and liver at the puncture site was associated with stent migration into the abdominal cavity after EUS-HGS [13]. This study suggested that puncture closer to the cardia may reduce migration risk by shortening the

stomach–liver distance. Because B2 puncture is generally considered to allow access closer to the cardia than B3 puncture, B2 puncture might be expected to shorten the stomach–liver distance. In this study, however, the puncture site was not associated with stent migration. Therefore, the higher migration rate observed in the FCSEMS group cannot be fully explained by the previously reported anatomical factor alone, and stent-related mechanical properties should also be considered. Female sex was also associated with stent migration in this study; however, this finding should be interpreted cautiously because no clear mechanism has been established to explain this association. This result may reflect residual confounding or a chance finding, and further studies are needed to validate this observation.

Stent-related mechanical properties may also have contributed to the higher migration risk in the FCSEMS group. Unlike transpapillary biliary stenting across a malignant stricture, EUS-HGS stents are placed through a newly created fistula between the intrahepatic bile duct and the stomach, and the stent does not necessarily traverse a tight tumor-related stricture that provides firm anchoring. In addition, the covered membrane of FCSEMS prevents tissue ingrowth, which may reduce fixation within the fistula tract [14]. Other mechanical factors, including stent shortening, axial force, and the lack of dedicated anti-migration structures such as flanges, may also affect anchoring. In contrast, PS may have structural advantages for migration prevention, particularly when anti-migration features such as a pigtail structure or flanges are present [15]. These differences in stent structure may partly explain why FCSEMS were associated with a higher risk of stent migration than PS.

The higher migration risk with FCSEMS and the higher stent occlusion rate with PS have implications for stent selection in EUS-HGS. Previous studies have reported better stent patency with FCSEMS or metal stents than with PS in EUS-guided biliary drainage and EUS-HGS [16, 17]. However, a recent large single-center study showed that although metal stents were associated with longer overall stent patency, PS provided comparable patency within the first 100 days after EUS-HGS [18]. In this study, stent occlusion was less frequent in the FCSEMS group than in the PS group. The lower occlusion rate in the FCSEMS group is clinically plausible because the larger lumen of FCSEMS may reduce the likelihood of stent occlusion [19]. However, this advantage was offset by the higher rate of stent migration, resulting in no significant difference in TRBO between the two groups. Therefore, PS may remain a reasonable option in EUS-HGS, particularly when prevention of stent migration is prioritized. Thus, both occlusion and migration risks should be considered when selecting a stent for EUS-HGS.

The high migration rate observed with braided-type FCSEMS may not be generalizable to all types of metal stents used for EUS-HGS. Laser-cut FCSEMS may have different mechanical properties from braided-type FCSEMS, including less shortening and potentially more stable deployment. In addition, partially covered SEMS with anti-migration structures may reduce the risk of migration by providing additional anchoring while maintaining the luminal advantage of SEMS [20, 21]. However, partially covered SEMS may make reintervention more difficult, particularly when hyperplasia prevents stent removal [22]. Therefore, further studies comparing PS, braided-type FCSEMS, laser-cut FCSEMS, and partially covered SEMS are needed to clarify the optimal stent design for EUS-HGS.

This study has several limitations. First, this was a retrospective single-center study, and stent selection was determined by the endoscopist based on clinical judgment. Selection bias and residual confounding therefore cannot be excluded. Second, the study period was long, and changes in devices, dilation strategy, and operator preference may have influenced outcomes. Third, all FCSEMS used in this study were braided-type stents; therefore, the findings may not be generalizable to other metal stent designs.

In conclusion, braided-type FCSEMS were associated with a significantly higher risk of stent migration than PS after EUS-HGS. Therefore, the increased risk of stent migration should be carefully considered when selecting braided-type FCSEMS.

Declarations

Running title

Stent migration after EUS-HGS

Declarations

Conflict of interest:

Authors declare no conflict of interest for this article.

Ethics approval and consent to participate:

This study was approved by the Institutional Review Board of Yokohama City University Hospital (approval no. B200600003). The requirement for written informed consent was waived because of the retrospective nature of the study, and an opt-out approach was used.

Funding:

None.

Author Contribution

Y.H.: Conceptualization, methodology, investigation, and writing—original draft. Y.K.: Supervision, conceptualization, methodology, investigation, and writing—review and editing. T.Og., S.Y., T.S., T.Od., T.I., and S.H.: Investigation and data analysis. K.K. and M.Y.: Supervision and clinical advice. All authors reviewed and approved the final manuscript.

Acknowledgement

The authors are grateful to N. Kobayashi, A. Ujiie, Y. Yamazaki, and K. Kato from Yokohama City University for their assistance with this study.

Data Availability

The datasets analyzed during the current study are not publicly available due to patient privacy and institutional restrictions but may be available from the corresponding author upon reasonable request and with appropriate approval.

References

1. Speer AG, Cotton PB, Russell RC, et al. Randomised trial of endoscopic versus percutaneous stent insertion in malignant obstructive jaundice. *Lancet*. 1987;2:57–62. https://doi.org/10.1016/s0140-6736(87)92733-4.
2. Nakai Y, Isayama H, Yamamoto N, et al. Indications for endoscopic ultrasonography (EUS)-guided biliary intervention: Does EUS always come after failed endoscopic retrograde cholangiopancreatography? *Dig Endosc*. 2017;29:218–225. https://doi.org/10.1111/den.12752.
3. Giovannini M, Moutardier V, Pesenti C, Bories E, Lelong B, Delpero JR. Endoscopic ultrasound-guided bilioduodenal anastomosis: a new technique for biliary drainage. *Endoscopy*. 2001;33:898–900. https://doi.org/10.1055/s-2001-17324.
4. Binda C, Dajti E, Giuffrida P, et al. Efficacy and safety of endoscopic ultrasound-guided hepaticogastrostomy: a meta-regression analysis. *Endoscopy*. 2024;56:694–705. https://doi.org/10.1055/a-2282-3350.
5. Giri S, Mohan BP, Jearth V, et al. Adverse events with EUS-guided biliary drainage: a systematic review and meta-analysis. *Gastrointest Endosc*. 2023;98:515–523.e518. https://doi.org/10.1016/j.gie.2023.06.055.
6. Kawakubo K, Isayama H, Kato H, et al. Multicenter retrospective study of endoscopic ultrasound-guided biliary drainage for malignant biliary obstruction in Japan. *J Hepatobiliary Pancreat Sci*. 2014;21:328–334. https://doi.org/10.1002/jhbp.27.
7. Okuno N, Hara K, Mizuno N, Hijioka S, Imaoka H, Yamao K. Stent migration into the peritoneal cavity following endoscopic ultrasound-guided hepaticogastrostomy. *Endoscopy*. 2015;47 Suppl 1 UCTN:E311. https://doi.org/10.1055/s-0034-1392314.
8. Martins FP, Rossini LG, Ferrari AP. Migration of a covered metallic stent following endoscopic ultrasound-guided hepaticogastrostomy: fatal complication. *Endoscopy*. 2010;42 Suppl 2:E126–127. https://doi.org/10.1055/s-0029-1243911.
9. Hijioka S, Sakamoto Y, Nagashio Y, Maruki Y, Okusaka T, Saito Y. Troubleshooting for endoscopic ultrasound-guided hepaticogastrostomy stent migration: Additional stenting by the partial stent-in-

stent method. *Endoscopy*. 2023;55:E122–e124. https://doi.org/10.1055/a-1941-8357.

10. Yane K, Imagawa T, Yoshida M. Spontaneous migration of a dedicated plastic stent after endoscopic ultrasound-guided hepaticogastrostomy in a patient with surgically altered anatomy: a case report. *J Rural Med*. 2024;19:196–198. https://doi.org/10.2185/jrm.2023-050.
11. Minaga K, Kitano M, Yamashita Y, Nakatani Y, Kudo M. Stent migration into the abdominal cavity after EUS-guided hepaticogastrostomy. *Gastrointest Endosc*. 2017;85:263–264. https://doi.org/10.1016/j.gie.2016.03.016.
12. Cotton PB, Eisen GM, Aabakken L, et al. A lexicon for endoscopic adverse events: report of an ASGE workshop. *Gastrointest Endosc*. 2010;71:446–454. https://doi.org/10.1016/j.gie.2009.10.027.
13. Ochiai K, Fujisawa T, Ishii S, et al. Risk Factors for Stent Migration into the Abdominal Cavity after Endoscopic Ultrasound-Guided Hepaticogastrostomy. *J Clin Med*. 2021;10:3111. https://doi.org/10.3390/jcm10143111.
14. Baron TH. Migration of covered expandable metal stents after endoscopic ultrasound-guided hepaticogastrostomy: stent covering versus stent design? *Clin Endosc*. 2024;57:471–472. https://doi.org/10.5946/ce.2024.158.
15. Umeda J, Itoi T, Tsuchiya T, et al. A newly designed plastic stent for EUS-guided hepaticogastrostomy: a prospective preliminary feasibility study (with videos). *Gastrointest Endosc*. 2015;82:390–396.e392. https://doi.org/10.1016/j.gie.2015.02.041.
16. Shibuki T, Okumura K, Sekine M, et al. Covered self-expandable metallic stents versus plastic stents for endoscopic ultrasound-guided hepaticogastrostomy in patients with malignant biliary obstruction. *Clin Endosc*. 2023;56:802–811. https://doi.org/10.5946/ce.2022.211.
17. Hashimoto S, Iwashita Y, Taguchi H, et al. Comparison of recurrent biliary obstruction with the use of metal and plastic stents in EUS-guided biliary drainage: A propensity score-matched analysis. *Endosc Ultrasound*. 2023;12:64–73. https://doi.org/10.4103/eus-d-21-00251.
18. Yamashige D, Hijioka S, Nagashio Y, et al. Metal stent versus plastic stent in endoscopic ultrasound-guided hepaticogastrostomy for unresectable malignant biliary obstruction: Large single-center retrospective comparative study. *Dig Endosc*. 2025;37:117–129. https://doi.org/10.1111/den.14956.
19. Lam R, Muniraj T. Fully covered metal biliary stents: A review of the literature. *World J Gastroenterol*. 2021;27:6357–6373. https://doi.org/10.3748/wjg.v27.i38.6357.
20. Ishii S, Isayama H, Sasahira N, et al. A pilot study of Spring Stopper Stents: Novel partially covered self-expandable metallic stents with anti-migration properties for EUS-guided hepaticogastrostomy. *Endosc Ultrasound*. 2023;12:266–272. https://doi.org/10.4103/eus-d-22-00104.
21. Anderloni A, Fugazza A, Spadaccini M, et al. Feasibility and safety of a new dedicated biliary stent for EUS-guided hepaticogastrostomy: The FIT study (with video). *Endosc Ultrasound*. 2023;12:59–63. https://doi.org/10.4103/eus-d-22-00023.
22. Iwasa Y, Maruta A, Iwata K, et al. Clinical Outcomes of Reintervention After Endoscopic Ultrasound-Guided Hepaticogastrostomy Using a Partially Covered Self-Expandable Metal Stent. *Dig Dis Sci*. 2026;71:4784–4793. https://doi.org/10.1007/s10620-026-10035-3.

Figures

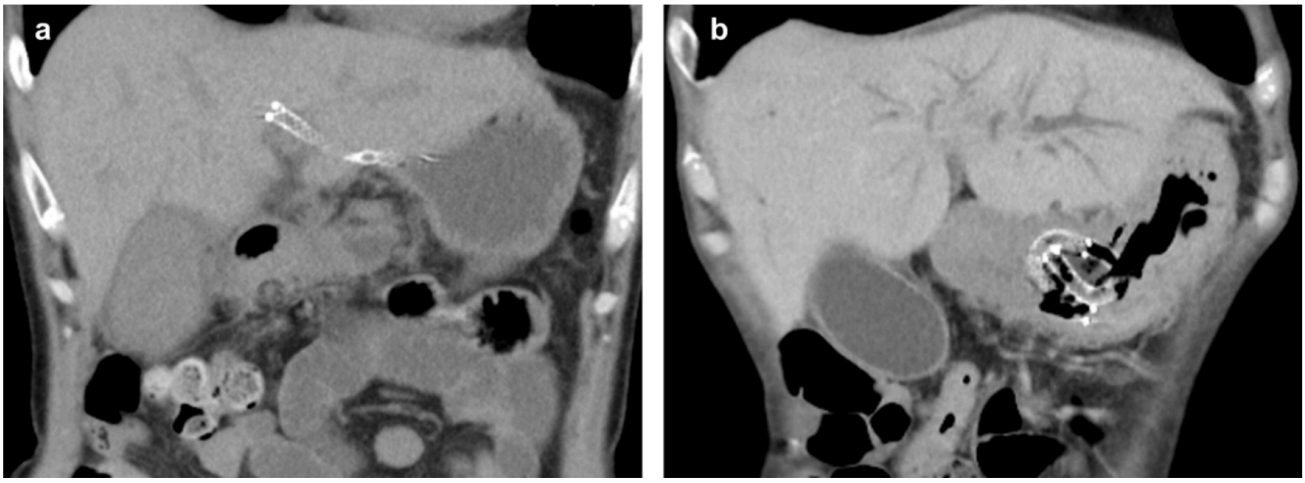

Figure 1

Coronal CT images after endoscopic ultrasound-guided hepaticogastrostomy (EUS-HGS). (a) CT image on day 1 after EUS-HGS showing the fully covered self-expandable metal stent (FCSEMS) placed within the intrahepatic bile duct. (b) CT image on day 86 after EUS-HGS showing complete migration of the FCSEMS into the stomach

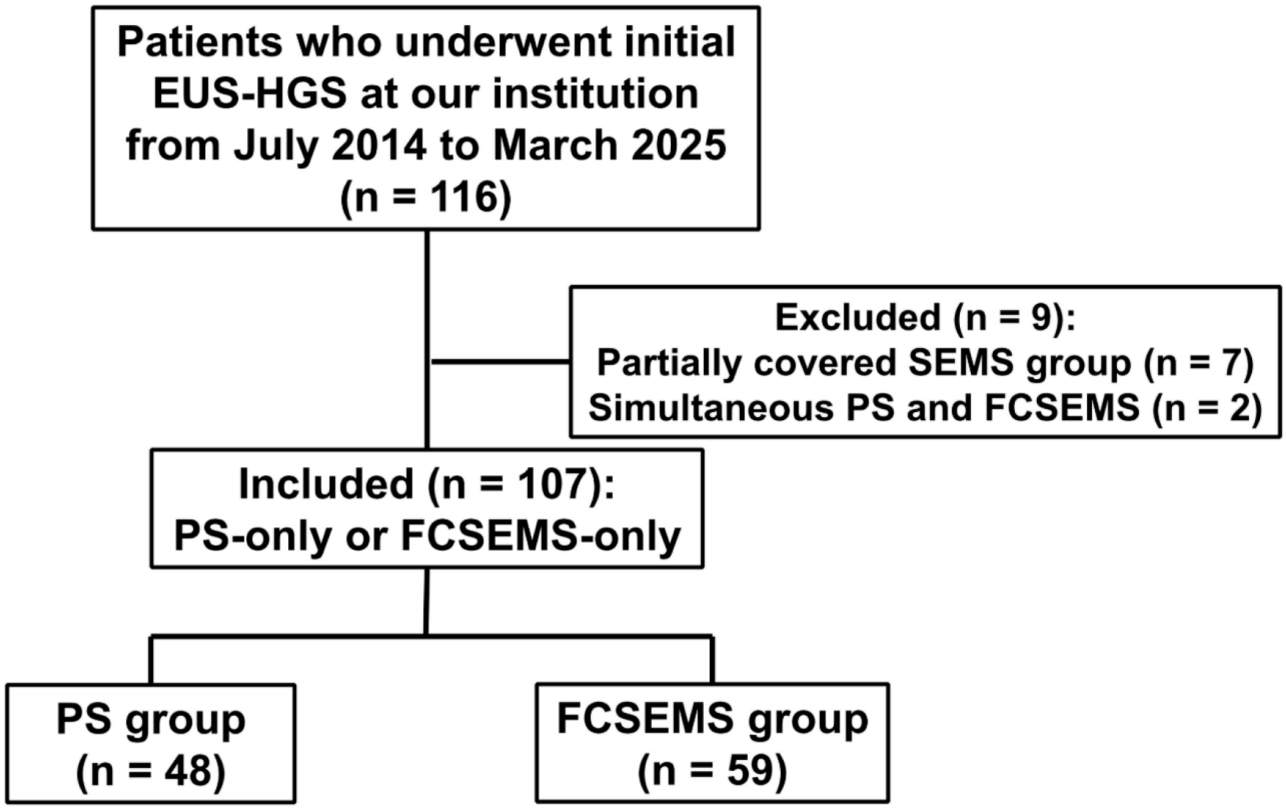

Figure 2

Flow diagram of patient selection and study cohort

EUS-HGS, endoscopic ultrasound-guided hepaticogastrostomy; FCSEMS, fully covered self-expandable metal stent; PS, plastic stent; SEMS, self-expandable metal stent

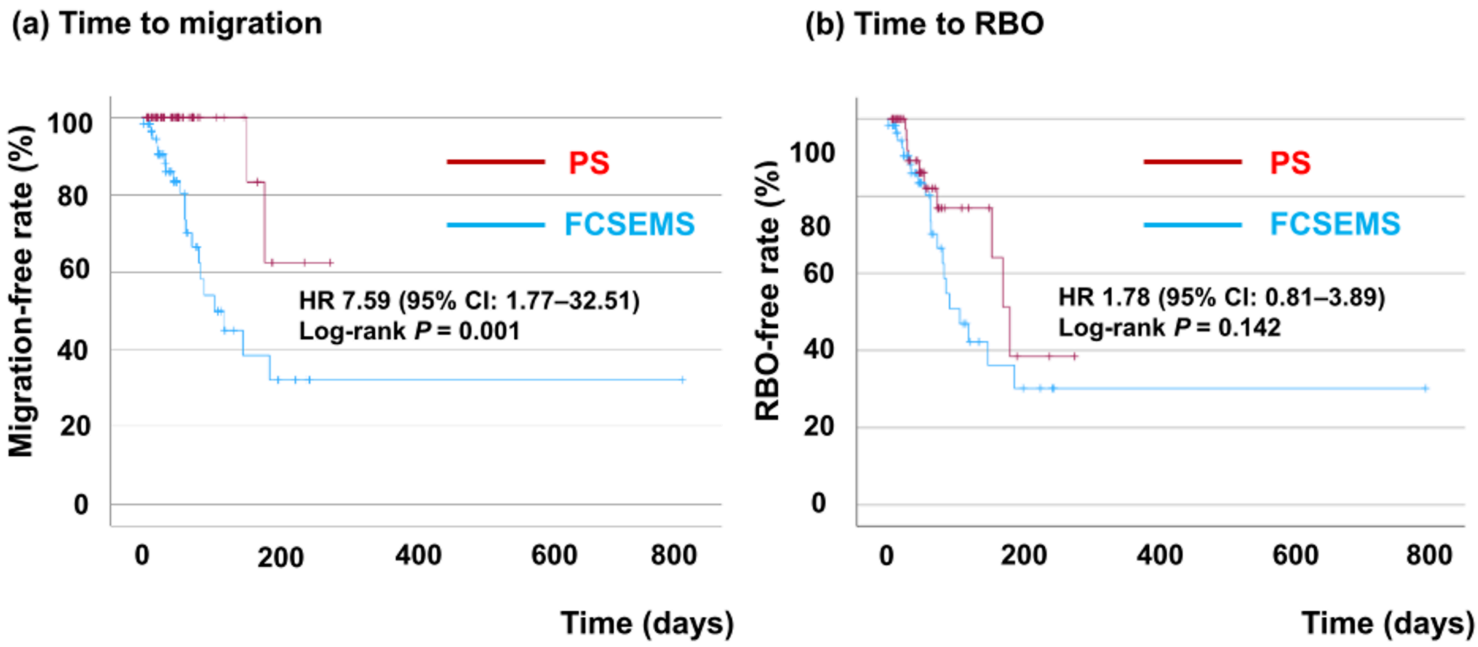

Figure 3

Kaplan–Meier curves comparing plastic stents (PS) and fully covered self-expandable metal stents (FCSEMS) are shown for (a) time to stent migration and (b) time to recurrent biliary obstruction (RBO). (a) The median time to stent migration was not reached in the PS group and was 106 days (95% confidence interval [CI], 60–152) in the FCSEMS group. The hazard ratio (HR) for time to stent migration (FCSEMS vs. PS) was 7.59 (95% CI, 1.77–32.51), and time to stent migration was significantly shorter in the FCSEMS group than in the PS group (*P* = 0.001). (b) The median time to RBO (TRBO) was 179 days (95% CI, 147–211) in the PS group and 106 days (95% CI, 66–146) in the FCSEMS group. The HR for TRBO (FCSEMS vs. PS) was 1.78 (95% CI, 0.81–3.89), and no statistically significant difference was observed between the two groups (*P* = 0.142). Tick marks indicate censored observations