Research Square

Preprints are preliminary reports that have not undergone peer review.
They should not be considered conclusive, used to inform clinical practice,
or referenced by the media as validated information.

Hemorrhagic germ cell tumor with a choriocarcinoma component in the lateral ventricular region: a case report

Yang Ge
First Affiliated Hospital of Kunming Medical University
Sunjiang Liu
First Affiliated Hospital of Kunming Medical University
Rui Pu
First Affiliated Hospital of Kunming Medical University
Fangying Su
First Affiliated Hospital of Kunming Medical University
Qiujian Yu
yu.jianqiu@outlook.com
First Affiliated Hospital of Kunming Medical University

Case Report

Keywords: β-human chorionic gonadotropin, obstructive hydrocephalus, diagnostic sampling, immunohistochemistry

Posted Date: November 25th, 2026

DOI: https://doi.org/10.21203/rs.3.rs-11670140/v1

License: This work is licensed under a Creative Commons Attribution 4.0 International License.
Read Full License

Additional Declarations: No competing interests reported.

Abstract

Germ cell tumors with a choriocarcinoma component rarely involve the lateral ventricular region, where hemorrhage and hydrocephalus may dominate the presentation. A 15-year-old boy presented with behavioral change, somnolence, headache, and vomiting. Imaging demonstrated a 49 × 41 × 36 mm hemorrhagic mass predominantly in the right lateral ventricular region, with contralateral extension and obstructive hydrocephalus. Serum β-human chorionic gonadotropin was 34,378.74 mIU/mL and alpha-fetoprotein was 24.64 ng/mL before open sampling. Emergency ventricular drainage was followed by planned tissue acquisition and limited resection, with bleeding risk constraining removal; gross-total resection was not intended. Initial intraoperative assessment favored glial proliferation, whereas permanent examination and immunohistochemistry established a germ cell tumor with a choriocarcinoma component. Persistent hydrocephalus required an externalized shunt system. Recommended chemotherapy and radiotherapy were declined before discharge. The patient died on the third day after discharge; the immediate cause was not established. This case highlights the importance of correlating tumor markers with representative pathological assessment and distinguishing diagnostic tissue acquisition and cerebrospinal fluid diversion from definitive oncological treatment.

Introduction

Central nervous system germ cell tumors usually involve the pineal or suprasellar region; lateral ventricular involvement is uncommon but previously reported [2, 4]. A choriocarcinoma component may produce a highly vascular, hemorrhagic presentation [5]. We describe an adolescent in whom markedly elevated serum β-human chorionic gonadotropin (β-hCG), initially inconclusive sampling, and subsequent pathological assessment required integrated interpretation.

Case report

A 15-year-old boy was admitted on June 10, 2026, after approximately 2 weeks of behavioral change, irritability, and somnolence, followed by 1 week of headache that worsened over 3 days with nausea and vomiting. His Glasgow Coma Scale score was 14. Speech was slowed, memory and calculation were impaired, and limb strength was grade 4 bilaterally. Pupillary reactions and extraocular movements were preserved. Relevant family history was unremarkable.

Computed tomography (CT) on June 10 showed a hyperdense hemorrhagic mass and ventricular enlargement. Worsening consciousness and obstructive hydrocephalus prompted external ventricular drainage on June 11; approximately 30 mL of clear, colorless cerebrospinal fluid (CSF) was slowly released under high pressure. Magnetic resonance imaging (MRI) later that day demonstrated a 49 × 41 × 36 mm heterogeneous mass predominantly in the right lateral ventricular region, extending into the left lateral ventricle, with hemorrhagic/necrotic components, heterogeneous enhancement, edema, and indistinct margins with the right dorsal thalamus (Fig. 1). Testing on June 12 showed β-hCG of 34,378.74 mIU/mL and alpha-fetoprotein (AFP) of 24.64 ng/mL (reference ≤ 7 ng/mL).

Surgery was planned to obtain tissue for pathological diagnosis and planned genetic testing to inform subsequent chemoradiotherapy. Limited removal was intended within the constraints of bleeding control; gross-total resection was not an operative goal. On June 15, a right frontal craniotomy and middle frontal gyrus approach exposed a soft, extremely vascular subependymal lesion containing old hemorrhage and organizing fibrous tissue. Initial intraoperative assessment favored glial proliferation and deferred definitive diagnosis. Ultrasonic aspiration-assisted removal of superior tumor tissue provided material for permanent examination; septostomy and ventricular drainage were also performed. The extent of resection was not quantified.

Permanent sections showed extensive hemorrhage and necrosis with residual atypical cells (Fig. 2). The final diagnosis was “germ cell tumor with a choriocarcinoma component.” Immunohistochemistry was positive for hCG, SALL4, pancytokeratin, and AFP; focally positive for CD117, placental alkaline phosphatase, and CD30; and negative for OCT3/4, GFAP, and Olig-2. The Ki-67 index was approximately 90%.

Electrolyte and supportive management continued; serum sodium was 168.96 mmol/L on June 16. CT showed persistent hemorrhagic lesion and ventriculomegaly (Fig. 3). Persistent hydrocephalus required bilateral ventricular catheters connected through a Y-connector and valve to externally drained distal tubing on June 24; peritoneal internalization was deferred. Multidisciplinary consultation recommended chemotherapy and radiotherapy, which the guardian declined before discharge. Refusal and self-discharge forms were signed on June 28, and discharge occurred on June 29. The patient died on the third day after discharge. The immediate cause of death was not established (Table 1).

Table 1
Clinical timeline

Date	Clinical event
June 10, 2026	Admission; CT showed a hemorrhagic ventricular region mass with hydrocephalus.
June 11, 2026	Emergency ventricular drainage, followed by MRI assessment later that day.
June 12, 2026	β-hCG 34,378.74 mIU/mL and AFP 24.64 ng/mL documented before open sampling.
June 15, 2026	Planned diagnostic tissue acquisition and limited removal, septostomy, and ventricular drainage; initial assessment favored glial proliferation.
June 16, 2026	Serum sodium 168.96 mmol/L; electrolyte and supportive management.
Subsequent permanent examination	Germ cell tumor with a choriocarcinoma component established by permanent examination and immunohistochemistry.
June 24–25, 2026	Bilateral ventricular catheters connected to an externalized shunt system; next-day CT showed both catheters.
June 28–29, 2026	Recommended chemotherapy/radiotherapy declined; refusal and self-discharge forms signed on June 28; discharge on June 29.
Third day after discharge	Death; immediate cause not established.

Discussion

Hemorrhage, necrosis, and heterogeneous enhancement are not specific to germ cell tumors. In an adolescent with a ventricular mass, however, marked β-hCG elevation redirects the differential toward a nongerminomatous germ cell tumor (NGGCT) [2, 5, 8]. European consensus uses hCG ≥ 50 IU/L for International Society of Paediatric Oncology (SIOP) NGGCT protocols, whereas the Children's Oncology Group (COG) ACNS1123 trial used β-hCG > 100 IU/L [1, 2]. These treatment-classification thresholds do not establish a pure histological subtype.

Extensive hemorrhage and necrosis can compromise representative sampling [7]. The initial glial-proliferation interpretation therefore needed correlation with the marker profile and subsequent permanent examination. The final report establishes a choriocarcinoma component, while limited sampling cannot exclude other components. AFP elevation alone does not establish a yolk sac component [8].

The aim of surgery was to obtain diagnostically useful tissue, including material intended for genetic testing, while limiting hemorrhagic risk. Gross-total resection was deliberately excluded from the preoperative plan. Although some protocols permit marker-based treatment without biopsy, histological

characterization can clarify tumor components [2, 6]. Such decisions must balance tissue requirements against the vascularity and location of the lesion. CSF diversion addressed obstruction, while definitive NGGCT management generally combines chemotherapy and radiotherapy, with residual-tumor surgery when indicated [1–3, 6].

Anatomical origin and stage remained uncertain: thalamic margins were indistinct, extracranial and neuraxial assessment was incomplete, and chest CT showed indeterminate pulmonary nodules and ground-glass opacities rather than confirmed metastases. The immediate cause of death was not established. Serial imaging and tumor-marker data were insufficient to assess disease evolution. Consequently, neither the survival effect of limited removal nor the effect of declining recommended treatment can be determined from this case.

Conclusion

Marked β-hCG elevation warrants integrated germ cell tumor assessment in adolescents with hemorrhagic ventricular masses, even when initial sampling is inconclusive. Operative planning should distinguish diagnostic tissue acquisition and hydrocephalus management from definitive oncological therapy.

Declarations

Ethics approval and consent to participate

Formal ethics committee approval and consent to participate were not required for this retrospective single-patient case report, which describes routine clinical care and did not involve a prospective research intervention, in accordance with the institutional policy of the First Affiliated Hospital of Kunming Medical University.

Consent to publish

Written informed consent for publication of this case report and the accompanying images was obtained from the patient's legal guardian using an electronically signed consent form.

Competing interests

The authors declare that they have no competing interests.

Funding

No funding was received for this work.

Author Contribution

Yang Ge led the drafting of the manuscript. Sunjiang Liu was responsible for the patient's clinical care. Rui Pu and Fangying Su assisted with manuscript writing and data collection. Qiujian Yu served as the corresponding author.

References

1. Fangusaro J, Wu S, MacDonald S, Murphy E, Shaw D, Bartels U, Khatua S, Souweidane M, Lu HM, Morris D, Panigrahy A, Onar-Thomas A, Fouladi M, Gajjar A, Dhall G. Phase II trial of response-based radiation therapy for patients with localized CNS nongerminomatous germ cell tumors: a Children's Oncology Group study. J Clin Oncol. 2019;37:3283–90. https://doi.org/10.1200/JCO.19.00701.
2. Frappaz D, Dhall G, Murray MJ, Goldman S, Faure Conter C, Allen J, Kortmann RD, Haas-Kogan D, Morana G, Finlay J, Nicholson JC, Bartels U, Souweidane M, Schönberger S, Vasiljevic A, Robertson P, Albanese A, Alapetite C, Czech T, Lau CC, Wen P, Schiff D, Shaw D, Calaminus G, Bouffet E. EANO, SNO and Euracan consensus review on the current management and future development of intracranial germ cell tumors in adolescents and young adults. Neuro Oncol. 2022;24:516–27. https://doi.org/10.1093/neuonc/noab252.
3. Hong KT, Han JW, Fuji H, Byun HK, Koh KN, Wong RX, Lee HL, Yoon HI, Lee JH, Phi JH, Kim SK, Kim DS, Lyu CJ, Choi JY, Kang HJ, Chen YW, Lee YY, Im HJ, Ra YS, Ahn SD, Low SYY, Looi WS, Park HJ, Suh YG, Suh CO, Wang KC, Tan EEK, Wong TT, Kim JY. Outcomes of intracranial non-germinomatous germ cell tumors: a retrospective Asian multinational study on treatment strategies and prognostic factors. J Neurooncol. 2022;160:41–53. https://doi.org/10.1007/s11060-022-04100-w.
4. Kawakami Y, Yamada O, Tabuchi K, Ohmoto T, Nishimoto A. Primary intracranial choriocarcinoma. J Neurosurg. 1980;53:369–74. https://doi.org/10.3171/jns.1980.53.3.0369.
5. Lv XF, Qiu YW, Zhang XL, Han LJ, Qiu SJ, Xiong W, Wen G, Zhang YZ, Zhang J. Primary intracranial choriocarcinoma: MR imaging findings. AJNR Am J Neuroradiol. 2010;31:1994–8. https://doi.org/10.3174/ajnr.A2194.
6. Nakamura H, Takami H, Yanagisawa T, Kumabe T, Fujimaki T, Arakawa Y, Karasawa K, Terashima K, Yokoo H, Fukuoka K, Sonoda Y, Sakurada K, Mineharu Y, Soejima T, Fujii M, Shinojima N, Hara J, Yamasaki K, Fujimura J, Yamasaki F, Takahashi M, Suzuki T, Sato I, Nishikawa R, Sugiyama K. The Japan Society for Neuro-Oncology guideline on the diagnosis and treatment of central nervous system germ cell tumors. Neuro Oncol. 2022;24:503–15. https://doi.org/10.1093/neuonc/noab242.
7. Sun T, Liu R, Tian Y, Wan W, Li C. Primary intracranial choriocarcinoma: a report of 8 cases with review of literature. Int J Clin Exp Pathol. 2017;10:1937–45.
8. Takami H, Graffeo CS, Perry A, Giannini C, Nakazato Y, Saito N, Matsutani M, Nishikawa R, Daniels DJ, Ichimura K. Impact of tumor markers on diagnosis, treatment and prognosis in CNS germ cell tumors: correlations with clinical practice and histopathology. Brain Tumor Pathol. 2023;40:124–32. https://doi.org/10.1007/s10014-023-00460-x.

Figures

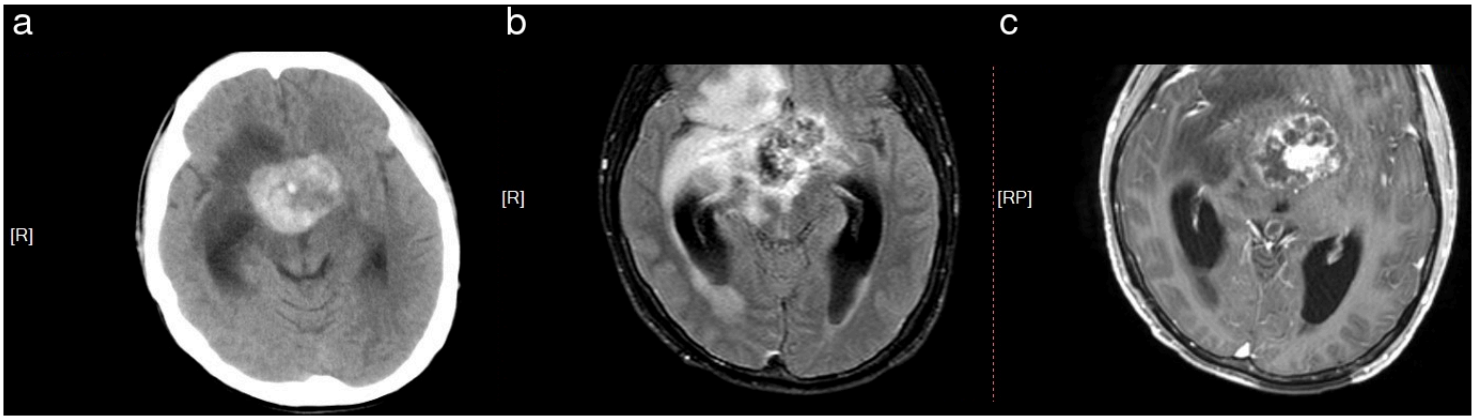

Figure 1

Diagnostic imaging centered on the ventricular lesion. a Axial CT on June 10, 2026 showing a hyperdense hemorrhagic mass and enlarged lateral ventricles. b Fluid-attenuated inversion recovery (FLAIR) MRI on June 11 showing heterogeneous lesion signal and surrounding edema. c Contrast-enhanced axial MRI from the same examination showing heterogeneous enhancement

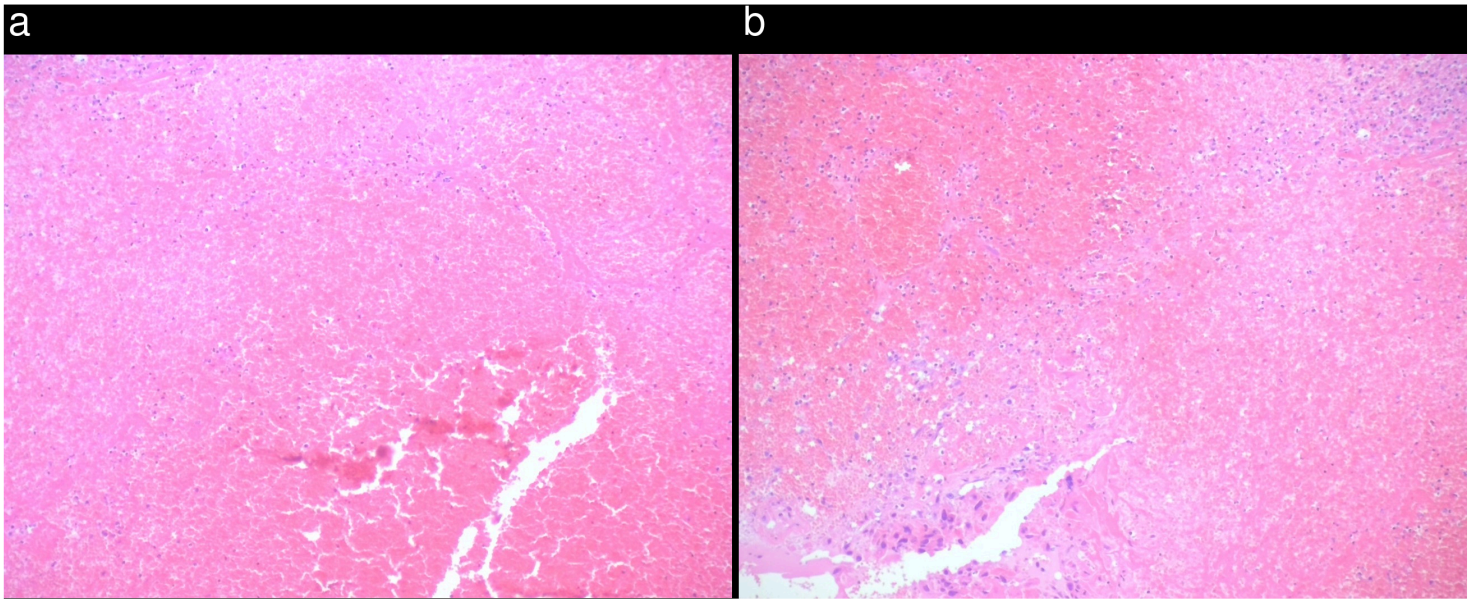

Figure 2

Hematoxylin and eosin stained sections. a Extensive hemorrhage and necrosis. b Residual atypical cells along part of the tissue edge within predominantly hemorrhagic and necrotic tissue

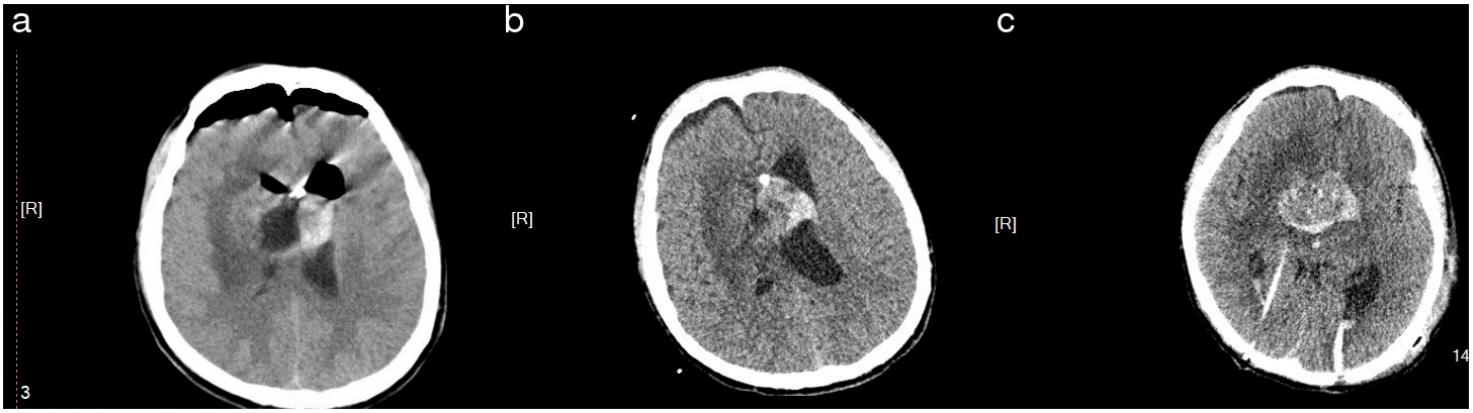

Figure 3

Perioperative CT in chronological order. a June 15, 2026 after open sampling and limited tissue removal, showing postoperative air and persistent hemorrhagic lesion. b June 22 showing persistent lesion and ventricular enlargement. c June 25 after bilateral ventricular catheter placement, showing both posterior catheters