Research Square

Preprints are preliminary reports that have not undergone peer review.
They should not be considered conclusive, used to inform clinical practice,
or referenced by the media as validated information.

Paediatric HIV-associated intracranial aneurysm with recurrent middle cerebral artery infarction and disseminated tuberculosis: balancing vasculopathy, vasculitis and infection

Faatimah Dollie
University of The Witwatersrand
Irtiza Ahmad Chaudhry
irtizachaudhry@gmail.com

University of The Witwatersrand
Mohammad Hassan Khan
University of The Witwatersrand
Jaques-Robin Steyn
University of The Witwatersrand
Nilesh Lala
University of The Witwatersrand
Victor Mngomezulu
University of The Witwatersrand
Barri Strimling
University of The Witwatersrand

Case Report

Keywords: HIV-associated vasculopathy, Paediatric stroke, Cerebral aneurysm, Tuberculous vasculitis, Immunosuppression

Posted Date: November 23rd, 2026

DOI: https://doi.org/10.21203/rs.3.rs-11669386/v1

License: This work is licensed under a Creative Commons Attribution 4.0 International License.
Read Full License

Additional Declarations: No competing interests reported.

Abstract

HIV-associated cerebral aneurysmal vasculopathy is a rare but increasingly recognised cause of childhood strokes. This is true particularly in settings where there is high tuberculosis (TB)/HIV-burden. HIV vasculitis presents an important diagnostic overlap. We report a 9-year-old boy with previously undiagnosed stage 4 HIV infection (CD4 9 cells/μL, viral load 353,441 copies/mL) and disseminated tuberculosis who then developed left-sided weakness during admission for miliary TB and Pneumocystis pneumonia. Non-contrast CT demonstrated evidence of asaccular right internal carotid artery (ICA) terminus aneurysm that was subsequently confirmed on CT angiography: revealing a mixed fusiform-saccular aneurysm at the right ICA/middle cerebral artery (MCA) junction with distal M1 beading. MRI confirmed evolving right MCA-territory infarction with features of vasculitis. Large-vessel vasculitis (Takayasu arteritis) and a mycotic aneurysm were both considered but were not supported by FDG-PET nor on the repeated negative blood cultures. Because of the diffuse vascular involvement, high procedural risk and severe immunosuppression, the aneurysm was managed conservatively with antiplatelet therapy, antiretroviral and anti-tuberculous treatment followed by rehabilitation. The follow-up imaging at three months showed a persistent aneurysm remnant with complete right MCA and A1 occlusion.

This case illustrates that HIV-associated aneurysmal vasculopathy can coexist with tuberculosis without being fully explained by it, and that management often proceeds without histopathological certainty.

Introduction

Children with human immunodeficiency virus (HIV) remain at increased risk of cerebrovascular disease despite wider access to antiretroviral therapy (ART), particularly in sub-Saharan Africa, where advanced immunosuppression and co-infection continue to shape neurological presentation[3,5, 6]. HIV-associated aneurysmal vasculopathy typically produces fusiform or mixed dilatation of the proximal circle of Willis and predominantly affects severely immunosuppressed children with vertically acquired infection[1,4]. In high tuberculosis (TB)/HIV-burden settings such as South Africa, tuberculous meningitis is an additional important cause of childhood stroke, acting through basal inflammatory exudates and obliterative vasculitis[7]. Distinguishing primary HIV-associated vasculopathy from infectious arteritis, a mycotic aneurysm, or overlapping pathology matters because management differs substantially. But clinical and radiological overlap is common. We describe a child with previously undiagnosed advanced HIV, disseminated TB and a large right internal carotid artery (ICA)/middle cerebral artery (MCA) aneurysm causing recurrent infarction.

Case report

A 9-year-old boy, HIV-exposed with a negative maternal test in 2018, presented with a one-year history of productive cough and one day of fever. He was febrile, tachypnoeic and hypoxic (oxygen saturation 83–86% on room air), severely wasted (body mass index 12.4 kg/m²), with oral candidiasis, tinea, and

generalised lymphadenopathy. His neurological examination was normal. Chest radiography showed a miliary pattern with hilar lymphadenopathy. HIV-1 enzyme-linked immunosorbent assay was confirmed positive with a CD4 count of 9 cells/μL (1.3%) and viral load 353,441 copies/mL. Urine lipoarabinomannan and Pneumocystis jirovecii polymerase chain reaction (PCR) were positive, supporting disseminated TB with probable concurrent Pneumocystis pneumonia. Cerebrospinal fluid studies did not identify an organism (Table 1). Antituberculous therapy, co-trimoxazole and antifungals were started immediately. ART was introduced four weeks later as per the World Health Organization guidance for severe TB with central nervous system involvement.

Table 1
Timeline of key clinical, laboratory and radiological findings

Date	Event	Key finding
5 Feb 2026	Admission	Chronic cough, severe wasting (BMI 12.4 kg/m²), hypoxia; chest radiograph showed miliary pattern with hilar lymphadenopathy
First week	HIV/TB diagnosis; treatment started	HIV confirmed (CD4 9 cells/μL, 1.3%; viral load 353,441 copies/mL); urine lipoarabinomannan and Pneumocystis jirovecii PCR positive; antituberculous therapy, co-trimoxazole and antifungals commenced
16 Feb 2026 (day 11)	First neurological event	Acute left hemiparesis; CT showed a 9×5 mm saccular right ICA-terminus aneurysm; infarct not identified on initial read
24 Feb 2026 (day 19)	CT angiography	Mixed fusiform–saccular 7.8×8.7×6.9 mm right ICA/MCA aneurysm with distal M1 beading and A1 dilatation
4 Mar 2026 (day 27)	ART commenced	Per WHO guidance for severe TB with CNS involvement
6 Mar 2026 (day 29)	Second neurological event	Dense left hemiplegia, focal seizures; CT showed acute-on-subacute right MCA infarction
Interim	Vasculitis/fungal work-up	FDG-PET: no large-vessel hypermetabolism (argues against active vasculitis); avid TB nodal/marrow uptake; β-D-glucan 168 pg/mL (attributed to PJP/tinea)
20 Mar 2026 (day 43)	MRI brain	Subacute infarction of right lentiform nucleus/caudate; aneurysm unchanged (6.6 mm neck, 10.5 mm length); complete right M1 occlusion
30 Mar 2026	Discharge	Residual left hemiparesis (3–4/5); aspirin, ART and anti-TB therapy continued; viral load fallen to 784 copies/mL
~ 3 months post-discharge	Follow-up CT angiography	Established right MCA-territory encephalomalacia and crossed cerebellar diaschisis; complete occlusion of right MCA AND A1 around persistent fusiform ICA aneurysm remnant

On day 11, he developed acute left-sided facial, arm and leg weakness (power 2–4/5). Non-contrast computed tomography (CT) showed a 9×5 mm saccular aneurysm at the right ICA terminus; a

corresponding area of temporal cytotoxic oedema was appreciated. CT angiography (day 19) confirmed a mixed fusiform–saccular aneurysm complex at the right ICA/MCA junction with beading of the distal M1 and dilatation of the proximal A1, without disseminated large-vessel disease (Fig. 1). Electroencephalography showed right-hemisphere asymmetry. Genetic thrombophilia testing and echocardiography were normal.

A second stroke on day 29 caused dense left hemiplegia, hyperreflexia, clonus, an extensor plantar response and focal seizures (levetiracetam commenced). Repeat CT confirmed acute right MCA infarction. Diminished left-sided pulses raised concern for a large-vessel vasculitis such as Takayasu arteritis. Fluorodeoxyglucose positron emission tomography (obtained while awaiting magnetic resonance imaging [MRI]) showed no medium or large-vessel hyper-metabolism, but confirmed avid mesenteric nodal and marrow uptake in keeping with disseminated TB. A raised β-D-glucan (168 pg/mL) was attributed to Pneumocystis pneumonia and cutaneous fungal disease rather than invasive fungaemia. Repeated blood cultures remained negative throughout. MRI was delayed by resource constraints until day 43, that subsequently confirmed subacute infarction of the right lentiform nucleus and caudate, as well as an unchanged aneurysm (6.6 mm neck, 10.5 mm length), and complete occlusion of the distal right M1 (Fig. 2).

Given diffuse aneurysm morphology, severe immunosuppression and a high anaesthetic risk, neurosurgery and anaesthesia advised against intervention. He was discharged on aspirin, ART and anti-tuberculous therapy with residual left hemiparesis (3–4/5). At discharge the patient's viral load had fallen to 784 copies/mL. At three-month follow-up, CT angiography demonstrated established right MCA-territory encephalomalacia with Wallerian degeneration and crossed cerebellar diaschisis, and interval progression to complete occlusion of both the right MCA and the A1 segment of the right anterior cerebral artery around a persistent short-segment fusiform ICA aneurysm remnant. The right hemisphere was now dependent on collateral flow (Fig. 3).

Discussion

This case raises the question of whether the aneurysm and progressive infarction reflect primary HIV-associated aneurysmal vasculopathy, TB-related vasculitis, a mycotic aneurysm, or overlapping pathology. The clinic-radiological picture most strongly supports HIV-associated vasculopathy with infectious and inflammatory overlap. The patient's age, profound immunosuppression (CD4 9 cells/μL) and anterior-circulation aneurysmal morphology with distal beading closely mirror described paediatric HIV-associated arteriopathy, in which proximal vessels around the circle of Willis develop fusiform or mixed aneurysmal change. This often presents with associated infarction, through medial fibrosis, destruction of the internal elastic lamina and chronic inflammation[1, 4].

TB cannot be dismissed as incidental in this high-burden setting. Tuberculous meningitis is a recognised cause of childhood stroke via basal exudative vasculitis. Cerebral infarction complicates roughly one-third of paediatric TB meningitis[2, 7]. However, the vascular abnormalities here were confined to the

anterior circulation with aneurysmal remodelling rather than the perforator-territory pattern typical of basal exudate-related arteritis, and PET showed no medium- or large-vessel hypermetabolism to support an active vasculitis such as Takayasu arteritis. TB therefore appears to be a biologically plausible contributor and diagnostic confounder rather than a sufficient unifying explanation.

A mycotic aneurysm was also considered given the degree of immunosuppression, but classical supportive features, including bacteraemia, endocarditis, and a more peripheral, rupture-prone aneurysm, were absent. Blood cultures and echocardiography were repeatedly negative, and the proximal anterior-circulation location is atypical for an infective aneurysm. The raised β-D-glucan most likely reflected Pneumocystis pneumonia and cutaneous fungal disease rather than intravascular fungaemia.

Management was necessarily conservative based on: diffuse aneurysm morphology, severe comorbidity and anaesthetic risk precluding intervention, consistent with reported paediatric experience in which similar factors limit endovascular or surgical intervention[1]. The early CT can also under-recognised evolving ischaemia, apparent on later imaging, a reminder that infarction can be radiologically subtle even when the culprit aneurysm is already visible.

Conclusion

HIV-associated aneurysmal vasculopathy should be considered in children with advanced HIV who present with multifocal intracranial aneurysms and recurrent stroke, even where tuberculosis or other infections coexist, since these do not always provide a sufficient unifying explanation. Management is often conservative and multidisciplinary, guided by repeated vascular imaging and integration of infectious, inflammatory and neuroimaging findings rather than histopathological confirmation. Clinicians in high TB/HIV-burden settings should recognise that profound HIV-related vasculopathy can coexist with tuberculosis without being wholly explained by it.

Declarations

Acknowledgements: None

Clinical Trial Number: Not applicable

Competing interests:

The authors have no relevant financial or non-financial interests to disclose.

Ethics approval:

Approval received from the university of Witwatersrand

Consent to participate:

Written informed consent to participate was obtained from the patient's parent/legal guardian

Consent to publish:

Written informed consent for publication of the clinical details and accompanying images was obtained from the patient's parent/legal guardian.

Funding:

The authors did not receive support from any organization for the submitted work.

Author Contribution

All authors contributed to the study conception, design, write up and review of the final manuscipt.

References

1. Baeesa SS, Bakhaidar M, Almekhlafi MA, Madani TA. Human immunodeficiency virus-associated cerebral aneurysmal vasculopathy: a systematic review. World Neurosurg. 2016;87:220–9. https://doi.org/10.1016/j.wneu.2015.11.023.
2. Donald KAM, Walker K, Riordan G, Govender R, Wilmshurst J. Neurological complications of HIV/AIDS in childhood. Continuing Med Educ. 2012;30(1):21–4.
3. Howlett WP. Neurological disorders in HIV in Africa: a review. Afr Health Sci. 2019;19(2):1953–77. https://doi.org/10.4314/ahs.v19i2.19.
4. Patsalides AD, Wood LV, Atac GK, Sandifer E, Butman JA, Patronas NJ. Cerebrovascular disease in HIV-infected pediatric patients: neuroimaging findings. AJR Am J Roentgenol. 2002;179(4):999–1003. https://doi.org/10.2214/ajr.179.4.1790999.
5. Phiri TE, Holroyd KB, Bernard Healey SA, Mallon DH, Benjamin LA. Stroke and HIV: emerging mechanisms and management in a changing epidemic. Int J Stroke. 2026. https://doi.org/10.1177/17474930261424713. (Epub ahead of print).
6. Schneider CL, Mohajeri-Moghaddam S, Mbewe EG, Kabundula PP, Dean O, Buda A, Potchen MJ, Mwanza-Kabaghe S, Saylor D, Adams HR, Birbeck GL, Bearden DR. Cerebrovascular disease in children perinatally infected with human immunodeficiency virus in Zambia. Pediatr Neurol. 2020;112:14–21. https://doi.org/10.1016/j.pediatrneurol.2020.08.003.
7. van Well GTJ, Paes BF, Terwee CB, Springer P, Roord JJ, Donald PR, van Furth AM, Schoeman JF. Twenty years of pediatric tuberculous meningitis: a retrospective cohort study in the Western Cape of South Africa. Pediatrics. 2009;123(1):e1–8. https://doi.org/10.1542/peds.2008-1353.

Figures

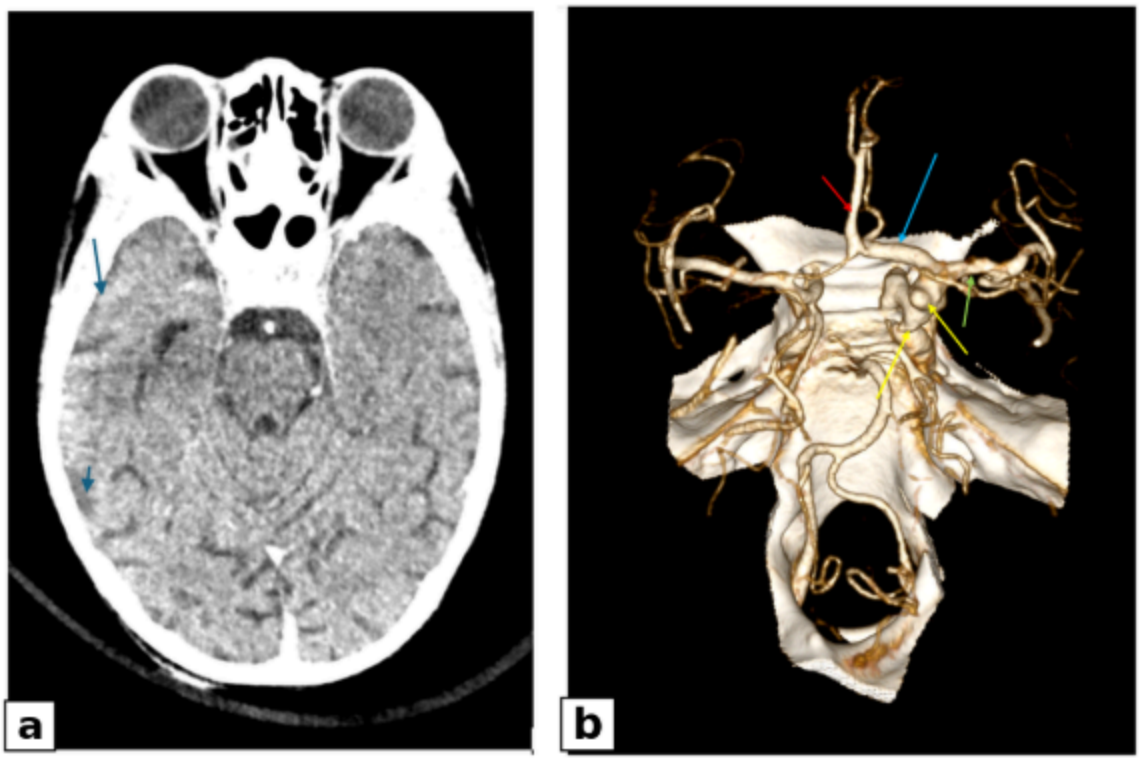

Figure 1

Neuroimaging at first neurological event (day 11). (a) Non-contrast axial CT showing subtle right temporal cortical hypodensity (arrows), representing early cytotoxic oedema. (b) Three-dimensional cinematic-rendered CT angiogram of the circle of Willis showing a saccular aneurysm at the communicating (C2) segment of the right ICA (yellow arrow), fusiform dilatation of the pre-communicating (A1) anterior cerebral artery (blue arrow), a fusiform sphenoidal (M1) segment aneurysm (green arrow) and a post-communicating (A2) aneurysm (red arrow)

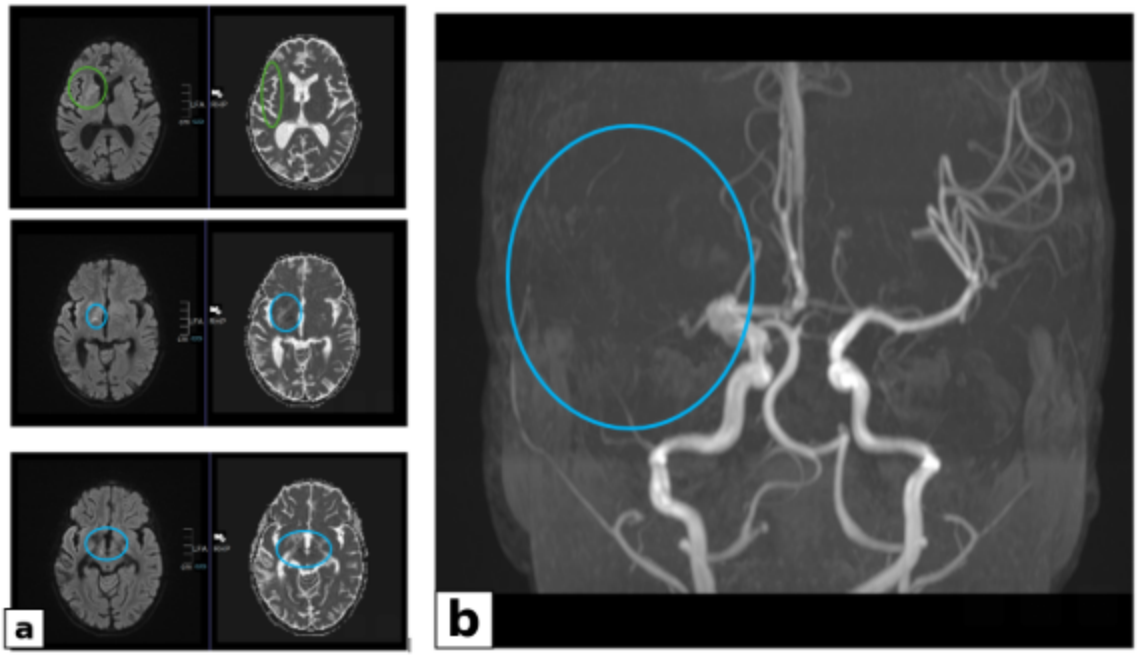

Figure 2

MRI/MR angiography (20 March 2026) confirming right MCA-territory infarction. (a) Axial diffusion-weighted (left column) and apparent diffusion coefficient (right column) images at three levels showing restricted diffusion involving the right anterior choroidal artery perforator territory (top), lentiform nucleus (middle) and caudate nucleus (bottom). (b) Coronal MR angiogram showing markedly reduced flow-related signal throughout the right MCA territory (circle) compared with the normal left hemisphere

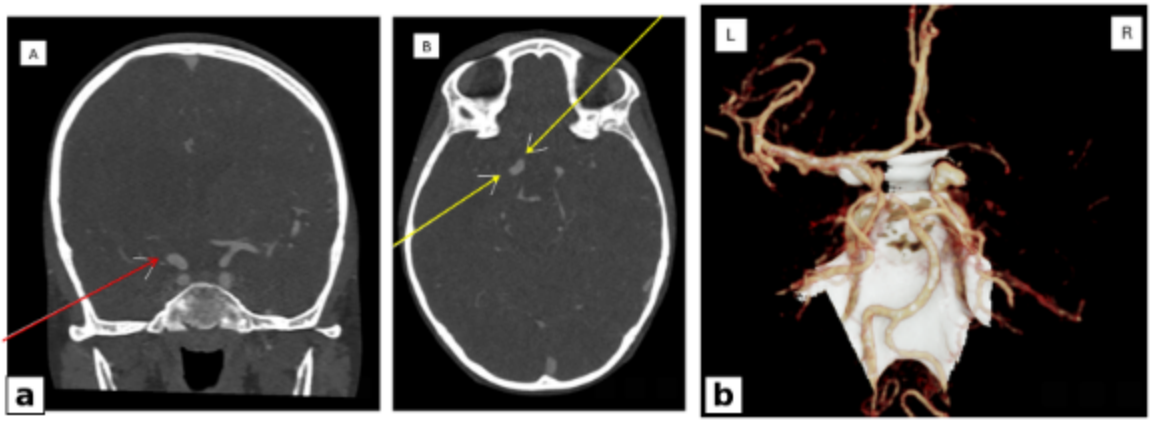

Figure 3

Follow-up imaging approximately 3 months after discharge. (a) Coronal (A) and axial (B) contrast CT angiogram showing a residual short-segment fusiform aneurysm of the distal right ICA (arrows). (b) Three-dimensional cinematic-rendered CT angiogram showing a normal left-sided (L) arterial tree but near-complete absence of right-sided (R) arterial opacification, confirming complete right MCA and A1 occlusion with the hemisphere dependent on collateral flow