Research Square

Preprints are preliminary reports that have not undergone peer review.
They should not be considered conclusive, used to inform clinical practice,
or referenced by the media as validated information.

Effects of castor oil-derived ricinoleic acid salt on midgut morphology, digestive enzyme activity, and cuticular composition in engorged females of Rhipicephalus linnaei

Yousmel Alemán Gainza
São Paulo State University “Júlio de Mesquita Filho” (UNESP)
Bruna Jéssyca Nascimento Horn
São Paulo State University “Júlio de Mesquita Filho” (UNESP)
Eduarda Cristina da Vinha
São Paulo State University “Júlio de Mesquita Filho” (UNESP)
Kirley Marques Canuto
Embrapa Tropical Agroindustry
Maria Izabel Camargo-Mathias
maria.izabel@unesp.br

São Paulo State University “Júlio de Mesquita Filho” (UNESP)

Research Article

Keywords: Ricinus communis, midgut histochemistry, digestive enzymes, cuticular chitin, blood digestion

Posted Date: November 24th, 2026

DOI: https://doi.org/10.21203/rs.3.rs-11667889/v1

License: This work is licensed under a Creative Commons Attribution 4.0 International License.
Read Full License

Additional Declarations: No competing interests reported.

Effects of castor oil-derived ricinoleic acid salt on midgut morphology, digestive enzyme activity, and cuticular composition in engorged females of *Rhipicephalus linnaei*.

Yousmel Alemán Gainza[a], Bruna Jéssyca Nascimento Horn[a], Eduarda Cristina da Vinha[a], Kirley Marques Canuto[b], Maria Izabel Camargo-Mathias[a]*

[a] São Paulo State University "Júlio de Mesquita Filho" (UNESP), Institute of Biosciences, Department of General and Applied Biology, 24A Ave, 1515, Bela Vista, Rio Claro, SP, 13506-700, Brazil
[b] Embrapa Tropical Agroindustry, Rua Doutora Sara Mesquita, 2270, Planalto do Pici, Fortaleza, CE, 60511-110, Brazil.

*Corresponding author: maria.izabel@unesp.br

ABSTRACT

The brown dog tick, *Rhipicephalus linnaei*, is a medically and veterinary important ectoparasite for which alternative control agents are needed because of increasing acaricide resistance and concerns about environmental residues. This study evaluated the effects of a castor oil-derived ricinoleic acid salt on engorged female *R. linnaei*, focusing on acaricidal activity, digestive enzyme activity, cuticular composition, and midgut morphology. Ticks were exposed to concentrations ranging from 0.195 to 100 mg/mL using the Adult Immersion Test. Reproductive parameters were assessed, while alkaline phosphatase, acid phosphatase, and serine protease activities were quantified after 24 and 48 h. Cuticular protein and chitin contents were also determined. Midgut tissues were examined using histological and histochemical techniques. The ricinoleic acid salt showed no acaricidal activity or inhibition of oviposition at any tested concentration, whereas selamectin achieved 96.9% efficacy. Enzyme activities in treated ticks generally remained similar to those in the negative control, although selamectin produced significantly higher values. Likewise, cuticular protein and chitin contents did not differ significantly between the ricinoleic acid salt and negative-control groups. In contrast, histological analyses revealed disorganization of the midgut epithelium, cytoplasmic vacuolation, cellular detachment, and altered protein and polysaccharide labeling, particularly at concentrations from 0.78 to 12.5 mg/mL. These findings indicate that, despite lacking acute acaricidal activity, the ricinoleic acid salt can induce sublethal cellular alterations in the tick midgut. Further studies should investigate its potential as a synergist or component of integrated tick-control strategies.

Keywords: *Ricinus communis*; midgut histochemistry; digestive enzymes; cuticular chitin; blood digestion

Introduction

The incidence of tick-borne diseases that affect humans and animals has been growing, as the distribution of ticks around the globe and the consequent spread of diseases increases. In the species of ticks that have dogs as their preferred hosts, the increase in transmission is evident, since currently dogs and cats are considered as members of families, living in the same environment with people and facilitating the dynamics of pathogen transmission. Thus, the search for the development of alternative methods and products that have the potential to control tick populations should become a priority for health and public health agencies. It should also be considered that the expansion of the range of products that can be safely used in livestock, wild animals and pets, reduces the impacts of the acaricides currently marketed (Kunz and Kemp 1994; De Meneghi et al. 2016; Wanzala 2017; Laing et al. 2018).

Studies show that commonly used ectoparasiticides are losing efficacy as ticks develop resistance, underscoring the need to prioritize integrated control and prevention strategies alongside new synthetic options to reduce pathogen transmission and associated health, ecological, and economic impacts (Pfister and Armstrong 2016; Klafke et al. 2017; Vilela et al. 2020). It should be noted that compounds of botanical origin or even from other animals (e.g.: secretions) have been investigated as new biopesticides, focusing on their efficiency and on the fact that they cause less damage to non-target organisms (Ellse and Wall 2014; Ntalli et al. 2019).

The dog tick *Rhipicephalus linnaei* (the tropical lineage of the brown dog tick), expanding the possibility of transmitting infectious agents not only to the dog (babesiosis, monocytic ehrlichiosis, hepatozoonosis) but also to man himself (Rocky Mountain spotted fever / Brazilian spotted fever) (Do et al. 2024; Dantas-Torres et al. 2024Santos et al. 2024). Currently, the control of these ticks has been carried out with the application of synthetic base tick compounds, but similarly to what occurs with other species of economic importance, the resistance of *R. linnaei* to these active principles has been observed (Coles and Dryden 2014; Becker et al. 2019).

The ability of pathogens to survive in the intestinal lumen of ectoparasites, penetrate and multiply in the intestinal epithelium, before reaching the hemocoel (body cavity) and invading other organs (salivary glands and ovaries) has been reported (de la Fuente et al. 2007). Therefore, the gut of ticks must have an arsenal of innate defense mechanisms that are efficient and capable of controlling the development and multiplication of such pathogenic agents (Taylor 2006; Sonenshine and Hynes 2008), but still preserving the gut

microbiota (Ha et al. 2009).

The study and identification of new molecules obtained from natural products has been growing with the need to combat ectoparasites. Elucidating the cellular, subcellular, and metabolic mechanisms of these bioactive is justified by their potential to reduce synthetic acaricide use, thereby mitigating resistance and minimizing toxic residues in animal products and the environment.

Accordingly, this study evaluated the effects of ricinoleic acid salts in castor oil, identifying key metabolic pathways and assessing whether exposure induces histophysiology changes in the ectoparasite intestine—findings that would advance understanding of the mode of action and inform new control strategies.

Material and methods

Biochemical analysis

The salts of ricinoleic acid from castor oil used were synthesized and kindly provided by Prof. Dr. Gilberto Chierice (*in memoriam*) and are now on the premises of BCSTM (Brazilian Central of Studies on Ticks Morphology) headquartered at UNESP, Rio Claro-SP. These were chemically characterized by Dr. Kirley Marques Canuto, at the Multiuser Laboratory of Chemistry of Natural Products - LMQPN, Embrapa Tropical Agroindustry, Ceará, Brazil. This characterization was performed in nuclear magnetic resonance spectrum, a ^{1}H NMR chemometrics according Biais et al. (2009) with some modifications.

Isolates of Rhipicephalus linnaei

The procedures performed in this study were approved by the Ethics Committee in Animal Use (CEUA) of UNESP, Rio Claro-SP, Opinion No. 05/2023, and registered with the Genetic Patrimony Management Council under no. A483C7F.

For the development of the bioassays, engorged females of *R. linnaei*, fed on rabbits of the Botucatu Genetic Group, weighing between 3 and 3.5 kg each. Infestations were conducted in a room at the Animal Facility of the Department of General and Applied Biology, Institute of Biosciences (IB), UNESP, Rio Claro (SP), which houses the Brazilian Center for Tick Morphology Studies (BCSTM) and maintains tick colonies.

Adult Immersion Test (AIT)

The engorged females were manually harvested from host rabbits, with the aid of tweezers, by means of rotation movements until their total detachment, which allowed preserving the integrity of the ectoparasite's mouthparts. Subsequently, they were cleaned with distilled water, rinsed with absorbent paper and selected based on similarity in weight.

The bioassays were carried out in triplicates, according to the allocation of engorged females in the Controls (C1-C3) and Treatments (T1-T10) groups, respectively, as below

C1: Control, exposed only to distilled water

C2: control, exposed only to 2% Tween 80

C3: Control, exposed only to Selamectin at a concentration of 0.512 mg/mL

T1-T10: treatment, exposed to the ricinoleic acid salt of castor oil at concentrations of 0.195 to 100 mg/mL

The ticks were immersed (10 individuals/group for 5 minutes) in glass containers filled with 3 mL of each compound to be tested, according to Drummond et al. (1973). Excess liquid was blotted with absorbent paper, and the groups were placed in labeled Petri dishes and incubated in a BOD chamber under controlled conditions (28 ± 3°C, 80% relative humidity, 12 h photoperiod) for 15 days to allow oviposition. After laying, eggs were weighed, transferred to 5 mL plastic syringes sealed with hydrophilic cotton, and returned to the same incubation conditions for an additional 15 days.

Impact of formulations on intestinal enzymes of treated engorged females

Three digestive enzymes: alkaline phosphatase, acid phosphatase, and serine protease have been reported to be present in midgut tick cells (Agyei et al. 1992; Gough and Kemp 1995; Reyes et al. 2020). In the present study, these enzymes were quantified in adult females exposed to the ricinoleic acid salt of castor oil, following the protocol proposed by Muharsini et al. (2000).

After 24 h of exposure to the compounds, the females were dissected to remove fragments from the midgut (Midgut Lumen and Diverticula/Caeca) and integument fragments (Cuticle/Procuticle), which were identified and properly stored at -20ºC for further analysis of the different enzymes. To standardize the sample volume required for the tests, 96-well microtiter plates were incubated in the dark, and filled with 0.1, 0.2, 0.3, 0.5 and 1 mL of alkaline phosphatase, acid phosphatase and serine proteases, respectively, using one plate for each enzyme.

Alkaline phosphatase (ALP) activity

The working substrate solution of 7.6 mM p-Nitrophenylphosphate and glycine buffer (pH 10.5) containing 9.5 mg of magnesium chloride ($MgCl_2$) were prepared in distilled water and 1 N sodium hydroxide (NaOH), respectively, for storage at 4ºC. The working substrate solution was prepared fresh by mixing equal volumes of p-Nitrophenylphosphate and buffer solution. A sample (100 mg) of the midgut was crushed in glycine buffer (pH 10.5), centrifuged at 1,100 x g for 5 min, and the supernatant collected. Three microtubes (one test, one test blank and one reagent blank) containing substrate (76 mg of p-Nitrophenylphosphate), except for the test blank tube, were pre-incubated for 5 min at 37ºC. The 0.2 mL of supernatant was added to the tubes, except for the blank reagent tube. Then, 0.2 mL of distilled water was added and incubated at 37ºC for 30 min and then 1 mL of 0.1 N NaOH was added to all tubes. The optical density (OD) was read at 405 nm against white and the enzyme activity determined as:

Alkaline phosphatase activity (IU) = {[A(T) - A(TB)-A(RB)]/Exb} * 10^6 * (TV/EV) * (1/t) = {[A(T)-A(TB)-A(RB)]/18530} * 10^6 * (2.5/0.02) * (1/30) = A(T)-A(TB)-A(RB) * 20.25 µmol/min/L

Where: A(T) - Absorbance of the test sample; A(TB)-test white absorbance; A(RB)-reagent white absorbance; 10^6- converting moles to µmol; TV - test volume; EV - sample volume; t - incubation time; Exb - value of the coefficient.

Acid phosphatase (ACP) activity

0.02 M p-Nitrophenyl phosphate solution and citrate buffer (pH 5.0) were prepared in distilled water and stored at 4ºC. The working substrate solution was prepared by mixing equal volumes of p-Nitrophenylphosphate and buffer before use. Three substrate-containing microtubes (74 mg of p-Nitrophenylphosphate), except for the test blank, were pre-incubated for 5 min at 37ºC. A standardized volume of supernatant was added, except in the blank reagent tube, along with an equal volume of distilled water. The samples were then incubated at 37ºC for 30 min and 1 mL of 0.1 N NaOH was added to all tubes. The DO was estimated at 420 nm against white and the enzyme activity determined using the equation:

Acid phosphatase activity (IU) = {[A(T) - A(TB) - A(RB)]/Exb} * 10^6 * (TV/EV) * (1/t) ={[A(T)-A(TB)-A(RB)]/18530} * 10^6 * (2.5/0.02) * (1/30) = A(T)-A(TB)-A(RB) * 20.25 µmol/min/L

Serine protease activity

Commercially available p-Nitroaniline (Sigma-Aldrich, 185310) was used for the preparation of the standard curve. The stock solution was prepared by dissolving 5 mg of p-Nitroaniline in 5 mL of Tris-hydrochloride 100 mM (Tris-HCl) containing 20 mM of calcium chloride ($CaCl_2$). In a 96-well microtiter plate, 100 µL of the stock solution was used to perform serial dilutions, and the final concentration of p-Nitroaniline was 1mg/mL. After the preparation of the standard curve, Tris-HCl 100 mM, pH 7.8 containing 20 mM $CaCl_2$ and 3.5 mM SAPNA (N-succinyl-Ala-Ala-Pro-Phe-p-nitroanilide) were prepared in distilled water, and this solution was later stored at 4ºC.

All parts of the midgut of females exposed to the compound described here were kept independently for each concentration of the evaluated compound, in a solution of Tris-HCl 100 mM, pH 7.8 containing $CaCl_2$ 20 mM until the analysis of the enzymatic activity. The assays were performed on 96-well microtiter plates by adding 40 µL of substrate (3.5 mM SAPNA) to 150 µL of buffer (10 µL of sample for each well). The plates were incubated (1 h, 37ºC) and the absorbance was measured at 405 nm. The standard curve of p-Nitroaniline (Sigma-Aldrich) was used to determine the concentration of the product.

Determination of total protein and cuticle chitin

To evaluate the action of exposure to the salt of ricinoleic acid in castor oil on the cuticle of female ticks, after AIT, the concentrations of total protein and the concentration of chitin of the cuticular homogenate were determined, according to Bradford (1976).

Protein Concentration Analysis

Cuticle fragments were removed, washed with 1% sodium tetraborate and rapidly washed in distilled water and 70% ethanol. The purity of the proteins was then verified according to Bradford's protocol (1976). About 10 mg of cuticle/replica were kept at -20ºC, crushed in 5 mM Tris buffer containing 7M urea in a crucible with pistil, sonicated and centrifuged at 10,000 x g for 10 min. The supernatant was collected, and the protein concentration was estimated using a standard curve of the BSA method (bovine albumin serum).

Chitin Concentration Analysis

Commercially available N-acetyl-D-glucosamine (Sigma-Aldrich, A8625**)** was used for standard curve preparation. The stock solution was prepared by dissolving 20 mg of N-acetyl-D-glucosamine in 10 mL of distilled water, followed by serial dilutions with distilled water, and the final concentration adjusted to 2 mg/mL. The cuticular homogenate was centrifuged (1,500 x g, 5 min, 2ºC), the supernatant was discarded, and the sediment was resuspended in 4 mL of sodium lauryl sulfate (SDS 3% w/v) and heated (100ºC, 15 min). After cooling, another centrifugation step was performed, and the supernatant was discarded. The sediment was then washed once with distilled water, resuspended to 3 mL of potassium hydroxide (KOH) (120 g in 100 mL of water) and heated (130ºC, 1 h). After cooling, 8 mL of ice-cold ethanol (75% v/v) was added, and the samples were shaken until the KOH and ethanol formed only one phase.

The tubes were kept in ice water for 15 min and 0.3 mL of Celite suspension (1 g of Celite 545 was mixed with 75% ethanol to collect the supernatant after 2 min). Then they were centrifuged (1,500 x g, 5 min, 2ºC) and the sediment washed once with cold ethanol (40% v/v) and twice with ice water. The sediment containing insoluble chitosan was stored at 4ºC for the subsequent bioassay. Distilled water was added to the chitosan pellet up to the 0.5 mL mark in the sample tubes. Since chitosan is evaluated against a known amount of glucosamine, the standards containing 0.2 mL of water or 0.2 mL of glucosamine (10 µg/mL) have been adjusted.

0.5 mL of sodium nitrite ($NaNO_2$ 5% w/v) and 0.5 mL of potassium bisulfate (KHSO 4.5% w/v) were added to each of the samples; at least 0.2 mL of each solution was added to the standards. All tubes were gently mixed three times and then centrifuged (1,500 x g, 2 min, 2ºC).

A volume of 0.6 mL of supernatant from the sample tubes were taken into two tubes and together with the standards were brought to room temperature. 0.2 mL of ammonium sulfamate (12.5% w/v) were added to all tubes and mixed vigorously for 5 min. Then, 0.2 mL of a solution of MBTH (50 mg of 3-methyl-benzo-2-thiazorolone HCl monohydrate in 10 mL of water) prepared fresh was added and the tubes were then heated (100ºC, 3 min).

After cooling, 0.2 mL of ferric chloride hexahydrate ($FeCl_3$- $6H_2O$ 0.83% w/v) was added and the optical density (650 nm) measured after 25 min in a spectrophotometer. The chitin content was expressed as a glucosamine equivalent.

The untreated cuticle that gave a slight color reaction was used as white. The chitin

content of the cuticle (X) was determined by the equation: X=5 (A-B)+(G-W) µg glucosamine, where the optical density (650 nm) for the test sample is A, the untreated control is B, the glucosamine standard is G, and the water standard is W.

Morphological analysis of the midgut

After 24 h of exposure of the females (10/group) to the different concentrations of the ricinoleic acid salt of castor oil, they were collected. Subsequently, ticks were anesthetized by thermal shock (2°C for 1 min to reduce metabolism without causing mortality), their midguts were dissected and fixed in 4% paraformaldehyde for 72 h, then transferred to sodium phosphate buffer (pH 7.2) for 24 h. Dehydration was performed in a graded ethanol series (70%, 80%, 90%, and 95%) at 20-min intervals. Leica resin infiltration was performed (Leica Historesin Embedding Kit) and then the tissues were placed in plastic molds and kept at 4ºC, thus delaying the polymerization of the resin and allowing it to penetrate the tissues. After polymerization, the blocks were sectioned to 3 µm thick in Leica RM 2255 microtome, and the sections were collected on glass slides

Harris-eosin aqueous hematoxylin staining

The sections were rehydrated for 1 minute in distilled water and stained with Harris hematoxylin for eight minutes. After being washed for three minutes in running water, they were stained with aqueous eosin for five minutes and washed again under running water (Junqueira and Junqueira 1983). After drying on wooden supports at room temperature, they were dipped in xylol and covered with Entellan (medium for mounting permanent slides) between coverslips for microscopic observation.

Histochemistry

Bromophenol Blue Technique

For the detection of total proteins, the sections were stained by the bromophenol blue solution at room temperature for 2 hours (Pearse 1985). They were then bathed in an aqueous solution of 0.5% acetic acid for 5 minutes. Soon after, they were passed in tertiary butyl alcohol for 5 minutes. Then, they were dried, diaphanized in xylol and mounted on Entellan and coverslip for later microscopic observation.

Periodic acid-Schiff PAS technique

The sections were rehydrated for 1 minute in distilled water, stored in 10% neutral-buffered formalin (NBF) and transferred to 4% periodic acid solution for 10 minutes. Afterwards, they were washed in distilled water for 1 minute and immersed for 1 hour in Schiff's reagent (Junqueira and Junqueira 1983). They were washed for 30 minutes in running water, dried at room temperature, diaphanized in xylol and mounted on Entellan and coverslip for later microscopic observation.

After applying histological and histochemical techniques, the permanent slides were examined and photographed using a Leica DM750 (Leica®) bright field microscope at the Histology Laboratory of the Department of General and Applied Biology at IB/UNESP/Rio Claro, São Paulo.

Statistical analyses

The biological parameters used to evaluate the effects of ricinoleic acid salt by AIT followed those established by Drummond et al. (1973) and Bennett (1974).

The regression analysis probit was applied to the data obtained from the AITs, respectively, to express the LC_{50}.

The data obtained from the impact of the bioactive on the activity of the different enzymes of the midgut of adult females were analyzed by the two-way ANOVA test followed by Tukey's post hoc test, to evaluate the differences between the arithmetic means of the treated and control groups; and the effects of concentration, time, and the concentration × time interaction (for the assessment of enzymatic activity). All statistical analyses were performed using the XLSTAT 2021 program, and the significance level for all tests was set at $p < 0.05$.

Results

Biochemical analyses

The qualitative analysis showed that the salt of ricinoleic acid was identified as the main compound from bioactive. Figure 1 details the purity of the identified compound

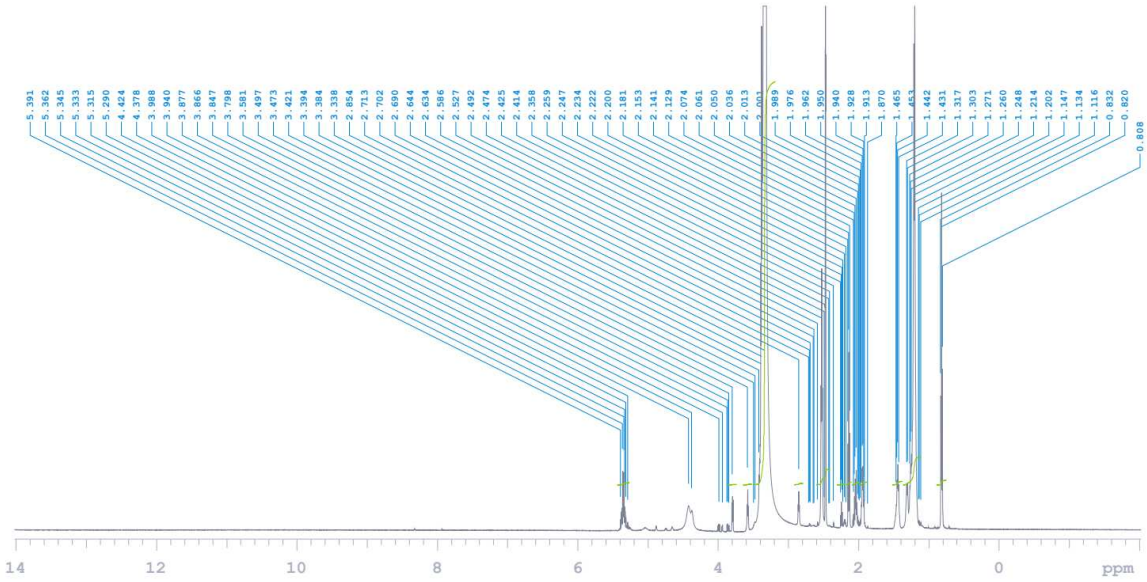

i cdc ph

INTEGRAL VALUES

Integral	start(ppm)	end	value
1	5.44638	5.26039	0.468
2	3.86154	3.7333	0.091
3	3.64716	3.51403	0.173
4	3.49347	3.17827	86.077
5	2.92081	2.78671	0.364
6	2.60659	2.40102	3.335
7	2.31292	2.19643	0.191
8	2.19643	2.09854	0.589
9	2.09756	1.98401	0.521
10	1.98303	1.8685	0.590
11	1.52099	1.37415	0.713
12	1.37415	1.10593	5.929
13	0.893513	0.743741	0.961

PEAK FREQUENCIES

index	freq(ppm)	intensity
1	5.39111	2.44005
2	5.38034	4.08114
3	5.37251	4.83157
4	5.36174	13.1064
5	5.35293	10.7155
6	5.3451	12.9058
7	5.33335	5.187
8	5.3265	4.20833
9	5.31476	2.47673
10	5.29029	1.7866
11	5.2805	1.01236
12	4.42401	5.37195
13	4.37801	4.38741
14	3.9992	1.27417
15	3.98843	1.35127
16	3.9806	1.17556
17	3.94047	1.18752
18	3.87684	1.25593
19	3.86607	1.39749
20	3.85824	0.952489
21	3.84748	1.06794
22	3.80636	6.05077
23	3.79755	7.4739
24	3.79462	4.92053
25	3.78972	6.72478
26	3.59004	5.6556
27	3.58123	9.01081
28	3.57144	5.42524
29	3.49705	1.10658
30	3.48139	1.80289
31	3.47258	1.84775
32	3.4207	12.3289

PEAK FREQUENCIES(CONTINUED)

index	freq(ppm)	intensity
33	3.41189	15.9063
34	3.40406	19.1372
35	3.39427	59.5548
36	3.3835	112.359
37	3.37372	96.4918
38	3.33848	5809.27
39	2.86374	5.61555
40	2.85395	8.61298
41	2.84514	5.55463
42	2.713	1.10471
43	2.70223	1.46351
44	2.69049	1.23124
45	2.64448	1.01681
46	2.63371	1.06553
47	2.58869	1.49842
48	2.58575	1.83469
49	2.58281	1.58694
50	2.53681	32.2891
51	2.52702	58.3322
52	2.51723	31.7159
53	2.49178	2.37653
54	2.48004	50.2853
55	2.4771	107.238
56	2.47416	146.021
57	2.47123	106.066
58	2.42522	0.977778
59	2.41445	1.0361
60	2.36062	1.30843
61	2.35768	1.56445
62	2.35474	1.30565
63	2.25882	3.34587
64	2.24707	6.30217
65	2.23435	4.02404
66	2.22162	1.39189
67	2.20988	1.82334
68	2.20498	1.97081
69	2.20009	2.40779
70	2.19323	2.2861
71	2.18834	1.65327
72	2.18149	1.25528
73	2.1531	19.2366
74	2.14136	39.668
75	2.12863	21.6463
76	2.0836	2.21956
77	2.07382	3.5444
78	2.06109	7.43113
79	2.05032	11.4386
80	2.04641	10.3317
81	2.03564	13.3608
82	2.02585	6.16195
83	2.01313	3.0719

PEAK FREQUENCIES(CONTINUED)

index	freq(ppm)	intensity
84	2.00138	2.00812
85	1.98866	1.70461
86	1.97593	2.17463
87	1.96223	5.62357
88	1.95831	5.49189
89	1.95048	13.8366
90	1.93972	14.2292
91	1.92797	6.83812
92	1.91329	1.44533
93	1.87022	0.936099
94	1.46498	5.67551
95	1.45323	11.1866
96	1.44246	14.5521
97	1.43072	10.1357
98	1.31717	10.1554
99	1.30934	8.48299
100	1.30347	10.4329
101	1.27117	9.83213
102	1.2604	14.74
103	1.24768	16.9352
104	1.21439	108.484
105	1.20167	126.9
106	1.14685	1.86257
107	1.13413	2.06924
108	1.12238	1.55229
109	1.11553	1.73876
110	0.831668	29.9537
111	0.819922	75.2163
112	0.812091	11.1491
113	0.808176	35.9087

Figure 1. Salt base chromatogram of ricinoleic acid from castor oil (*Ricinus communis*)

Results of AIT/*In vitro* dose dependent response

Table 1 shows the mean results obtained by AIT for the different concentrations of the ricinoleic acid salt in castor oil and for the negative and positive controls.

Table 1. Mean of effects of treatments on biological parameters of *Rhipicephalus linnaei* in the Adult Immersion Test (AIT)

Treatments (mg/mL)	FW(g)	EW (g)	% hatching	REI	Efficacy (%)
100	2.49 ± 0.2 [a]	1.25 ± 0,3 [a]	95.00 ± 1.2 [a]	98.14 ± 2.0 [b]	-
50	2.44 ± 0.1 [a]	1.20 ± 0.0 [a]	95.00 ± 1.5 [a]	98.10 ± 2.0 [b]	-
25	2.40 ± 0.0 [a]	1.10 ± 0.0 [a]	98.00 ± 2.1 [a]	98.07 ± 1.1 [b]	-
12.5	2.42 ± 0.0 [a]	1.13 ± 0.0 [a]	98.00 ± 2.1 [a]	98.03 ± 1.1 [b]	-
6.25	2.38 ± 0.0 [a]	1.20 ± 0.1 [a]	98.00 ± 2.1 [a]	98.00 ± 1.1 [b]	-
3.13	2.38 ± 0.0 [a]	1.10 ± 0.0 [a]	98.00 ± 1.9 [a]	98.00 ±1.1 [b]	-
1.56	2.40 ± 0.0 [a]	1.00 ± 0.0 [a]	98.00 ± 1.5 [a]	98.02 ± 1.1 [b]	-
0.78	2.36 ± 0.0 [a]	1.13 ± 0.0 [a]	98.00 ± 1.1 [a]	98.21 ± 1.1 [b]	-

0.39	2.38 ± 0.0 [a]	1.11± 0.0 [a]	98.00 ± 1.7 [a]	98.12 ± 3.1 [b]	-
0.195	2.36 ± 0.0 [a]	1.13 ± 0.0 [a]	97.00 ± 2.2 [a]	99.01 ± 1.1 [b]	-
H_2O (Ctrl Negative)	2.40 ± 0.0 [a]	1.19 ± 0.0 [a]	98.00 ± 1.2 [a]	98.31 ± 3.1 [b]	-
Selamectin [0.512]	2.42 ± 0.0 [a]	0.61 ± 0.2 [a]	83.00 ± 2.4 [a]	2.80 ± 3.3[a]	96.9 ± 4.0

*Different letters in the same column indicate significantly different values by ANOVA and Tukey's test ($p \leq 0.05$). Engorged female weight - FW, egg weight - EW, Reproductive Efficiency Index – REI.

As shown in Table 1, the negative control (distilled water) had no deleterious effect on engorged females, yielding a high Reproductive Efficiency Index (REI) of 98.31%. In contrast, ricinoleic acid salt in castor oil showed no efficacy or oviposition inhibition at 100 mg/mL or at lower concentrations, whereas the positive control (Selamectin at 0.512 mg/mL) achieved 96.9% efficacy against engorged females.

According to these results (Table 1), it was not possible to calculate the respective lethal concentrations (LC_{50} and LC_{90}). For the subsequent experiments, that is, morpho-histochemical analyses, engorged females exposed to the bioactive at doses of 25 to 0.195 mg/mL were used.

Even in the absence of acute acaricidal activity, assessing digestive enzyme activity and midgut histology is scientifically justified, as sublethal exposure can uncover mode-of-action signals, physiological stress, or early toxicity biomarkers that precede mortality. Such mechanistic and histological analyses convert a “no mortality” result into actionable biological insight, guiding the rational design of next-generation tick-control agents.

Impact of castor oil ricinoleic acid salt on intestinal enzymes of engorged females

The levels of alkaline phosphatase, acid phosphatase, and serine protease, respectively, are shown in Table 2. Compared between the control and treatment groups, no significant differences were observed.

Table 2. Comparative quantitative profile of enzymes (mean ± standard error) in homogenized intestinal tissue of *R. linnaei* 24 and 48 hours after exposure to ricinoleic acid salt from castor oil.

Midgut enzymes (µmole/min/L)	Control Groups				Treatment Groups					
	H_2O		Selamectin [0.512]		25		12.5		6.25	
	24h	48h	24h	48h	24h	48h	24h	48h	24h	48h
Alkaline phosphatase	15.22 ± 0.2 ^{a}	16.10 ± 0.2 ^{a}	23.00 ± 0.2^{c}	27.27 ± 0.5^{c}	15.77 ± 0.4 ^{a}	18.22 ± 0.2 ^{ab}	16.16 ± 0.1 ^{a}	18.00 ± 0.3 ^{ab}	15.41 ± 0.3 ^{a}	17.08 ± 0.2 ^{ab}
Acid phosphatase	28.47 ± 0.3 ^{a}	29.27 ± 0.1 ^{a}	46.87 ±0.1^{e}	50.21 ± 0.9^{f}	27.09 ± 0.9 ^{a}	29.16 ± 0.7 ^{ab}	26.12 ± 0.2 ^{a}	29.11 ± 0.2 ^{ab}	28.00 ± 0.1 ^{a}	31.33 ± 0.3 ^{b}
Serine proteases	0.89 ± 0.0 ^{a}	0.9 ± 0.0 ^{a}	1.56 ± 0.1 ^{b}	2.01 ± 0.2 ^{b}	0.90 ± 0.1 ^{a}	1.00 ± 0.1 ^{a}	0.87 ± 0.0 ^{a}	0.93 ± 0.0 ^{a}	0.91 ± 0.0 ^{a}	0.99 ± 0.1 ^{a}

Table 2. Continued

Midgut enzymes (µmole/min/L)	Treatment Groups									
	3.13		1.56		0.78		0.39		0.195	
	24h	48h	24h	48h	24h	48h	24h	48h	24h	48h
Alkaline phosphatase	15.12 ± 0.4^{a}	16.80 ± 0.6^{a}	14.97 ± 0.0^{a}	16.11 ± 0.1^{a}	15.00 ± 0.5^{a}	16.96 ± 0.3^{ab}	15.11 ± 0.3 ^{a}	17.22 ± 0.1 ^{ab}	16.23 ± 0.4 ^{a}	18.88 ± 0.4 ^{ab}
Acid phosphatase	29.12 ± 0.3^{a}	32.44 ± 0.3^{b}	29.56 ± 0.2^{a}	29.88 ± 0.1^{a}	30.98 ± 0.1^{ab}	33.47 ± 0.2^{b}	36.40 ± 0.2^{c}	37.12 ± 0.3^{c}	37.47 ± 0.3^{c}	39.27 ± 0.1^{d}
Serine proteases	0.93 ± 0.0 ^{a}	1.01 ± 0.2^{a}	0.89 ± 0.1^{a}	0.97 ± 0.0 ^{a}	0.88 ± 0.0^{a}	0.99 ± 0.0^{a}	0.96 ± 0.3 ^{a}	1.00 ± 0.5 ^{a}	0.98 ± 0.1 ^{a}	1.06 ± 0.1 ^{a}

*Different letters in the same row indicate (for each enzyme) significantly different values effects of concentration, time, and the concentration × time interaction; according to two-way ANOVA and Tukey's test ($p \leq 0.05$).

Regarding the enzymes alkaline and acid phosphatase, the results of the present study showed that the activity indices of both enzymes in the control (water) and treatment groups (0.195 to 25.0 mg/mL) were statistically similar for the same evaluation period (24 or 48 h after exposure), however, all the previous ones differed statistically from the positive control group (Selamectin at 0.512 mg/mL), where the highest index of enzymatic activity was observed from 23.00 to 27.27 μmol/min/L and 46.87 to 50.21 μmol/min/L after 24 and 48 h, respectively, of the engorged females having been exposed to the salt of ricinoleic acid in castor oil.

The result of the serine protease analysis in all treatment and negative control groups was statistically similar when compared to the results in the same period of exposure to the bioactive, but all statistically different from the positive control group (Revolution®); where the highest activity indices (1.56 to 2.01 μmol/min/L) were detected.

Effect of ricinoleic acid salt on total protein and cuticle chitin production of engorged females

Table 3 presents the results of total protein as well as the quantification of the chitin content. The protein concentrations of the extracts obtained from the cuticle of engorged female ticks of the different groups analyzed here were detected by the Bradford method (Bradford, 1976) using fetal bovine serum albumin as standard.

Table 3. Quantitative profile of chitin and total cuticular protein content in engorged females of *R. linnaei* exposed to ricinoleic acid salt from castor oil

Treatments (mg/mL)	Chitin content (mg of glucosamine/mL)	Total Protein (mg/mL)
100	0.89 ± 0.0^{ab}	2.96 ± 0.0^{ab}
50	0.90 ± 0.0^{ab}	2.92 ± 0.2^{ab}
25	0.89 ± 0.0^{ab}	2.98 ± 0.0^{ab}
12.5	0.89 ± 0.0^{ab}	2.98 ± 0.0^{ab}
6.25	0.88 ± 0.0^{ab}	2.97 ± 0.0^{ab}
3.13	0.88 ± 0.0^{ab}	2.99 ± 0.0^{ab}
1.56	0.89 ± 0.0^{ab}	2.98 ± 0.0^{ab}
0.78	0.87 ± 0.0^{ab}	2.98 ± 0.0^{ab}
0.39	0.89 ± 0.0^{ab}	2.98 ± 0.0^{ab}
0.195	0.88 ± 0.0^{ab}	2.99 ± 0.1^{ab}
H_2O (Ctrl Negative)	0.91 ± 0.0^{a}	3.02 ± 0.1^{b}

Selamectin [0.512]	0.68 ± 0.1[a]	2.12 ±0.1[a]

* Different letters in the same column indicate values that are significantly different according to ANOVA and Tukey's test ($p \leq 0.05$).

Thus, the following results were obtained regarding the chitin content: Control (distilled water) = 0.91 mg of glucosamine/mL; Treatment (0.195 to 100 mg/mL) = 0.89 ± 1 mg glucosamine/mL; Positive Control (Selamectin) = 0.68 mg of glucosamine/mL, which were statistically similar, however, the treatment and control groups, respectively, differed statistically from the positive control.

The behavior of the total protein content of the integument of engorged females, exposed to the salt of ricinoleic acid in castor oil, was the same as that of the quantification of chitin. The treatment and negative control groups were statistically similar but differed statistically from the positive control group.

Morphological and histochemical analyses of engorged females exposed to the salt of ricinoleic acid in castor oil

The digestive tract of *R. linnaei* females is composed of three distinct regions: foregut, midgut and hindgut. In this study, the midgut of engorged females was analyzed using histological techniques (hematoxylin and eosin staining) and histochemical techniques (periodic acid Schiff reaction for neutral polysaccharide (PAS) labeling and bromophenol blue total protein labeling.

Control group: The histological results revealed that the midgut of engorged females is covered by a stratified epithelium, with cells ranging from cubic to cylindrical; having round or oval nuclei in different positions (Figure 2A). The latter are positioned close to the lumen and exhibit spherical to oval nuclei with condensed heterochromatin. The cells of the basal layers (undifferentiated) have cytoplasm intensely stained by hematoxylin and some vacuoles weakly stained. The cells of the layers closest to the lumen have highly vacuolated cytoplasm and weakly stained by the dyes tested. In the apical region of the cells of the layer closest to the lumen, probably digestive cells, vacuoles are observed. Some cells still seem to be releasing vesicles towards the intestinal lumen, which are rounded in shape and have different sizes. In addition, some of these vesicles were heavily stained, and everything indicates that they contained cell debris inside.

Treatment groups: In these groups (doses from 0.78 to 12.5 mg/mL), the stratified intestinal epithelium was disorganized, a fact that was not previously observed in the control group

(Figure 2B, C, D, E, F, G). It is also noted that the epithelium of the group exposed to a dose of 25.0 mg/mL (Figure 2G) presents cells with the same characteristics observed in the control group. The generative cells, mostly cubic in shape, showed cytoplasmic vacuolation and nuclei with chromatin ranging from less condensed to pycnotic (Figure 2C). More intense disorganization was observed in the intestine of females exposed to 0.79 mg/mL (Figure 2B) of the bioactive, where the intestinal epithelium was simple, with the basement membrane that supports the epithelium detaching from it leaving a large empty space. Cell boundaries were no longer evident, especially those of generative cells (Figure 2C, D, E, F). In general, the cellular changes did not follow a dose-response pattern, that is, the greatest changes were observed only in the exposures of females to lower doses of the bioactive.

Histochemical analysis

Protein detection

The histochemical results for total protein labeling showed that in engorged female *R. linnaei* ticks, the digestive cells were strongly marked by the test.

In the control group (Figure 2A), it was found that the midgut epithelium is still stratified and reacting positively to the test. The cytoplasmic content of digestive cells did not show variation in the intensity of bromophenol blue staining. It was possible to observe the cells with an intact aspect, but weakly marked, showing a low protein content. Near the lumen, vacuolation was observed with weak positivity to bromophenol blue, during weakly positive cytoplasmic remains.

As for the treatment groups, i.e., females exposed to the ricinoleic acid salt of castor oil at doses of 0.78 to 12.5 mg/mL, the cellular limits could no longer be evidenced, especially in generative cells (Figure 2C, D, E, F). The cytoplasm of the generative cells showed a decrease in the intensity of bromophenol blue staining (median positivity) in relation to the control group. The cells of the epithelial layers located closer to the lumen of the intestine showed cytoplasm with vacuolation and weakly positive to bromophenol blue. In Figures 2 E to 2F, it is observed that the apical domain of the digestive cells is the place where there is greater vacuolation and this is weakly positive. Likewise, the cells of the basal layers (generative or undifferentiated cells) showed cytoplasm strongly stained by bromophenol blue with the presence of some faintly positive vacuoles.

In the group of females exposed to the dose of 25.0 mg/mL (Figure 2G), the same characteristics were not observed; The integrity of the cells was preserved, like those of the

control group, and showed weak weakly positive labeling for proteins.

Detection of polysaccharides

The generative intestinal cells of the females allocated to the control group presented the cytoplasm with intense positive polysaccharide granulation heterogeneously distributed (Figure 2A). The presence of polysaccharides in the intercellular space of digestive and generative cells was also observed.

In the treatment groups, more intense positive PAS marking was observed in the cytoplasm (Figure 2E, F, G). The cells in direct contact with the lumen showed negative vacuoles to PAS. Some appeared to be releasing portions or even detaching from the epithelium towards the lumen, in the form of strongly PAS-positive vesicles (Figure 2 B, D, F and G).

In the digestive cells, cytoplasmic vacuolation was observed with the same pattern of labeling for proteins described for the control group (Figure 2G). In these cells, cytoplasmic granules were also observed that reacted moderately to PAS. In addition, digestive cells were partially or totally filled by yellowish/brownish granulation.

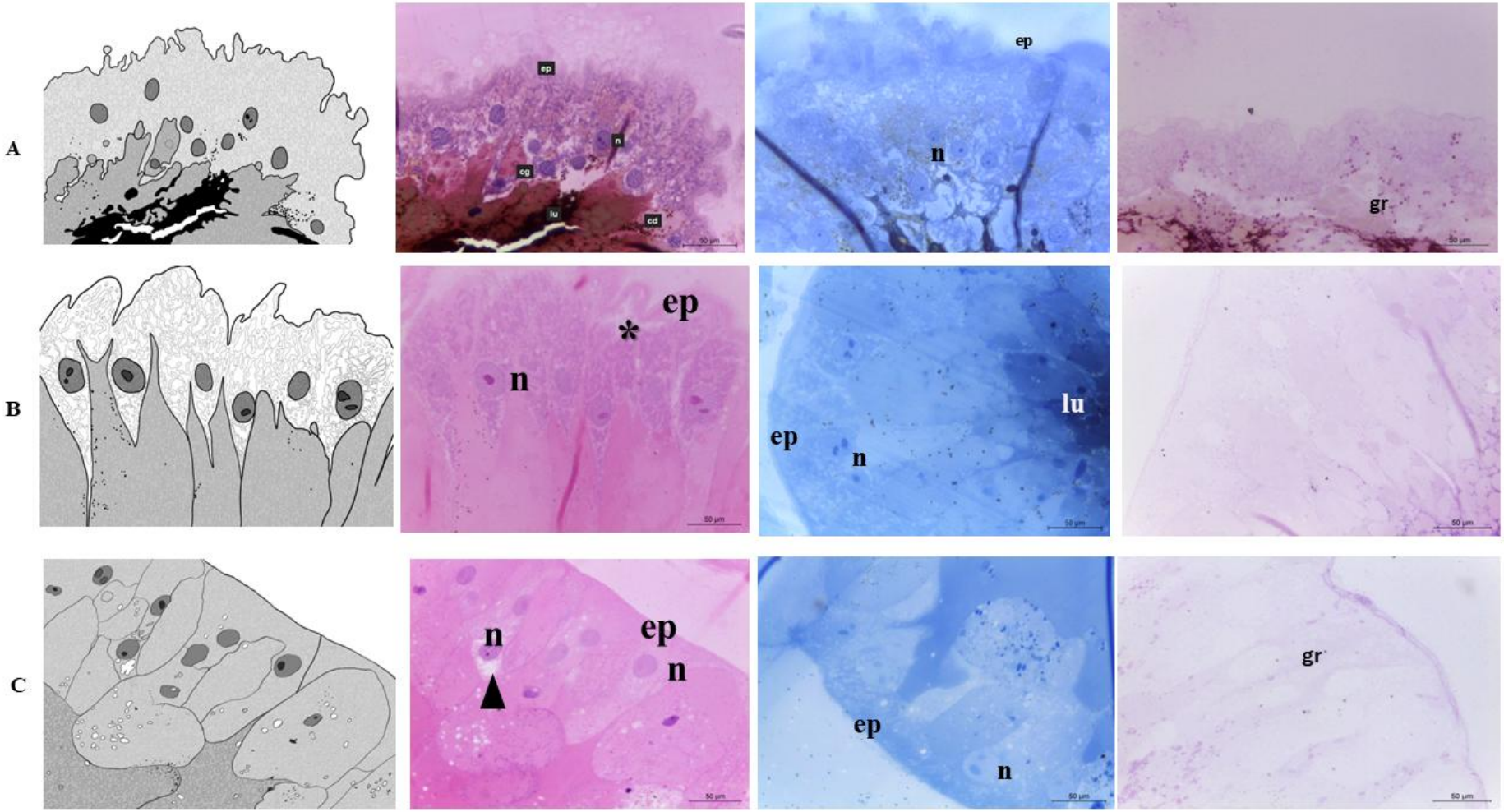
A
B
C
ep
n
cg
lu
cd
gr
*
50 µm

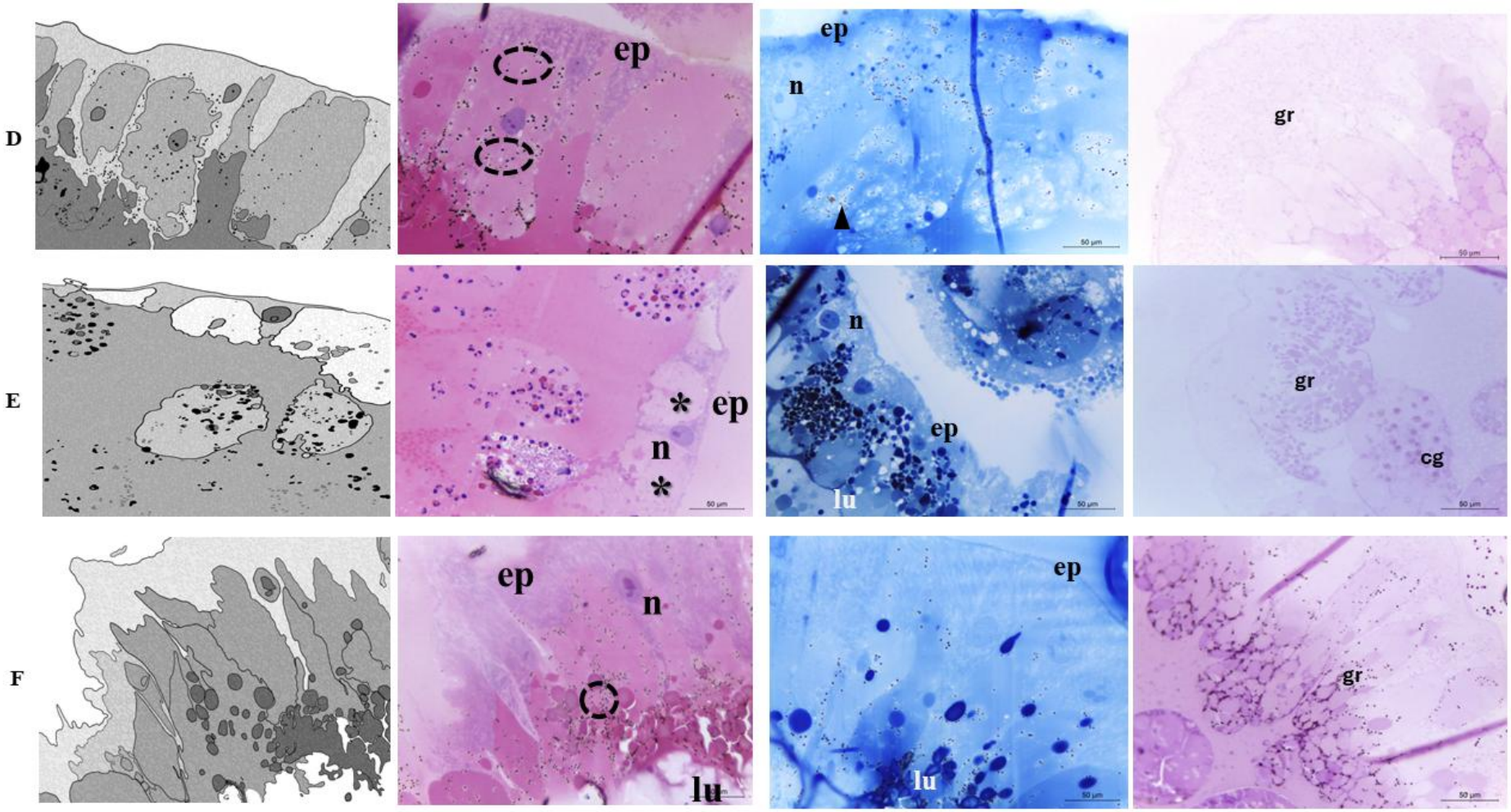
D
ep
ep
n
gr
E
* ep
n
*
n
ep
lu
gr
cg
F
ep
n
lu
ep
lu
gr

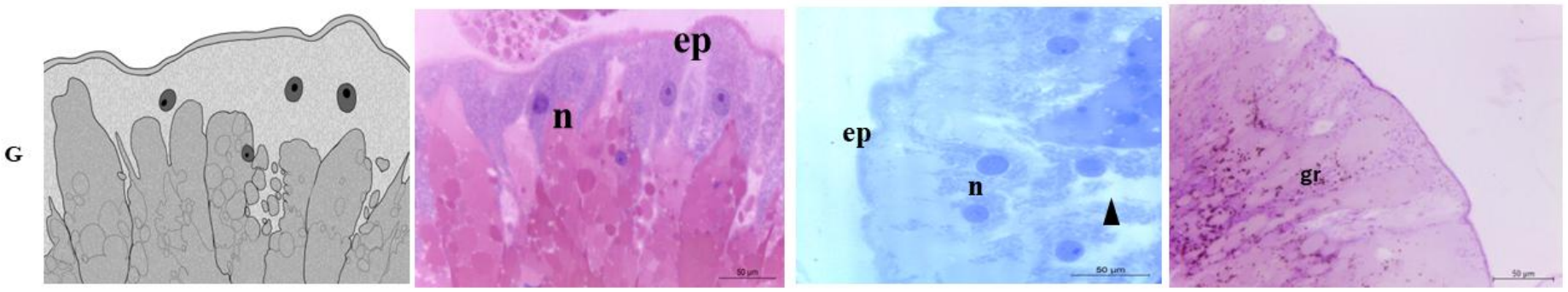

Figure 2. Schematic representation (column 1), Hematoxylin and eosin staining (column 2), Bromophenol blue staining for total proteins (column 3), Periodic acid–Schiff staining for carbohydrate-rich components (column 4) of the midgut of R. *linnaei* females exposed to different doses of the ricinoleic acid salt in castor oil

A – Control Group; **B** – Treatment group at 0.78 mg/mL; **C** – Treatment group at 1.56 mg/mL; **D** – Treatment group at 3.13 mg/mL; **E** – Treatment group at 6.25 mg/mL; **F** – Treatment group at 12.5 mg/mL; **G** – Treatment group at 25 mg/mL

Details of epithelium (ep), nucleus (n), generative cells (cg), digestive cells (cd) and lumen (lu), vacuolization, (black arrowheads), space resulting from the detachment of the basement membrane (*), fragments of hematin-rich lized cells and free particles (dotted circle), granules, specifically secretory granules (gr). Range: bar = 50µm

Discussion

In the present study, the evaluation of the effects of the different doses of the ricinoleic acid salt of castor oil on engorged females of *R. linnaei* exposed to the bioactive through the immersion bioassay, showed that there was no inhibitory effect on the reduction of egg mass. Thus, the evaluation of the toxic potential (LC_{50}) obtained from the bioassays, in which the engorged females are submerged in different concentrations of the ricinoleic acid salt of castor oil (Adult Immersion Test), was not estimated, given the low efficacy/acaricidal activity of the bioactive.

For tick control, chemical tick repellents are used to disrupt specific functions of target organs so that the population can be controlled at a significant level. In the present study, we focused on the midgut of ticks, which is the site of predilection for blood digestion (Sonenshine and Roe 2014). As digestion in ticks is an intracellular process, changes in the profile of digestive cells can affect the process of blood digestion and therefore the synthesis of vital proteins necessary for successful vitellogenesis and egg production. It should be noted that several digestive enzymes are involved in the digestion of blood in ticks (Chevillon et al. 2007; Sojka et al. 2013).

In this sense, digestive enzymes, acid phosphatase (ACP), alkaline phosphatase (ALP) and serine proteases (SP) have been reported to be present in midgut cells of ticks (Mulenga et al. 2003), located in intracellular vesicles in the epithelia of the midgut, and under normal conditions would not be available in the midgut lumen. In the present study, it was observed that the activity of the enzymes ACP, ALP and SP, in both evaluation periods (24 and 48 hours), remained at values very close to those of the negative control group (distilled water), suggesting the occurrence of an inhibition on the part of the digestive cells, which, being altered, lost part of the capacity to absorb proteins from the host's blood. as well as the formation of endosomes and, finally, phagolysosomes (Bisht et al. 2024). The results found here also suggested the non-involvement of these enzymes in the detoxification process against xenobiotics, thus signaling the low probability of the emergence of tick resistance to the ricinoleic acid salt of castor oil.

Externally, ticks are surrounded and protected by an exoskeleton made up of proteins (chitin) and polysaccharides, which also provide them with stability and flexibility (Hackman 1982; Kramer et al. 1988). There is an interaction of other proteins with chitin, in a narrow zone (the Schmidt layer) where a relatively large amount of water (about 90%) is present, presumably with hydrophobic functions, an important factor in the stabilization process

(Hillerton and Vincent 1983). Although in the present study no significant morphological changes were observed in the integument of ticks exposed to the ricinoleic acid salt of castor oil, the quantitative protein and chitin profile performed did not show a significant difference in chitin content among females exposed to the bioactive (0.88 ± 0.0 mg/mL) when compared to those in the control group (0.91 ± 0.0 mg/mL), This result corroborated that of Remedio et al. (2014) who, when evaluating the effects of the aqueous extract of neem leaves on *R. sanguineus* ticks and did not find significant variation in cuticle morphometry, however, morphological changes were observed in the integument of exposed ticks.

Also in the present study, the action of the ricinoleic acid salt in castor oil on the morpho-histology of the midgut of engorged females of *R. linnaei* ticks was evident, observed by means of morpho-histochemical alterations, caused by concentrations of 0.78 to 6.25 mg/mL of this compound in the organ. It was found that in the epithelium, the digestive cells were not uniform, and the lumen of the intestine filled with digestive vesicles, often ruptured, in addition to the presence of hematin granules. Similar results were also obtained by Araujo et al. (2014) after exposure of *R. sanguineus* to selamectin, when they observed a cytotoxic effect on different types of cells in the midgut, including degeneration of the intestinal epithelium. Similarly, de Oliveira et al. (2013, 2016) reported the presence of vacuolation in midgut cells and significant changes in digestive cell subtypes in *R. sanguineus* during exposure to fluazuron and dinotefuran.

According to data available in the literature, digestive cells would be considered the main ones present in the epithelium of the midgut of ticks and other living organisms and would be responsible for the production and secretion of digestive enzymes, in addition to the absorption of water and other digested substances (Harrison and Foelix 1999). In the present study, the results showed that although morpho-histological changes occurred in the cells of the midgut of females exposed to the ricinoleic acid salt of castor oil, the participation of digestive enzymes remained unchanged in relation to the results obtained in the negative control group. This finding indicated that this bioactive has only the potential to disrupt the midgut at the cellular level without, however, exerting pressure on enzyme expression as a defense mechanism against xenobiotic/tick. Of the two broad mechanisms involved in the development of resistance, the role of overexpression of metabolic enzymes has already been established in several arthropod species (Hemingway and Ranson 2000; Rosario-Cruz et al. 2009; Bass and Jones 2018).

The histochemical results obtained through the analysis of the midguts of *R. linnaei* females exposed to the bioactive were important since they showed the presence of proteins,

which in the digestive cells of the intestinal epithelium at concentrations of 0.78 to 6.25 mg/mL of the bioactive, were less marked in the cytoplasm, probably due to the structural disorganization of the midgut itself. which probably interfered with their production (mainly in the form of digestive enzymes). The weak labeling observed would probably be, at least in part, due to the presence of the so-called structural proteins, which are produced to be used by the cells themselves, and/or even in part, they could be synthesized and subsequently stored for later use (Harrison and Foelix 1999).

In previous studies carried out by other authors exposing *R. sanguineus* to the ricinoleic acid esters of castor oil, the results showed that as the concentrations of the bioactive decreased, the digestive cells of the midgut suffered an increase in the extent of cytoplasmic vacuolation, which would consequently react weakly to the dyes used. These data corroborated those found for the foregut and midgut of ticks of the species *R. appendiculatus* by Till (1961); Coons et al. (1982), authors who interpreted that the presence of these vacuoles would be the result of the fusion of secretory vesicles that did not release their contents to the lumen of the intestine, which could signal that ticks exposed to the bioactive could have already started the synthesis of defense products (of non-enzymatic origin), which could be affecting the physiology of their intestine.

Conclusion

It was possible verify the salt of ricinoleic acid in castor oil did not cause an acaricidal effect against engorged females of *R. linnaei*. The morpho-histological changes observed as a function of the exposure of the engorged females to the bioactive occurred only on the digestive cells of the females, signaling the occurrence of some type of interference in the production of new digestive cells.

Authors contributions

Yousmel Alemán Gainza: Writing – review & editing, Writing – original draft, Methodology, Formal analysis, Conceptualization. **Bruna Jéssyca Nascimento Horn:** Writing – original draft, Methodology, Formal analysis. **Eduarda Cristina da Vinha:** Writing – original draft, Methodology, Conceptualization. **Kirley Marques Canuto:** Writing – original draft, Software, Chemical analysis. **Maria Izabel Camargo-Mathias:** Writing – review & editing, Visualization, Conceptualization.

Disclosure statement

No potential conflict of interest was reported by the authors.

Funding

We would like to thank the São Paulo Research Foundation (FAPESP) for the financial support (grant Nº 2021/08570–7).

Declaration of using generative artificial intelligence (AI) and AI-assisted technologies.

The authors declare they have not used any of the Generative AI tools in creating this article.

ORCID

Yousmel Alemán Gainza https://orcid.org/0000-0002-8257-9495
Bruna Jéssyca Nascimento Horn https://orcid.org/0000-0002-4364-9614
Eduarda Cristina da Vinha https://orcid.org/0000-0002-6450-8642
Kirley Marques Canuto https://orcid.org/0000-0003-3194-6125
Maria Izabel Camargo-Mathias https://orcid.org/0000-0002-9418-8934

References

Agyei AD, Runham NW, Blackstock N (1992) Histochemical changes in the midgut of two ixodid tick species *Boophilus microplus* and *Rhipicephalus appendiculatus* during digestion of the blood meal. Exp Appl Acarol 13(3): 187-212. https://doi.org/10.1007/bf01194936.

Araujo AM, Oliveira PR, Sampieri BR, Furquim KC, Camargo-Mathias MI (2014) Morphological changes in the midgut of *Rhipicephalus sanguineus* females (Acari: Ixodidae) exposed to selamectin. Curr Top Toxicol 10(1): 87–93.

Bass C, Jones CM (2018) Editorial overview: Pests and resistance: Resistance to pesticides in arthropod crop pests and disease vectors: mechanisms, models and tools. Curr Opin Insect Sci 27: iv–vii. https://doi.org/10.1016/j.cois.2018.04.009.

Becker S, Webster A, Doyle RL, Martins JR, Reck J, Klafke GM (2019) Resistance to deltamethrin, fipronil and ivermectin in the brown dog tick, *Rhipicephalus sanguineus* sensu stricto, Latreille (Acari: Ixodidae). Ticks Tick Borne Dis 10(5): 1046-1050. https://doi.org/10.1016/j.ttbdis.2019.05.015.

Bennett GF (1974) Ovoposition of *Boophilus microplus* (Canestrini) (Acarida: Ixodidae). I. Influence of tick size on egg production. Acarologia 16(1): 52-61.

Biais B, Allwood JW, Deborde C, Xu Y, Maucourt M, Beauvoit B, Dunn WB, Jacob D, Goodacre R, Rolin D, Moing A (2009) ^{1}H NMR, GC-EI-TOFMS, and data set correlation for

fruit metabolomics: Application to spatial metabolite analysis in melon. Anal Chem 81(8): 2884–2894. https://doi.org/10.1021/ac9001996.

Bisht N, Fular A, Saini M, Kumar S, Sankar M, Sharma AK, Ghosh S (2024) Effect of ivermectin, amitraz and fipronil on midgut epithelium and digestive enzyme profile in *Rhipicephalus microplus* ticks (Acari: Ixodidae). Exp Appl Acarol 92(4): 851–870. https://doi.org/10.1007/s10493-024-00913-8.

Bradford MM (1976) A rapid and sensitive method for the quantitation of microgram quantities of protein utilizing the principle of protein-dye binding. Anal Biochem 72: 248–254. https://doi.org/10.1006/abio.1976.9999.

Chevillon C, Koffi BB, Barré N, Durand P, Arnathau C, de Meeûs T (2007) Direct and indirect inferences on parasite mating and gene transmission patterns: pangamy in the cattle tick *Rhipicephalus* (*Boophilus*) *microplus*. Infect Genet Evol 7(2): 298–304. https://doi.org/10.1016/j.meegid.2006.11.007.

Coles TB, Dryden MW (2014) Insecticide/acaricide resistance in fleas and ticks infesting dogs and cats. Parasit Vectors 7: 8. https://doi.org/10.1186/1756-3305-7-8.

Coons LB, Tarnowski B, Ourth DD (1982) *Rhipicephalus sanguinius*: localization of vitellogenin synthesis by immunological methods and electron microscopy. Exp Parasitol 54(3): 331–339. https://doi.org/10.1016/0014-4894(82)90042-x.

Dantas-Torres F, de Sousa-Paula LC, Otranto D (2024) The *Rhipicephalus sanguineus* group: updated list of species, geographical distribution, and vector competence. Parasit Vectors 17(1):540. https://doi.org/10.1186/s13071-024-06572-3.

de la Fuente J, Blouin EF, Manzano-Roman R, Naranjo V, Almazán C, Pérez de la Lastra JM, Zivkovic Z, Jongejan F, Kocan KM (2007) Functional genomic studies of tick cells in response to infection with the cattle pathogen, *Anaplasma marginale*. Genomics 90(6): 712-722. https://doi.org/10.1016/j.ygeno.2007.08.009.

de Meneghi D, Stachurski F, Adakal H (2016) Experiences in Tick Control by Acaricide in the Traditional Cattle Sector in Zambia and Burkina Faso: Possible Environmental and Public Health Implications. Front Public Health 4: 239. https://doi.org/10.3389/fpubh.2016.00239.

de Oliveira PR, Calligaris IB, Roma GC, Bechara GH, Camargo-Mathias MI (2013) Fluazuron-induced morphophysiological changes in the cuticle formation and midgut of *Rhipicephalus sanguineus* nymphs. Parasitol Res 112(1): 45–58. https://doi.org/10.1007/s00436-012-3103-7.

de Oliveira PR, Oliveira Remédio RN, Bechara GH, Anholeto LA, Mathias MI (2016) Dinotefuran-induced morphophysiological changes in the ovaries and midgut of semi-

engorged females *Rhipicephalus sanguineus* ticks. Parasitol Res 115(2): 829–849. https://doi.org/10.1007/s00436-015-4814-3.

Do T, Bui LK, Umemiya-Shirafuji R, Inpankaew T, Hasan T, Zafar I, Ma Z, Hang L, Mohanta UK, Amer M, El-Sayed SAE, Xuan X, Kamyingkird K (2024) The detection of zoonotic microorganisms in *Rhipicephalus sanguineus* (brown dog ticks) from Vietnam and the frequency of tick infestations in owned dogs. Front Vet Sci 11:1435441. https://doi.org/10.3389/fvets.2024.1435441.

Drummond RO, Ernst SE, Trevino JL, Gladney WJ, Graham OH (1973) *Boophilus annulatus* and *B. microplus*: laboratory tests of insecticides. J Econ Entomol 66(1): 130-133. https://doi.org/10.1093/jee/66.1.130.

Ellse L, Wall R (2014) The use of essential oils in veterinary ectoparasite control: A review. Med Vet Entomol 28(3): 233-243. https://doi.org/10.1111/mve.12033.

Gough JM, Kemp DH (1995) Acid phosphatase in midgut digestive cells in partially fed females of the cattle tick *Boophilus microplus*. J Parasitol 81(3): 341-349.

Ha EM, Lee KA, Seo YY, Kim SH, Lim JH, Oh BH, Kim J, Lee WJ (2009) Coordination of multiple dual oxidase-regulatory pathways in responses to commensal and infectious microbes in Drosophila gut. Nat Immunol 10(9): 949-957. https://doi.org/10.1038/ni.1765.

Hackman RH (1982) Structure and function in tick cuticle. Annu Rev Entomol 27: 75-95. https://doi.org/10.1146/annurev.en.27.010182.000451.

Harrison WF, Foelix RF (1999) Microscopic Anatomy of Invertebrates. Volume 8B, Chelicerata Arthropoda. Wiley-Liss Editors. p. 267-514, 1999.

Hemingway J, Ranson H (2000) Insecticide resistance in insect vectors of human disease. Annu Rev Entomol 45: 371–391. https://doi.org/10.1146/annurev.ento.45.1.371.

Hillerton JE, Vincent JFV (1983) Consideration of the importance of hydrophobic interactions in stabilizing insect cuticle. Int J Biol Macromol 5(3): 163–166. https://doi.org/10.1016/0141-8130(83)90032-6.

Junqueira LCU, Junqueira LMMS (1983) Técnicas Básicas de Citologia e Histologia. Livraria e Editora Santos, São Paulo, 1ª ed. 123 p.

Klafke G, Webster A, Dall Agnol B, Pradel E, Silva J, de La Canal LH, Becker M, Osório MF, Mansson M, Barreto R, Scheffer R, Souza UA, Corassini VB, Dos Santos J, Reck J, Martins JR (2017) Multiple resistance to acaricides in field populations of *Rhipicephalus microplus* from Rio Grande do Sul state, Southern Brazil. Ticks Tick Borne Dis 8(1): 73-80. https://doi.org/10.1016/j.ttbdis.2016.09.019.

Kramer KJ, Hopkins T, Schaefer J (1988) Insect cuticle structure and metabolism. In Biotechnology for crop protection. Symposium Series, Vol. 379. American Chemical Society. pp 160-185.

Kunz SE, Kemp DH (1994) Insecticides and acaricides: Resistance and environmental impact. Rev Sci Tech 13(4): 1249-1286. https://doi.org/10.20506/rst.13.4.816.

Laing G, Aragrande M, Canali M, Savic S, De Meneghi D (2018) Control of Cattle Ticks and Tick-Borne Diseases by Acaricide in Southern Province of Zambia: A Retrospective Evaluation of Animal Health Measures According to Current One Health Concepts. Front Public Health 6: 45. https://doi.org/10.3389/fpubh.2018.00045.

Muharsini S, Sukarsih Riding G, Partoutomo S, Hamilton S, Willadsen P, Wijffels G (2000) Identification and characterization of the excreted/secreted serine proteases of larvae of the old-world screwworm fly, *Chrysomya bezziana*. Int J Parasitol 30(6): 705-714. https://doi.org/10.1016/s0020-7519(00)00055-2.

Mulenga A, Misao O, Sugimoto C (2003) Three serine proteinases from midguts of the hard tick *Rhipicephalus appendiculatus*; cDNA cloning and preliminary characterization. Exp Appl Acarol 29(1-2): 151–164. https://doi.org/10.1023/a:1024278402288.

Ntalli N, Koliopoulos G, Giatropoulos A, Menkissoglu-Spiroudi U (2019) Plant secondary metabolites against arthropods of medical importance. Phytochem Rev 18: 1255-1275. https://doi.org/10.1007/s11101-019-09647-7.

Pearse AGE (1985) Histochemistry theoretical and applied. 4 ed., Churchill: Livingstone., p. 614.

Pfister K, Armstrong R (2016) Systemically and cutaneously distributed ectoparasiticides: A review of the efficacy against ticks and fleas on dogs. Parasit Vectors 9(1): 436. https://doi.org/10.1186/s13071-016-1719-7.

Remedio RN, Nunes PH, Anholeto LA, Camargo-Mathias MI (2014) Morphological alterations in the synganglion and integument of *Rhipicephalus sanguineus* ticks exposed to aqueous extracts of neem leaves (*Azadirachta indica* A. JUSS). Microsc Res Tech 77(12): 989–998. https://doi.org/10.1002/jemt.22427.

Reyes J, Ayala-Chavez C, Sharma A, Pham M, Nuss AB, Gulia-Nuss M (2020) Blood digestion by trypsin-like serine proteases in the replete Lyme disease vector tick, Ixodes scapularis. Insects. 11(3): 201. https://doi.org/10.3390/insects11030201.

Rosario-Cruz R, Almazan C, Miller RJ, Dominguez-Garcia DI, Hernandez-Ortiz R, de la Fuente J (2009) Genetic basis and impact of tick acaricide resistance. Front Biosci 14(7): 2657–2665. https://doi.org/10.2741/3403.

Santos HF, Flausino W, Martins TF, Silito IS, Luz HR, Serpa MCA, Labruna MB, Faccini JLH (2024) Ticks (Acari: Ixodidae) and tick-borne agents associated with domestic dogs in an environmental protection area in Brazil, with molecular evidence of *Rhipicephalus linnaei* (Audouin, 1826). Braz J Vet Parasitol 33(3): e008224. https://doi.org/10.1590/S1984-29612024045.

Sojka D, Franta Z, Horn M, Caffrey CR, Mareš M, Kopáček P (2013) New insights into the machinery of blood digestion by ticks. Trends Parasitol 29(6): 276–285. https://doi.org/10.1016/j.pt.2013.04.002.

Sonenshine DE, Hynes,WL (2008) Molecular characterization and related aspects of the innate immune response in ticks. Front Biosci 13: 7046-7063. https://doi.org/10.2741/3209.

Sonenshine DE, Roe RM (2014) Biology of ticks. 2nd edition. Oxford University Press: NY, USA. p. 540.

Taylor D (2006) Innate immunity in ticks: a review. J Acarol Soc Jpn 15(2): 109-127. http://dx.doi.org/10.2300/acari.15.109.

Till WM (1961) A contribution to the anatomy and histology of the brown ear tick *Rhipicephalus appendiculatus*. Mem Entomol Soc Southern Africa 6: 1-124.

Vilela VLR, Feitosa TF, Bezerra RA, Klafke GM, Riet-Correa F (2020) Multiple acaricide-resistant *Rhipicephalus microplus* in the semi-arid region of Paraíba State, Brazil. Ticks Tick Borne Dis 11(4): 101413. https://doi.org/10.1016/j.ttbdis.2020.101413.

Wanzala W (2017) Potential of Traditional Knowledge of Plants in the Management of Arthropods in Livestock Industry with Focus on (Acari) Ticks. Evid Based Complement Alternat Med 2017: 8647919. https://doi.org/10.1155/2017/8647919.