Research Square

Preprints are preliminary reports that have not undergone peer review.
They should not be considered conclusive, used to inform clinical practice,
or referenced by the media as validated information.

Efficacy and safety outcomes of CyberKnife stereotactic radiosurgery for brainstem metastases: a retrospective cohort study

Zhaoyan Wang
First Hospital of Hebei Medical University
Li He
First Hospital of Hebei Medical University
Lei Zhang
First Hospital of Hebei Medical University
Changwen Bo
bochangwen13@163.com
First Hospital of Hebei Medical University

Research Article

Keywords: CyberKnife, Radiosurgery, Brainstem Metastases, Survival Time, Adverse Reactions

Posted Date: November 25th, 2026

DOI: https://doi.org/10.21203/rs.3.rs-11658386/v1

License: This work is licensed under a Creative Commons Attribution 4.0 International License.
Read Full License

Additional Declarations: No competing interests reported.

Efficacy and safety outcomes of CyberKnife stereotactic radiosurgery for brainstem metastases: a retrospective cohort study

Zhaoyan Wang[1,2], Li He[1], Lei Zhang[1,2],Changwen Bo[1*]

1. Department of Oncology, First Hospital of Hebei Medical University, Shijiazhuang, China
2. Department of Internal Medicine, Hebei Medical University

Correspondence： Changwen Bo

E-mail addresses: bochangwen13@163.com

*These authors contributed equally to this work.

Keywords:CyberKnife, Radiosurgery, Brainstem Metastases, Survival Time, Adverse Reactions.

Abstract

Background To investigate the clinical efficacy and safety of CyberKnife (CK) in the treatment of brainstem metastases (BSMs), providing evidence-based references for the standardized treatment of patients and offering a clinical basis for treatment decision-making and outcome assessment.

Methods A retrospective analysis was conducted on the clinical data of 34 patients with BSMs treated with CyberKnife at the First Hospital of Hebei Medical University from January 2021 to November 2025. Parameters including overall survival (OS), local control (LC), and symptom relief rates were recorded. Factors such as gender, age, maximum tumor diameter, Karnofsky Performance Status (KPS) score, and history of whole-brain radiotherapy (WBRT) or systemic therapy were analyzed for their impact on the prognosis of BSM patients treated with CK.

Results For the 34 included patients, the median maximum tumor diameter was 0.875 cm (range: 0.1–3.6 cm). The median total dose ranged from 10.0 to 27.0 Gy, delivered in 1 to 3 fractions. The median biologically effective dose (BED, $\alpha/\beta=10$) was 41.6 Gy (range: 20.0–70.4 Gy). The median equivalent single-fraction prescription dose ($\alpha/\beta=10$) was 16.5 Gy (range: 10.0–22 Gy), and the median maximum equivalent single-fraction dose was 22.0 Gy (range: 13.8–31.4 Gy). The median survival time was 10 months (range: 0.17–47 months). The 1-year and 2-year survival rates were 50% and 26%, respectively.Among the cohort, 11 patients did not complete imaging follow-up at our institution: 6 died shortly after treatment before follow-up could occur, and 5 were followed up at external hospitals (2 refused to provide imaging data,

while 3 showed varying degrees of tumor shrinkage). The remaining 23 patients underwent imaging evaluation at a mean of 8.7 months (range: 1–26 months) post-treatment: 4 achieved complete disappearance of the tumor, 7 showed shrinkage, 5 remained stable, and 7 experienced tumor progression.

Conclusion CyberKnife stereotactic radiosurgery (SRS) and hypofractionated stereotactic radiotherapy (hSRT) provide favorable local control, acceptable survival outcomes, and effective neurological symptom relief in patients with brainstem metastases. Treatment-related toxicities were mild and manageable, with no Grade ≥3 adverse events observed, indicating a favorable short-to-medium-term safety profile. Utilizing fractionated dosing regimens with CyberKnife may help reduce the risk of late radiation-induced brainstem injury. Furthermore, its non-invasive, frameless immobilization ensures high patient comfort and treatment compliance, making it a viable therapeutic option for lesions located in deep or functionally critical brainstem regions.

Introduction

Brain metastasis is a common intracranial complication of solid tumors, most frequently originating from lung cancer, followed by breast cancer, melanoma, colorectal cancer, and renal cell carcinoma. Epidemiological data indicate that the incidence of brain metastases is approximately 2 to 10 times higher than that of primary central nervous system malignancies (such as gliomas). Autopsy studies have confirmed that approximately 10% to 30% of patients with malignant tumors harbor occult or overt brain metastases.Brainstem metastases (BSMs) represent a distinct subtype of brain metastases, specifically referring to metastatic lesions localized within the midbrain, pons, or medulla oblongata. Since the brainstem accounts for only about 3% of total brain volume, its incidence is relatively low, comprising approximately 3% to 5% of all brain metastases(1,2). Currently, the primary therapeutic strategy for brainstem metastases consists of precision radiotherapy combined with systemic pharmacological therapy(3).

Precision radiotherapy relies on high-accuracy localization to effectively eradicate tumor cells while maximizing the preservation of adjacent normal brainstem tissues, thereby balancing therapeutic efficacy with safety. However, the potential risk of radiation-induced reactions remains. Multiple retrospective studies have demonstrated the definitive safety and clinical efficacy of Stereotactic Radiotherapy (SRT) in the management of brainstem metastases(4-6).

Stereotactic radiotherapy modalities include Gamma Knife (GK), CyberKnife (CK), and X-Knife. These systems share common characteristics: high spatial resolution, steep dose gradients, and minimal dose to surrounding normal tissues. Currently, Gamma Knife is widely regarded as the preferred platform for stereotactic treatment of brainstem metastases; however, it requires the application of a rigid stereotactic head frame under local anesthesia, which limits patient mobility, impacts tolerability, and typically restricts the treatment to a single-fraction regimen.In contrast, CyberKnife offers greater therapeutic flexibility and adaptability, particularly for lesions located in anatomically complex and functionally eloquent regions such as the brainstem. Utilizing non-invasive infrared optical tracking and a robotic arm with

real-time correction systems, CyberKnife eliminates the need for rigid frame fixation, significantly improving patient comfort. Furthermore, it enables individualized dose distribution based on the three-dimensional morphology of the tumor, achieving superior target coverage and protection of Organs at Risk (OARs). Notably, CyberKnife supports multisession (hypofractionated) treatment regimens, which help mitigate the risk of radiation injury associated with high single-fraction doses—offering a distinct safety advantage for large-volume brainstem metastases or those in close proximity to critical structures. Consequently, CyberKnife has emerged as an increasingly important clinical option for brainstem metastases.To date, clinical reports regarding CyberKnife for brainstem metastases remain limited, and there is a lack of robust data to substantiate its definitive efficacy and safety profiles. This study aims to retrospectively analyze the clinical data of 34 patients with brainstem metastases treated with CyberKnife at the First Hospital of Hebei Medical University between January 2021 and November 2025, systematically evaluating the short-term outcomes, survival benefits, and safety characteristics of this technology.

1. Materials and Methods

1.1 Patient Characteristics

A total of 34 patients with brainstem metastases who received CyberKnife treatment at the First Hospital of Hebei Medical University between January 2021 and November 2025 were included in this retrospective analysis.This retrospective study adhered to the Declaration of Helsinki and was approved by the Ethics Committee of the First Hospital of Hebei Medical University, with the requirement for informed consent waived due to its retrospective design.

1.2 Inclusion and Exclusion Criteria

Inclusion Criteria:

(1) Diagnosis of brainstem metastasis confirmed by imaging studies.

(2) Primary lesion histologically or pathologically confirmed as a malignant tumor.

(3) Expected survival duration > 3 months.

(4) Availability of complete clinical records.

Exclusion Criteria:

(1)Expected survival duration < 3 months.

(2)Presence of contraindications to radiotherapy.

(3.)Concurrent severe dysfunction of vital organs (e.g., heart, brain, liver, or kidneys).

1.3 Treatment Protocol

1.3.1 Pre-treatment Evaluation

All patients underwent comprehensive pre-treatment assessments, including laboratory tests (complete blood count, liver and kidney function, coagulation profiles, and tumor markers) and performance status evaluation. High-resolution contrast-enhanced MRI (T1-weighted, 1.0 mm slice thickness) of the head was performed for all patients prior to treatment.

1.3.2 CyberKnife Treatment

Radiotherapy was delivered using the 6th-generation CyberKnife system

(Accuray Inc., Sunnyvale, CA, USA). Simulation was performed using a Philips 4D CT simulator, and treatment planning was executed using the Accuray Precision 1.1 treatment planning system (TPS).Patients were immobilized using a custom thermoplastic mask system, and localization was achieved through the Skull Tracking system. The Gross Tumor Volume (GTV) was defined as the enhancement seen on contrast-enhanced MRI. The GTV was delineated following CT or MRI image fusion; critical Organs at Risk (OARs), including the brainstem, lenses, and optic chiasm, were also contoured. The Clinical Target Volume (CTV) was defined as equal to the GTV. The Planning Target Volume (PTV) was generated by adding a 1.6 mm margin to the CTV to account for setup uncertainties.

Dose Constraints for OARs (Single-fraction equivalent dose):Brainstem: Volume receiving over 14 Gy (V14 Gy）<2 cm^3;Maximum Dose（Dmax）<25Gy;LensDmax<2 Gy.The general principle for prescribing the dose to brain metastases was to adjust the dosage based on the maximum diameter of the lesion. Dose limits for normal tissues, including the brainstem, optic nerves, and brain parenchyma, were strictly controlled according to the criteria recommended by Timmerman[7].

The Biologically Effective Dose (BED) for target lesions treated with CyberKnife was calculated using the Linear-Quadratic (LQ) model formula:

$$BED=nd\times[1+d/(\alpha/\beta)]$$

n represents the number of treatment sessions, d represents the dose per fraction (Gy/fraction), and the α/β ratio is standardized at 10 Gy for tumor and acutely responding normal tissues.

1.4 Observation Indicators

1.4.1 Efficacy Assessment

After stereotactic radiosurgery treatment, the clinical efficacy of patients will be evaluated every 1–3 months according to the Response Evaluation Criteria in Solid Tumors version 1.1 (RECIST 1.1). Complete response (CR): All target lesions have disappeared. Partial response (PR): The sum of the longest diameters of target lesions has decreased by at least 30% compared to the baseline status. Progressive disease (PD): The sum of the longest diameters of target lesions has increased by more than 20%, or one or more new lesions have appeared. Stable disease (SD): The condition falls between PR and PD. Symptomatic progression is defined as a worsening of symptoms caused by brainstem lesions compared to the baseline after treatment. Tumor control is defined as CR + PR + SD.

1.4.2 Adverse Reaction Assessment

Radiation adverse events were graded according to the Common Terminology Criteria for Adverse Events version 5.0 (CTCAE v5.0) developed by the National Cancer Institute (NCI).

1.5 Statistical Analysis

Statistical analyses were performed using SPSS 26.0. A P-value of less than 0.05 was considered statistically significant.Survival curves were constructed using the Kaplan-Meier method, with a significance level of $\alpha = 0.05$.

2. Results

2.1 Clinical Baseline Characteristics of Patients

This study included 34 patients with brainstem metastases who underwent radiosurgery at the First Hospital of Hebei Medical University from January 2021 to November 2025. Among them, 16 were male and 18 were female; their ages ranged from 45 to 82 years, with a median age of 60.5 years. Prior to radiosurgery, 6 patients (17.6%) had received whole-brain radiotherapy, and 31 patients (91.2%) had undergone at least one systemic treatment (including chemotherapy, targeted therapy, or immune checkpoint inhibitor therapy). Twenty-three patients (67.6%) had concurrent metastases in other extracranial sites. The median KPS score was 70 (ranging from 40 to 90). The maximum diameter of the brainstem metastases ranged from 0.1 to 3.6 cm, with a median value of 0.875 cm. Among these patients, 28 had ≤2 brainstem metastases, while 6 had multiple brainstem metastases. The primary tumor histopathological types included: lung cancer in 23 cases (67.6%), breast cancer in 3 cases (8.8%), colorectal cancer in 2 cases (5.9%), and ovarian cancer, renal cancer, choriocarcinoma, esophageal cancer, gastric cancer, and cutaneous squamous cell carcinoma each in 1 case (all at 2.9%). Before treatment, 25 patients (73.5%) presented with neurological symptoms, including dizziness, headache, blurred vision, hemiparesis, diplopia, ataxia, and seizures. (Table 1)

Table 1: Baseline Characteristics of 34 Patients with Brainstem Metastases

Characteristics	N=34(%)
Gender	
Male	16（47.1）
Female	18（52.9）
Age(years)	60.5（45-82）
Median KPS score	70（40-90）
No. of brainstem metastases	
Single(≤2)	28（82.4）
Multiple (≥3)	6（17.6）
No. of brain metastases	
Single (≤2)	6（17.6）
Multiple (≥3)	28（82.4）
Prior whole-brain radiotherapy	
Yes	6（17.6）
No	28（82.4）
Systemic therapy history	
Yes	31（91.2）
No	3（8.8）
Primary tumor site	
Lung cancer	23（67.6）
Breast cancer	3（8.8）
Rectal cancer	2（5.9）
Ovarian cancer	1（2.9）

Renal cell carcinoma	1（2.9）
Choriocarcinoma	1（2.9）
Esophageal cancer	1（2.9）
Gastric cancer	1（2.9）
Cutaneous squamous cell carcinoma	1（2.9）
Extracranial metastasis	
Yes	23（67.6）
No	11（32.4）

Table 2. Dosimetric Characteristics of 34 Patients with Brainstem Metastases

Characteristics	Median (range)
Maximum diameter of brainstem metastasis	0.875（0.1-3.6）
Median total dose	17（10-27）Gy/1-3fractions
Median dose per fraction	15（6-22）Gy
BED10	41.6(20-70.4)

2.1 Dosimetry Results

Table 2 summarizes the radiation therapy dosimetric parameters for 34 patients. The median maximum tumor diameter was 0.875 (0.1–3.6) cm, and the total irradiation dose ranged from 10.0 to 27.0 Gy,delivered in 1 to 3 fractions.The median biologically effective dose (BED) ($\alpha/\beta = 10$) was 41.6 (range, 20.0-70.4) Gy. The median single-fraction equivalent prescribed dose ($\alpha/\beta = 10$) was 16.5 (range, 10.0-22) Gy. The median maximum single-fraction equivalent dose was 22.0 (range, 13.8-31.4) Gy, and the median isodose line coverage was 72.0% (range, 70.0%-85.0%).

2.2 Follow-up Status

As of November 2025, the median follow-up time was 20.5 (10–47) months; 10 patients were alive, and 24 patients had died.

2.3 Local Control Effect

As of the follow-up period, 11 patients who completed treatment did not undergo imaging follow-up evaluation at our hospital: among them, 6 had short survival times and thus were unable to complete the follow-up examination; the remaining 5 were followed up at other hospitals, of which 2 refused to provide follow-up information, while in the other 3, imaging studies confirmed that the lesions had achieved varying degrees of response—either partial response or better, or stable disease (SD), partial response (PR), or complete response (CR). The remaining 23 patients underwent imaging follow-up evaluation at our hospital: among them, 4 showed tumor disappearance, 7 experienced tumor shrinkage, 5 maintained stable disease, and 7 exhibited tumor growth.

One patient with renal cell carcinoma and brain metastases (Figure 1A) underwent MRI T1-enhanced scanning prior to treatment, which revealed a tumor with a maximum diameter of 1.46 cm. The patient received stereotactic radiosurgery using the CyberKnife, with a total dose of 27 Gy delivered in three fractions. A

follow-up examination four months after treatment showed local partial response (PR) (Figure 1B). The patient died nine months after irradiation; the cause of death remains unknown.

Another patient with a medullary-pontine dorsal metastatic tumor from gastric cancer (Figure 1C) showed a maximum tumor diameter of 1.65 cm on pre-treatment MRI T1-enhanced imaging. The patient underwent stereotactic radiosurgery using the CyberKnife, receiving a total dose of 18 Gy in a single fraction. Follow-up imaging two months after treatment revealed local complete response (CR) (Figure 1D). However, one year and two months after CyberKnife treatment, the patient died due to bleeding from the primary lesion.

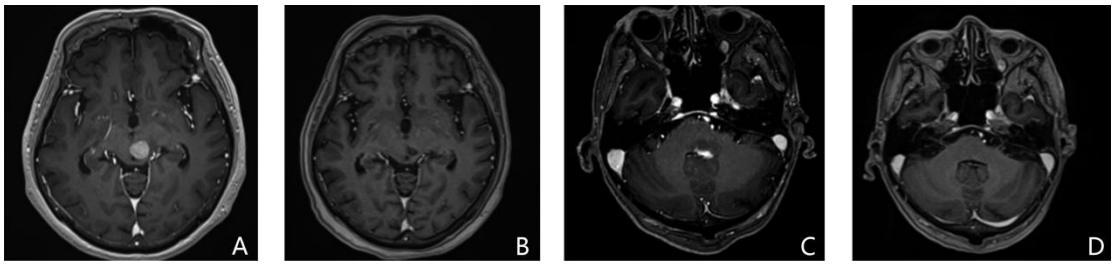

Figure 1. Contrast-enhanced T1-weighted MRI of patients with brainstem metastases before and after stereotactic radiosurgery (SRS). **(A)** Baseline MRI showing a left midbrain metastasis in a patient with renal cell carcinoma. **(B)** Partial response observed at 4 months after treatment. **(C)** Baseline MRI showing a dorsal medullo-pontine metastasis in a patient with gastric cancer. **(D)** Complete response observed at 3 months after treatment.

2.4 Survival Status

The median overall survival (OS) for all patients in the cohort was 10 months (95% CI: 0.17–47.0).The Kaplan-Meier survival curve is shown in Figure 2. The 1-year and 2-year overall survival (OS) rates were 50.0% and 26.0%, respectively. Among the 24 deceased patients, the cause of death was unknown in 12 cases; 2 died from bleeding at the primary tumor site; 7 died from tumor progression at extracranial sites; 2 died from cardiac events; and 1 died from septic shock.

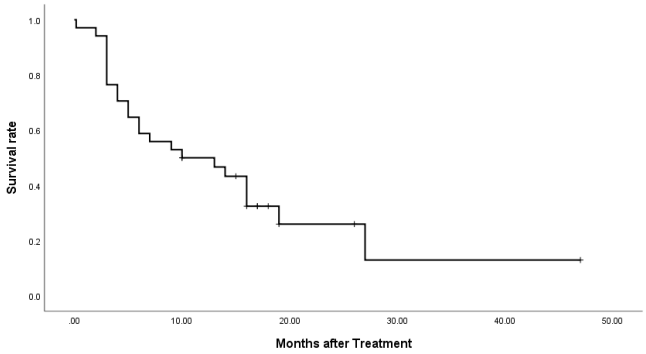

Figure 2: Kaplan-Meier Overall Survival (OS) Curve for the Entire Patient Cohort

2.5 Univariate and Multivariate Analysis

Univariate analysis revealed that KPS score, the presence or absence of extracranial metastasis, the maximum diameter of brainstem metastases, and biologically effective dose (BED10) were all significantly associated with overall patient survival ($P < 0.05$; Figure 3). However, gender, age, number of intracranial metastatic lesions, histological type of the primary tumor, and prior.Factors such as acceptance of WBRT and systemic treatment did not show a significant association with survival ($P > 0.05$). When the above four variables with statistical significance were incorporated into a multivariate Cox proportional hazards model, the results indicated that extracranial metastasis (HR = 2.5, 95% CI: 0.9–6.8, P = 0.079) and larger brainstem metastases (HR = 2.2, 95% CI: 0.8–6.1, P = 0.121) both showed a trend toward increased mortality risk, though neither reached statistical significance. On the other hand, a KPS score ≥ 70 (HR = 0.4, 95% CI: 0.1–1.3, P = 0.112) and a higher BED10 (HR = 0.5, 95% CI: 0.2–1.4, P = 0.198) exhibited a protective effect, but neither reached statistical significance either.

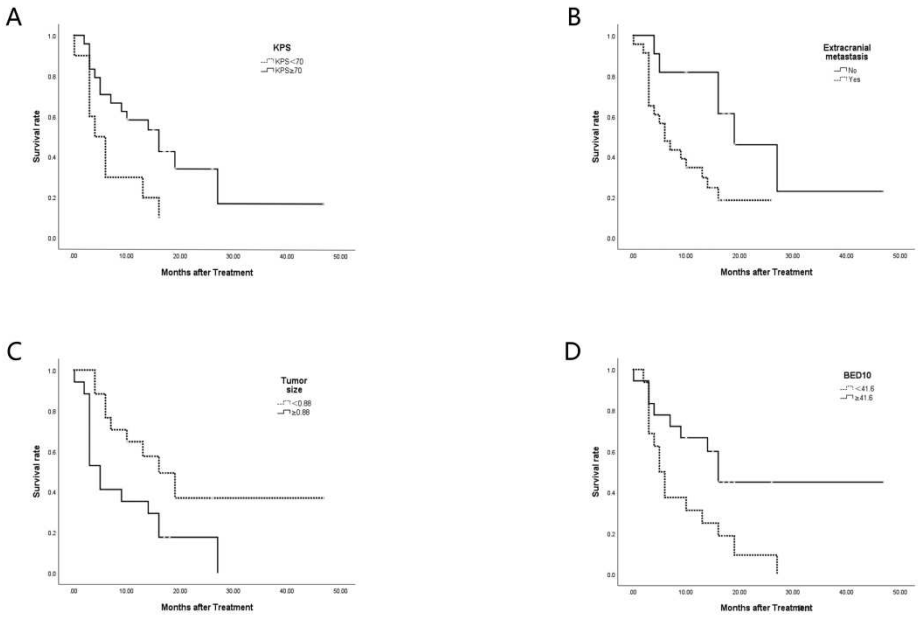

Figure 3: Univariate Survival Analysis Results for the Entire Patient Cohort

A: Survival curves for two groups with KPS scores <70 and ≥70; median survival was significantly prolonged in the group with KPS ≥70 ($p<0.05$).

B: Survival curves for the two groups—those with and without extracranial metastasis; patients without extracranial metastasis showed a significant survival advantage ($p < 0.05$).

C: Survival curves for the two groups—those with brainstem metastases whose largest diameter is below the threshold versus those above the threshold. Patients with smaller lesions had significantly better survival than those with larger lesions ($p < 0.05$).

D: Survival curves for the two groups with BED10 < 41.6 Gy and ≥41.6 Gy; survival was significantly improved in the high-BED10 group ($p < 0.05$).

Table 3. Prognostic Factors for Survival in Patients with Brainstem Metastases Treated with CyberKnife Radiosurgery

Variable	Univariate Analysis		Multivariate Analysis	
	HR(95%CI)	P	HR (95%CI)	P
Gender	0.045	0.832		
Age (≥80 vs <80 years)	1.201	0.273		
KPS（≥70 vs ＜70)	4.193	0.041	0.63(0.24－1.65)	0.346
No. of brainstem metastases (single vs multiple)	1.446	0.229		
No. of brain metastases (single vs multiple)	1.13	0.288		
Prior whole-brain radiotherapy (yes vs no)	1.015	0.314		
Systemic therapy history (yes vs no)	0.018	0.892		
Primary tumor site (lung cancer vs others)	0.189	0.664		
Extracranial metastasis (yes vs no)	5.253	0.022	2.48(0.79－7.74)	0.118
Maximum diameter of brainstem metastasis (≥0.875 vs <0.875 cm)	4.641	0.031	2.18(0.86－5.54)	0.101
BED_{10} (≥41.6 vs <41.6 Gy)	4.00	0.046	0.71(0.28－1.78)	0.458

2.6 Adverse Reactions

All 34 patients successfully completed CyberKnife treatment. A total of 5 treatment-related adverse reactions occurred, all classified as Grade 1 or 2 according to the CTCAE v5.0 criteria, with the main symptoms including headache, nausea, and fatigue. One patient developed radiation-induced bone marrow suppression, which resolved after symptomatic supportive treatment. Another patient experienced new-onset hypertension following treatment, which was considered related to radiation-induced cerebral edema and secondary intracranial hypertension; the symptoms improved after treatment with mannitol combined with dexamethasone. No acute or late toxicities of Grade 3 or higher were observed in the entire cohort, suggesting that CyberKnife treatment has a favorable safety profile.

2.7 Symptom Relief Rate

Before treatment, 25 out of 34 patients exhibited neurological symptoms, including dizziness/headache.Blurred vision, hemiplegia, diplopia, ataxia, and epileptic seizures, among others; among these cases, 17 showed varying degrees of improvement in the above symptoms after stereotactic radiosurgery treatment, with an overall symptom relief rate of 68.0%

Discussion

Between 20% and 40% of patients with malignant tumors develop brain metastases during the course of their disease. The brainstem has a finely structured anatomy, highly complex and critical functions, and poses an extremely high surgical risk for resection. The vast majority of brainstem metastases cannot be safely removed due to their deep-seated location, proximity to crucial nuclei and neural tracts. Moreover, most chemotherapeutic agents struggle to cross the blood-brain barrier, limiting the efficacy of systemic chemotherapy. Furthermore, whole-brain radiotherapy (WBRT) exhibits low tolerance toward brainstem tissues and readily induces radiation-induced brainstem damage, further restricting its clinical application. The brainstem is densely populated with Life-sustaining centers (such as the nuclei regulating respiration and heart rate) and important ascending/descending conduction pathways,once metastasis occurs, severe neurological deficits such as diplopia, dysarthria, dysphagia, ataxia, limb paralysis, and even altered consciousness often develop rapidly, significantly impairing the patient's quality of life. Among patients with brainstem metastases who receive no active intervention, the median survival time is less than 6 months(8).Before the widespread adoption of stereotactic radiosurgery (SRS), whole-brain radiation therapy (WBRT) was the only available palliative radiotherapy option[9]. However, previous studies have shown that patients with brainstem metastases treated with WBRT had a median overall survival of only 2 months—a subgroup with the worst prognosis—and no significant survival benefit or improvement in quality of life was observed(9). By contrast, the introduction of SRS technology has markedly improved the survival outcomes for patients with brain metastases(10). A comparative study confirmed that the median survival time in the group receiving combined WBRT and SRS (6.5 months) was significantly longer than that in the group treated with WBRT alone (4.9 months) ($P = 0.04$)(11).According to the 2025 NCCN Guidelines, the treatment principles for brain metastases are centered on "prolonging survival, protecting neurological function, and maintaining quality of life." For solitary lesions that are large in size (>3–4 cm) or exhibit significant mass effect and are amenable to surgical resection, maximal safe resection is recommended. For patients with ≤4 metastatic lesions and a total lesion volume <15 mL, SRS is the preferred treatment modality. If the number of lesions ranges from 5 to 10 but the total volume remains below 15 mL, SRS may also be considered after comprehensive multidisciplinary team (MDT) evaluation. For patients who have previously undergone WBRT and experienced local recurrence, SRS can still be cautiously selected as salvage therapy, provided that cumulative radiation dose is rigorously assessed and safety is ensured. Current evidence indicates that for patients with single or isolated brain metastases (BM), initial treatment with SRS can achieve local control rates and long-term intracranial progression-free survival comparable to those achieved with surgical resection (SR); there was no statistically significant difference in overall survival (OS) between the SR and SRS groups(12). Stereotactic radiotherapy encompasses techniques such as Gamma Knife, CyberKnife, and X-Knife; The term "radiosurgery" refers to a closed-skull surgical procedure that employs stereotactic techniques to deliver a single high-dose radiation fraction

precisely to an intracranial target, thereby ablating the lesion without craniotomy(13).Among these, the Gamma Knife is a highly precise radiotherapy platform that integrates modern computer navigation, stereotactic localization, and neurosurgical principles. Based on the principle of stereogeometric targeting, it uses a titanium alloy head frame rigidly fixed to the patient's skull (anchored by cranial screws) to establish a stable and reproducible three-dimensional coordinate system, enabling submillimeter-level (error ≤ ±0.1 mm) target localization and beam focusing. During treatment, gamma rays emitted from 201 cobalt-60 sources converge from multiple directions onto the target site, delivering a single high-dose irradiation that induces focal necrosis or functional inactivation of the lesion tissue while maximizing protection of the surrounding normal brain tissue. Several clinical studies have demonstrated that Gamma Knife therapy can achieve a 1-year local control rate of 80%–90% for brainstem metastases, with a median overall survival ranging from 6 to 17 months(5,8,14,15). However, the head-frame fixation procedure causes significant discomfort, limiting its broader clinical applications beyond single-session treatments. In particular, for larger lesions, a single high-dose irradiation may increase the risk of radiation-induced damage; thus, the clinical application of the Gamma Knife is primarily restricted to smaller lesions.In 2020, Gueliz Acker et al. reported a study on radiosurgery treatment for 97 elderly patients with brain metastases, which showed an overall survival rate of 23% at 12 months following SRS(16). A retrospective study conducted by Wendy Hara et al. in 2009 included patients with brain metastases from renal cell carcinoma or melanoma; the median survival after SRS was 8.3 months, with 6-month and 12-month survival rates of 57% and 37%(17). In 2015, Keisuke Tamari et al. retrospectively analyzed 67 lung cancer patients with brain metastases (totaling 109 lesions) who underwent radiosurgery between 1998 and 2011: Among these, 79 lesions received single-fraction SRS (median dose, 24 Gy), while 30 lesions received fractionated stereotactic radiotherapy (FSRT; median dose, 30 Gy in 3 fractions). The median overall survival for the entire cohort was 13.1 months, with 1-year and 3-year overall survival rates of 54.8% and 25.9%(18).

Previous reports on the survival prognosis of brainstem metastases treated with SRS/SRT have shown considerable heterogeneity: an early study on large-volume brainstem metastases treated with FSRT (as either initial or salvage therapy) reported a median overall survival of 14.7 months, though no 1-year survival data were provided（19）. Tadashi Sugimoto et al. reported that patients with brainstem metastases treated with FSRT had a 1-year survival rate of 35%, with a median overall survival of 9 months（20）. A 2021 meta-analysis including 27 studies and a total of 1,254 patients showed that the 1-year overall survival rate following SRS/SRT for brainstem metastases was 33%, while among the 22 studies providing follow-up data (n = 959), the 2-year survival rate was 13%（6）. In this study, we employed a high-precision stereotactic radiotherapy platform to deliver individualized treatment to patients with brainstem metastases. The results showed that the 1-year and 2-year overall survival rates after treatment were 50% and 26%, respectively, with a median overall survival of 10 months. These survival outcomes are superior to most previous historical reports, and the underlying reasons may include: (1) the technical

advantages of our center's equipment in terms of image-guided precision, dose distribution optimization algorithms, and personalized treatment planning; (2) the rapid advancement of systemic therapies—such as molecular targeted therapies and immune checkpoint inhibitors—in recent years, which have provided more effective systemic control options for patients with brainstem metastases; (3) the increased prevalence of early neuroimaging screening, enabling earlier detection and more timely intervention for small brainstem metastatic lesions. Currently, high-quality evidence from randomized controlled trials on radiosurgery for brainstem metastases remains relatively limited; however, existing research findings are encouraging. In 2019, Tianjin Medical University Cancer Hospital reported that 49 patients with brainstem metastases treated with radiosurgery had a median survival time of 14 months (range: 1–43 months), with 1-year and 2-year survival rates of 55.1% and 28.6%（**Error! Reference source not found.**）, a result highly consistent with those of our study. In summary, the survival times and local control rates observed in this study were comparable to or better than those reported in previous studies. However, due to the small sample size and retrospective data collection, this study has certain methodological limitations. We will continue to expand the sample size in future studies,and conduct more detailed subgroup analyses to further validate and deepen the study findings.

In this study, univariate regression analysis revealed that factors influencing survival time after radiosurgical treatment in patients with brainstem metastases include the KPS score, the presence or absence of extracranial metastases, the maximum diameter of brainstem metastases, and the biologically effective dose (BED10). Although multivariate regression analysis in this study did not identify total dose, single-fraction dose, or prior whole-brain radiotherapy as significantly associated with patient survival during stereotactic radiosurgery, Kaplan–Meier survival curves suggest that patients receiving higher radiation doses and those who had not previously undergone WBRT exhibited better survival outcomes. Studies by Peterson et al.(21) and Lorenzoni et al.(23) both indicated that, compared to stereotactic radiosurgery alone, combined stereotactic radiosurgery and WBRT may lead to poorer prognosis in patients with brainstem metastases. On the other hand, some studies have found no significant difference in survival between the two approaches; however, to date, there is still a lack of high-quality evidence supporting the notion that combined therapy offers superior efficacy over stereotactic radiosurgery alone. Lin et al. conducted a retrospective analysis of 48 brainstem metastatic lesions in 45 patients, and univariate analysis showed a trend toward improved local control rates in patients receiving marginal doses greater than 14 Gy ($P = 0.059$), suggesting that increasing the dose might confer clinical benefits(24). This study also observed a similar trend. Therefore, there is an urgent need for large-scale, prospective, multicenter randomized controlled trials to systematically explore and establish the optimal dose regimen for stereotactic radiosurgery in the treatment of brainstem metastases, thereby striking a balance between maximizing therapeutic efficacy and minimizing toxicity. Furthermore, previous studies have confirmed that the status of primary tumor control, RPA grading, and history of prior

WBRT are all important prognostic factors affecting survival after stereotactic radiosurgery in patients with brainstem metastases(**Error! Reference source not found.**).

In terms of safety, radiosurgical treatment for brainstem metastases has a relatively low incidence of adverse reactions (1%–12%)(26). Given that the brainstem is a highly radiation-sensitive "high-risk serial organ," it is particularly sensitive to single high-dose irradiation. Currently, there is no international consensus on the optimal tumor margin dose for SRS treatment. Due to the influence of various confounding factors—including tumor volume, histopathological type, and prior radiotherapy history—the quantitative relationship between margin dose and local control rate as well as adverse reaction incidence remains difficult to define precisely(27). Moreover, the specific radiosurgical technology platform employed—such as Gamma Knife or LINAC-based SRS—can also affect the dose gradient distribution and attenuation characteristics, thereby influencing the actual dose delivered to the tumor margin. Although some studies have reported a significant association between higher margin doses, smaller tumor volumes, and longer survival, this strategy may carry an increased risk of severe toxicities such as radiation necrosis, making it challenging to establish a robust trade-off model among "margin dose, local control, and toxicity"(28). Lin et al. used LINAC-SRS to treat 48 brainstem metastases (median volume: 0.40 mL), with a median margin dose of 14 Gy (range: 10–17 Gy, covering the 90% isodose line). At 6 months and 1 year, the local control rates were 92% and 88%, respectively, and the median overall survival was 11.6 months. Among these patients, those receiving a margin dose greater than 14 Gy showed a trend toward improved local control ($P = 0.059$); however, the 17-Gy group experienced symptomatic radiation necrosis. Based on these findings, the authors suggested that for lesions smaller than 0.4 mL, a margin dose of 14–16 Gy could be considered a “dose window” that balances safety and efficacy. It should be noted, however, that this study reported only a 4.7% incidence of grade ≥3 severe complications within 2 years and lacked long-term follow-up data. Furthermore, the number of cases with tumor volumes greater than 0.4 mL or margin doses exceeding 16 Gy was extremely limited, precluding any definitive conclusions about safety thresholds at larger tumor volumes or higher doses(24). In this study, dose constraints primarily based on the established tolerance limits for normal brainstem tissue, the actual dose received by tumors often significantly exceeds these limits. Moreover, given the relatively short overall survival of patients with brainstem metastases, the occurrence of late tumor recurrence and delayed radiation-induced damage may be masked, leading to a "survival-time bias"—a risk of underestimating toxicity because patients die before the time window for radiation-induced damage becomes apparent. Therefore, how to scientifically balance antitumor efficacy against long-term neurotoxicity within the limited survival period and precisely define the optimal dose for SRS treatment of brainstem metastases still requires further in-depth exploration and prospective validation.

In this study, the incidence of treatment-related adverse reactions was generally consistent with that reported in previous literature. None of the enrolled patients experienced adverse events of Grade 3 or higher according to the CTCAE criteria; only 5 cases (14.7%) exhibited mild adverse reactions of Grades 1–2, primarily manifesting as headache, nausea, and fatigue. All these symptoms were completely relieved after symptomatic treatments such as dehydration and intracranial pressure reduction. Chen et al. conducted a systematic review of 31 single-center retrospective studies (involving a total of 1,421 patients) and reported that the incidence of symptomatic adverse events following stereotactic radiosurgery for the brainstem was 5.6%, while the incidence of severe toxicities of Grades 3–5 was 2.4%(6). Similarly, Koyfman et al. did not observe any Grade 3 or 4 toxicities in their cohort; only 3 patients experienced transient weakness, ataxia, or needle-track hemorrhage of Grades 1–2(15). In summary, CyberKnife treatment for brainstem metastases demonstrates good safety and tolerability.

In summary, both single-fraction stereotactic radiosurgery (SRS) and fractionated stereotactic radiotherapy (FSRT) can provide significant survival benefits and symptom relief for patients with brainstem metastases. Among these, the CyberKnife system—owing to its non-invasive nature, frameless immobilization, and flexible dose fractionation capabilities—demonstrates potential advantages in reducing the risk of radiation-induced necrosis and exhibits an overall favorable safety profile. Stereotactic radiotherapy generally has excellent tolerability and high treatment completion rates; moreover, since the CyberKnife does not require head fixation with a frame, it enjoys higher patient compliance and acceptance.Rigorously designed prospective, multicenter, randomized controlled trials are urgently warranted to systematically evaluate the long-term efficacy, safety, and quality-of-life outcomes of CyberKnife treatment for brainstem metastases across different fractionation regimens, thereby providing high-level evidence to inform clinical practice.

Several limitations of the present study should be acknowledged. First, this was a single-center retrospective analysis with a relatively small sample size (n = 34), which inherently introduces selection bias and limits the statistical power of multivariate Cox regression analyses to detect independent prognostic factors. Second, the cohort exhibited substantial clinical heterogeneity in terms of primary tumor histologies, extracranial disease burden, prior cranial irradiation, and concurrent or subsequent systemic therapies (such as targeted agents and immune checkpoint inhibitors), all of which may have confounded overall survival outcomes. Third, post-treatment neuroimaging follow-up at our institution was unavailable for 11 patients (6 due to early mortality and 5 followed up externally, including 2 without accessible imaging records), which may affect the precision of long-term local control estimates. Finally, because the median overall survival of patients with brainstem metastases remains relatively short (10.0 months in this cohort), late-onset radiation-induced brainstem necrosis may have been underestimated due to competing mortality risks (survival-time bias). Therefore, prospective, multicenter studies with larger cohorts and standardized longitudinal neuroimaging protocols are needed to

confirm these findings.

Declarations

Abbreviations

BED: biologically effective dose; BSMs: brainstem metastases; CK: CyberKnife; CR: complete response; CTV: clinical target volume; CTCAE: Common Terminology Criteria for Adverse Events; FSRT: fractionated stereotactic radiotherapy; GK: Gamma Knife; GTV: gross tumor volume; KPS: Karnofsky Performance Status; LC: local control; LQ: linear-quadratic; OARs: organs at risk; OS: overall survival; PD: progressive disease; PR: partial response; PTV: planning target volume; RECIST: Response Evaluation Criteria in Solid Tumors; SD: stable disease; SRS: stereotactic radiosurgery; WBRT: whole-brain radiotherapy

Ethics approval and consent to participate:

This study was conducted in accordance with the ethical principles of the Declaration of Helsinki and was approved by the Ethics Committee of the First Hospital of Hebei Medical University. Due to the retrospective nature of the study and the use of anonymized clinical data, the requirement for written informed consent to participate was waived by the Ethics Committee of the First Hospital of Hebei Medical University.

Consent for publication

Written informed consent for publication of anonymized clinical details and radiological images was obtained from the patients or their legal representatives.

Availability of data and materials

The datasets generated and/or analyzed during the current study are not publicly available due to patient privacy protections, but are available from the corresponding author on reasonable request.

Competing Interests

The authors declare that they have no competing interests.

Funding

This research received no specific grant from any funding agency in the public, commercial, or not-for-profit sectors.

Authors' contributions:
ZW and LH contributed equally to this work. ZW and CB conceived and designed the study. LH and LZ collected and analyzed the clinical data. ZW drafted the manuscript. CB critically revised the manuscript for important intellectual content. All authors read and approved the final manuscript.

Acknowledgements:
Not applicable.

References

1.Brain metastases: epidemiology. In: *Handbook of Clinical Neurology*. Vol 149. Elsevier; 2018:27-42. doi:10.1016/B978-0-12-811161-1.00002-5

2.Sacks P, Rahman M. Epidemiology of Brain Metastases. *Neurosurgery Clinics of North America*. 2020;31(4):481-488. doi:10.1016/j.nec.2020.06.001

3.Wang Z, Chen H, Chen Q, et al. Efficacy and safety of a “sandwich therapy” based on staged stereotactic radiosurgery and bevacizumab for large brainstem metastases. *Clinical Neurology and Neurosurgery*. 2023;233:107911. doi:10.1016/j.clineuro.2023.107911

4.Patel A, Dong T, Ansari S, et al. Toxicity of Radiosurgery for Brainstem Metastases. *World Neurosurgery*. 2018;119:e757-e764. doi:10.1016/j.wneu.2018.07.263

5.Huang CF, Kondziolka D, Flickinger JC, Lunsford LD. Stereotactic radiosurgery for brainstem metastases. *J Neurosurg*. 1999;91(4):563-568. doi:10.3171/jns.1999.91.4.0563

6.Chen WC, Baal UH, Baal JD, et al. Efficacy and Safety of Stereotactic Radiosurgery for Brainstem Metastases: A Systematic Review and Meta-analysis. *JAMA Oncol*. 2021;7(7):1033-1040. doi:10.1001/jamaoncol.2021.1262

7.Timmerman R. A Story of Hypofractionation and the Table on the Wall. *Int J Radiat Oncol Biol Phys*. 2022;112(1):4-21. doi:10.1016/j.ijrobp.2021.09.027

8.Patel A, Mohammadi H, Dong T, et al. Brainstem metastases treated with Gamma Knife stereotactic radiosurgery: the Indiana University Health experience. *CNS Oncol*. 2018;7(1):15-23. doi:10.2217/cns-2017-0029

9.Bhatnagar AK, Flickinger JC, Kondziolka D, Lunsford LD. Stereotactic radiosurgery for four or more intracranial metastases. *Int J Radiat Oncol Biol Phys*. 2006;64(3):898-903. doi:10.1016/j.ijrobp.2005.08.035

10.Rosenfelder N, Brada M. Integrated treatment of brain metastases. *Curr Opin Oncol*. 2019;31(6):501-507. doi:10.1097/CCO.0000000000000573

11.Patil CG, Pricola K, Sarmiento JM, Garg SK, Bryant A, Black KL. Whole brain radiation therapy (WBRT) alone versus WBRT and radiosurgery for the treatment of brain metastases. *Cochrane Database Syst Rev*. 2012;2012(9):CD006121. doi:10.1002/14651858.CD006121.pub3

12.Liu Z, He S, Li L. Comparison of Surgical Resection and Stereotactic Radiosurgery in the Initial Treatment of Brain Metastasis. *Stereotact Funct Neurosurg*. 2020;98(6):404-415. doi:10.1159/000509319

13.Terahara A. [Gamma knife]. *Gan To Kagaku Ryoho*. 1993;20(14):2133-2142.

14.Yen CP, Sheehan J, Patterson G, Steiner L. Gamma knife surgery for metastatic brainstem tumors. *J Neurosurg*. 2006;105(2):213-219. doi:10.3171/jns.2006.105.2.213

15.Koyfman SA, Tendulkar RD, Chao ST, et al. Stereotactic Radiosurgery for Single Brainstem Metastases: The Cleveland Clinic Experience. *International Journal of Radiation Oncology, Biology, Physics*. 2010;78(2):409-414. doi:10.1016/j.ijrobp.2009.07.1750

16.Efficacy and safety of CyberKnife radiosurgery in elderly patients with brain metastases: a retrospective clinical evaluation - PubMed. Accessed January 23, 2026. https://pubmed.ncbi.nlm.nih.gov/32993672/

17.Hara W, Tran P, Li G, et al. Cyberknife for brain metastases of malignant melanoma and renal cell carcinoma. *Neurosurgery*. 2009;64(2 Suppl):A26-32. doi:10.1227/01.NEU.0000339118.55334.EA

18.Tamari K, Suzuki O, Hashimoto N, et al. Treatment outcomes using CyberKnife for brain metastases from lung cancer. *J Radiat Res*. 2015;56(1):151-158. doi:10.1093/jrr/rru092

19.Chatzikonstantinou G, Wolff R, Tselis N. Fractionated stereotactic radiotherapy as a primary or salvage treatment for large brainstem metastasis. *J Cancer Res Ther*. 2022;18(6):1604-1609. doi:10.4103/jcrt.jcrt_426_21

20.Sugimoto T, Matsuda R, Tamamoto T, et al. Linac-Based Fractionated Stereotactic Radiotherapy with a Micro-Multileaf Collimator for Brainstem Metastasis. *World Neurosurg*. 2019;132:e680-e686. doi:10.1016/j.wneu.2019.08.049

21.Liu Q, Wang XG, Yin Q, Dong Y, Li FT, Yuan ZY. Clinical efficacy and prognostic factors of CyberKnife for brainstem metastases. Chin J Clin Oncol. 2019;46(19):1003-7. [Article in Chinese]

22.Peterson HE, Larson EW, Fairbanks RK, et al. Gamma knife treatment of brainstem metastases. *Int J Mol Sci*. 2014;15(6):9748-9761. doi:10.3390/ijms15069748

23.Lorenzoni JG, Devriendt D, Massager N, et al. Brain stem metastases treated with radiosurgery: prognostic factors of survival and life expectancy estimation. *Surg Neurol*. 2009;71(2):188-195; discussion 195, 195-196. doi:10.1016/j.surneu.2008.01.029

24.Lin CS, Selch MT, Lee SP, et al. Accelerator-based stereotactic radiosurgery for brainstem metastases. *Neurosurgery*. 2012;70(4):953-958; discussion 958. doi:10.1227/NEU.0b013e31823c40fe

25.Aizer AA, Tanguturi SK, Shi DD, et al. Stereotactic Radiosurgery in Patients With Small Cell Lung Cancer and 1-10 Brain Metastases: A Multi-Institutional, Phase II, Prospective Clinical Trial. *J Clin Oncol*. 2025;43(27):2986-2997. doi:10.1200/JCO-25-00056

26.Donovan EK, Parpia S, Greenspoon JN. Incidence of radionecrosis in single-fraction radiosurgery compared with fractionated radiotherapy in the treatment of brain metastasis. *Curr Oncol*. 2019;26(3):e328-e333. doi:10.3747/co.26.4749

27.Vogelbaum MA, Angelov L, Lee SY, Li L, Barnett GH, Suh JH. Local control of brain metastases by stereotactic radiosurgery in relation to dose to the tumor margin. *J Neurosurg*. 2006;104(6):907-912. doi:10.3171/jns.2006.104.6.907

28.Hatiboglu MA, Chang EL, Suki D, Sawaya R, Wildrick DM, Weinberg JS. Outcomes and prognostic factors for patients with brainstem metastases undergoing stereotactic radiosurgery. *Neurosurgery*. 2011;69(4):796-806; discussion 806. doi:10.1227/NEU.0b013e31821d31de