Research Square

Preprints are preliminary reports that have not undergone peer review.
They should not be considered conclusive, used to inform clinical practice,
or referenced by the media as validated information.

Uncommon Manifestation of Extraskeletal Bone Formation Associated with Dystocia in a Greater Rhea (Rhea americana)

João Ricardo Sales Rocha Filgueiras
ricardofilgueiras@edu.unifor.br

Universidade de Fortaleza
Maria Eduarda Rocha Almeida
Universidade de Fortaleza
Juliana Sousa Benevides
Unichristus
Fernanda Menezes de Oliveira e Silva
Universidade de Fortaleza
Karen Emanuelly Pinheiro Gomes
Fortaleza Zoobotanical Park
Fábio Ranyeri Nunes Rodrigues
IFVET Diagnostic Pathology Laboratory
Belise Maria Oliveira Bezerra
Universidade de Fortaleza
Raqueli Teresinha França
Universidade Federal de Pelotas

Case Report

Keywords: Avian medicine, Heterotopic ossification, Ornithopathology, Ratite, Zoo medicine

Posted Date: November 25th, 2026

DOI: https://doi.org/10.21203/rs.3.rs-11650193/v1

License: This work is licensed under a Creative Commons Attribution 4.0 International License.
Read Full License

Additional Declarations: No competing interests reported.

Abstract

Heterotopic ossification (HO), also known as ectopic ossification, involves the formation of extra-skeletal bone tissue in muscles and other soft tissues and is considered rare in veterinary medicine, especially in birds. Its pathogenesis is not yet fully understood, but it is generally associated with traumatic, surgical or chronic inflammatory processes. This report describes a case of HO associated with dystocia in an adult female greater rhea (*Rhea americana*) kept in captivity. The animal had a clinical history of intermittent bloody faeces, lethargy and mild weight loss, progressing to death. During necropsy, a retained egg was observed in the oviduct, with an irregular, thick and grumous shell. Additionally, multifocal, irregular, rough, hard, white plaques were adhered to the muscular coelomic wall. Microscopically, the muscle tissue showed extensive amorphous minerals deposits, areas of dystrophic calcification and the formation of mineralised bone tissue interposed between muscle fibres, with osteocytes, bone matrix, bone marrow, mixed inflammatory infiltrate and marked vascular congestion, findings consistent with HO. The pancreas showed haemorrhagic and congestive changes, with no evidence of ossification. The findings suggest that prolonged distension of the coelomic cavity and mechanical overload resulting from dystocia acted as predisposing factors for repetitive microtrauma and aberrant activation of osteogenic pathways in muscle tissue. This report advances knowledge on HO in birds and, for the first time, describes its association with reproductive disorders in a *Rhea americana*.

Introduction

Heterotopic ossification (HO), or ectopic ossification, is defined as the formation of extraskeletal bone within muscles or other tissues, at sites where bone does not normally exist. This abnormality results from a metaplastic process in soft tissues, usually adjacent to large joints (Shehab et al. 2002; Hartmann et al. 2004). It is a true ossification process associated with aberrant tissue repair and is increasingly recognised as a common complication of trauma, surgery and other local or systemic insults. The aetiology remains unknown, but several factors are being investigated as responsible for the osteoblastic activation observed in this disease in humans (Hartmann et al. 2004; Teasell et al. 2010; Hausmann et al. 2016).

HO can be initiated by tissue injury, followed by an influx of inflammatory cells and, subsequently, a signaling cascade among predominantly resident cells of mesenchymal origin. These downstream signaling events inappropriately activate osteogenic or osteochondrogenic pathways, leading to ectopic bone formation (Urist et al. 1978; Meyers et al. 2019). Reports of this condition in animals are uncommon and, when present, are generally associated with traumatic processes or surgical interventions in mammals. In birds, HO has been reported in eagles following trauma (Sato et al. 2014; Morton et al. 2015; Hausmann et al. 2016; Huenerfauth et al. 2022; Legler et al. 2024). However, a study employing osteoinducers derived from demineralised bone matrix (DBM) combined with bone morphogenetic proteins (BMPs) in pigeons demonstrated that this biomaterial is capable of inducing

heterotopic bone formation in allogeneic recipients, showing low immunogenicity in birds, as well as in humans (Reza Sanaei et al. 2013).

In avian medicine, disorders of the female reproductive tract are common, with dystocia representing a significant cause of morbidity and mortality. It is an alteration in the oviposition process, characterised by egg retention in the oviduct and associated with clinical signs such as lethargy, dyspnoea, haematochezia or achesia, coelomic distension, restlessness, reluctance to move, lameness, paresis and sudden death (Gündüz et al. 2009; Rosen 2012). Consequently, prolonged egg retention within the oviduct can trigger shell thickening and systemic changes, such as compression of digestive organs and bone calcium mobilisation, further exacerbating this condition (Pollock and Orosz, 2002). Given the rarity of HO in birds and the lack of reports linking it to reproductive disorders, this case report describes an unusual manifestation of extraskeletal bone formation associated with dystocia in a captive greater rhea (*Rhea americana*).

Case history and clinical examination

A 12-year-old, sexually mature female greater rhea (*Rhea americana*), measuring approximately 170 cm in height and weighing 23 kg, belonging to the Fortaleza Zoobotanical Park, was submitted for clinical evaluation. The animal was maintained in a spacious, well-ventilated outdoor enclosure shared with two other individuals of the same species and sex, where they were fed a species-appropriate diet. The rhea had a history of intermittent bloody faeces, with periods of more pronounced bleeding than others, a condition that persisted for two months prior to the animal's death. She also exhibited lethargy and mild weight loss. No other relevant clinical signs were observed. Despite medical management, the animal died and was submitted for necropsy at the Veterinary Pathology Sector of the same institution.

Results

During the necropsy, the main external finding, upon abdominal palpation, was a large, oval, firm structure compatible with an egg. No external lesions were observed. Upon entering the coelomic cavity, involvement of the internal muscular wall was noted, presenting multifocal, lumpy, irregular, stony, white plaques firmly adhered to the wall (Fig. 1), measuring between 4.7 × 3.2 × 1.1 cm and 0.9 × 0.7 × 0.5 cm. The pancreas was also conspicuous, exhibiting haemorrhagic areas and irregular surfaces similar to the plaques on the coelomic wall (Fig. 1a). The intestinal loops showed multiple petechiae distributed along the serosa, accompanied by prominent, engorged vessels (Fig. 1b).

Among the findings that contributed to the animal's death, haemorrhage and vascular engorgement were noted throughout the entire length of the mesentery. The oviduct was also congested, with a notable increase in volume in the portion corresponding to the uterus (Fig. 1c); upon sectioning, an egg with an irregular, lumpy and thickened shell weighing approximately 520 g was observed (Fig. 1d). Internally, the egg contents were heterogeneous and yellowish, with no clear distinction between yolk and albumen, consistent with marked protein denaturation.

Upon sectioning the muscle tissue affected by the plaques, an altered consistency was observed, displaying resistance and a gritty sensation on sectioning. The pancreas showed no abnormalities on the cut surface. Samples from all organs were collected, fixed in 10% neutral buffered formalin, processed using conventional histological techniques and stained with haematoxylin and eosin (H&E). Microscopically, histopathological sections of the pancreas revealed marked diffuse interstitial haemorrhage, characterised by an accumulation of free nucleated erythrocytes around the acinar units (Fig. 2a). Blood vessels were congested, with lumens distended by red blood cells. The parenchyma retained its architecture, with prominent pancreatic islets.

At lower magnification, the muscle tissue of the coelomic wall exhibited exuberant calcification, characterised by extensive amorphous, granular and basophilic mineral deposits distributed between muscle fibres (Fig. 2b). Interposed between these deposits and the muscle fibres, multiple areas of well-differentiated, mature bone tissue were observed, consisting of mineralised trabeculae containing osteocytes embedded within bone matrix lacunae (Fig. 2c and 2d). These areas were associated with a mixed inflammatory infiltrate, predominantly composed of lymphocytes, macrophages and rare heterophils. Between the trabeculae, adipose tissue and bone marrow were present, represented by erythroid lineage cells. Additionally, marked vascular congestion was noted in the areas adjacent to the ossification. Based on the anatomopathological findings, a diagnosis of heterotopic ossification was established.

Discussion

The dystocia in the rhea described in this report may have played a central role in the pathogenesis of the lesion. In cases of prolonged egg retention, particularly beyond 48 hours, distension of the reproductive tract and the coelomic cavity can lead to significant vascular and neural compressions, resulting in lameness, paresis, paralysis and impaired perfusion of adjacent organs (Clayton and Ritzman, 2006; Gündüz et al. 2009). Although the oviductal mucosa may undergo necrosis due to direct pressure from the impacted egg, the muscular coelomic wall, although not the primary impact point, is also affected due to the continuous mechanical support it provides and the gravitational load of the egg in ratites such as rheas, thereby contributing to microtrauma and secondary tissue stress. For this reason, the coelomic wall becomes an important site of tissue injury in the case described (Rosen 2012).

Prolonged mechanical overload creates an environment conducive to repetitive microinjury, characterised by muscle fibre disruption, vascular leakage and continuous activation of the local inflammatory response. This process promotes inflammatory cell chemotaxis and dystrophic calcification within the injured tissue. Additionally, local high vascularity acts as a predisposing factor for ossification by activating resident cells of mesenchymal origin, which become responsive to pro-osteogenic stimuli (Meyers et al. 2019; Alessi and Santos 2023). This downstream signalling network results in inappropriate activation of osteoblastic and chondroblastic pathways driven by transcription factors such as RUNX2 and SOX9, culminating in ectopic formation of bone tissue (Urist et al. 1978; Meyers et al. 2019).

In the present case, the combination of these factors created an environment conducive to the aberrant activation of tissue signalling pathways, consistent with the multifocal macroscopic presentation of ossification in the affected animal (Urist et al. 1978; Hartmann et al. 2004). Furthermore, owing to the anatomical convergence of the digestive, urinary and reproductive systems within the cloaca, the presence of blood in the cloacal region may be associated with haemorrhage originating from any of these systems. In the described animal, the clinical presentation mimicking haematochezia resulted from oviductal bleeding with subsequent mixing of blood with faecal material within the cloaca, which can complicate the immediate determination of the bleeding source during initial clinical examination (Vasconcelos et al. 2012).

Heterotopic bone is produced by previously undifferentiated mesenchymal cells present within interstitial tissues. In veterinary medicine, HO is recognized to develop across four site categories: soft tissues, non-skeletal musculoskeletal structures, entheses and periosteal tissues (Hartmann et al. 2004; Javdani et al. 2016). In the present case, bone formation occurred within the muscle tissue, and histopathological sections were essential for establishing the diagnosis, revealing a heterogeneous cell population associated with the production of mature bone tissue containing bone marrow, accompanied by inflammatory infiltration and tissue hyperaemia. These findings are consistent with HO, which involves the formation of mature bone in abnormal sites (Shehab et al. 2002; Alberti et al. 2025).

Reports of HO in birds are limited. In a golden eagle (*Aquila chrysaetos*), the condition was observed in the musculature adjacent to a projectile injury and was attributed to the displacement of bone cells into the ballistic cavity, where they acted as ectopic osteoprogenitor cells (Javdani et al. 2016). In bald eagles (*Haliaeetus leucocephalus*), three cases were associated with repetitive microtrauma to the adductor muscles resulting from daily management with jesses, highlighting repetitive trauma as a triggering factor for aberrant tissue repair and osseous metaplasia (Legler et al. 2024). To date, there are no reports linking HO to reproductive disorders or dystocia in birds. Furthermore, no evidence suggests a hereditary nature of this condition or a consistent association with skeletal anomalies in animals, particularly in birds, in contrast to human medicine (Warren and Carpenter, 1984).

Histopathological evaluation of the plaques revealed mineralised bone tissue interspersed between muscle fibres, accompanied by vascular hyperaemia and inflammatory infiltration, findings consistent with an active process of heterotopic ossification associated with dystrophic calcification. The location of the lesion within the muscle layer, with no anatomical connection to joints, tendons, or ligaments, highlights its atypical extraskeletal nature (Javdani et al. 2016; Legler et al. 2024; Alberti et al. 2025). Additionally, extensive areas of amorphous, granular, basophilic material, unorganized into osteoid matrix or bone tissue, were identified adjacent to the areas of ossification. These deposits are consistent with dystrophic calcification, a phenomenon associated with calcium deposition in injured or necrotic tissues. Considering the reproductive physiology of birds, systemic calcium mobilisation for eggshell formation may have contributed to local calcium precipitation within regions of tissue injury, exacerbating the aberrant mineralisation process (Pollock and Orosz 2002).

In contrast, histopathological evaluation of the pancreas revealed no bone tissue at any stage of formation, nor areas of calcification. The identified changes were limited to marked haemorrhage and vascular congestion within the parenchyma and capsule, with preservation of the pancreatic islet architecture, findings consistent with compressive injury (Alessi and Santos 2023). This pattern indicates that the pressure exerted by the impacted egg led to vascular stasis, congestion, and microvascular rupture. Furthermore, this pancreatic congestion may have occurred, in part, secondarily to the compression of mesenteric vessels that, in ratites, share drainage with the pancreas, thereby obstructing intestinal venous return and aggravating the pancreatic condition (Vasconcelos et al. 2012).

Thus, this report contributes to a better understanding of heterotopic ossification in birds, broadening knowledge regarding its possible pathophysiological mechanisms and clinical presentations. Notably, it highlights its occurrence in birds with reproductive disorders, such as dystocia, a condition capable of inducing internal lesions with the potential to activate osteogenic pathways in soft tissues, even in the absence of evident external trauma.

Declarations

Compliance with ethical standards

Ethical approval All applicable international, national, and/or institutional guidelines for the care and use of animals were followed. All procedures performed in studies involving animals were in accordance with the ethical standards of the institution or practice at which the studies were conducted.

Informed consent

Informed consent was obtained from all individual participants included in the study.

Consent for publication

Consent for publication was obtained for every individual person’s data included in the study.

Conflict of interest

The authors declare no competing interests.

Funding

This study was not supported by any funding.

Author Contribution

João Ricardo Sales Rocha Filgueiras: Investigation, Methodology, Writing – Original Draft. Maria Eduarda Rocha Almeida: Investigation, Resources, Data Curation. Juliana Sousa Benevides: Investigation, Methodology, Writing – Original Draft. Karen Emanuelly Pinheiro Gomes: Investigation, Methodology. Fábio Ranyeri Nunes Rodrigues: Resources, Writing – Review & Editing. Raqueli Teresinha França: Methodology, Writing – Review & Editing. Fernanda Menezes de Oliveira e Silva: Investigation, Methodology. Belise Maria Oliveira Bezerra: Data Curation, Writing – Original Draft. All authors reviewed the manuscript.

Data availability

No datasets were generated or analysed during the current study

References

1. Alberti TS, Nogueira AT, Furquim MD, Santos DF, Zamboni R, Sallis ESV, Marcolongo-Pereira C. Intraocular osseous metaplasia in Norfolk Black Turkey (*Meleagris gallopavo*): Clinicopathological characterization of a rare avian condition. Vet. Ophthalmol. 2025; 0:1–6. doi: https://doi.org/10.1111/vop.70118
2. Alessi AC, Santos RL. Patologia veterinária. 3rd ed. Rio de Janeiro: Roca; 2023.
3. Clayton LA, Ritzman TK. Egg binding in a cockatiel (*Nymphicus hollandicus*). Vet Clin Exot Anim. 2006;9(3):511–518, 2006. doi:10.1016/j.cvex.2006.05.004
4. Gündüz M, Toydemir S, Enginler SA, Yılmaz ÖT, Yigit F, Uçmak M. Hysterectomy operation for the treatment of the egg binding in the Lovebird (Agapornis comprise): Case report. İstanbul Üniversitesi Veteriner Fakültesi Dergisi. 2009;35(1):43–48. doi: https://doi.org/10.16988/iuvfd.56447
5. Hartmann AP, Ximenes AR, Hartmann LG, Fernandes AR, Natour J, D'Ippolito G. Diagnostic imaging in the evaluation of heterotopic ossification. Rev. Bras. Reumatol. 2004;44, 291–293. doi: https://doi.org/10.1590/S0482-50042004000400008
6. Hausmann JC, Manasse J, Churgin S, Steinberg H, Clyde VL, Wallace R. Myositis ossificans traumatica in a Vampire Bat (*Desmodus rotundus*). J. Zoo Wildl. Med. 2016;47(3):895–899.
7. Huenerfauth EL, Molnár V, Rosati M, Ciurkiewicz M, Söbbeler FJ, Harms O, Hildebrandt, R, Baumgärtner W, Tipold A, Volk, HA. Case report: Unable to jump like a Kangaroo due to Myositis ossificans circumscripta. Front. Vet. Sci. 2022;9:886495. doi: https://doi.org/10.3389/fvets.2022.886495
8. Javdani M, Hashemnia M, Nikousefat Z. Heterotopic ossification secondary to gunshot and fragment wounds in a Golden Eagle (*Aquila chrysaetos*). J Avian Med Surg. 2016;30(1):66–70. doi: https://doi.org/10.1647/2014-058
9. Legler M, Von Dörnberg K, Wohlsein P, Fehr M. Heterotopic ossification of the adductor muscles in Bald Eagles (*Haliaeetus leucocephalus*). Vet Sci. 2024;11(11):556. doi:

https://doi.org/10.3390/vetsci11110556

10. Meyers C, Lisiecki J, Miller S, Levin A, Fayad L, Ding C, James AW. Heterotopic Ossification: A comprehensive review. JBMR plus. 2019;3(4):e10172. doi: https://doi.org/10.1002/jbm4.10172
11. Morton BA, Hettlich BF, Pool RR. Surgical treatment of traumatic myositis ossificans of the extensor carpi radialis muscle in a dog. Vet Surg. 2015;44(5):576–580. doi: https://doi.org/10.1111/j.1532-950X.2014.12297.x
12. Pollock CG, Orosz SE. Avian reproductive anatomy, physiology and endocrinology. Vet. Clin. Exot. Anim. 2002;5(3):441–474. doi: https://doi.org/10.1016/S1094-9194(02)00010-5
13. Reza Sanaei M, Abu J, Nazari M, Mohd Zuki AB, Allaudin ZN. Qualitative and quantitative evaluation of avian demineralized bone matrix in heterotopic beds. Vet Surg. 2013;42(8):963–970. doi: https://doi.org/10.1111/j.1532-950X.2013.12057.x
14. Rosen LB. Topics in Medicine and Surgery, Avian reproductive disorders. J. Exot. Pet Med. 2012;21(2):124–131. doi: https://doi.org/10.1053/j.jepm.2012.02.013
15. Sato F, Shibata R, Shikichi M, Ito K, Murase H, Ueno T, Yamada K. Rupture of the gastrocnemius muscle in neonatal thoroughbred foals: a report of three cases. J. Equine Sci. 2014; 25(3):61–64. doi: https://doi.org/10.1294/jes.25.61
16. Shehab D, Elgazzar AH, Collier BD. Heterotropic Ossification. J. Nucl. Med. 2002;43(3):346–353. PMID: 11884494
17. Teasell RW, Mehta S, Aubut JL, Ashe MC, Sequeira K, Macaluso S, Tu L. A systematic review of the therapeutic interventions for heterotopic ossification after spinal cord injury. Spinal cord, 2010;48(7):512–521. doi: https://doi.org/10.1038/sc.2009.175
18. Urist MR, Nakagawa M, Nakata N, Nogami H. Experimental myositis ossificans: cartilage and bone formation in muscle in response to diffusible bone matrixderived morphogen. Arch Pathol Lab Med. 1978;102:312–316. PMID: 580725.
19. Vasconcelos BG, Silva FOC, Miranda RL, Pereira CCH, Santos AC, Miglino MA. Origin and distribution of the celiac artery in Ostriches (*Struthio camelus*). Ciênc. Anim. Bras. 2012;13(1):108–114. https://doi.org/10.5216/cab.v13i1.15520
20. Warren HB, Carpenter JL. Fibrodyplasia Ossifican in three cats. Vet. Pathol. 1984; 21(5):495–499. doi: https://doi.org/10.1177/030098588402100507

Figures



Figure 1

Coelomic cavity of *Rhea americana*. a) Multiple yellowish plaques firmly adhered to the inner muscular wall of the coelomic cavity (arrowheads), which were firm on cut sections and presented a gritty appearance. The pancreas (asterisk) is enveloped by adipose tissue of a similar colour to the plaques. b) Intestinal loop showing petechiae and vascular congestion on the serosal surface. c) Oviduct with engorged vessels and containing an egg within the uterus. d) Egg removed from the reproductive tract, exhibiting an irregular, lumpy and thickened shell with yellowish content consistent with protein denaturation.

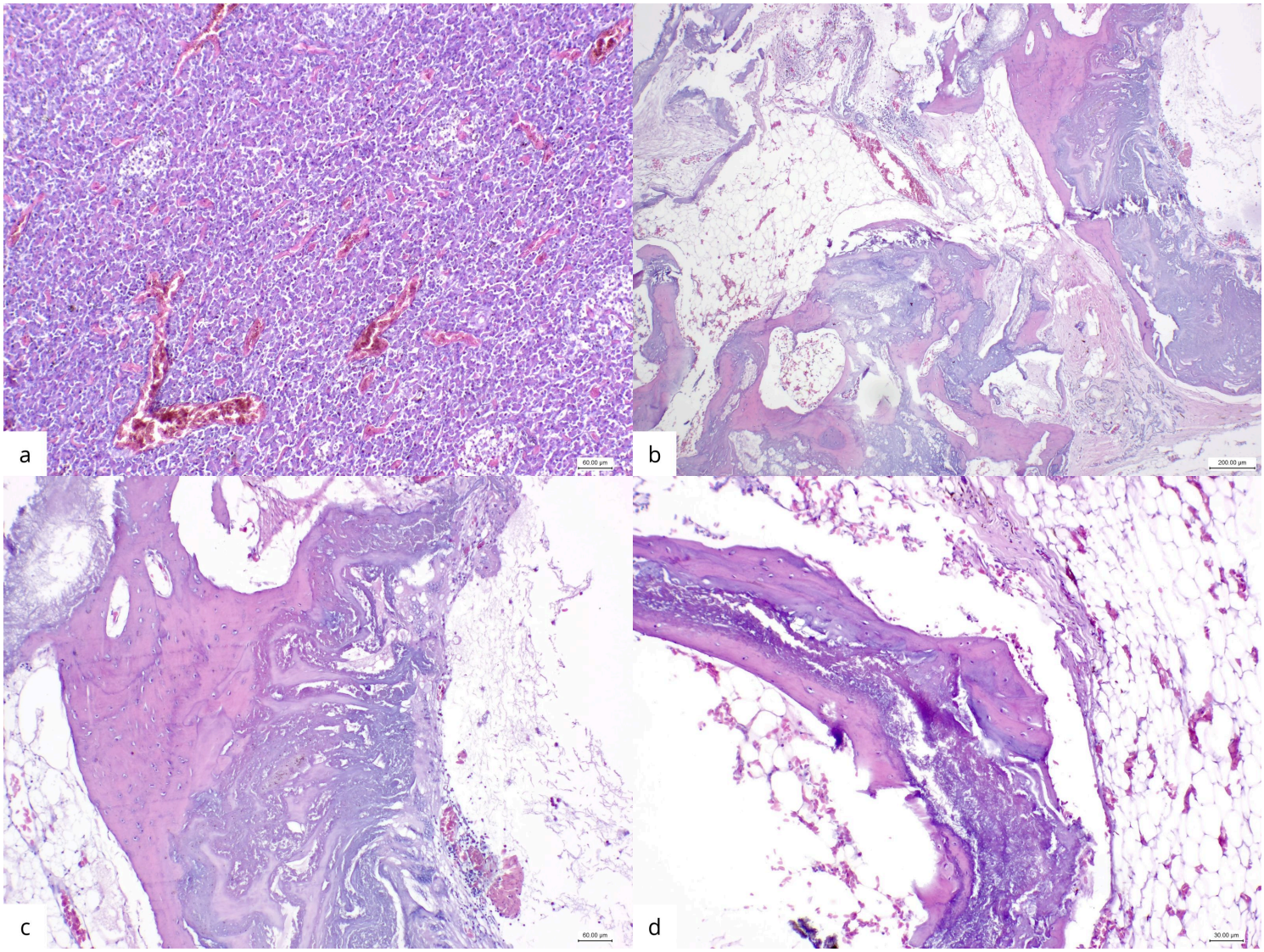

Figure 2

Photomicrographs of the pancreas and extraskeletal bone formations in *Rhea americana*. a) Pancreas exhibiting marked vascular congestion with areas of parenchymal haemorrhage (HE, 10×. Bar = 60.00 µm). b) Lower magnification showing areas of exuberant ossification and mineralisation with deposition of amorphous, basophilic material within the muscle tissue (HE, 4×. Bar = 200.00 µm). c) Mineralised bone tissue interposed between muscle fibres and adipocytes, with associated inflammatory infiltrate related to the ossification process. Note vascular congestion near the bone formation (HE, 10×. Bar = 60.00 µm). d) Osteocytes embedded within the bone matrix, which exhibits eosinophilic staining in contrast to the adjacent areas of mineralisation characterized by amorphous, granular and basophilic material (HE, 20×. Bar = 30.00 µm).