Research Square

Preprints are preliminary reports that have not undergone peer review.
They should not be considered conclusive, used to inform clinical practice,
or referenced by the media as validated information.

Association Between CT Distribution Patterns and Longitudinal Changes in Inte stinal Graft-Versus-Host Disease and Clinical Outcomes: A Retrospective Study

Lan Lan
First Affiliated Hospital of GuangXi Medical University
Yugui Huang
First Affiliated Hospital of GuangXi Medical University
Yingtai Huang
First Affiliated Hospital of GuangXi Medical University
Jiatong Liang
First Affiliated Hospital of GuangXi Medical University
Xingxing Xie
First Affiliated Hospital of GuangXi Medical University
Yixun Li
First Affiliated Hospital of GuangXi Medical University
Xia Su
First Affiliated Hospital of GuangXi Medical University
Peng Peng
doublep@126.com

First Affiliated Hospital of GuangXi Medical University

Research Article

Keywords: intestinal graft-versus-host disease, computed tomography, spatial distribution, longitudinal imaging, clinical outcomes

Posted Date: November 25th, 2026

DOI: https://doi.org/10.21203/rs.3.rs-11648307/v1

License: This work is licensed under a Creative Commons Attribution 4.0 International License.
Read Full License

Additional Declarations: No competing interests reported.

Abstract

Background

Intestinal graft-versus-host disease (GVHD) is a major complication following allogeneic haematopoietic stem cell transplantation. Although computed tomography (CT) can characterise the extent and distribution of intestinal abnormalities, the relationship between CT-defined spatial patterns, longitudinal changes, and clinical outcomes remains unclear. To investigate whether the extent and spatial distribution of initial CT abnormalities in intestinal GVHD are associated with adverse clinical outcomes, and to characterise patient-level longitudinal CT trajectories.

Methods

This single-centre retrospective study included 22 patients, divided into a survival group (n = 10) and an adverse outcome group (n = 12). The Mann–Whitney U test and Fisher's exact test were used to compare initial CT findings between groups. Eleven patients underwent clinically indicated follow-up CT scans, which were included in a descriptive longitudinal analysis.

Results

The adverse outcome group had a greater number of affected intestinal segments (r = 0.661, *P* = 0.001), thicker large intestinal walls (r = 0.675, *P* < 0.001), lower CT values on non-contrast large intestinal scans (r = 0.486, *P* = 0.021), a higher frequency of continuously distributed intestinal lesions (*P* = 0.012), and a higher frequency of the comb sign (OR = 12.00, 95% CI 1.58–91.08; *P* = 0.030).

Conclusion

A more extensive distribution of intestinal lesions, a continuous distribution pattern, more pronounced large intestinal wall thickening, lower CT values on non-contrast colon scans, and the presence of the comb sign are associated with poor outcomes.

Background

Allogeneic haematopoietic stem cell transplantation (allo-HSCT) is a key treatment for a wide range of haematological malignancies and certain non-malignant haematological and immunological disorders [1]. Although survival outcomes following allo-HSCT have improved in recent years, non-relapse mortality and transplant-related complications remain significant clinical issues [2]. Graft-versus-host disease (GVHD) is a major and potentially life-threatening complication following allo-HSCT [3–5]. Gastrointestinal (GI) lesions are a major clinical manifestation of GVHD, and severe GI-GVHD is

associated with poor clinical outcomes [3, 5–7]. The clinical management of acute GI-GVHD refractory to corticosteroids, particularly in severely affected patients, remains a significant challenge [8].

Gastrointestinal graft-versus-host disease (GI-GVHD) may present as diarrhoea, abdominal pain, nausea, vomiting, and gastrointestinal haemorrhage; its diagnosis requires a comprehensive assessment of clinical manifestations, exclusion of infection, and endoscopic and histopathological findings [7, 9–11]. Endoscopic mucosal biopsy provides important diagnostic evidence for intestinal GVHD; however, in patients with severe thrombocytopenia, coagulopathy, or granulocytopenia, biopsy may increase procedural risk [7]. Furthermore, because endoscopy primarily assesses the gastrointestinal mucosa and cannot fully reflect abnormalities in structures outside the intestinal wall, such as the mesentery, Computed tomography(CT) can provide supplementary information [9, 12].

Although CT findings are not specific to intestinal GVHD, CT can provide supplementary information on the entire abdomen when clinically indicated, including the extent and distribution of intestinal lesions, mesenteric vasodilation, and potential complications [9, 12]. It can be informative when endoscopy cannot be performed promptly, when the extent of abdominal involvement needs to be assessed, or when other complications need to be ruled out [9]. Previous studies have also attempted to combine CT findings with clinical indicators to construct predictive models to aid in the diagnosis of GI-GVHD [12]. Previous research has shown that CT manifestations of intestinal GVHD include intestinal wall thickening, intestinal dilation, abnormal mucosal enhancement, mesenteric vascular changes, and ascites [7, 13–15]. Furthermore, some studies suggest that the extent of affected bowel segments and specific CT features are associated with clinical severity, pathological grading, or treatment response [7, 14, 16]. A small number of studies have further described the temporal evolution of CT findings [17]. However, little is known about the relationship between the CT-defined spatial distribution of lesions, patient-level longitudinal trajectories, and subsequent clinical outcomes. Therefore, this study aims to determine whether the spatial distribution of intestinal lesions on the initial CT scan is associated with adverse clinical outcomes and to explore the longitudinal trajectories of CT changes during clinically indicated follow-up examinations.

Materials and Methods

1. Study Design and Study Population

This was a single-centre, retrospective, exploratory study that included patients who developed gastrointestinal symptoms following allo-HSCT between January 2018 and August 2025 and were diagnosed with intestinal GVHD. Inclusion criteria were: (1) a history of allo-HSCT; (2) the presence of gastrointestinal symptoms such as diarrhoea, abdominal pain, nausea, vomiting, or gastrointestinal haemorrhage, which were comprehensively diagnosed as intestinal GVHD based on clinical data, infection screening, endoscopy, and/or pathological findings from mucosal biopsies [10–11]; (3) completion of at least one abdominal and pelvic CT scan; and (4) availability of clinical outcome data. A total of 22 patients met the eligibility criteria and were included in the final analysis (Fig. 1). This study

was approved by the hospital's Ethics Committee (Ethics No.: 2026-E0630). As this was a retrospective study, the Ethics Committee granted an exemption from the requirement for informed consent.

Exclusion criteria were: (1) CT image quality insufficient to assess the intestinal wall; (2) the presence of other definite intestinal diseases capable of independently explaining the current intestinal presentation, including neutropenic enteritis, cytomegalovirus enteritis, Clostridium difficile-associated colitis, and intestinal tumours; and (3) lack of key clinical or imaging data.

Patients were categorised into the survival group and the adverse outcome group based on the outcome at the final follow-up. The survival group was defined as those still alive at the time of the final follow-up; the composite adverse outcome group was defined as those who died during hospitalisation or who were discharged after further treatment was discontinued due to critical illness.

2. CT Examination Protocol

2. CT Examination Protocol
Abdominal and pelvic CT scans for all 22 patients were performed as clinically indicated using various CT scanners, including the Siemens SOMATOM Definition/Force, Siemens 64-slice CT, and GE 256-slice CT. The standard slice thickness was 5 mm, with a reconstruction slice thickness of 3 mm; the scan range extended from the diaphragmatic dome to the lower margin of the pubic symphysis. Contrast-enhanced scanning utilised a non-ionic iodinated contrast agent (iopamidol, 300 mg iodine/mL, 1–2 mL/kg, 2.5–3.0 mL/s). Owing to the extended duration of the study and its retrospective design, the CT acquisition protocols were not fully standardised in terms of equipment type, contrast-enhanced phases, and certain scanning parameters.

3. CT Image Assessment and Definitions

Two radiologists, each with more than five years of experience in abdominal imaging, independently reviewed the images while blinded to the patients' final clinical outcomes and group allocation; disagreements were resolved by consensus through joint review. The intestine was divided into eight segments: duodenum, jejunum, ileum, ascending colon, transverse colon, descending colon, sigmoid colon, and rectum. The number of affected intestinal segments and the distribution pattern of the lesions were recorded. A continuous distribution was defined as consecutive abnormal changes in the intestinal wall appearing in adjacent segments, whereas a discontinuous distribution was defined as the presence of radiologically normal intestinal segments between affected segments [16–17].

Abnormal intestinal wall thickening was defined as a small intestine wall thickness > 3 mm and a large intestine wall thickness > 5 mm [18–19]; small intestine dilatation > 3 cm and large intestine dilatation > 8 cm were defined as pathological luminal dilatation [17]; lymph node enlargement was operationally defined as a short axis > 10 mm [20]. The comb sign, blurring of the peritoneal fat space, ascites, and signs of intestinal wall layering were assessed visually. For non-contrast CT measurements of the

intestinal wall, regions of interest (ROIs) were delineated at the sites of most pronounced wall thickening, avoiding intestinal contents and adjacent fat; three measurements were taken at each site and the mean value was calculated. For follow-up CT measurements, efforts were made to select the same anatomical segments and similar slices as in the initial CT scan.

4. Statistical Analysis

Statistical analysis was performed using SPSS 27.0. Owing to the small sample size and the non-normal distribution of the data, the Mann–Whitney U test was used for intergroup comparisons of continuous variables, and precise two-sided P-values were reported; the effect size was calculated as $r = |Z|/\sqrt{N}$. For dichotomous variables, Fisher's exact test was used, and the odds ratio (OR) and 95% confidence interval (CI) were reported; for multicategorical variables, the Fisher–Freeman–Halton exact test was used, with Cramér's V used to indicate the strength of association. All tests were two-sided.

For patients who underwent follow-up CT scans, the initial CT and the second CT were treated as paired observation time points. The change in continuous variables (Δ) was defined as the second CT measurement minus the initial CT measurement, and exploratory comparisons of these changes between the two groups were performed using the Mann–Whitney U test. For categorical CT findings, exploratory comparisons of the distribution of change categories between the two groups were performed using the Fisher–Freeman–Halton exact test.

Results

1. Patient Characteristics and Outcomes

There were no statistically significant differences between the two groups in terms of age, sex, type of primary disease, HLA matching, donor–recipient relationship, stem cell source, time from transplantation to the first CT scan, involvement of the skin, liver, or central nervous system, or key laboratory parameters. There was a difference between the groups in the distribution of lesions observed on colonoscopy ($P = 0.005$); lactate dehydrogenase levels were higher in the adverse outcome group ($P = 0.050$). All patients in the adverse outcome group had grade 4 intestinal graft-versus-host disease (GVHD), whereas 7 of 10 patients in the survival group developed grade 4 intestinal lesions ($P = 0.078$) (Table 1).

Table 1
Clinical, transplant and follow-up characteristics of the two groups of patients

Characteristic	Survival group (n = 10)	Adverse outcome group(n = 12)	*P*
Age (years)	12.5 (9.25, 17.00)	11 (8.50, 19.25)	0.722
Gender (male/female)	8/2	6/6	0.204
Underlying disease(β-THAL/MDS/CML/ALL/PID)	7/1/0/1/1	9/1/1/1/0	0.920
HLA type (fully matched/partially matched)	3/7	8/4	0.198
Relationship to donor (related/unrelated)	6/4	5/7	0.670
Stem cell source (bone marrow/peripheral blood/bone marrow + peripheral blood)	1/4/5	1/8/3	0.568
Time to first colonoscopy post-transplant (days)	41.5 (29.75, 137.50)	40.5 (29.50, 49.50)	0.692
Time to first CT scan post-transplant (days)	41 (22.00, 154.25)	50 (30.00, 77.00)	0.531
Location of lesions on colonoscopy (none/large intestine/small intestine/large intestine + small intestine)	7/1/1/1	1/4/0/7	0.005
Skin involvement, n (%)	4 (40.00%)	7 (58.33%)	0.670
Liver involvement, n (%)	0 (0%)	4 (33.33%)	0.096
Abnormalities on cranial CT/MRI, n (%)	2 (20.00%)	3 (25.00%)	1.00
Albumin (g/L)	31.75 (30.175, 33.95)	33.85 (28.53, 36.18)	0.616
Lactate dehydrogenase (U/L)	162.5 (139.75, 197.50)	308.5 (259.50, 630.50)	0.050
Platelets (×10⁹/L)	59.85 (47.73, 96.03)	61.4 (44.00, 107.28)	0.821
Absolute lymphocyte count (×10⁹/L)	0.5 (0.13, 0.89)	0.16 (0.07, 0.97)	0.570
Intestinal GVHD grade (grade 1/2/3/4)	0/1/2/7	0/0/0/12	0.078

Note: Data are presented as median (25th percentile, 75th percentile) or number of patients [n (%)], as appropriate. For multicategorical variables, counts are presented in the order specified in the corresponding row.

Abbreviations: β-THAL, β-thalassaemia; MDS, myelodysplastic syndrome; CML, chronic myeloid leukaemia; ALL, acute lymphoblastic leukaemia; PID, primary immunodeficiency; GVHD, graft-versus-host disease.

2. Association Between Initial CT Findings and Clinical Outcomes

Intergroup comparisons of initial CT scans revealed that patients in the adverse outcome group had a greater number of affected intestinal segments (r = 0.661, *P* = 0.001), more pronounced large intestine wall thickening (r = 0.675, *P* < 0.001), lower CT values on non-contrast large intestine scans (r = 0.486, *P* = 0.021), and a higher prevalence of continuous distribution patterns of intestinal wall lesions and the comb sign. No statistically significant differences were observed between the two groups regarding small intestine wall thickness, small intestine CT values on non-contrast scans, intestinal wall stratification, luminal dilatation or fluid accumulation, lymph node enlargement, blurring of the fat planes, or ascites (*P* > 0.05) (Table 2; Figs. 2 and 3).

Table 2
Comparison of initial CT findings with clinical outcomes

Item	Survival group (n = 10)	Adverse outcome group (n = 12)	Effect size	*P*
Number of affected intestinal segments	0 (0.00, 2.25)	3.50 (2.25, 6.75)	r = 0.661	0.001
Maximum small intestine wall thickness (mm)	1.89 (1.59, 3.48)	4.14 (1.62, 6.44)	r = 0.218	0.322
Maximum large intestine wall thickness (mm)	3.52 (2.07, 6.76)	8.94 (6.67, 12.50)	r = 0.675	< 0.001
Ring-like stratification of the intestinal wall, n (%)	5 (50.00%)	7 (58.33%)	OR = 1.40(95% CI 0.259–7.582)	1.000
CT values (HU) of the small intestine on non-contrast scan	31.50 (20.25, 37.25)	28.00 (26.50, 36.00)	r = 0.021	0.935
CT values (HU) of the large intestine on non-contrast scan	30.50 (25.75, 45.25)	19.00 (14.25, 24.25)	r = 0.486	0.021
Intestinal dilation or fluid accumulation, n (%)	6 (60.00%)	6 (50.00%)	OR = 0.667(95% CI 0.122–3.640)	0.691
Distribution pattern of affected intestinal segments (none/continuous/discontinuous)	7/1/2	2/8/2	Cramér's V = 0.607	0.012
Comb sign, n (%)	2 (20.00%)	9 (75.00%)	OR = 12.00(95% CI 1.581–91.084)	0.030
Lymph node enlargement or multiple visible lymph nodes, n (%)	6 (60.00%)	5 (41.67%)	OR = 0.476(95% CI 0.086–2.628)	0.670
Blurred fat spaces, n (%)	2 (20.00%)	7 (58.33%)	OR = 5.60(95% CI 0.814–38.512)	0.099
Ascites, n (%)	4 (40.00%)	6 (50.00%)	OR = 1.50(95% CI 0.275–8.189)	0.691
Intrahepatic bile duct dilatation, n (%)	0 (0%)	1 (8.33%)	NE	1.000
Thickened gallbladder wall, n (%)	0 (0%)	1 (8.33%)	NE	1.000

Item	Survival group (n = 10)	Adverse outcome group (n = 12)	Effect size	*P*
Thickened bladder wall, n (%)	1 (10.00%)	2 (16.67%)	OR = 1.80(95% CI 0.139–23.374)	1.000

3. Dynamic Changes in CT Findings During Patient Follow-Up

Follow-up CT scans were performed according to clinical indications; the timing and frequency of follow-up varied between patients. Eleven patients underwent at least two CT scans (seven in the survival group and four in the adverse outcome group). The median interval between the initial and second CT scans was 7 weeks in the survival group and 3 weeks in the adverse outcome group.

On the second CT scan and in subsequent patient trajectories, patients in the adverse outcome group more frequently exhibited a continuous distribution of persistent segmental lesions, the comb sign, and blurring of the peritoneal fat space. Of the four patients in the adverse outcome group, three presented with continuous segmental lesions on the second CT scan; of these, one exhibited a persistent continuous distribution of the affected intestinal segments, whereas two transitioned from other distribution patterns to a continuous distribution pattern; the remaining patient transitioned to a discontinuous distribution pattern. The proportion of patients in the adverse outcome group with a persistently positive comb sign and blurred peritoneal fat spaces was higher than that in the survival group (Table 3, Fig. 4).

Table 3
Exploratory analysis of changes in key CT findings on follow-up CT scans

Parameter	Survival group (n = 7)	Adverse outcome group (n = 4)	*P*
Time interval between baseline CT and first follow-up CT (weeks)	7 (4, 9)	3 (3, 9)	0.412
Change in number of affected intestinal segments (Δ segments)	2 (0, 4)	0.50 (0, 2.50)	0.545
Change in small intestine wall thickness (Δ mm)	1.62 (−0.48, 3.56)	3.52 (0.09, 7.04)	0.412
Change in large intestine wall thickness (Δ mm)	2.26 (−1.01, 3.57)	0.25 (−0.80, 2.77)	0.788
Evolution of lesion distribution (persistently negative / persistently continuous distribution / transition to continuous distribution / transition to discontinuous distribution / persistently discontinuous distribution	2/1/2/1/1	0/1/2/1/0	0.903
Changes in the comb sign (resolved / persistently negative / new onset / persistently positive), n (%)	0/2/3/2	0/0/1/3	0.394
Changes in blurring of the peritoneal fat space (resolved / persistently negative / new onset / persistently positive)	0/3/3/1	0/0/1/3	0.200
Changes in intraluminal fluid or dilatation (persistently negative / improvement / stable positive / worsening)	2/3/0/2	2/0/1/1	0.509
New-onset pneumatosis intestinalis during follow-up, n (%)	1 (14.30)	0 (0%)	1.000

Note: Data are presented as median (25th percentile, 75th percentile) or number of patients [n (%)], as appropriate. For multicategorical variables, counts are presented in the order specified in the corresponding row. Changes in continuous variables (Δ) were calculated as the measurement on the second CT scan minus that on the initial CT scan. For intestinal wall thickness, a positive Δ indicates an increase in wall thickness, whereas a negative Δ indicates a decrease in wall thickness.

4. Descriptive Findings From the Contrast-Enhanced CT Subgroup

Seven patients underwent contrast-enhanced CT scans, of whom six (three in each group) demonstrated layered enhancement. Owing to variations in the timing of the contrast-enhanced examinations, scanning phases, and equipment parameters, only the CT values of the intestinal wall were subjected to descriptive analysis (Supplementary Table S1, Supplementary Figure S1).

Discussion

This exploratory study suggests that the spatial extent and distribution patterns of intestinal abnormalities on CT scans may be associated with clinical outcomes in intestinal GVHD. Patients with adverse outcomes had a greater number of affected intestinal segments, a higher frequency of continuous lesion distribution, more pronounced large intestine wall thickening, lower CT values on non-contrast large intestine scans, and a higher frequency of the comb sign. These findings may reflect, respectively, more extensive intestinal involvement, more severe intestinal wall oedema or damage, and mesenteric vascular congestion.

Previous studies have reported that gastrointestinal GVHD may present with CT features such as intestinal wall thickening, abnormal enhancement, mesenteric vascular dilation, and the comb sign [7, 9, 13–14]. Kalantari et al. found that the number of affected, thickened intestinal segments was associated with a higher grade of gastrointestinal GVHD [16]. Brodoefel et al. observed a correlation between mucosal density on non-contrast CT and clinical and pathological grading [14]. This study further observed that the number of affected intestinal segments on the initial CT scan, the pattern of continuous lesion distribution, and lower non-contrast CT values of the large intestine wall were associated with composite adverse clinical outcomes.

CT should be regarded as a supplement to, rather than a substitute for, endoscopy and mucosal biopsy [7, 9]. Endoscopy and histopathology provide direct assessment of mucosal disease and diagnostic confirmation, whereas clinically indicated CT provides comprehensive abdominal information regarding the spatial extent of intestinal lesions, intestinal wall thickening, mesenteric changes, and complications.

Longitudinal observation also provides further evidence regarding spatial presentation. Lesions exhibiting a continuous distribution pattern—whether persisting or newly developing during follow-up examinations—were more common in patients with adverse outcomes; the presence of a comb sign and blurring of the peritoneal fat space was also more frequent in this group. However, only 11 patients underwent follow-up CT scans, and these were clinically driven. Consequently, the CT findings may be subject to indication bias, unequal observation frequency, and incomplete longitudinal sampling.

This study has several limitations. First, the cohort was small and single-centre, limiting precision, statistical power, and the feasibility of multivariate adjustment. Second, follow-up CT scans were performed based on clinical indications rather than at pre-defined time points, leading to selection and indication bias. Furthermore, patients' clinical outcomes may also be influenced by the severity of GVHD, treatment response, infection, and other transplant-related factors [21–22]. Given the limited sample size of this study, the aforementioned potential confounding factors have not been adequately controlled for. Consequently, future studies should be multicentre, large-scale, and prospective, utilising standardised diagnostic criteria, CT acquisition protocols, and pre-defined follow-up windows.

Conclusion

In this single-centre, retrospective, exploratory study, a broader range of intestinal lesions as defined by CT, a continuous lesion distribution pattern, marked large intestine wall thickening, lower CT values on

non-contrast large intestine CT, and the presence of the comb sign were associated with a poor overall clinical outcome in intestinal GVHD following allogeneic transplantation. Patient-level follow-up suggests that persistent or newly emerging continuous lesion distribution patterns and mesenteric abnormalities at follow-up may provide additional information regarding disease progression. These findings require validation in standardised, multicentre, large-sample prospective studies.

Abbreviations

allo-HSCT
Allogeneic haematopoietic stem cell transplantation
CT
Computed tomography
GI
Gastrointestinal
GI-GVHD
Gastrointestinal graft-versus-host disease
GVHD
Graft-versus-host disease

Declarations

1. Ethics approval and consent to participate

This study was approved by the Ethics Committee of The First Affiliated Hospital of Guangxi Medical University (Approval No. 2026-E0630). The requirement for informed consent to participate was waived by the ethics committee because of the retrospective nature of the study. The study was conducted in accordance with the Declaration of Helsinki and relevant institutional and national regulations.

2. Consent for publication

The requirement for consent for publication was waived by the Ethics Committee because of the retrospective nature of the study.

3. Availability of data and materials

The datasets generated and/or analysed during the current study are not publicly available due to patient confidentiality and institutional data-protection requirements. De-identified data may be available from the corresponding author upon reasonable request, subject to institutional approval and applicable ethical and legal restrictions.

4. Competing interests

The authors declare that they have no competing interests.

5. Funding

This work was supported by the National Natural Science Foundation of China [grant numbers 82660398, 81760305, 81641066]; the Beijing Medical Award Foundation Ruiying Scientific Research Fund Key Project [grant number YXJL-2024-0530-0321]; and the Empowerment Action Plan (Guangxi Key Research and Development Program) Project [grant number FN2600640144].

6. Authors' contributions

Lan Lan conceived and designed the study. Yugui Huang and Yingtai Huang collected the clinical and imaging data. Jiatong Liang and Xingxing Xie independently reviewed the CT images and participated in consensus assessment. Yixun Li performed the statistical analysis. Lan Lan drafted the manuscript. Lan Lan and Peng Peng critically revised the manuscript for important intellectual content. All authors read and approved the final manuscript.

7. Acknowledgements

Not applicable.

References

1. Snowden JA, Sánchez-Ortega I, Corbacioglu S, Basak GW, Chabannon C, de la Camara R, et al. Indications for haematopoietic cell transplantation for haematological diseases, solid tumours and immune disorders: current practice in Europe, 2022. Bone Marrow Transpl. 2022;57(8):1217–39. 10.1038/s41409-022-01691-w.
2. McDonald GB, Sandmaier BM, Mielcarek M, Sorror M, Pergam SA, Cheng GS, et al. Survival, nonrelapse mortality, and relapse-related mortality after allogeneic hematopoietic cell transplantation: comparing 2003–2007 versus 2013–2017 cohorts. Ann Intern Med. 2020;172(4):229–39. 10.7326/M19-2936.
3. Malard F, Holler E, Sandmaier BM, Huang H, Mohty M. Acute graft-versus-host disease. Nat Rev Dis Primers. 2023;9(1):27. 10.1038/s41572-023-00438-1.
4. Aladağ E, Kelkitli E, Göker H. Acute Graft-Versus-Host Disease: A Brief Review. Turk J Haematol. 2020;37(1):1–4. 10.4274/tjh.galenos.2019.2019.0157.
5. Ferrara JL, Levine JE, Reddy P, Holler E. Graft-versus-host disease. Lancet. 2009;373(9674):1550–61. 10.1016/S0140-6736(09)60237-3.
6. Zeiser R, Blazar BR. Acute Graft-versus-Host Disease - Biologic Process, Prevention, and Therapy. N Engl J Med. 2017;377(22):2167–79. 10.1056/NEJMra1609337.
7. Shimoni A, Rimon U, Hertz M, Yerushalmi R, Amitai M, Portnoy O, et al. CT in the clinical and prognostic evaluation of acute graft-vs-host disease of the gastrointestinal tract. Br J Radiol. 2012;85(1016). 10.1259/bjr/60038597.

8. Kujawska J, Zeiser R, Gil L. Recent advances in acute gastrointestinal graft versus host disease (aGvHD): aspects of steroid-resistant disease. Ann Hematol. 2025;104(2):855–65. 10.1007/s00277-024-05952-0.
9. Mahgerefteh SY, Sosna J, Bogot N, Shapira MY, Pappo O, Bloom AI. Radiologic imaging and intervention for gastrointestinal and hepatic complications of hematopoietic stem cell transplantation. Radiology. 2011;258(3):660–71. 10.1148/radiol.10100025.
10. Schoemans HM, Lee SJ, Ferrara JL, Wolff D, Levine JE, Schultz KR, et al. EBMT-NIH-CIBMTR Task Force position statement on standardized terminology & guidance for graft-versus-host disease assessment. Bone Marrow Transpl. 2018;53(11):1401–15. 10.1038/s41409-018-0204-7.
11. Harris AC, Young R, Devine S, Hogan WJ, Ayuk F, Bunworasate U, et al. International, multicenter standardization of acute graft-versus-host disease clinical data collection: a report from the Mount Sinai Acute GVHD International Consortium. Biol Blood Marrow Transpl. 2016;22(1):4–10. 10.1016/j.bbmt.2015.09.001.
12. Feng Q, Xu F, Guan K, Li T, Sheng J, Zhong W, et al. Diagnostic prediction of gastrointestinal graft-versus-host disease based on a clinical- CT- signs nomogram model. Insights Imaging. 2024;15(1):84. 10.1186/s13244-024-01654-3.
13. Brogna B, Frieri C, Risitiano AM, Urciuoli L, Storti G, Santoro L, et al. Intestinal and extraintestinal findings of graft-versus-host disease on CT: a case series with radiological and histopathological correlations. Biomedicines. 2024;12(7):1516. 10.3390/biomedicines12071516.
14. Brodoefel H, Bethge W, Vogel M, Fenchel M, Faul C, Wehrmann M, et al. Early and late-onset acute GvHD following hematopoietic cell transplantation: CT features of gastrointestinal involvement with clinical and pathological correlation. Eur J Radiol. 2010;73(3):594–600. 10.1016/j.ejrad.2009.01.011.
15. Arpaci T. Computed tomography imaging of acute gastrointestinal graft-versus-host disease after haematopoietic stem cell transplantation in children. Contemp Oncol (Pozn). 2018;22(3):178–83. 10.5114/wo.2018.78932.
16. Kalantari BN, Mortelé KJ, Cantisani V, Ondategui S, Glickman JN, Gogate A, et al. CT features with pathologic correlation of acute gastrointestinal graft-versus-host disease after bone marrow transplantation in adults. AJR Am J Roentgenol. 2003;181(6):1621–5. 10.2214/ajr.181.6.1811621.
17. Ketelsen D, Vogel W, Bethge W, Faul C, Claussen CD, Horger M. CT-analysis of the course of gastrointestinal graft-versus-host disease—patterns of involvement. Eur J Radiol. 2011;79(1):36–41. 10.1016/j.ejrad.2009.12.007.
18. Fernandes T, Oliveira MI, Castro R, Araújo B, Viamonte B, Cunha R. Bowel wall thickening at CT: simplifying the diagnosis. Insights Imaging. 2014;5(2):195–208. 10.1007/s13244-013-0308-y.
19. Uzzaman MM, Alam A, Nair MS, Borgstein R, Meleagros L. Computed tomography findings of bowel wall thickening: its significance and relationship to endoscopic abnormalities. Ann R Coll Surg Engl. 2012;94(1):23–7. 10.1308/003588412x13171221498983.

20. Spijkers S, Staats JM, Littooij AS, Nievelstein RAJ. Abdominal lymph node size in children at computed tomography. Pediatr Radiol. 2020;50(9):1263–70. 10.1007/s00247-020-04715-z.
21. Levine JE, Logan B, Wu J, Alousi AM, Ho V, Bolaños-Meade J, et al. Blood and Marrow Transplant Clinical Trials Network. Graft-versus-host disease treatment: predictors of survival. Biol Blood Marrow Transpl. 2010;16(12):1693–9. 10.1016/j.bbmt.2010.05.019.
22. Styczyński J, Tridello G, Koster L, Iacobelli S, van Biezen A, van der Werf S, et al. Infectious Diseases Working Party EBMT. Death after hematopoietic stem cell transplantation: changes over calendar year time, infections and associated factors. Bone Marrow Transpl. 2020;55(1):126–36. 10.1038/s41409-019-0624-z.

Figures

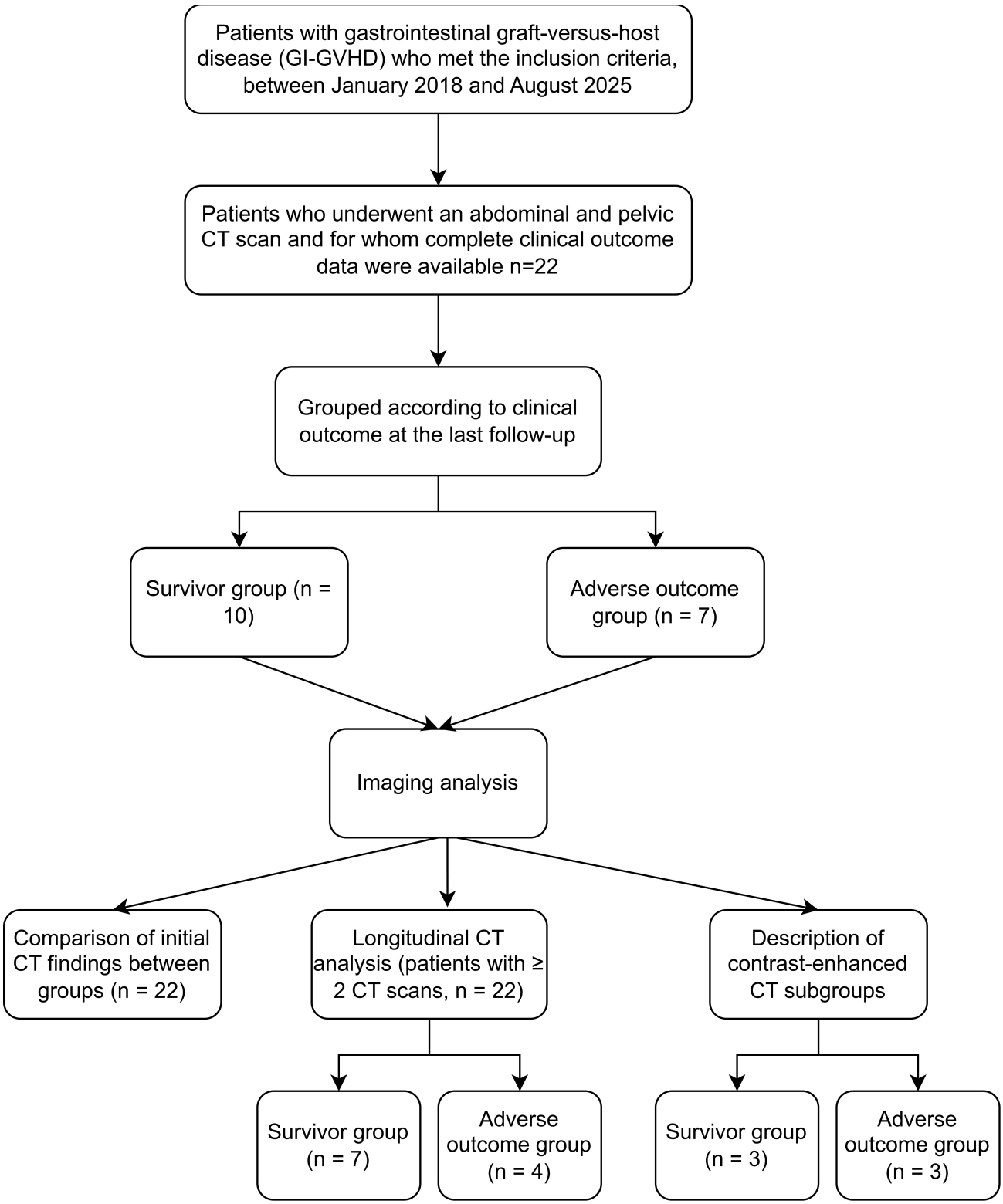

Figure 1

Patient selection, grouping, and imaging analysis of intestinal GVHD after allo-HSCT.

Abbreviations: allo-HSCT, allogeneic haematopoietic stem cell transplantation; GI-GVHD, gastrointestinal graft-versus-host disease.

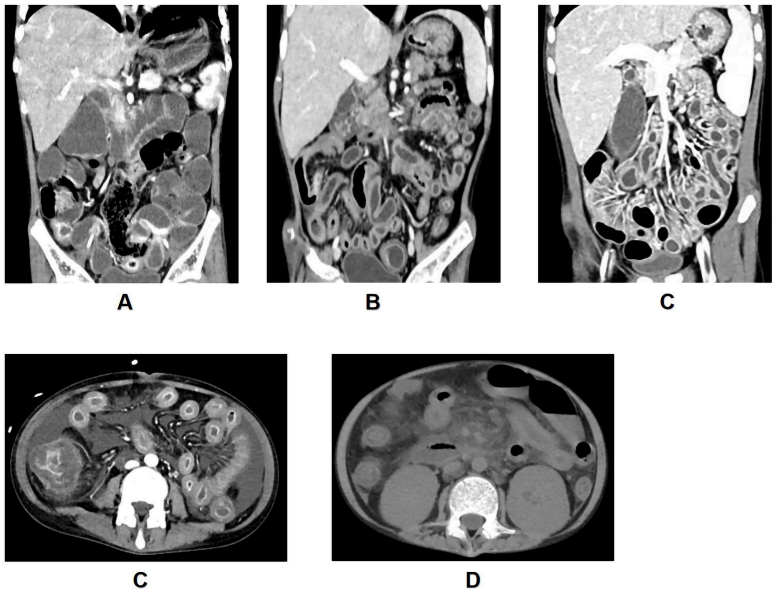

Figure 2

Comparison of the main morphological features on initial abdominal CT scans in patients with intestinal GVHD.

(A) Survival group: localised, non-contiguous bowel involvement. (B) Adverse outcome group: extensive, contiguous involvement of the large and small intestines. (C) Comb sign. (D) Marked thickening of the large intestine wall. (E) Blurred peritoneal fat space.

Abbreviations: CT, computed tomography; GVHD, graft-versus-host disease.

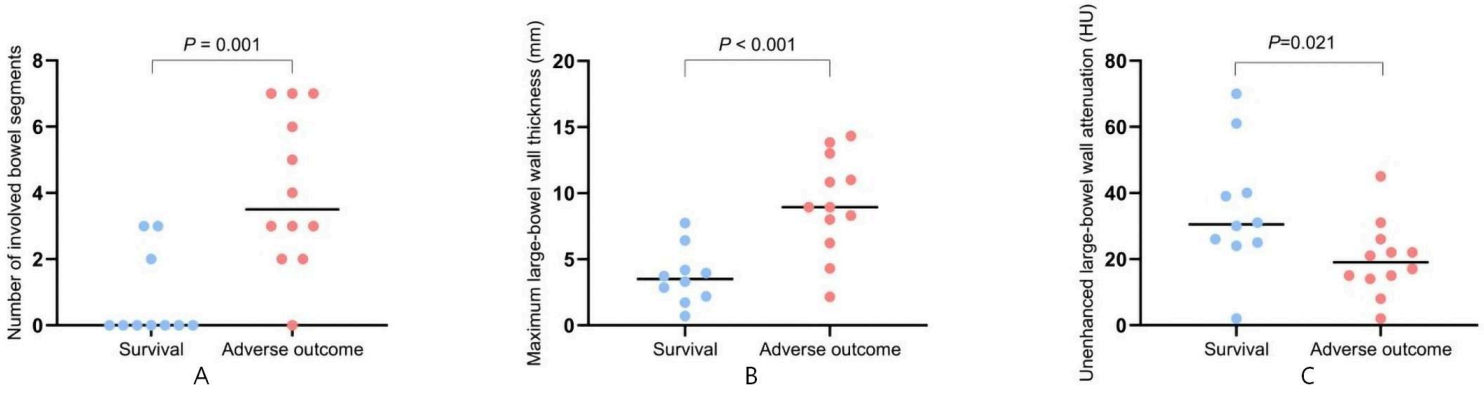

Figure 3

Key quantitative CT findings according to clinical outcome.

Individual patient values are shown for (A) the number of involved bowel segments, (B) maximum large-intestine wall thickness, and (C) large-intestine wall attenuation on unenhanced CT in the survival and adverse outcome groups. Each dot represents an individual patient, and horizontal lines indicate median values. Between-group comparisons were performed using the Mann–Whitney U test, with two-sided exact P values reported.

Abbreviations: CT, computed tomography; HU, Hounsfield unit.

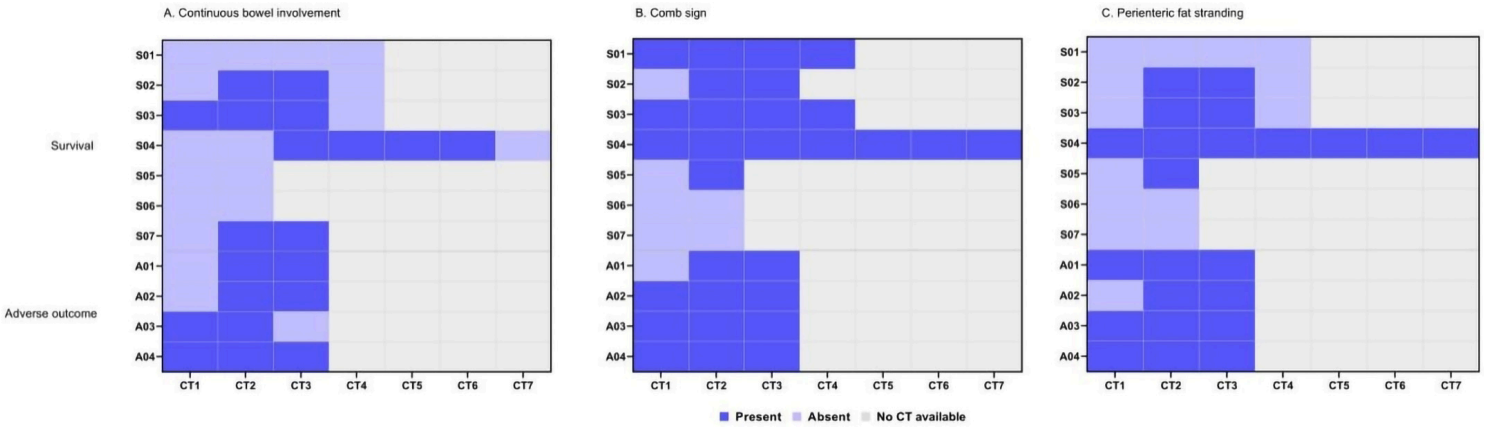

Figure 4

Patient-level longitudinal changes in selected CT findings during follow-up.

Serial changes in CT findings are illustrated for 11 patients with intestinal graft-versus-host disease (GVHD), including seven patients in the survival group and four in the adverse outcome group. All available CT examinations during follow-up were considered, with some patients undergoing up to seven follow-up CT examinations. The longitudinal trajectories illustrate changes in the distribution of involved bowel segments and selected CT findings, including the comb sign and perienteric fat stranding.

Abbreviations: CT, computed tomography; GVHD, graft-versus-host disease.

Supplementary Files

This is a list of supplementary files associated with this preprint. Click to download.

- Table1.docx
- Table2.docx
- Table3.docx
- SupplementaryFigureS1.jpg
- SupplementaryTableS1.docx