Research Square

Preprints are preliminary reports that have not undergone peer review.
They should not be considered conclusive, used to inform clinical practice,
or referenced by the media as validated information.

Thyroglossal Duct Cyst with Extension Through the Thyrohyoid Membrane into the Pre-epiglottic Space: A Case Report

Mohamed Maher Ghrah
Damascus University
Jad Samaan
jadsamaanmd@gmail.com

Damascus University
Alaa Sharekah Hajjar
Damascus University
Fares Al Akabane
Damascus University
Reem Mannoun
Damascus University
Abduljaleel Hammod
Damascus University

Case Report

Keywords: Thyroglossal duct cyst, Pre-epiglottic space, Thyrohyoid membrane, Sistrunk procedure, Case report

Posted Date: November 20th, 2026

DOI: https://doi.org/10.21203/rs.3.rs-11647035/v1

License: This work is licensed under a Creative Commons Attribution 4.0 International License.
Read Full License

Additional Declarations: No competing interests reported.

Abstract

Background

Thyroglossal duct cysts (TGDCs) are the most common congenital neck anomalies, typically presenting in early childhood as midline cervical masses near the hyoid bone. Presentation in late adulthood with atypical intralaryngeal or pre-epiglottic extension through the thyrohyoid membrane is exceedingly rare.

Case presentation:

We report a case of a 48-year-old Middle Eastern male presenting with a 4-cm paramedian neck mass. The patient was of Syrian, Middle Eastern ethnicity. Preoperative contrast-enhanced computed tomography (CT) demonstrated a well-defined cystic mass extending through the thyrohyoid membrane into the pre-epiglottic space without laryngeal mucosal perforation or cartilage erosion. The patient underwent a successful Sistrunk procedure with complete en bloc resection of the cyst, hyoid core, and tract up to the tongue base. Histopathological analysis confirmed a benign thyroglossal duct cyst containing ectopic thyroid follicles. No recurrence was noted at 4 months of follow-up.

Conclusions

This case highlights the importance of cross-sectional imaging and endoscopic assessment in defining deep extension and guiding safe surgical management of atypical TGDCs.

Introduction

Thyroglossal duct cysts (TGDCs) represent the most prevalent congenital anomaly of the neck, accounting for approximately 7% of the general population [1]. These lesions develop due to incomplete obliteration of the embryonic thyroglossal duct during the descent of the thyroid gland from the foramen cecum at the base of the tongue to its definitive anterior lower cervical location [1]. Although TGDCs can arise anywhere along this migratory pathway, the vast majority are situated in the midline near the hyoid bone as smooth, mobile, non-tender masses [1]. The subhyoid (infrahyoid) region is the most frequent anatomical site [2].

Although TGDCs are predominantly diagnosed in pediatric patients under 10 years of age, they may remain clinically silent until adulthood [1]. Presentation in middle-aged or older adults (> 40 years) remains uncommon. Furthermore, deep intralaryngeal or pre-epiglottic extension without a distinct prominent endolaryngeal mucosal defect is extremely rare, with only a limited number of cases reported in the literature [3]. Typically, most TGDCs range from 1.5 to 3 cm in diameter [4]. Secondary complications include acute infection, abscess formation, or development of fistulous tracts [1] .

Ultrasonography (US) serves as the primary non-invasive initial imaging modality [1]. Definitive treatment requires surgical excision via the classic Sistrunk procedure—en bloc resection of the cyst, the central core of the hyoid bone, and a surrounding tissue cuff along the tract up to the base of the tongue—to minimize recurrence [1]. Active infection requires preoperative antimicrobial therapy [1]. Postoperative hormone replacement is rarely warranted, except when the cyst harbors the patient's sole functioning thyroid tissue [1].

Herein, we present a rare case of an adult male over 40 years old presenting with a large (> 3 cm) paramedian TGDC penetrating through the thyrohyoid membrane into the pre-epiglottic space, managed successfully via the Sistrunk procedure.

Case Presentation

A 48-year-old Syrian Middle Eastern male presented to the ENT department complaining of a progressively enlarging, painless midline anterior neck mass noted four months prior. The patient was Middle Eastern ethnicity and was unemployed. He denied dyspnea, dysphagia, hoarseness, local pain, weight loss, or systemic symptoms. He was a current smoker with a 45-pack-year smoking history. His past medical history was unremarkable. His past surgical history was significant for surgery for a testicular hydrocele. There was no relevant family or psychosocial history. He was not taking any regular medications and had no known allergies. He had not undergone previous investigations or treatment for the neck mass elsewhere.

(Fig. 1)

Physical examination revealed a firm, non-tender, mobile cystic mass measuring approximately 3.5–4 cm, situated slightly to the left of the cervical midline overlying the thyrohyoid membrane. The mass demonstrated elevation during deglutition. The overlying skin was freely mobile with no signs of erythema or inflammation (Fig. 1A, B). Flexible fiberoptic laryngoscopy demonstrated a mild bulge of the hypopharyngeal wall with intact overlying endolaryngeal mucosa and fully mobile vocal cords bilaterally. Fine-needle aspiration cytology (FNAC) was not performed.

High-resolution neck ultrasonography showed a well-defined cystic lesion enclosed by a regular wall, filled with turbid contents and focal vascularized internal foci on Doppler examination. Contrast-enhanced CT scans revealed a well-circumscribed, bilobed cystic mass measuring 3 × 4 cm extending from the hyoid bone to the upper border of the thyroid cartilage, shifted leftward. The lesion breached the thyrohyoid membrane into the pre-epiglottic space without erosion of the thyroid cartilage or destruction of the adjacent framework (Fig. 2A, B).

(Fig. 2)

Surgical Management and Postoperative Course

Under general anaesthesia with endotracheal intubation, a transverse cervical incision was made. Intraoperatively, the cyst demonstrated a bilobed structure: one major component was extrinsic to the larynx, while the deeper lobule breached the thyrohyoid membrane, extending directly into the pre-epiglottic space (Fig. 3A, B). The thyroid cartilage and internal laryngeal mucosa remained intact.

Meticulous blunt and sharp dissection allowed complete mobilization and peeling of the cyst wall away from the thyroid cartilage and internal mucosa without mucosal perforation or requirement for laryngeal reconstruction. Superiorly, the tract extended posterior to the hyoid bone toward the tongue base. The central portion of the hyoid bone was resected en bloc with the cyst mass, and the tract was securely ligated at the tongue base.

(Fig. 3)

Gross pathology confirmed two tissue portions measuring 1.2 × 2.7 × 6.5 cm and 0.2 × 1 × 1.2 cm. Histopathological examination demonstrated fibrous cyst wall partially lined by pseudostratified ciliated columnar and focal squamous epithelium, containing ectopic colloid-filled thyroid follicles, confirming a benign thyroglossal duct cyst with no evidence of malignancy (Fig. 4A, B).

(Fig. 4)

On the third postoperative day, the patient developed a localized seroma, given its localized nature, the clinical decision was made to manage it with sterile fine-needle aspiration without surgical re-exploration. Postoperatively, the patient received amoxicillin-clavulanic acid. At the 4-month postoperative follow-up, the patient was completely asymptomatic and expressed satisfaction with the outcome, he had no clinical or endoscopic evidence of recurrence.

(Fig. 5)

Discussion

This case illustrates an unusual anatomical presentation of TGDC in a 48-year-old male, characterized by extension through the thyrohyoid membrane into the pre-epiglottic space, with preservation of the laryngeal framework and mucosa.

Comparative studies of pediatric and adult cohorts indicate that adult TGDCs have a higher prevalence of left-sided deviation, infrahyoid positioning, and larger average dimensions[5]. Our patient's clinical presentation is consistent with these features; however, extension through the thyrohyoid membrane into the pre-epiglottic space represents a distinct anatomical rarity.

The anatomical basis of this trajectory may be related to the variable relationship between the embryological thyroglossal tract and the hyoid bone. An anatomical study of 200 adult laryngeal specimens identified persistent thyroglossal remnants in 7% of cases, with these remnants following courses along the anterior surface, inferior border, or posterior aspect of the hyoid bone [6].

Although extension into the pre-epiglottic or paraglottic spaces has occasionally been reported [7–9], some reported cases were accompanied by thyroid cartilage erosion or true intralaryngeal mucosal involvement [7–9]. In contrast, our patient exhibited extension through the thyrohyoid membrane without cartilage erosion or mucosal perforation, allowing preservation of the laryngeal framework and mucosa.

Ultrasonography provides an initial assessment of cystic morphology and thyroid gland presence [1], whereas cross-sectional imaging (CT or MRI) is essential for mapping atypical extensions and defining anatomical boundaries [10]. In our case, contrast-enhanced CT accurately localized the pre-epiglottic involvement and confirmed the integrity of the thyroid cartilage. Flexible laryngoscopy further confirmed the integrity of the laryngeal mucosa.

FNAC was not performed in our patient. Although FNAC may be considered when there is clinical or radiological suspicion of malignancy, current evidence does not support its routine use in all patients with TGDCs. A retrospective study involving adults and children suggested that TGDC diagnosis may be established on clinical grounds in adult patients, with ultrasonography, with or without FNAC, serving as a supplementary modality [11]. Similarly, a 9-year surgical series proposed reserving FNAC for cases with clinical or ultrasonographic features suggestive of malignancy [12]. In our case, the lesion was predominantly cystic and well circumscribed, without a discrete suspicious solid component. As definitive excision was planned, FNAC was not considered essential before surgery.

The Sistrunk procedure remains the gold standard for the treatment of TGDCs [13]. Surgical technique may vary depending on the extent of laryngeal involvement [9]. For instance, Shaari et al. reported a pre-epiglottic TGDC associated with thyroid cartilage erosion, while the perichondrium remained intact, allowing standard excision without reconstruction. In our case, meticulous dissection enabled complete en bloc excision using the classic Sistrunk procedure without the need for structural repair.

Histopathological evaluation is particularly important in adult patients because malignant transformation of TGDCs, although uncommon, has been reported, most frequently in the form of papillary thyroid carcinoma [14]. In our patient, histopathological examination confirmed ectopic colloid-filled thyroid follicles, with no evidence of atypia or malignancy.

The strengths of this case include the detailed correlation between preoperative imaging, endoscopic findings, and intraoperative anatomy, which allowed precise characterization of the unusual extension and facilitated appropriate surgical planning. Histopathological confirmation further strengthened the diagnosis and excluded malignant transformation. Nevertheless, several limitations should be acknowledged. The short follow-up period of 4 months limits the assessment of long-term recurrence. In addition, as a single case report, these findings cannot be generalized to all TGDCs with deep or atypical extension. Finally, the rarity of this anatomical presentation limits direct comparison with larger series of similar cases.

Conclusion

Thyroglossal duct cysts can present in adults with atypical deep extension into the pre-epiglottic space. Preoperative CT and endoscopic assessment are crucial for defining the precise anatomical relationships. The standard Sistrunk procedure, combined with meticulous dissection, allows complete excision while preserving the laryngeal framework and mucosa, without major morbidity.

Abbreviations

CT
computed tomography
ENT
ear, nose, and throat
FNAC
fine-needle aspiration cytology
H&E
hematoxylin and eosin
MRI
magnetic resonance imaging
TGDC(s)
thyroglossal duct cyst(s)
US
ultrasonography.

Declarations

Ethics approval and consent to participate:

This case report involved a single patient and did not require approval from an ethics committee, in accordance with institutional policy. Written informed consent to participate was obtained from the patient.

Consent for publication:

Written informed consent was obtained directly from the patient for publication of this case report and any accompanying images. A copy of the written consent is available for review by the Editor-in-Chief of this journal.

Funding:

No funding was received for this work.

Author Contribution

M.M.A., J.S., A.S.H., F.A., R.M. and A.H. have all written and revised the manuscript.J.S. supervised the whole process

Acknowledgement

The authors would like to thank Dr. Mohammad Basheer Alameer for his help with writing this paper

Availability of data and materials:

Not applicable.

Competing interests:

The authors declare no competing interests.

References

1. Amos J SA, Shermetaro C. : **Thyroglossal Duct Cyst.** In. Edited by [Internet]. S: Treasure Island (FL): Statpearls; 2025.
2. Kim JM, Park KW, Kim DH, Lee DH: **Thyroglossal Duct Cyst in the Suprasternal Region**. *Ear, Nose & Throat Journal* 2024, **103**(11):NP637-NP639.
3. Bao Y-Y, Ge Y-p, Zhang X-J, Guo Y, Dai L-B, Zhou S-H, Lin W: **Thyroglossal duct cyst with hoarseness as the sole symptom and an intralaryngeal extension masquerading as a laryngeal mass: Clinical experience and literature review**. *Ear, Nose & Throat Journal* 2022, **104**(4).
4. Patigaroo SA, Dar NH, Jallu AS, Ahmad R: **Thyroglossal Duct Cysts: A Clinicosurgical Experience**. *Indian Journal of Otolaryngology and Head & Neck Surgery* 2016, **69**(1):102-107.
5. Lin ST, Tseng FY, Hsu CJ, Yeh TH, Chen YS: **Thyroglossal duct cyst: a comparison between children and adults**. *Am J Otolaryngol* 2008, **29**(2):83-87.
6. Ellis PD, van Nostrand AW: **The applied anatomy of thyroglossal tract remnants**. *Laryngoscope* 1977, **87**(5 Pt 1):765-770.
7. Ng ACW, Yuen HW, Huang XY: **Atypical thyroglossal duct cyst with intra-laryngeal and para-glottic extension**. *Am J Otolaryngol* 2019, **40**(4):601-604.
8. Touati MM, Ammar H: **Intralaryngeal thyroglossal duct cyst**. *Pan African Medical Journal* 2015, **22**.
9. Shaari CM, Ho BT, Som PM, Urken ML: **Large thyroglossal duct cyst with laryngeal extension**. *Head Neck* 1994, **16**(6):586-588.
10. Ward RF, Selfe RW, St Louis L, Bowling D: **Computed tomography and the thyroglossal duct cyst**. *Otolaryngol Head Neck Surg* 1986, **95**(1):93-98.
11. Bhama AR, Smith RJ, Robinson RA, Weigel RJ, Sugg SL, Howe JR, Lal G: **Preoperative evaluation of thyroglossal duct cysts: children versus adults—is there a difference?** *The American Journal of Surgery* 2014, **207**(6):902-906.

12. Mettias B, Cole S, Valsamakis T: **Preoperative investigations in thyroglossal duct cyst surgery: a 9-year experience and proposed practice guide**. *The Annals of The Royal College of Surgeons of England* 2023, **105**(6):554-560.
13. Rohof D, Honings J, Theunisse HJ, Schutte HW, van den Hoogen FJ, van den Broek GB, Takes RP, Wijnen MH, Marres HA: **Recurrences after thyroglossal duct cyst surgery: Results in 207 consecutive cases and review of the literature**. *Head Neck* 2015, **37**(12):1699-1704.
14. Rayess HM, Monk I, Svider PF, Gupta A, Raza SN, Lin HS: **Thyroglossal Duct Cyst Carcinoma: A Systematic Review of Clinical Features and Outcomes**. *Otolaryngol Head Neck Surg* 2017, **156**(5):794-802.

Figures

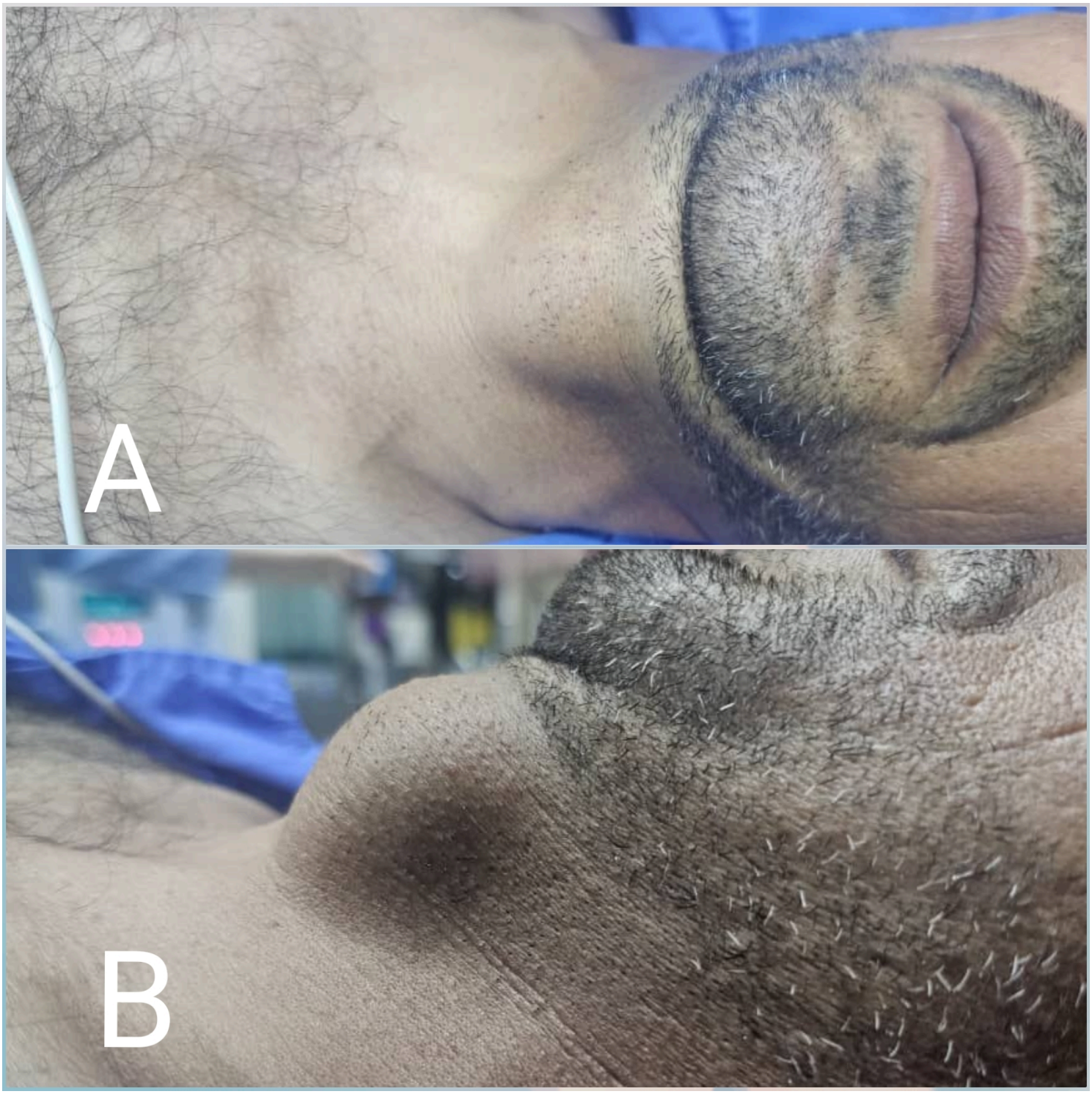

Figure 1

Preoperative clinical photographs (A, B) Prominent anterior cervical swelling located slightly left of the midline, with intact overlying skin and no signs of inflammation.

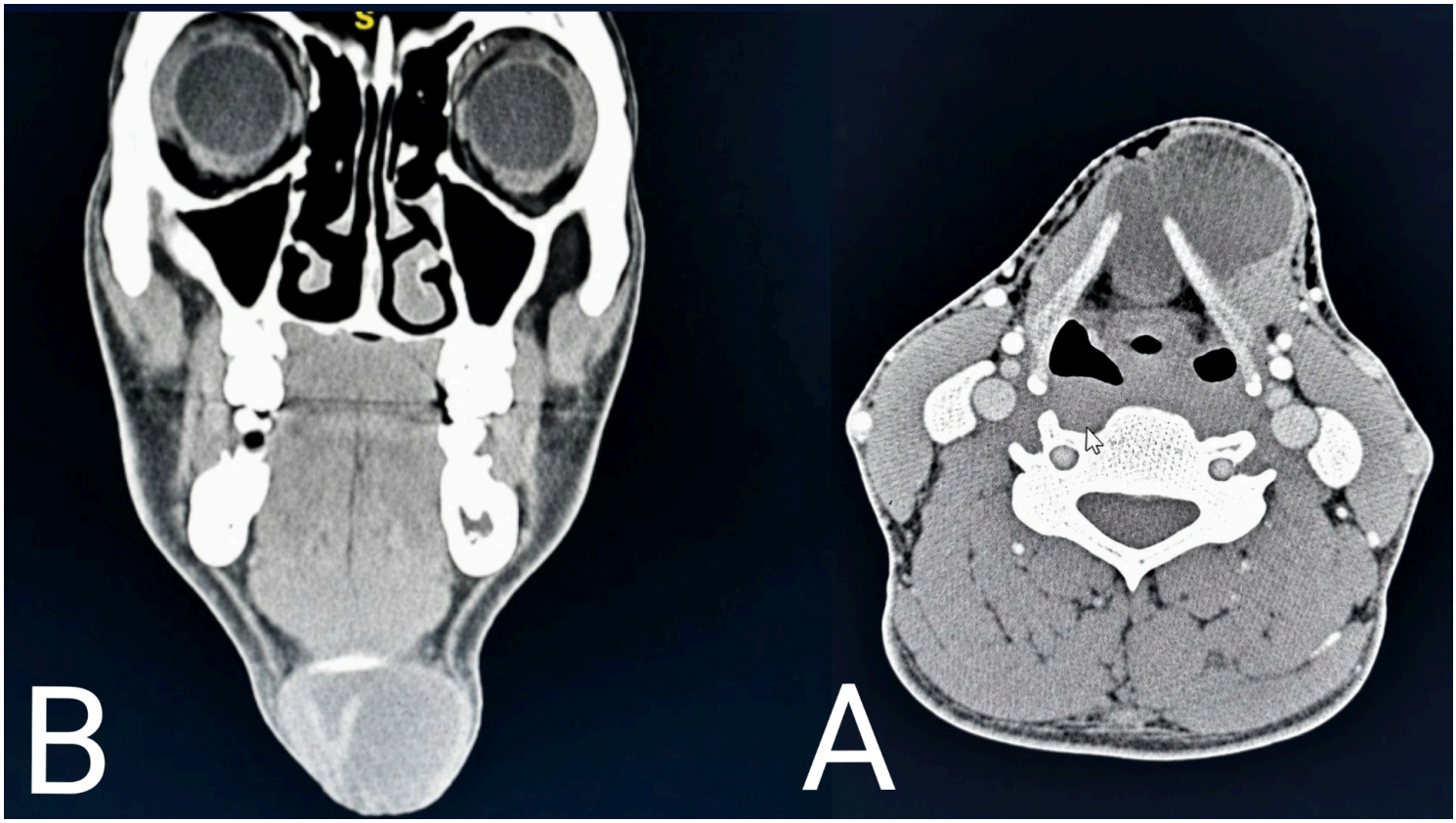

Figure 2

Contrast-enhanced computed tomography (CT) of the head and neck. (A) Axial CT image through the level of the thyroid cartilage demonstrating the cystic lesion with extension into the pre-epiglottic space and preservation of the thyroid cartilage. (B) Coronal CT image demonstrating the craniocaudal extent of the lesion.

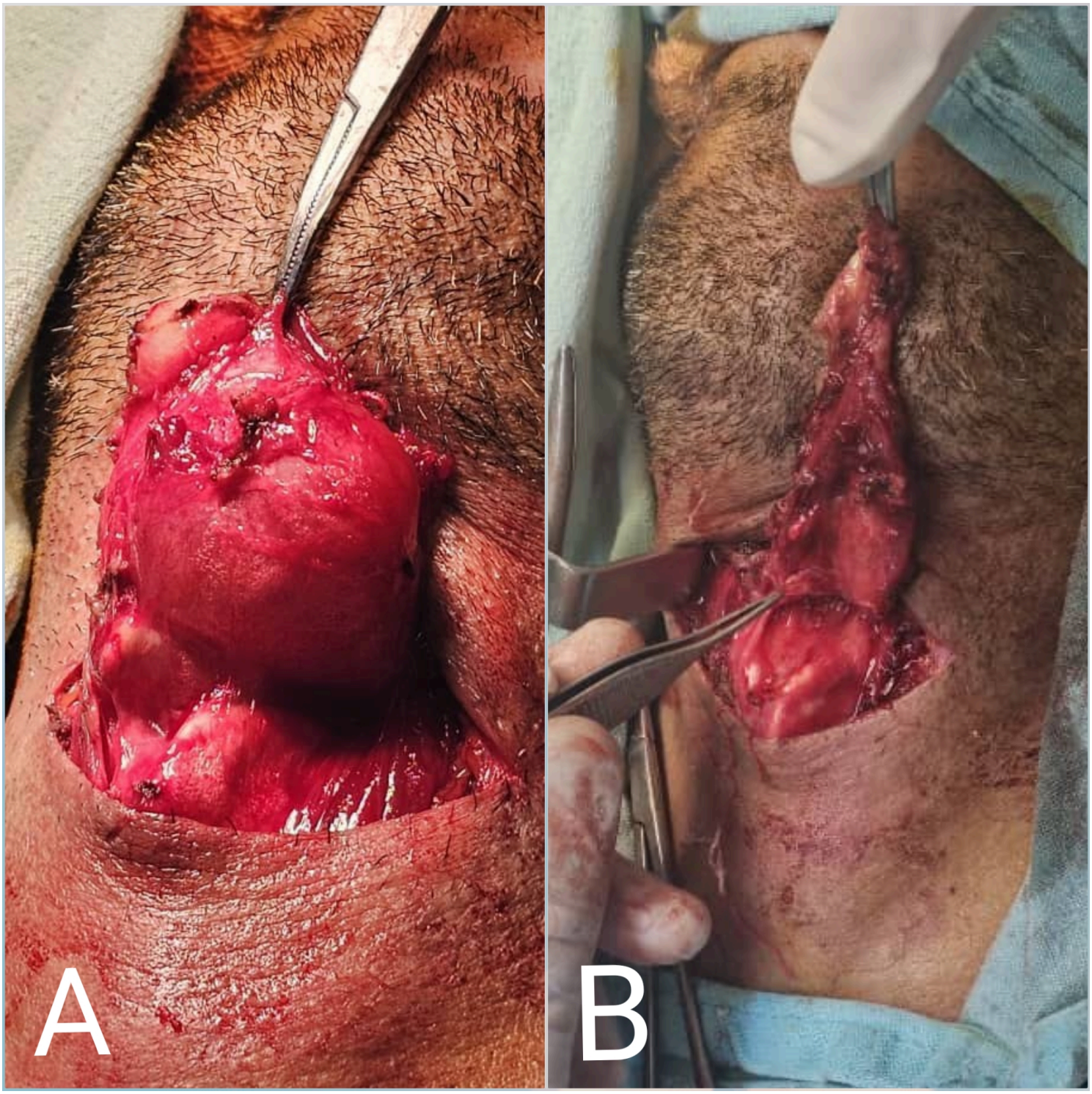

Figure 3

Intraoperative findings. (A) Exposure of the cystic lesion through a transverse cervical incision. (B) intraoperative dissection demonstrating the lesion and its deep extension toward the hyoid bone and pre-epiglottic region.

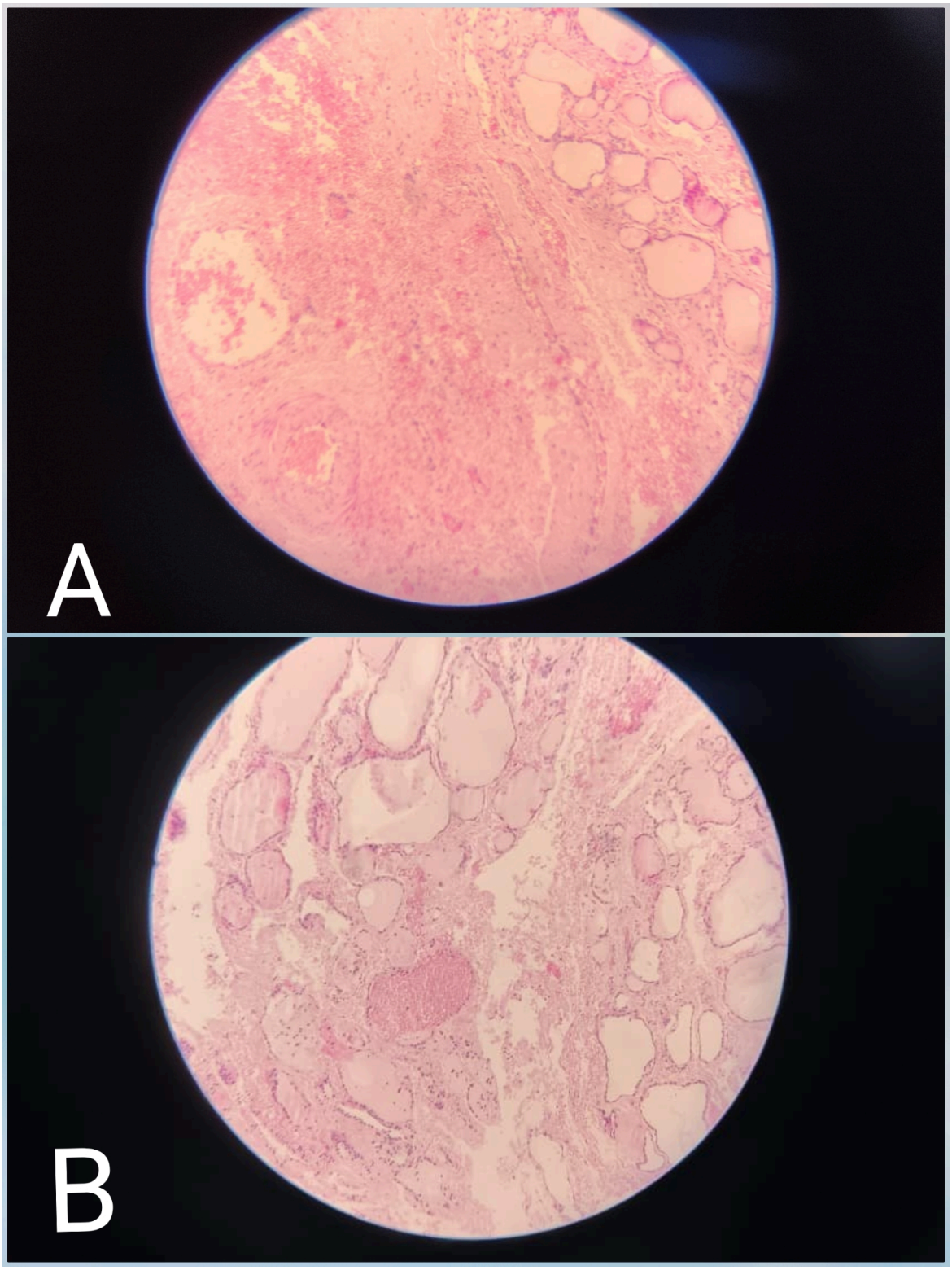

Figure 4

Histopathological examination of the lesion. (A, B) Hematoxylin and eosin (H&E)-stained sections demonstrating fibrous cystic wall with ectopic colloid-filled thyroid follicles, consistent with a benign thyroglossal duct cyst.

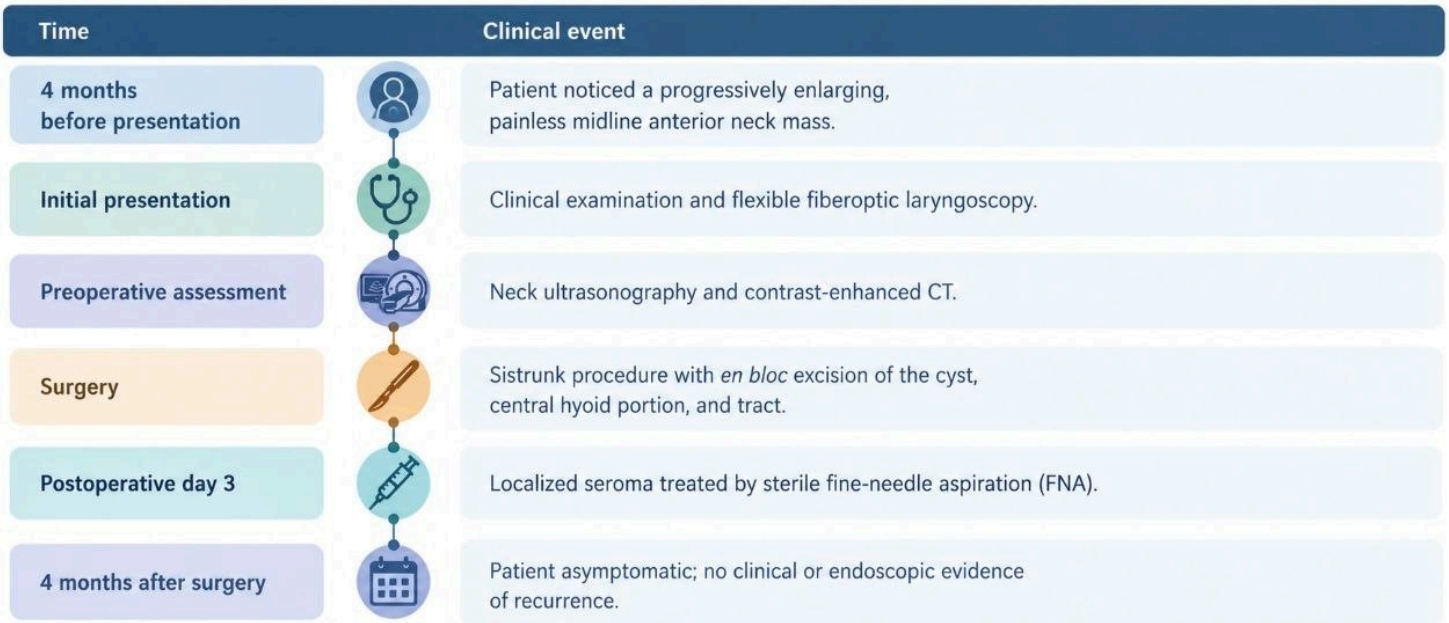

Figure 5

Timeline of the patient's clinical course.