Research Square

Preprints are preliminary reports that have not undergone peer review.
They should not be considered conclusive, used to inform clinical practice,
or referenced by the media as validated information.

Management of Advanced Uterovaginal Prolapse Under Local Anesthesia in a Patient with Complete Atrioventricular Block

Wondu Belayneh Dejene
Hawassa University
Mihiretu Tesfamariam Goshu
michotesfu1@gmail.com

Hawassa University

Case Report

Keywords: Pelvic organ prolapse, Complete atrioventricular (AV) block, Local anesthesia, colpocleisis

Posted Date: November 24th, 2026

DOI: https://doi.org/10.21203/rs.3.rs-11640803/v1

License: This work is licensed under a Creative Commons Attribution 4.0 International License.
Read Full License

Additional Declarations: No competing interests reported.

Abstract

Advanced pelvic organ prolapse can cause significant urinary and bowel dysfunction. Coexisting complete atrioventricular (AV) block with unavailability of temporary and permanent pacing poses significant perioperative anesthetic challenges. Our case involves a 70-year-old para 8 woman who presented with stage 4 uterovaginal prolapse complicated by difficulty defecating and urinary retention. She also had complete atrioventricular block with a ventricular rate of approximately 38 beats per minute, mild valvular regurgitation, and bronchial asthma. Pacemaker insertion was financially unaffordable. Following multidisciplinary assessment and high-risk informed consent, partial LeFort colpocleisis with perineorrhaphy was performed under local anesthesia using lidocaine infiltration with minimal systemic analgesia and continuous cardiorespiratory monitoring. The patient was stable throughout surgery and postoperatively and was discharged without complications. This case highlights the challenges of perioperative decision-making and the potential role of individualized anesthetic planning in resource-limited settings.

Introduction

Pelvic organ prolapse (POP) is a common condition among older women, resulting from weakening of the pelvic floor support structure(1). Advanced prolapse may cause urinary and bowel symptoms, including constipation, and obstructive uropathy (2). Surgery may be necessary in a woman with severe symptoms.

Complete atrioventricular (AV) block, also called third-degree AV block, is a cardiac conduction disorder characterized by the absence of electrical conduction from the atria to the ventricles (3). It can cause significant perioperative challenges because anesthesia-induced changes in heart rate, cardiac contractility, and vascular resistance could result in severe bradycardia and hemodynamic instability (5, 6). Permanent cardiac pacing is generally recommended for complete AV block after reversible causes have been ruled out (3). Although cardiac pacing is generally recommended in patients with acquired complete AV block, access to pacing services may be limited in resource-constrained settings. We report a case of stage 4 symptomatic uterovaginal prolapse with complete AV block managed by partial LeFort colpocleisis under local anesthesia in a setting where pacing was unavailable. This case highlights the challenges of individualized perioperative management when cardiac pacing is inaccessible and the importance of multidisciplinary assessment in balancing surgical benefits against cardiovascular risks.

Case Presentation

A 70-year-old para 8 woman, with a history of eight previous vaginal deliveries, presented with a 10-year history of a progressively worsening protruding mass through the vagina. The prolapse had gradually increased in size and had become increasingly symptomatic.

For the past 3 months, she had experienced intermittent difficulty with urination associated with painful urinary retention. She also reported constipation and difficulty with defecation, which improved with

manual perineal support.

She had a 5-year history of bronchial asthma managed with a salbutamol inhaler as needed and cardiac disease diagnosed approximately one year before presentation. Cardiology consultation confirmed complete atrioventricular block with severe bradycardia (38 beats/min), and permanent pacemaker implantation was recommended; however, the procedure was financially unaffordable to the patient. She had no history of previous surgery, syncopal attacks, exertional dyspnea, fever, or other symptoms suggestive of acute infection.

Physical Examination

General Examination

• The patient was conscious and clinically stable.

Her blood pressure was 135/85 mmHg, pulse rate 38 beats/min and irregular, respiratory rate 18–24 breaths/min, oxygen saturation 94% on room air, and temperature 36.8 ℃. Cardiovascular examination revealed severe bradycardia with irregular peripheral pulses, without audible murmur or gallop. Respiratory examination showed scattered bilateral wheezing throughout the lung fields. Abdominal and neurological examination were unremarkable. Pelvic examination revealed partially reducible stage 4 uterovaginal prolapse, with the uterus and vaginal walls completely protruding beyond the vaginal introitus. No evidence of acute infection or ulceration. POPQ (pelvic Organ Prolapse Quantification system) Staging

Aa = + 3cm; Ba = + 9cm; C = + 10cm

Gh=6cm; Pb=2cm; TVL= 10cm

Ap = + 1cm; Bp = + 7cm; D = + 7cm

Investigations

Electrocardiography showed complete (third-degree) AV block with atrioventricular dissociation and a ventricular escape rhythm of approximately 38 beats/min

(Fig. 1**).** Echocardiography revealed degenerative valvular changes with mild aortic and mitral regurgitation. Chest radiography was normal. Complete blood count, serum electrolytes, renal function tests, and liver function tests were within the normal range.

The final diagnosis was symptomatic stage 4 uterovaginal prolapse with complete AV block and severe bradycardia in a patient with bronchial asthma

Preoperative assessment and Anesthesia management

Given the patient's complete AV block, severe bradycardia, and lack of access to temporary or permanent cardiac pacing, the surgical and anesthesia team considered both neuraxial and general anesthesia to carry a significant risk of hemodynamic compromise. The patient's long-standing stage 4 uterovaginal prolapse, complicated by urinary retention and defecatory difficulty, which significantly affect her quality of life, led us to decide on surgery despite the cardiovascular risk. Following multidisciplinary assessment, discussion of the anticipated risks, and high-risk informed consent, the team decided to proceed with partial LeFort colpocleisis and perineorrhaphy under local anesthesia with minimal systemic analgesia. The patient agreed to an obliterative procedure that prevents future penetrative vaginal intercourse.

Before transferring the patient to the operating room, the team performed a salbutamol challenge (6 puffs) because of bilateral wheezing, and the wheezing improved after bronchodilator therapy. In the operating room, we established continuous cardiorespiratory monitoring and subsequently performed an atropine challenge. We administered atropine intravenously at 1mg, with 1mg repeat doses over 5 minutes, for a cumulative dose of 2 mg. Heart rate did not significantly increase despite escalating doses of atropine, suggesting poor chronotropic responsiveness. Emergency cardiovascular support, including a defibrillator, inotropes, and vasopressors, was prepared.

After 50µg fentanyl was given for analgesia. Local anesthesia was administered using topical 2% lidocaine cream and infiltration with 20 mL of 1% lidocaine containing adrenaline, diluted with normal saline.

Procedure Done:

The patient was placed in lithotomy position; perineum, medial thighs, and lower abdomen were prepared with povidone-iodine and draped. Topical lidocaine 2% was applied to the prolapse, perineum, vulva, mons pubis, and medial thighs, followed by infiltration with 20ml lidocaine with adrenaline, after dilution with normal saline. The surgeon performed a partial LeFort colpocleisis by dissecting the anterior and posterior vaginal mucosa while preserving approximately 3 cm of lateral vaginal mucosa and the mucosa covering the cervix. The preserved lateral vaginal mucosa was used to create a drainage channel. The vaginal canal was subsequently obliterated using five circumferential sutures with 2 – 0 polyglactin (Vicryl). Then a diamond incision was made over the perineum and distal posterior vaginal mucosa, and perineorrhaphy was done by plicating the levator ani muscles and transverse perineal muscles, followed by approximation of vaginal mucosa and the perineal skin.

Intraoperative and postoperative course:

Throughout the procedure, the patient remained clinically and hemodynamically stable. Her heart rate ranged from 37–40 beats/min, respiratory rate from 16–26 breaths/min, blood pressure from 120–

150/80–100 mmHg, and oxygen saturation from 92–96%. The operative duration was 40 minutes, with an estimated blood loss of 150ml. Postoperatively, the patient was followed in the ward, where her vital signs remained stable. Foley Catheter was removed, and oral feeding started four hours after surgery.

Diclofenac 75mg intramuscular twice daily and paracetamol 1g four times daily were administered to control post-operative pain. After 36 hours, analgesia was reduced to oral paracetamol 1g as needed because of improved pain control. The postoperative course was uneventful, and she was discharged home after 48 hours with planned follow-up by an internal medicine and gynecology team.

Follow-up Visit

At the third-week postoperative follow-up, she reported complete resolution of the vaginal bulge, urinary retention, and defecatory difficulty. She also denied leaking urine with coughing. She reported that every symptom has now disappeared after surgery. The favourable short-term outcome demonstrated successful anatomical symptom relief following partial LeFort colpocleisis under local anesthesia, despite the patient's underlying unpaced complete atrioventricular block.

Discussion

This case describes the management of stage 4 pelvic organ prolapse and coexisting complete AV block in an elderly woman. Because complete AV block is a clinically significant conduction abnormality, perioperative cardiovascular assessment is important before non-cardiac surgery (4). The main challenge in this case was the patient's complete AV block, which resulted in a ventricular rate of 38 beats/min. In complete heart block, cardiac output depends on stroke volume, so anything that lowers preload or systemic vascular resistance, such as sympathetic blockade from a neuraxial technique or the vasodilatory effects of general anesthetic agents, cannot be offset by a rise in heart rate. The failed atropine challenge in this case suggests poor responsiveness to pharmacological chronotropic stimulation and atropine's limited efficacy in the blockade below the AV node (7). The American College of Cardiology guidelines recommend pacing for complete AV block (3)but in this patient, financial constraints limit access to pacemaker treatment. As a result, the clinical team had to balance the symptomatic nature of prolapse against the significant cardiovascular risk and the limited availability of resources.

Local infiltration with a minimal opioid dose, as used here, preserved sympathetic tone and hemodynamic stability. We used adrenaline in the local anesthetic cautiously and prepared emergency support in advance. Choosing a partial LeFort colpocleisis procedure kept the operation short and limited physiological stress (8). This case highlights how limited access to advanced cardiovascular interventions can influence surgical and anesthetic decision-making in low-resource settings.

A prior report described the development of complete atrioventricular block during general and spinal anesthesia, highlighting that anesthesia may cause serious conduction abnormalities (5). In contrast, our patient already had complete AV block before surgery and underwent partial colpocleisis under local

anesthesia with minimal systemic analgesia. Therefore, this case adds to the limited literature by demonstrating an individualized approach to noncardiac surgery in a patient with unpaced complete AV block when pacing was unavailable.

This case demonstrates the feasibility of performing partial colpocleisis under local anesthesia with minimal systemic analgesia in carefully selected patients. Local anesthesia with systemic analgesia and intensive monitoring may be considered when conventional anesthesia options are deemed to pose significant risks.

Conclusion

Partial LeFort colpocleisis under local anesthesia with minimal systemic analgesia, multidisciplinary planning, and continuous monitoring was feasible and well tolerated in an elderly woman with stage 4 prolapse and unpaced complete heart block. This approach may benefit similar high-risk patients in resource-limited settings, though pacemaker implantation remains the definitive treatment for complete AV block.

Strengths and limitations

The case shows a practical strategy where pacing is unavailable. As a single case, it cannot establish general safety.

Patient perspective

After my surgery, I am finally free from the constant protrusion of mass from vagina and difficulty urinating that had embarrassed me for ten years.

Declarations

Abbreviations

AV Atrioventricular

POP Pelvic organ prolapse

POPQ Pelvic Organ Prolapse Quantification

PRN pro re nata (as needed)

Ethics approval and consent to participate:

Because this case report presents a retrospective case of routine clinical care and does not involve any experimental intervention or identifiable patient data beyond those required for diagnosis and treatment, the need for ethics approval was waived by the Department of Obstetrics and Gynecology Clinical

Research Ethics Committee, Hawassa University Comprehensive Specialized Hospital. The study was performed in accordance with the Declaration of Helsinki. Written informed consent was obtained from the patient for participation in the case study.

Consent for publication:

Written informed consent was obtained from the patient for participation and publication of her clinical information.

Conflicts of Interest:

The authors declare that they have no conflicts of interest related to this case report.

Clinical Trial Number

Not applicable

Funding:

The authors did not receive support from any organization for the submitted work.

Author Contribution

W.B. and M.G. both wrote the main manuscript text. W.B prepared the figures. M.G and W.B reviewed the case report.

Acknowledgement

The authors would like to thank the patient and healthcare professionals involved in the management.

Data availability:

All data generated or analysed during this study are included in this published article.

References

1. Vergeldt TFM, Weemhoff M, IntHout J, Kluivers KB. Risk factors for pelvic organ prolapse and its recurrence: a systematic review. Int Urogynecol J. 2015;26(11):1559–73. 10.1007/s00192-015-2695-8.

2. AlSary S, Al-Zahrani EF, Al Baalharith M. Vesical Calculi and Female Pelvic Organ Prolapse: A Case Report and Literature Review. Cureus 15(9):e44578. 10.7759/cureus.44578
3. Kusumoto FM, Schoenfeld MH, Barrett C, et al. 2018 ACC/AHA/HRS Guideline on the Evaluation and Management of Patients With Bradycardia and Cardiac Conduction Delay: A Report of the American College of Cardiology/American Heart Association Task Force on Clinical Practice Guidelines and the Heart Rhythm Society. Circulation. 2019;140(8):e382–482. 10.1161/CIR.0000000000000628.
4. Members WC, Thompson A, Fleischmann KE, et al. 2024 AHA/ACC/ACS/ASNC/HRS/SCA/SCCT/SCMR/SVM Guideline for Perioperative Cardiovascular Management for Noncardiac Surgery: A Report of the American College of Cardiology/American Heart Association Joint Committee on Clinical Practice Guidelines. J Am Coll Cardiol. 2024;84(19):1869–969. 10.1016/j.jacc.2024.06.013.
5. Hofer CK, Lang D, Suhner M, Straumann E, Zollinger A. [Complete heart block after spinal and general anaesthesia]. Anaesthesist. 2003;52(4):326–8. 10.1007/s00101-003-0457-3.
6. Mamiya K, Aono J, Manabe M. Complete atrioventricular block during anesthesia. Can J Anaesth J Can Anesth. 1999;46(3):265–7. 10.1007/BF03012607.
7. Hines RL, Jones SB. Stoelting's Anesthesia and Co-Existing Disease E-Book: Stoelting's Anesthesia and Co-Existing Disease E-Book. Elsevier Health Sciences; 2021.
8. Zebede S, Smith AL, Plowright LN, Hegde A, Aguilar VC, Davila GW. Obliterative LeFort colpocleisis in a large group of elderly women. Obstet Gynecol. 2013;121(2 Pt 1):279–84. 10.1097/AOG.0b013e31827d8fdb.

Figures

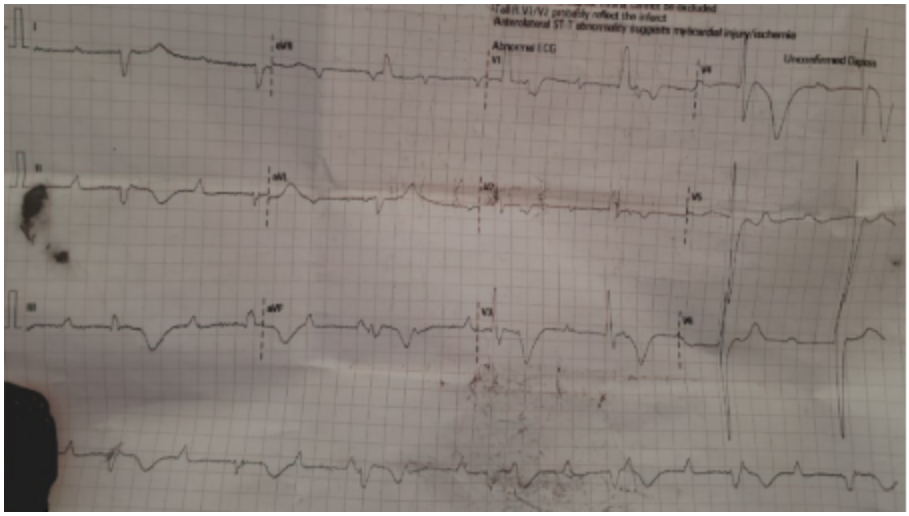

Figure 1

Complete (3rd-Degree) Atrioventricular (AV) Block with a slow ventricular escape rhythm (~38 bpm).