Research Square

Preprints are preliminary reports that have not undergone peer review.
They should not be considered conclusive, used to inform clinical practice,
or referenced by the media as validated information.

Simultaneous bilateral grade III diffuse lamellar keratitis after SMILE: a case report

Wenyan Wang
Leshan People's Hospital
Jiao Zhao
273703225@qq.com

Leshan People's Hospital
Budan Hu
Leshan People's Hospital
Yan He
Leshan People's Hospital

Case Report

Keywords: Diffuse lamellar keratitis, small-incision lenticule extraction, bilateral, interface irrigation, sterile inflammation

Posted Date: November 23rd, 2026

DOI: https://doi.org/10.21203/rs.3.rs-11631783/v1

License: This work is licensed under a Creative Commons Attribution 4.0 International License.
Read Full License

Additional Declarations: No competing interests reported.

Title page

Simultaneous bilateral grade III diffuse lamellar keratitis after SMILE: a case report

Wenyan Wang[1] , Jiao Zhao[1*] , Budan Hu[1] , Yan He[1]

[1] Leshan People's Hospital, Leshan, Sichuan, China

*Corresponding Author: Jiao Zhao, MD, E-mail: 273703225@qq.com

Abstract

Background: We report a case of simultaneous bilateral grade III diffuse lamellar keratitis (DLK) after small-incision lenticule extraction (SMILE).

Case presentation: A 23-year-old man underwent uneventful bilateral SMILE for myopia correction. On postoperative day 1, slit-lamp examination revealed bilateral grade III DLK involving the central visual axis. Initial treatment consisted of topical dexamethasone eye drops, dexamethasone ophthalmic ointment, topical antibiotics, and artificial tears. However, no meaningful clinical improvement was observed on postoperative days 2 and 3. Therefore, bilateral interface irrigation was performed on postoperative day 3, followed by intensive topical corticosteroid and antibiotic therapy. By postoperative day 4, corneal clarity had improved substantially in both eyes. At 1 month, both corneas remained clear, with an uncorrected distance visual acuity of 20/16 in each eye.

Conclusions: Simultaneous bilateral grade III DLK may develop after uncomplicated SMILE. When interface DLK shows no response to corticosteroids within 48 hours, irrigation should be considered promptly.

Keywords：Diffuse lamellar keratitis; small-incision lenticule extraction; bilateral; interface irrigation; sterile inflammation

Background

Diffuse lamellar keratitis (DLK) was first described after laser-assisted in situ keratomileusis (LASIK) in 1998[1]. DLK is an idiopathic sterile inflammatory reaction characterized by diffuse infiltration of inflammatory cells within the lamellar corneal interface. Small incision lenticule extraction (SMILE) is a minimally invasive, flapless refractive procedure associated with rapid visual recovery and reduced surgical trauma, and it has gained widespread acceptance among patients seeking spectacle independence[2]. DLK can also occur after SMILE[3-5], although reported incidences vary, and grade III disease or higher remains exceptionally uncommon[3,6]. Although bilateral DLK may occur, most cases demonstrate interocular asymmetry, and simultaneous bilateral grade III DLK has not been described after SMILE to date. We report a patient who developed bilateral grade III DLK on postoperative day 1 after uncomplicated SMILE.

Case Report

A 23-year-old man presented in January 2025 seeking corneal refractive surgery for long-standing myopia. Preoperative examination showed the following findings :

In the right eye, manifest refraction was −3.50/−1.25×5, with a corrected distance visual acuity (CDVA) of 20/16. Corneal topography showed keratometric values of 40.10 D and 41.50 D, and the central corneal thickness was 581μm. In the left eye, manifest refraction of −3.25/−1.00×175, with a CDVA of 20/16. Corneal keratometry was 39.80 D and 41.50 D, and the central corneal thickness was 585μm. Intraocular

pressuer (IOP) was 15 mmhg in the right eye and 14 mmhg in the left eye. Anterior and posterior segment examinations were unremarkable in either eye, and preoperative slit-lamp examination showed no lid margin abnormalities, meibomian gland dysfunction, or ocular surface disease. Bilateral SMILE was performed using the VisuMax femtosecond laser system (Carl Zeiss Meditec AG, Jena, Germany). The surgical procedures were completed uneventfully.

On postoperative day 1, the patient reported slightly blurred vision in both eyes. He had an uncorrected distance visual acuity (UDVA) of 20/20 bilaterally. Slit-lamp examination showed extensive grey-white, fluffy to plaque-like interface opacities in both eyes, densest over the central visual axis with relative sparing of the periphery. Based on these findings, bilateral grade III DLK after SMILE was diagnosed. Treatment was initiated with topical 0.1% dexamethasone eye drops four times daily, 0.1% dexamethasone ophthalmic ointment at night, 0.5% levofloxacin eye drops four times daily, and artificial tears four times daily. Close follow-up was scheduled.

On postoperative day 2, the patient continued to report blurred vision. The UDVA remained 20/20 in both eyes. Slit-lamp examination showed no appreciable change from the previous day (Fig.1). The patient was instructed to return the following day for further evaluation, and interface irrigation was considered if the condition failed to improve.

1

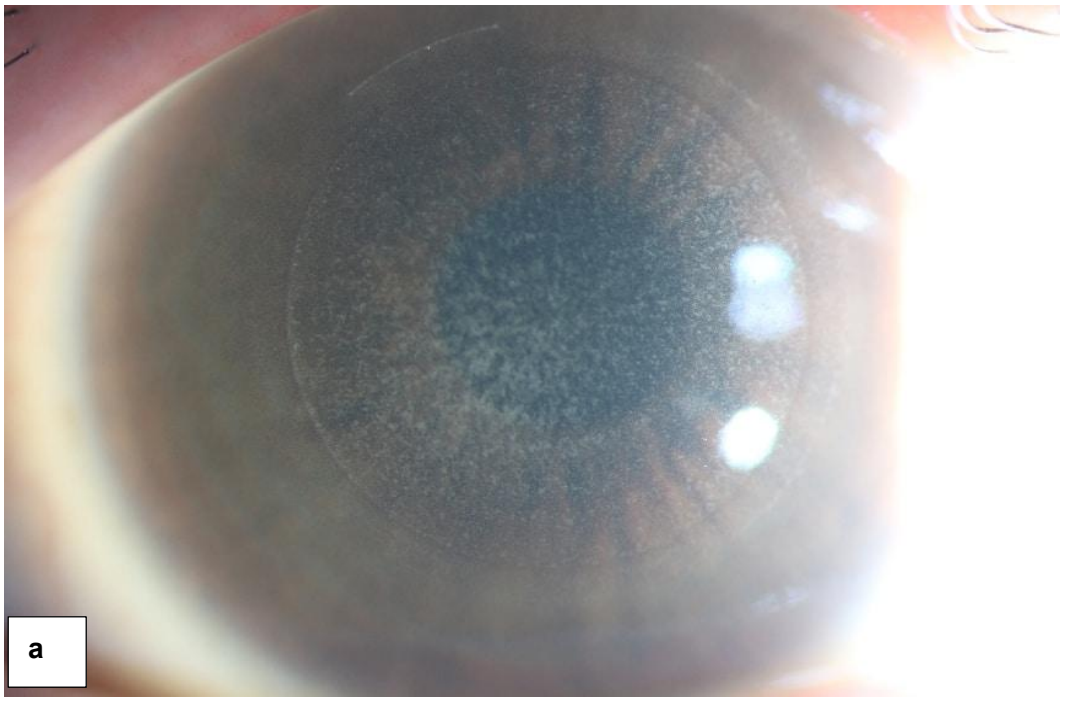

2



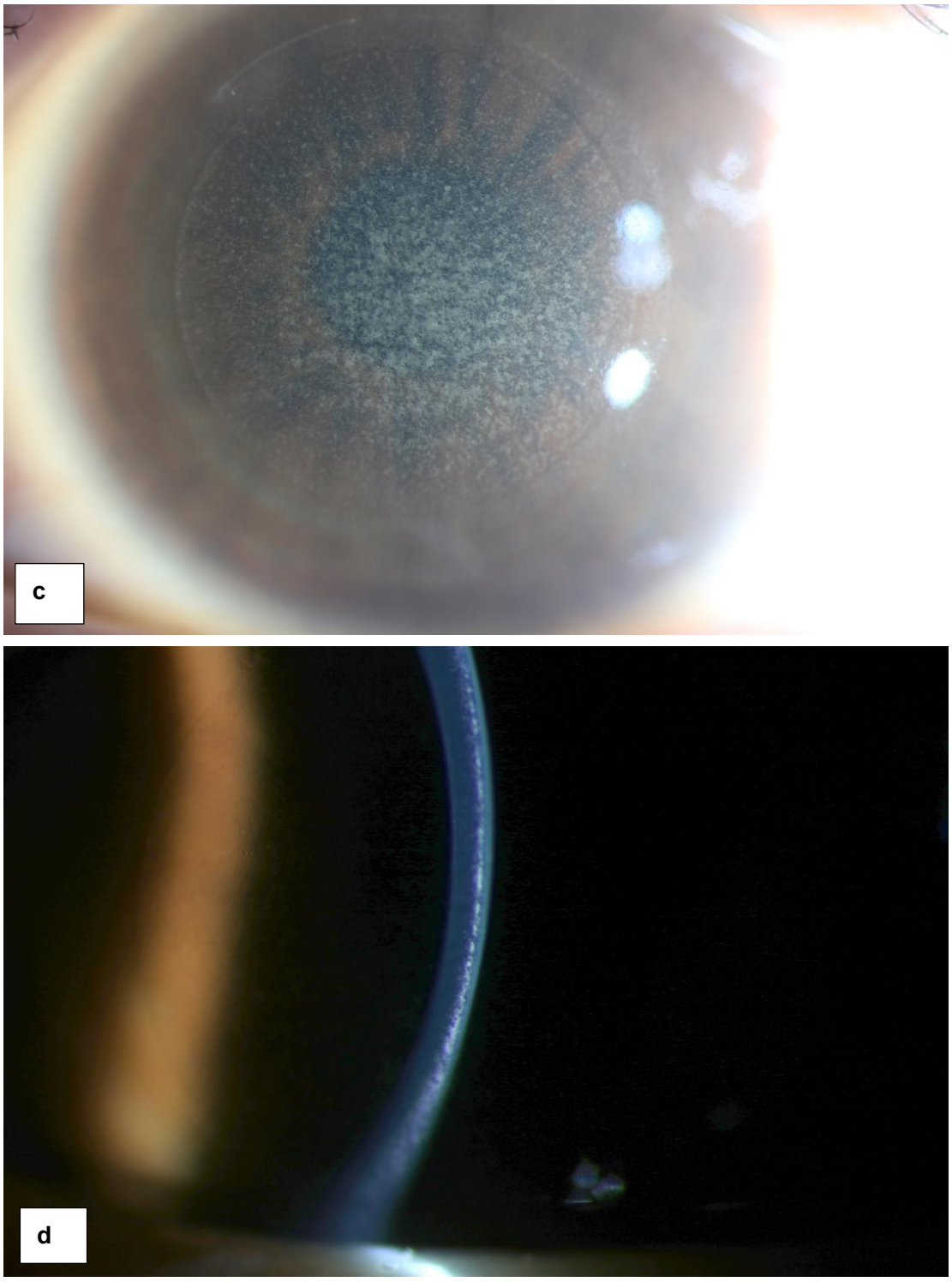

Fig 1. The slit-lamp images obtained on postoperative day 2 showing biliateral grade III diffuse lamellar keratitis. Panels a and b show the right eye; panels c and d show the left eye.

On postoperative day 3, the corneal interface inflammation showed no improvement

(Fig.2). Anterior segment optical coherence tomography (AS-OCT) was performed and showed a hyperreflective interface band without any optically empty space (Fig.3). Because there had been no response to intensive corticosteroid treatment, bilateral interface irrigation was performed using irrigation solution prepared from 500 mL of balanced salt solution and 5 mg of dexamethasone. Intraoperatively, copious mucus-like material was irrigated from the bilateral corneal interfaces. We submitted the sample for biochemical testing, revealing abundant proteinaceous content and no other identifiable abnormalities.

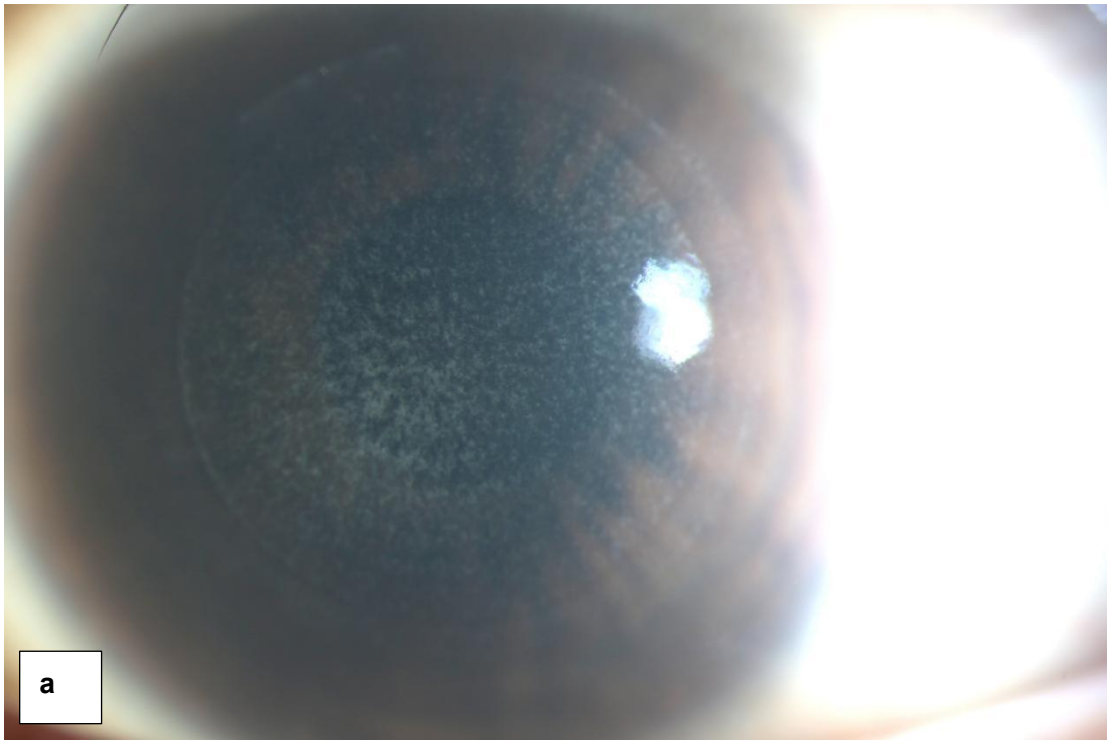

1

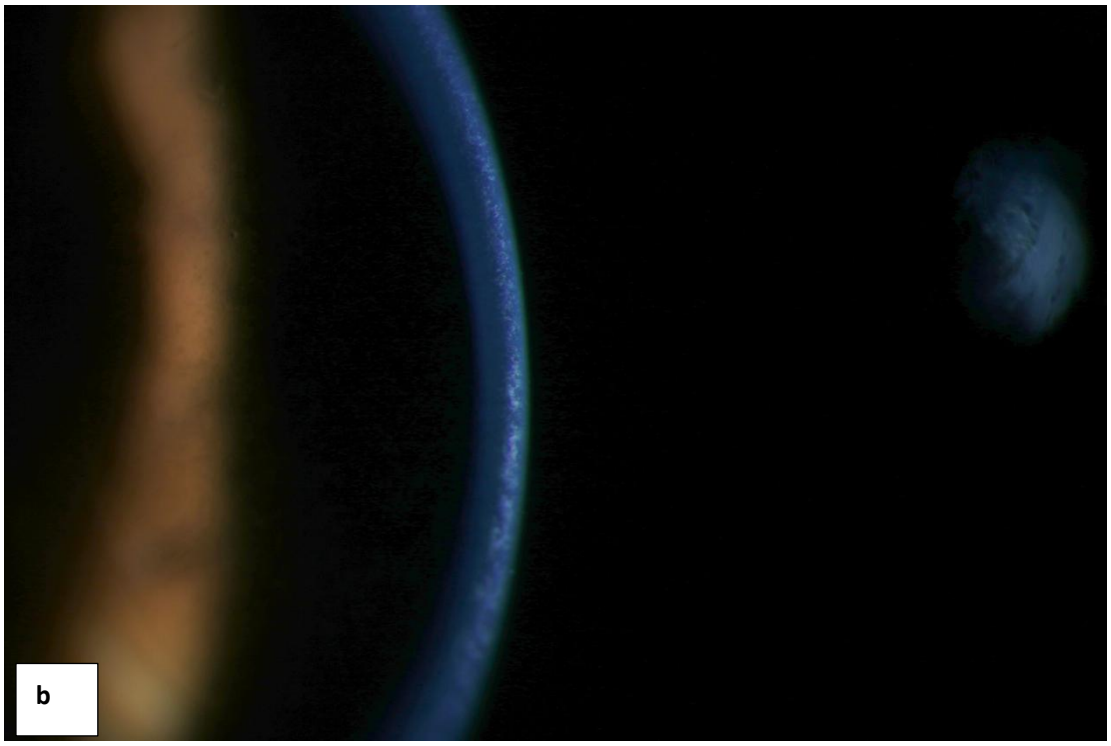

2

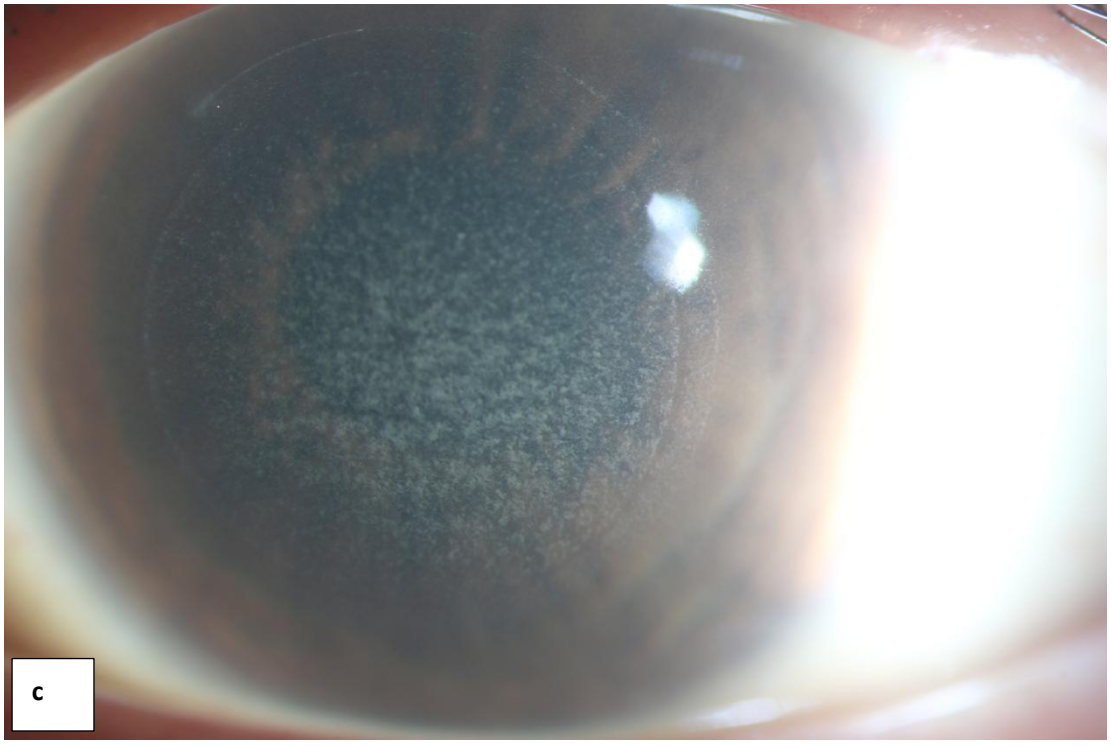

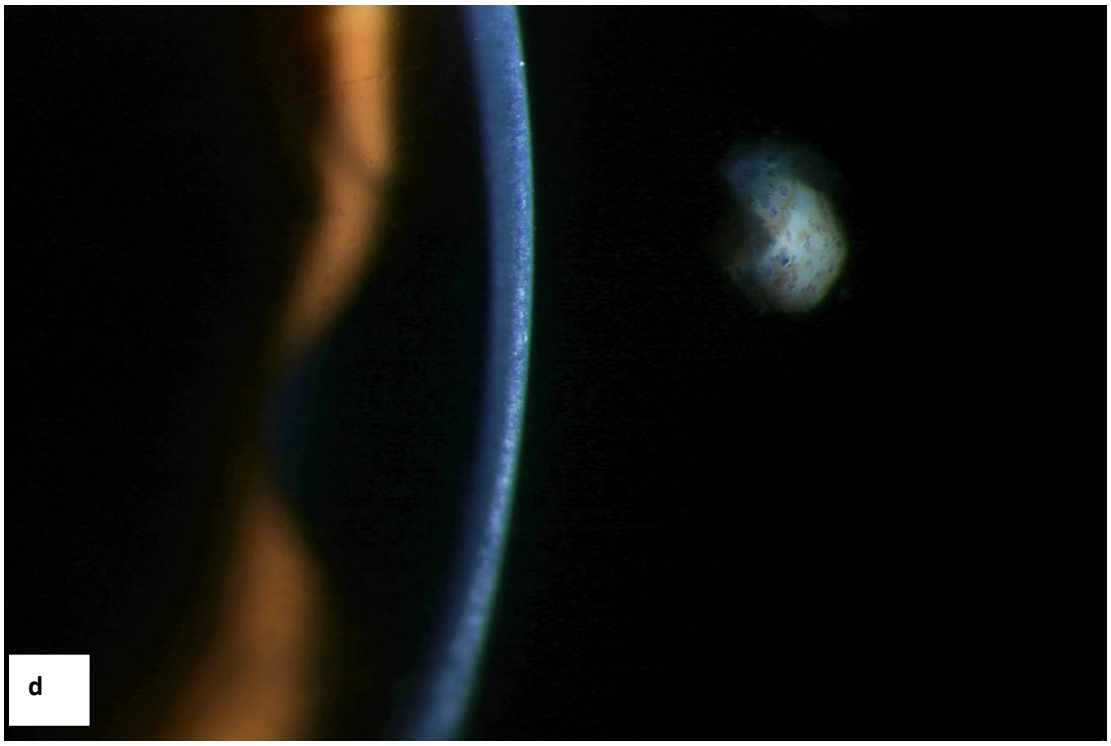

Fig 2. The slit-lamp images obtained on postoperative day 3 demonstrating no apparent improvement in bilateral interface inflammation. Panels a and b show the right eye; panels c and d show the left eye.

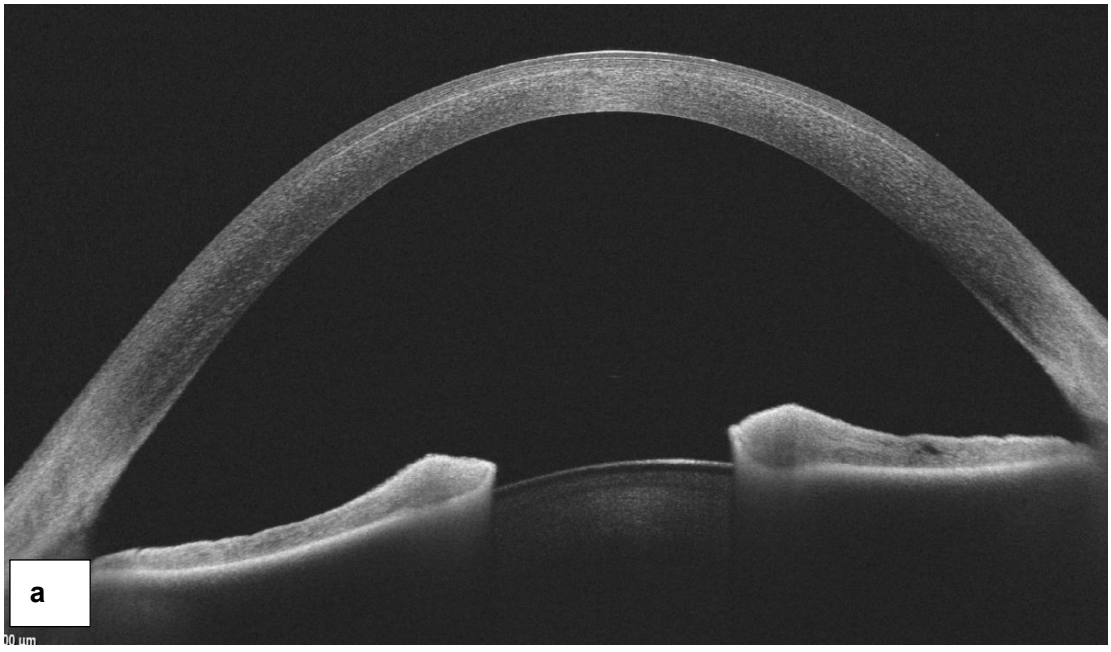

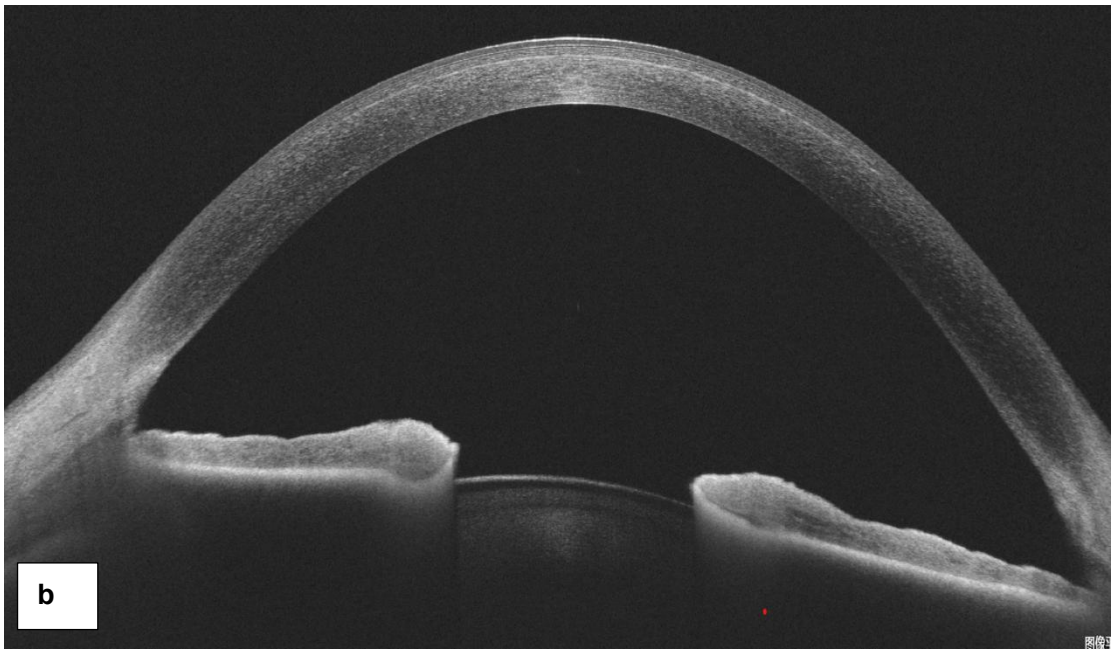

Fig 3. AS-OCT obtained on postoperative day 3 showing hyperreflective changes in the corneal stromal inteface of both eyes. Panel a shows the rigt eye; panel b shows the left eye.

On postoperative day 4, bilateral corneal clarity improved markedly (Fig. 4). His UDVA remained 20/20, and the interface opacities had largely resolved. We continued topical anti-inflammatory therapy and reviewed the patient one week later.

1

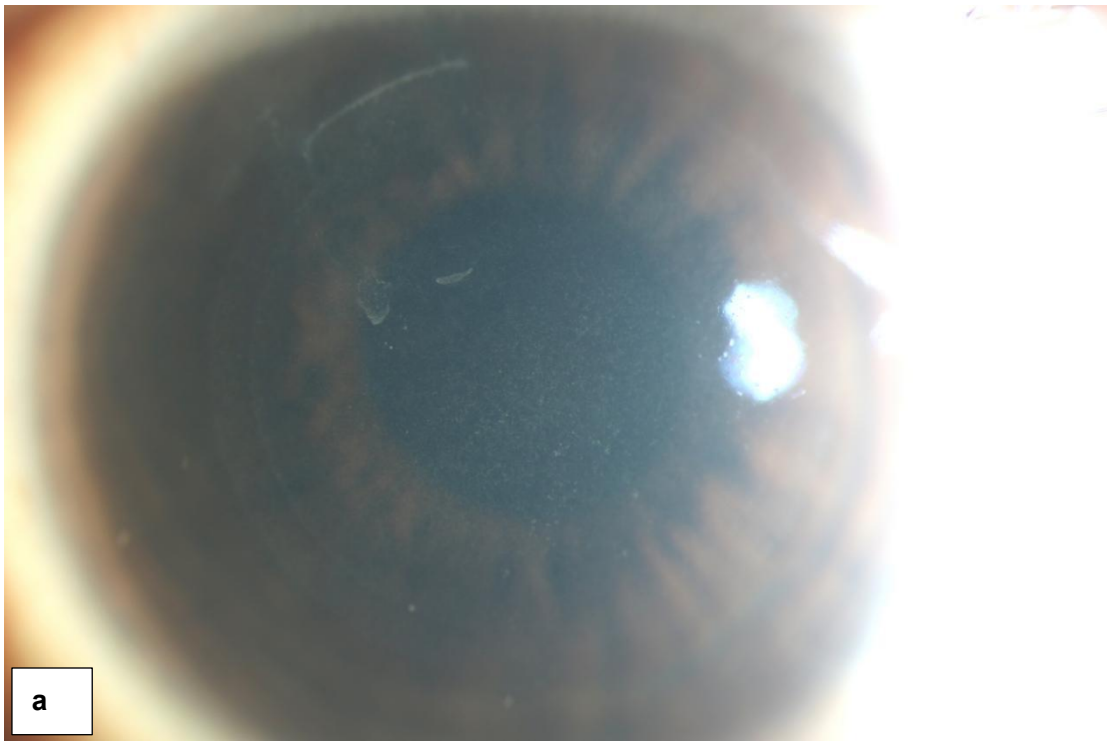

2

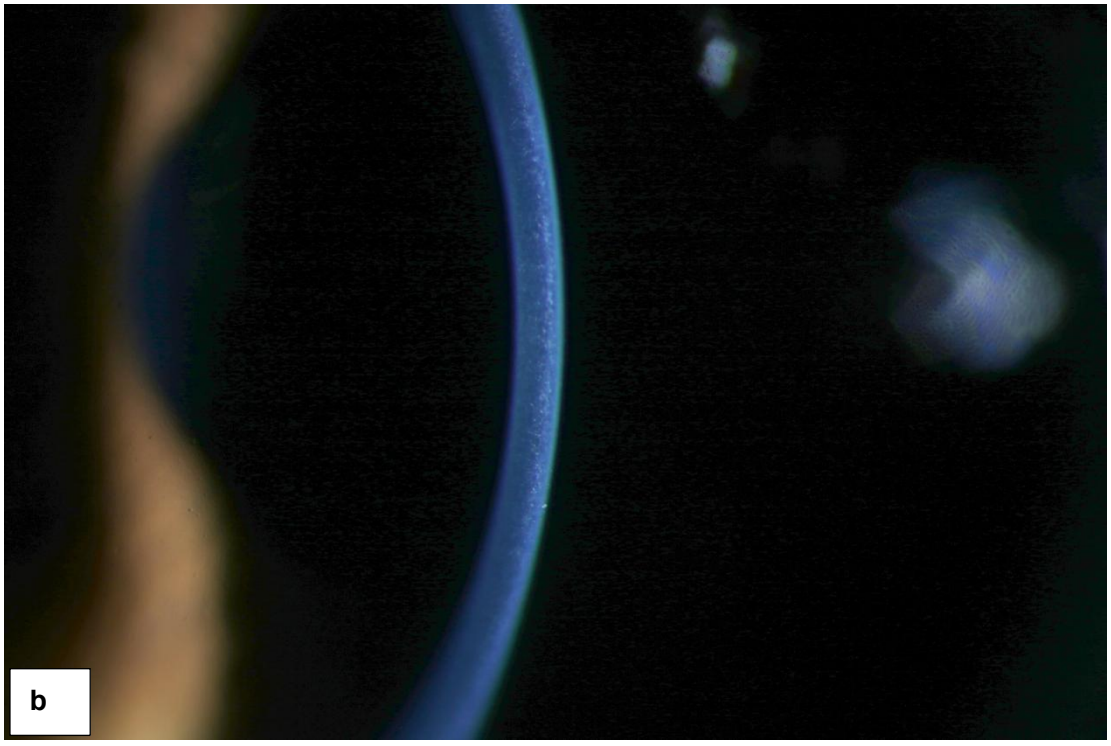

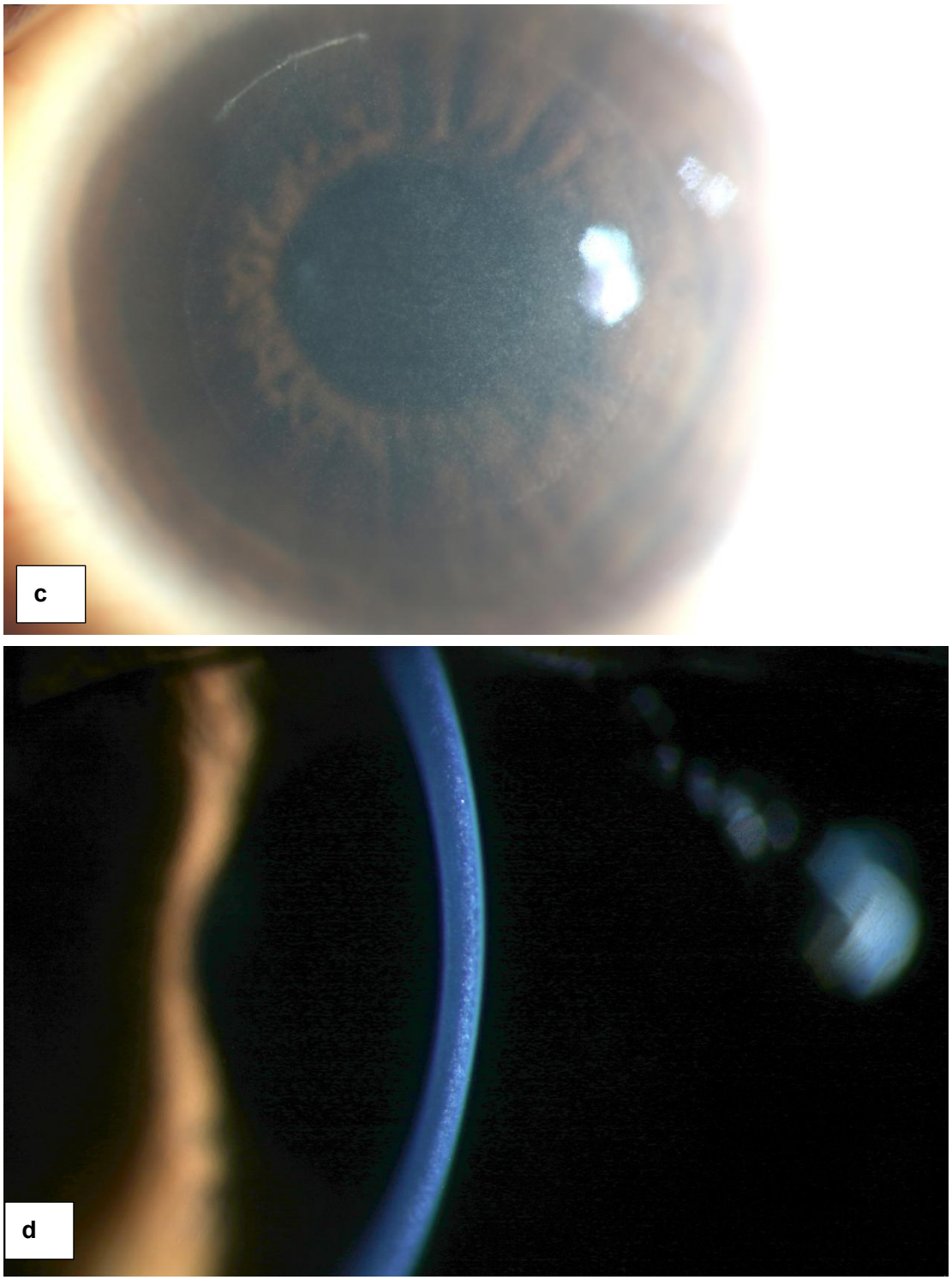

Fig 4. The slit-lamp images obtained after bilateral corneal interface irrigation showing markd improvement in corneal clarity in both eyes. Panels a and b show the right eye; panels c and d show the left eye.

On postoperative day 13, he remained asymptomatic with stable, clear vision bilaterally. The UDVA was 20/16 in both eyes. Slit-lamp examination showed clear corneas without residual interface inflammation. Topical corticosteroids were tapered over the following four weeks.

At the 1-month postoperative follow-up, the patient remained asymptomatic without any long-term complications. The UDVA was 20/16 in both eyes. Autorefraction showed +0.25 D in the right eye and +0.50 D in the left eye. Both corneas remained clear (Fig. 5).

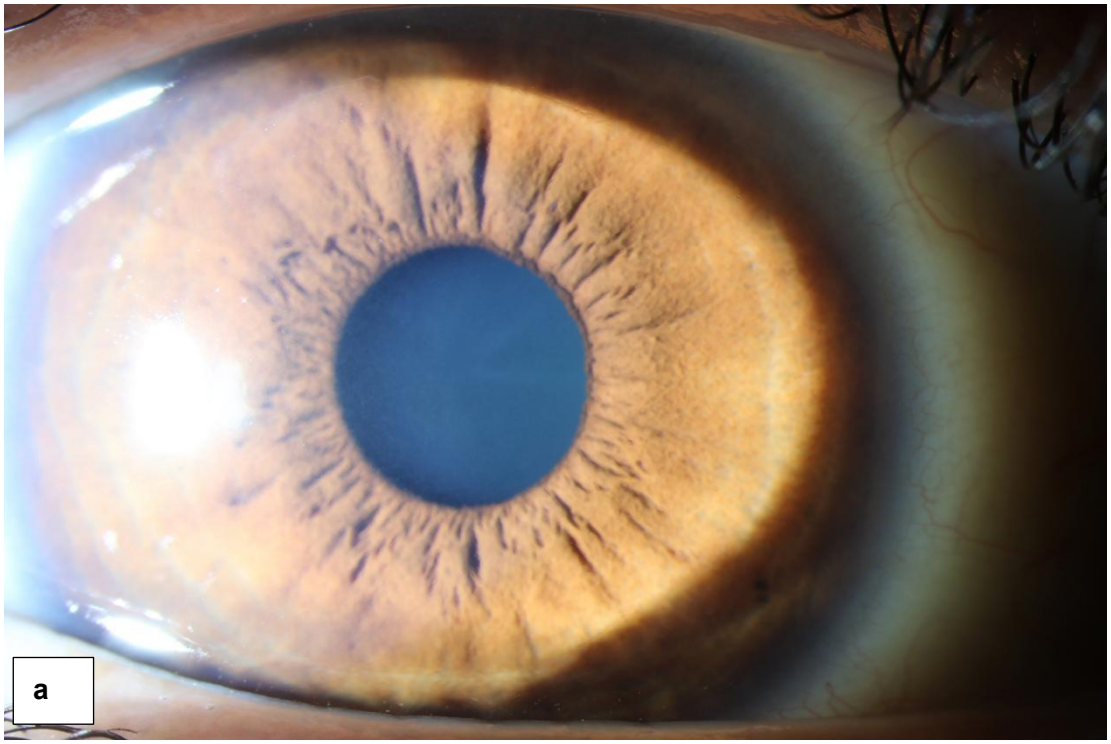

1

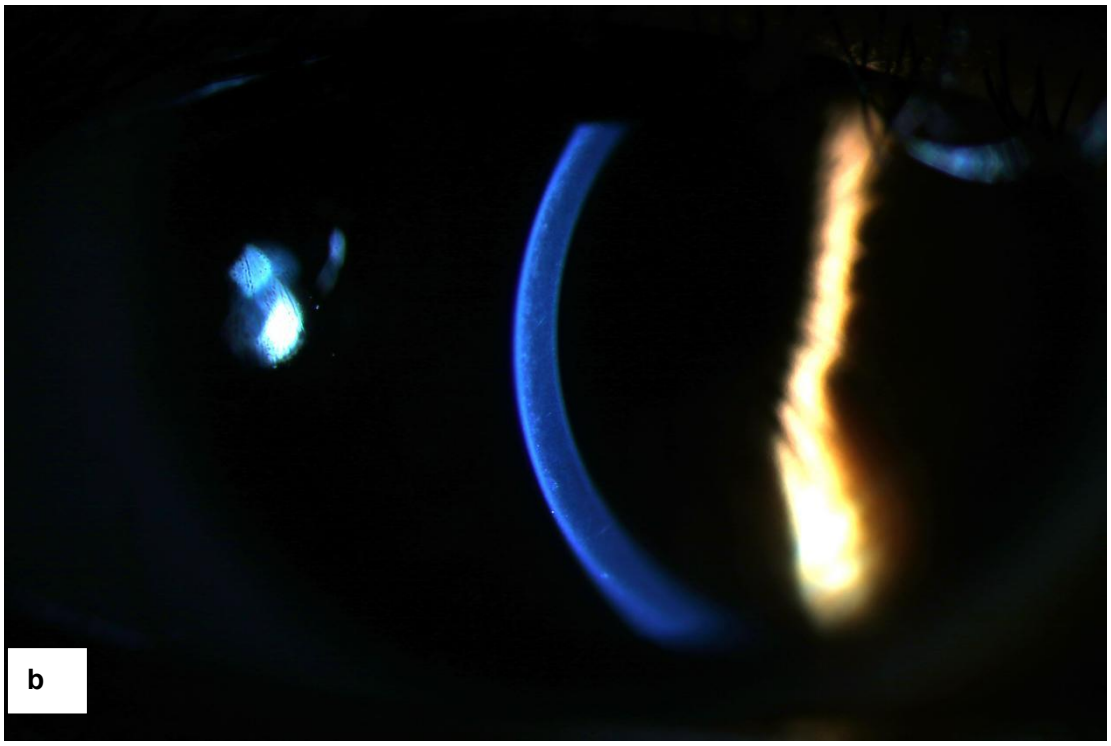

2



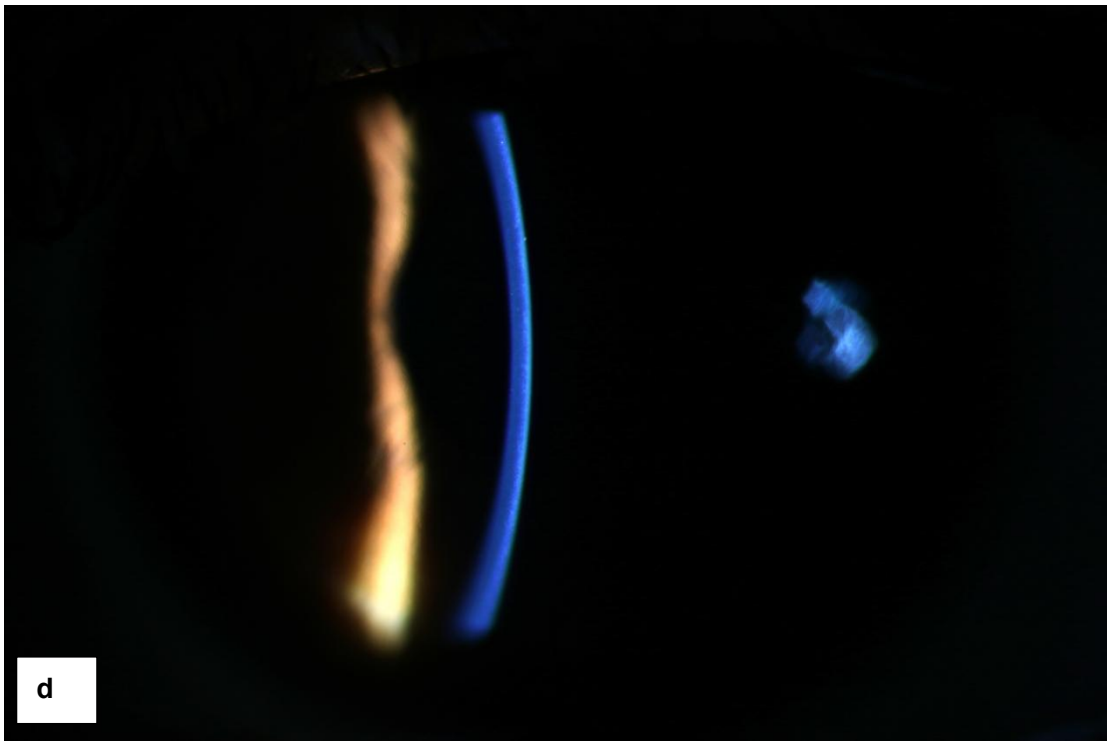

Fig 5. At the 1-month postoperative follow-up, slit-lamp images showed marked improvement in corneal clarity in both eyes. Panels a and b show the right eye; panels c and d show the left eye.

The patient remained stable during the subsequent 1-year follow-up, with sustained UDVA of 20/16 in both eyes and no recurrence of interface opacities. No elevation of IOP was recorded from postoperative day 1 onwards at all follow-up visits.

Discussion and conclusions

Bilateral synchronous involvement in DLK has been well recognised in the literature, although disease severity is frequently asymmetric, with most cases being grade I or II[3,7]; even grade III or IV cases are more frequently unilateral[3,8,9]. Bilateral cases have, in almost all instances, been associated with an identifiable trigger: eyelash extension removal[10], Cogan syndrome[11], meibomian gland dysfunction[12], permanent eyeliner tattoo[13], prior selective laser trabeculoplasty[14], viral

keratoconjunctivitis[15], or titanium eye shields[16] , and all have followed LASIK rather than SMILE. However, our patient had no preoperative ocular surface abnormality and no systemic condition predisposing to interface inflammation. The present case is therefore distinct in four respects: bilaterality, simultaneity, symmetric grade III severity, and the absence of any identifiable trigger after SMILE.

In this case, a critical diagnostic consideration was the distinction between DLK and infectious keratitis after SMILE. Based on previously described clinical criteria for distinguishing DLK from infectious keratitis[1], several findings in this case favored a diagnosis of DLK:(1) the lesions were strictly confined to the corneal interface; (2) the inflammatory changes were diffuse and involved a broad area of the corneal interface; (3) multiple small and relatively superficial infiltrates were observed; (4) there was no anterior chamber inflammatory reaction; (5) the corneal epithelium remained intact; (6) there was no significant conjunctival hyperemia. Therefore, these features favored a diagnosis of sterile inflammatory DLK rather than infectious keratitis.

Interface fluid syndrome (IFS) was also an important differential consideration. We excluded this diagnosis for three reasons[17]. IOP remained within normal limits at all visits, even during corticosteroid therapy. AS-OCT showed a hyperreflective interface band, with no optically empty space or fluid cleft beneath the cap. Most importantly, the opacities resolved rapidly after irrigation while topical corticosteroids were maintained at the same frequency; in IFS, ongoing steroid exposure typically leads to worsening rather than improvement.

Early, careful clinical evaluation and a structured management strategy are critical for optimizing outcomes in DLK. Most clinicians recognize that mild DLK can be successfully managed with intensive topical corticosteroids alone. Nevertheless, interface irrigation should be considered for severe cases or those demonstrating an inadequate response to corticosteroids. Multiple studies advocate early interface irrigation, preferably within postoperative days 2–3, to interrupt inflammatory progression and reduce the risk of stromal melting and permanent corneal scarring[6]. On the other hand, isolated reports indicate that even severe DLK may resolve with corticosteroid therapy alone without surgical intervention[8]. In the present case, bilateral grade III DLK was identified on postoperative day 1, and intensive topical corticosteroid therapy was initiated immediately. After 48 hours of treatment with no meaningful improvement, bilateral interface irrigation was performed on postoperative day 3. Corneal clarity improved rapidly after irrigation. This clinical course suggests that interface irrigation serves as an effective adjunctive treatment for severe DLK when the response to corticosteroid therapy remains suboptimal.

The material obtained during irrigation in this case was abundant and mucus-like bilaterally, with biochemical testing demonstrating predominantly proteinaceous content. This bilateral symmetrical pattern renders a focal surgical contaminant less plausible and points toward an endogenous patient-related predisposition. We hypothesise that altered tear or meibomian proteins could gain access to the interface during lenticule creation, though this remains speculative, as we did not perform meibomian gland evaluation or proteomic analysis.

Simultaneous bilateral grade III diffuse lamellar keratitis following SMILE represents an exceptionally rare postoperative complication. Prompt recognition, precise diagnosis and timely intervention are key to favourable clinical outcomes. While intensive topical corticosteroid therapy remains the cornerstone of management for grade III DLK, interface irrigation ought to be considered if inflammation shows inadequate improvement with medical treatment alone. Our case highlights the value of close postoperative monitoring and tailored management for severe DLK after SMILE.

Abbreviations

DLK: bilateral grade III diffuse lamellar keratitis; SMILE: small-incision lenticule extraction; LASIK: laser-assisted in situ keratomileusis; CDVA: corrected distance visual acuity; IOP: Intraocular pressuer; UDVA: uncorrected distance visual acuity; AS-OCT: Anterior segment optical coherence tomography

Declarations

Ethics approval and consent to participate

This case study was approved by the Ethics of Committee of The People's Hospital of Leshan.

Consent for publication

Written informed consent was obtained from the patient for publication of this case report and accompanying images.

Competing interests

The authors declare no competing interests.

Funding: This study was funded by Science and Technology Project of Leshan (NO. 23SZD013).

Author contributions

W.W. wrote the manuscript text, submitted to BMC; Z.J. evaluated the patient, provided surgical treatment, performed postoperative follow-up examinations; H. B. examined the patient and revised the manuscript and H. Y. performed postoperative follow-up examinations and assisted in making the diagnosis. All authors reviewed the manuscript.

Acknowledgments

None.

Availability of data and materials

No datasets were generated or analysed during the current study.

REFERENCES

1. Smith RJ, Maloney RK. Diffuse lamellar keratitis. A new syndrome in lamellar refractive surgery. Ophthalmology. 1998;105(9):1721–1726. doi:10.1016/S0161-6420(98)99044-3

2. Shah R, Shah S, Sengupta S. Results of small incision lenticule extraction: All-in-one femtosecond laser refractive surgery. J Cataract Refract Surg. 2011;37(1):127–137. doi:10.1016/j.jcrs.2010.07.033

3. Zhao J, He L, Yao P, et al. Diffuse lamellar keratitis after small-incision lenticule extraction. J Cataract Refract Surg. 2015;41(2):400–407. doi:10.1016/j.jcrs.2014.05.041

4. Yuan M, Ji R, Zhang R. A case of severe diffuse lamellar keratitis after small-incision lenticule extraction operation. Indian J Ophthalmol. 2024;72(8):1219–1223. doi:10.4103/IJO.IJO_2974_23

5. Fu G, Pan J, Yu H, Yang W, Wu Z. Delayed-onset diffuse lamellar keratitis due to retained SMILE lenticule: A case report and literature review. Medicine (Baltimore). 2025;104(16):e42095. doi:10.1097/MD.0000000000042095

6. Linebarger EJ, Hardten DR, Lindstrom RL. Diffuse lamellar keratitis: diagnosis and management. J Cataract Refract Surg. 2000;26(7):1072–1077. doi:10.1016/s0886-3350(00)00468-5

7. McLeod SD, Tham VM, Phan ST, Hwang DG, Rizen M, Abbott RL. Bilateral diffuse lamellar keratitis following bilateral simultaneous versus sequential laser in situ keratomileusis. Br J Ophthalmol. 2003;87(9):1086–7. doi:10.1136/bjo.87.9.1086.

8. Jarade E, Slim E, Antoun J, Khzam RA. Treatment of grade IV diffuse lamellar keratitis with oral doxycycline and topical 10% sodium citrate. Can J Ophthalmol. 2016;51(6):e178–e184. doi:10.1016/j.jcjo.2016.07.004

9. Li M, Yang D, Chen Y, Li M, Han T, Zhou X, et al. Late-onset diffuse lamellar keratitis 4 years after femtosecond laser-assisted small incision lenticule extraction: a case report. BMC Ophthalmol. 2017;17(1):244. doi:10.1186/s12886-017-0641-x.

10.Moshirfar M, Masud M, Shah TJ, Avila MR, Hoopes PC Sr. Chemical conjunctivitis and diffuse lamellar keratitis after removal of eyelash extensions. Am J Ophthalmol Case Rep. 2018;12:21–23. doi:10.1016/j.ajoc.2018.07.007.

11.Javaloy J, Barrera C, Muñoz G, Pérez-Santonja JJ, Vidal MT, Alió JL.

Spontaneous bilateral, recurrent, late-onset diffuse lamellar keratitis after LASIK in a patient with Cogan's syndrome. J Refract Surg. 2008;24(5):548–50. doi:10.3928/1081597X-20080501-16.

12. Ambrósio R Jr, Periman LM, Netto MV, Wilson SE. Bilateral marginal sterile infiltrates and diffuse lamellar keratitis after laser in situ keratomileusis. J Refract Surg. 2003;19(2):154–8. doi:10.3928/1081-597X-20030301-11.

13. Lu CW, Liu XF, Zhou DD, Kong YJ, Qi XF, Liu TT, et al. Bilateral diffuse lamellar keratitis triggered by permanent eyeliner tattoo treatment: A case report. Exp Ther Med. 2017;14(1):283–285. doi:10.3892/etm.2017.4506.

14. Holz H, Pirouzian A. Bilateral diffuse lamellar keratitis following consecutive selective laser trabeculoplasty in LASIK patient. J Cataract Refract Surg. 2010 May;36(5):847-9. doi: 10.1016/j.jcrs.2009.11.024. PMID: 20457380.

15. Gris O, Güell JL, Wolley-Dod C, Adán A. Diffuse lamellar keratitis and corneal edema associated with viral keratoconjunctivitis 2 years after laser in situ keratomileusis. J Cataract Refract Surg. 2004;30(6):1366–70. doi:10.1016/j.jcrs.2003.11.033.

16. Litzinger TC, Vastine D. Bilateral corneal opacities in a LASIK patient after the use of titanium eye shields. J Cataract Refract Surg. 2011;37(6):1160–4. doi:10.1016/j.jcrs.2011.03.027.

17. LoBue S, Coleman K, Lam P, Shelby C, Coleman WT. Interface Fluid Syndrome Masquerading as Diffuse Lamellar Keratitis After Small Incision Lenticule Extraction. Cureus. 2023;15(3):e36832. doi:10.7759/cureus.36832.

1

2