Research Square

Preprints are preliminary reports that have not undergone peer review.
They should not be considered conclusive, used to inform clinical practice,
or referenced by the media as validated information.

Sleeve Gastrectomy and the breakdown of the gastric barrier: a potential link to Invasive Listeriosis

Ambrogio Curtolo
National Institute for Infectious Diseases 'Lazzaro Spallanzani' -IRCCS
Alessandra D'Abramo
National Institute for Infectious Diseases 'Lazzaro Spallanzani' -IRCCS
Erica Binetti
erica.binetti@inmi.it
National Institute for Infectious Diseases 'Lazzaro Spallanzani' -IRCCS
Andrea Mariano
National Institute for Infectious Diseases 'Lazzaro Spallanzani' -IRCCS
Angela Corpolongo
National Institute for Infectious Diseases 'Lazzaro Spallanzani' -IRCCS
Rosario Alessandro Cavasio
National Institute for Infectious Diseases 'Lazzaro Spallanzani' -IRCCS
Silvia D'Arezzo
National Institute for Infectious Diseases 'Lazzaro Spallanzani' -IRCCS
Antonella Vulcano
National Institute for Infectious Diseases 'Lazzaro Spallanzani' -IRCCS
Emanuele Nicastri
National Institute for Infectious Diseases 'Lazzaro Spallanzani' -IRCCS

Case Report

Keywords: meningitis, invasive listeriosis, Listeria monocytogenes, sleeve gastrectomy, bariatric surgery

Posted Date: November 27th, 2026

DOI: https://doi.org/10.21203/rs.3.rs-11625715/v1

License: This work is licensed under a Creative Commons Attribution 4.0 International License. Read Full License

Additional Declarations: No competing interests reported.

Abstract

Background

Listeriosis is a severe foodborne infection caused by the Gram-positive bacterium *Listeria monocytogenes*, characterized by a high mortality rate among specific groups, including individuals at the extremes of age, pregnant women, and immunocompromised patients. The bacterium can survive the acidic environment of the stomach and the bactericidal effects of bile salts, cross the intestinal barrier and cause invasive listeriosis (sepsis and/or meningitis).

The stomach acts as a barrier against foodborne pathogens, by lowering gastric pH, producing pepsin and by mixing its contents. Sleeve gastrectomy (SG) causes anatomical and physiological changes, resulting in a reduced gastric acid production and accelerated gastric transit.

Cases Presentation

We report two cases of *Listeria monocytogenes* meningitis in immunocompetent women without conventional risk factors for invasive listeriosis but with a history of sleeve gastrectomy. Both presented with acute bacterial meningitis and were successfully treated with intravenous ampicillin for 21 days, with clinical and neurological recovery.

Conclusions

These cases suggest that the anatomical and physiological changes induced by SG may create a fast-track to facilitate the entry of intestinal pathogens. Although the current literature lacks studies directly associating SG with *L. monocytogenes* infections, gastric acid suppression is recognized as an independent risk factor for listeriosis. Moreover, SG induces profound and persistent alterations in the gut microbiota. Interestingly, obesity is associated with a reduced abundance of *Akkermansia muciniphila*, which has been shown to protect against *L. monocytogenes* infection in animal models. Although its abundance increases after SG, this is not associated with improved metabolic health, suggesting persistent microbiota alterations.

Although further studies are needed, our cases raise the hypothesis that SG may represent a previously underrecognized risk factor for listeriosis. This potential association could have implications for clinical risk assessment and empirical therapeutic decision-making, particularly in severe infections such as *L. monocytogenes* meningitis.

Background

Listeriosis is a severe foodborne infection caused by the Gram-positive bacterium Listeria monocytogenes, traditionally characterized by high mortality rate among specific vulnerable groups, including extremes of age (newborns <1 or adults >65 years-old), pregnant women, and immunocompromised patients [1]. The pathogenesis of the infections relies on the capacity of the bacterium to survive the acidic environment of the stomach and the bactericidal effects of bile salts in the intestine before crossing the intestinal barrier

[1]. Once it has survived digestion in the stomach and exposure to bile acids, L. monocytogenes can cause intestinal infections and invasive listeriosis (sepsis and/or meningitis), which is associated with high case fatality rates [1]. The stomach acts as a barrier against pathogens ingested through food, not only by lowering the pH and producing enzymes such as pepsin, but also by mixing its contents through contractions [2]. This creates a semi-liquid mixture of food bolus, acid, and enzymes called chyme, which passes through the pylorus to continue the digestive process [3]. Sleeve gastrectomy (SG) is considered one of the best surgical options in the treatment of obesity, typically indicated in case of body mass index (BMI) ≥ 40 ore BMI ≥ 35 with obesity related comorbidities (e.g. type II diabetes, high blood pressure) [4, 5]. Moreover, it has shown better efficacy in terms of non-alcoholic steatohepatitis (NASH) when compared with lifestyle intervention and medical therapy [6] Recently, evidence has emerged suggesting that bariatric surgery may increase the risk of enteric infection [7]. Among the others, SG significantly reduces the gastric volume [8]. This anatomical modification leads to critical functional changes, most notably reduced gastric acid production and accelerated gastric transit time without forming the chyme [9]. While bariatric surgery is known to increase the risk of intra-abdominal and enteric infections, it is rarely considered a primary predisposing factor for listeriosis in otherwise healthy individuals [7]. This case series presents two cases of invasive L. monocytogenes infection in patients who had previously undergone SG and possessed no other traditional risk factors, highlighting the potential for this surgical history to serve as a significant predisposing condition for invasive listeriosis.

Cases presentation

Case 1

A 61-year-old woman was admitted to the “Lazzaro Spallanzani” National Institute for Infectious Diseases Rome, Italy, with a one-day history of high-grade fever and altered mental status. She had a medical history of hypertension, secondary hypercalcemia related to hyperparathyroidism, and bariatric surgery, specifically SG, performed approximately 18 months earlier (BMI <30 one year after SG). At presentation to the emergency department (ED), laboratory tests revealed altered inflammatory markers with white blood cell (WBC) count of 11500 cells/mm³, neutrophilic count (N) 8500 cells/mm³, C-reactive protein (CPR) of 8.4 mg/dl, procalcitonin (PCT) 0.8 ng/dl. Blood glucose was 80 mg/dl. Brain and chest computed tomography (CT) scans were unremarkable. Electroencephalography (EEG) showed an acute diffuse cerebral dysfunction, characterized by slowing of the background activity with brief sequences of high-voltage waves diffusely involving the entire cerebral cortex.

A lumbar puncture (LP) showed opaline cerebrospinal fluid (CSF) with glucose of 9 mg/dL, protein of 209 mg/dL, and WBC count of 460 cells/mm³, predominantly neutrophils. Empirical therapy with ceftriaxone (CTX) 2g in bolus infusion every 12 hours, ampicillin (AMP) 2g as loading dose (LD) than a continuous infusion (CI) of AMP 12g daily and dexamethasone (DEX) 6mg in bolus infusions every 6 hours was initiated. A multiplex **Polymerase Chain Reaction** (PCR) panel on CSF was positive for *L. monocytogenes*.

On day 2, the patient was admitted to our department. The general condition was extremely severe presenting with a drowsy level of consciousness, with episodes of psychomotor agitation. On physical

examination, nuchal rigidity was noted, without focal neurological deficits. Laboratory findings showed N 9500 cells/mm³, CRP 2.97 mg/dL, and PCT 3.57 ng/mL.

On day 3, CSF and blood cultures confirmed the growth of *L. monocytogenes* with a confirmed sensitivity to AMP.

On day 4, a brain magnetic resonance imaging (MRI) resulted unremarkable, with no areas of altered signal intensity in the brain parenchyma or abnormalities of the ventricular system. Consequently, CTX, VAN and DEX were stopped. The therapy was continued with a CI of AMP 12g daily, in combination with gentamicin (GEN) 3mg/kg in single bolus infusion daily for the first 10 days. We assist to a progressive improvement in mental status, general and clinical conditions, and laboratory parameters. Follow-up blood culture collected at day 4 were negative.

Treatment was discontinued on day 21 when the patient was discharged in good clinical condition, fully independent, and without residual neurological deficits

Case 2

A 43-year-old woman was admitted to our unit with a six-day history of low-grade fever, nausea, and headache. She had a history of hypertension and obesity, for which she had undergone SG three years earlier, with a subsequent weight loss of more than 40 kg (after the weight loss BMI <30). Five days after the onset of initial symptoms, she presented to the ED with high-grade fever, altered mental status, ataxia, and diplopia. Neurological examination demonstrated impaired ocular abduction of the left eye, consistent with sixth cranial nerve palsy. Initial laboratory tests showed neutrophilic leucocytosis (WBC 12500 cells/mm³ with N 10300 cells/mm³) and elevated inflammatory markers (CRP 9.4 mg/dl, PCT 1.2 ng/mL). Glucose in blood was 84 mg/dl. Brain CT scan was unremarkable. Lumbar puncture revealed turbid CSF, with a glucose level of 5 mg/dL, protein 207 mg/dL, and a WBC count of 1650 cells/mm³, predominantly neutrophils. Empirical therapy with CTX 2g in bolus infusion every 12 hours, vancomycin (VAN) 1g as LD and VAN 30mg/kg every 24 hours in CI and DEX 6mg in bolus infusions every 6 hours was initiated. A multiplex PCR panel performed on CSF tested positive for *L. monocytogenes. Consequently,* AMP 2g as LD than a CI of AMP 12g daily was immediately added to the treatment scheme.

On day 2, the patient was admitted to our department. The general conditions were severe; she was alert but exhibited reduced responsiveness and motor slowing. Physical examination revealed nuchal rigidity with persistent diplopia.

On day 3, antibiotic therapy was de-escalated to AMP monotherapy, and corticosteroids were discontinued.

On day 4, blood and CSF cultures confirmed the growth of *Listeria monocytogenes* susceptible to AMP. A brain MRI demonstrated subcentimetric T2-weighted hyperintense lesions in the white matter, consistent with nonspecific demyelination, predominantly involving the frontal lobes. Mild diffuse meningeal thickening and enhancement were also observed, without evidence of cerebritis.

The patient received intravenous AMP for a total of 21 days. During hospitalization a rapid clinical improvement was observed, with normalization of clinical and mental status, and progressive resolution of neurological signs and symptoms marked by the complete recovery of the left sixth cranial nerve palsy.

Treatment was discontinued on day 21, and the patient was discharged the following day in good clinical condition, fully independent, and without residual neurological deficits.

Characteristics and clinical timeline of the cases presented above are summarized in Table 1 and Table 2.

Case	Age	Sex	Comorbidities	SG	Diagnostic test	Empirical treatment	Definitive treatment	Outcome
Case 1	61 y/o	F	HTN, HPT	18 months before admission	Multiplex PCR panel and culture on CSF	CTX 2g q12h + AMP 2g LD than AMP 12g q24h in CI + DEX 6mg q6h	AMP 12g q24h in CI for 21 days + GEN 3mg/kg q24h for the first 10 days	Recovery
Case 2	43 y/o	F	HTN	36 months before admission	Multiplex PCR panel and culture on CSF	CTX 2g q12h + VAN 1g LD than VAN 30mg/kg in CI + DEX 6mg q6h	AMP 12g q24h in CI for 21 days	Recovery

Table 1. Clinical Characteristics, Diagnostic Findings, Treatment, and Outcomes

Legend: AMP: ampicillin; CI: continuous infusion; CSF: cerebrospinal fluid; CTX: ceftriaxone; DEX: dexamethasone; F: female; GEN: gentamycin; PCR: polymerase chain reaction; HPT: hyperparathyroidism; HTN: hypertension; LD: loading dose; SG: sleeve gastrectomy; VAN: vancomycin y/o: years/old.

Timeline	Case 1 (61-year-old woman)	Case 2 (43-year-old woman)
Previous medical history	Sleeve gastrectomy 18 months before admission; hypertension and hyperparathyroidism	Sleeve gastrectomy 36 months before admission; hypertension
Symptom onset	High-grade fever and altered mental status (1 day before admission)	Low-grade fever, nausea and headache (6 days before admission)
Day 1 – ED presentation	Altered mental status; elevated inflammatory markers; brain CT unremarkable; EEG showing diffuse cerebral dysfunction	High-grade fever, altered mental status, ataxia, diplopia and left sixth cranial nerve palsy; brain CT unremarkable
Day 1 – Diagnosis and initial treatment	CSF pleocytosis, hypoglycorrhachia and elevated proteins; multiplex PCR positive for L. monocytogenes. Empirical CTX, AMP and DEX initiated	CSF pleocytosis, hypoglycorrhachia and elevated proteins; multiplex PCR positive for L. monocytogenes. Empirical CTX, VAN and DEX initiated; AMP added following PCR results
Day 2	Admission to Infectious Diseases Unit; drowsiness, psychomotor agitation and nuchal rigidity	Admission to Infectious Diseases Unit; reduced responsiveness, motor slowing, nuchal rigidity and persistent diplopia
Day 3	Blood and CSF cultures positive for L. monocytogenes, susceptible to AMP	Antibiotic therapy de-escalated to AMP monotherapy; DEX discontinued
Day 4	Brain MRI unremarkable; CTX and DEX discontinued; AMP continued with GEN for 10 days; follow-up blood cultures negative	Blood and CSF cultures positive for L. monocytogenes, susceptible to AMP; brain MRI showing mild meningeal enhancement without cerebritis
During hospitalization	Progressive clinical and neurological improvement	Progressive clinical and neurological improvement, with complete resolution of sixth cranial nerve palsy
Day 21–22 – Outcome	AMP completed on day 21; discharged on the same day without residual neurological deficits	AMP completed on day 21; discharged on day 22 without residual neurological deficits

Table 2. Clinical timeline

Legend: AMP, ampicillin; CSF, cerebrospinal fluid; CT, computed tomography; CTX, ceftriaxone; DEX, dexamethasone; ED, emergency department; EEG, electroencephalography; GEN, gentamicin; MRI, magnetic resonance imaging; PCR, polymerase chain reaction; VAN, vancomycin.

Methods

A multiplex polymerase chain reaction (PCR) based assay (BioFire® FilmArray® Meningitis/Encephalitis, ME, Panel bioMérieux) was performed as rapid diagnostic test on CSF. This test detects: *Neisseria meningitidis, Streptococcus pneumoniae, Escherichia coli K1, Haemophilus influenzae, L. monocytogenes, Streptococcus agalactiae*, herpes simplex virus types 1 and 2, varicella zoster virus, cytomegalovirus, enterovirus, human parechovirus, human herpesvirus 6, and *Cryptococcus neoformans/gattii*.

To perform CSF culture, CSF sample was centrifuged at 3000 rpm for 10 minutes. After aseptic decanting of the supernatant, the sediment was vortexed, and a drop was used to inoculate chocolate and blood agar plates (Thermo Fisher Scientific, San Diego, CA, USA). Inoculated plates were incubated at 37°C in 5% CO2 until 5 days.

Blood culture was performed with BD BACTEC FX instrument (Becton, Dickinson). Microbe identification was performed using the MALDI-TOF Biotyper Sirius system (Bruker Daltonics, Bremen, Germany) with MBT Compass software (version 4.2). Antimicrobial susceptibility testing (AST) was performed manually using the agar diffusion method (gradient-test), in accordance with European Committee on Antimicrobial Susceptibility Testing (EUCAST) standards. L. monocytogenes was considered susceptible to AMP with a MIC < 1.0 µg/mL.

During the writing of this manuscript, Copilot (Microsoft 365 Copilot. 2.20260602.20.0) was used to enhance the quality of Fig. 1.

Discussion and Conclusions

The clinical cases presented highlight a potential critical association between SG and invasive listeriosis. Traditionally, *L. monocytogenes* primarily affects the extremes of age, pregnant women, and immunocompromised individuals [8]. However, both patients were immunocompetent and had no conventional risk factors, suggesting that the anatomical and physiological changes induced by bariatric surgery may create a sort of fast-track to facilitate the entry of intestinal pathogens.

A swallowed bolus is stored in the proximal stomach while liquids disperse rapidly; solids then redistribute to the distal stomach (antrum), where coordinated antral–pyloric activity mixes and triturates contents into chyme that exits through the pylorus [2]. Gastric acidity is an important antimicrobial gatekeeper that limits bacterial overgrowth in the upper GI tract, and reduced acidity (e.g., with acid suppression or after gastric surgery) is associated with increased bacterial growth [9].

Sleeve gastrectomy removes up to 80% of the gastric corpus, altering acid-secreting mucosa and pH regulation, and it accelerates gastric emptying and small-bowel transit [8, 10, 12]. This alteration of the acid-secreting mucosa disrupts long-term pH regulation, while simultaneously accelerating gastric emptying and small-bowel transit time [11]. Consequently, these physiological shifts promote intestinal bacterial overgrowth and elevate the incidence of intra-abdominal infections [7, 12].

Although the current literature lacks studies directly associating SG with *L. monocytogenes* infections, gastric acid suppression is recognized as an independent risk factor for listeriosis [13]. Therefore, it can be speculated that the anatomical and physiological sequelae of a SG increase the susceptibility to foodborne abdominal infections, including invasive listeriosis. It is noteworthy that, in Case2, current international guidelines for the empirical management of bacterial meningitis would not have included antimicrobial coverage against *L. monocytogenes*, given the absence of established risk factors for invasive listeriosis [8, 14].

Multiplex molecular CSF testing is readily available in referral hospitals and provides results within one hour after LP. However, in peripheral healthcare settings molecular diagnostic tools are not immediately accessible, which may delay the diagnosis of invasive listeriosis in patients without apparent risk factors.

Beyond acid and enzyme suppression, SG induces profound and persistent alterations in the gut microbiota [15]. Post-surgical microbial profiles are often characterized by increased facultative anaerobes from the upper gastrointestinal tract and may fail to restore the preoperative microbiota composition [16].

Interestingly, individuals with obesity often exhibit a lower abundance of *Akkermansia muciniphila*, a commensal species that has been shown in animal models to enhance colonization resistance and reduce susceptibility to *L. monocytogenes* infection [17]. Although levels of *A. muciniphila* increase in individuals with a BMI < 30 following SG, they are not associated with an improvement in metabolic health [18]. Therefore, it is possible that post-SG alterations in the gut microbiota may predispose individuals to *L. monocytogenes* infection (Figure 1).

Figure 1. Schematic illustration of the pathophysiological changes in the gastric environment following sleeve gastrectomy, highlighting altered gastric acid secretion, reduced pepsin production, disruption of coordinated gastric contraction, accelerated emptying, and changes in the gut microbiota.

To the best of our knowledge, these are the first two case suggesting a correlation between invasive listeriosis and SG. As bariatric surgery remains a cornerstone for obesity and metabolic disease, clinicians should be aware of the potential long-term infectious consequences associated with the anatomical and physiological changes induced by these procedures.

Although further studies are needed, our cases raise the hypothesis that SG may represent a previously underrecognized risk factor for listeriosis. This potential association could have implications for clinical risk assessment and empirical therapeutic decision-making, particularly in severe infections such as *L. monocytogenes* meningitis.

Declarations

Notes

Author contributions

Conceptualization: AC, ADA, EB. Writing – Original Draft Preparation: AC, ADA, EB. Review & Editing: ADA, AC, EN. Investigation: AM, AC, RAC, SDA, AV. Supervision: ADA, AC, EB, EN. Funding acquisition: EN. All authors have read and approved the final manuscript.

Acknowledgements

We thank the healthcare workers at INMI Lazzaro Spallanzani for their collaboration in this case.

Data availability statement

Data are available to request from the Corresponding Author.

Declaration of generative AI and AI-assisted technologies in the manuscript preparation process

During the preparation of this manuscript, the authors used Copilot (Microsoft 365 Copilot. 2.20260602.20.0) to enhance the quality of Figure 1. After using this tool, the authors reviewed and edited the content as needed and take full responsibility for the content of the published article.

Financial support

This work was supported by fund allocated to the National Institute for Infectious Diseases “Lazzaro Spallanzani”, IRCCS, Rome, Italy, from the Italian Ministry of Health (Project P3, Line 1: Tropical and Neglected Infectious Diseases—Pathogenetic, Immunological and Diagnostic Aspects, 2025–2027).

Ethical approval

Ethics approval and consent to participate Not applicable.

Consent for publication

Patient gave written informed consent for their personal or clinical details along with any identifying images to be published in this study.

Potential conflict of interest

The authors declare no conflict of interest.

References

1. Disson O, Charlier C, Pérot P, Leclercq A, Paz RN, Kathariou S, Tsai YH, Lecuit M. Listeriosis. Nat Rev Dis Primers. 2025 Oct 2;11(1):71. doi: 10.1038/s41572-025-00654-x. PMID: 41038831.
2. Sensoy I. A review on the food digestion in the digestive tract and the used *in vitro* models. *Curr Res Food Sci*. 2021;4:308-319. Published 2021 Apr 14. doi:10.1016/j.crfs.2021.04.004
3. Hunt RH, Camilleri M, Crowe SE, et al. The stomach in health and disease. *Gut*. 2015;64(10):1650-1668. doi:10.1136/gutjnl-2014-307595
4. Salminen P, Grönroos S, Helmiö M, et al. Effect of Laparoscopic Sleeve Gastrectomy vs Roux-en-Y Gastric Bypass on Weight Loss, Comorbidities, and Reflux at 10 Years in Adult Patients With Obesity: The SLEEVEPASS Randomized Clinical Trial. *JAMA Surg*. 2022;157(8):656-666. doi:10.1001/jamasurg.2022.2229
5. Robert M, Poghosyan T, Romain-Scelle N, et al. Efficacy and safety of single-anastomosis duodeno-ileal bypass with sleeve gastrectomy versus Roux-en-Y gastric bypass in France (SADISLEEVE): results of a randomised, open-label, superiority trial at 2 years of follow-up. *Lancet*. 2025;406(10505):846-859. doi:10.1016/S0140-6736(25)01070-0

6. Verrastro O, Panunzi S, Castagneto-Gissey L, et al. Bariatric-metabolic surgery versus lifestyle intervention plus best medical care in non-alcoholic steatohepatitis (BRAVES): a multicentre, open-label, randomised trial. *Lancet*. 2023;401(10390):1786-1797. doi:10.1016/S0140-6736(23)00634-7
7. Goto T, Hirayama A, Faridi MK, Camargo CA Jr, Hasegawa K. Association of Bariatric Surgery With Risk of Infectious Diseases: A Self-Controlled Case Series Analysis. *Clin Infect Dis*. 2017;65(8):1349-1355. doi:10.1093/cid/cix541
8. Elad A, Moalem B, Sender D, et al. Sleeve gastrectomy reveals the plasticity of the human gastric epithelium. *Nat Commun*. 2025;16(1):869. Published 2025 Jan 20. doi:10.1038/s41467-025-56135-y
9. Melissas J, Leventi A, Klinaki I, et al. Alterations of global gastrointestinal motility after sleeve gastrectomy: a prospective study. *Ann Surg*. 2013;258(6):976-982. doi:10.1097/SLA.0b013e3182774522
10. Rosen R, Amirault J, Liu H, et al. Changes in gastric and lung microflora with acid suppression: acid suppression and bacterial growth. *JAMA Pediatr*. 2014;168(10):932-937. doi:10.1001/jamapediatrics.2014.696
11. Van de Beek D, Cabellos C, Dzupova O, et al. ESCMID guideline: diagnosis and treatment of acute bacterial meningitis. *Clin Microbiol Infect*. 2016;22 Suppl 3:S37-S62. doi:10.1016/j.cmi.2016.01.007
12. Pimentel M, Saad RJ, Long MD, Rao SSC. ACG Clinical Guideline: Small Intestinal Bacterial Overgrowth. *Am J Gastroenterol*. 2020;115(2):165-178. doi:10.14309/ajg.0000000000000501
13. Dalton CB, Merritt TD, Unicomb LE, Kirk MD, Stafford RJ, Lalor K. A national case-contro study of rish factors of listeriosis in Australia. Epidemiology and Infection. 2011; 139(3):437-445. doi:10.1017/S0950268810000944
14. Hasbun R. Progress and Challenges in Bacterial Meningitis: A Review. *JAMA*. 2022;328(21):2147-2154. doi:10.1001/jama.2022.20521
15. Morales-Marroquin E, Hanson B, Greathouse L, de la Cruz-Munoz N, Messiah SE. Comparison of methodological approaches to human gut microbiota changes in response to metabolic and bariatric surgery: A systematic review. *Obes Rev*. 2020;21(8):e13025. doi:10.1111/obr.13025
16. Akagbosu CO, McCauley KE, Namasivayam S, et al. Gut microbiome shifts in adolescents after sleeve gastrectomy with increased oral-associated taxa and pro-inflammatory potential. *Gut Microbes*. 2025;17(1):2467833. doi:10.1080/19490976.2025.2467833
17. Keane JM, Cazzaniga M, Gahan CGM. *Akkermansia muciniphila* in infectious disease: A new target for this next-generation probiotic?. *Sci Prog*. 2024;107(1):368504241231159. doi:10.1177/00368504241231159
18. Dao MC, Belda E, Prifti E, et al. *Akkermansia muciniphila* abundance is lower in severe obesity, but its increased level after bariatric surgery is not associated with metabolic health improvement. *Am J Physiol Endocrinol Metab*. 2019;317(3):E446-E459. doi:10.1152/ajpendo.00140.2019

Figures

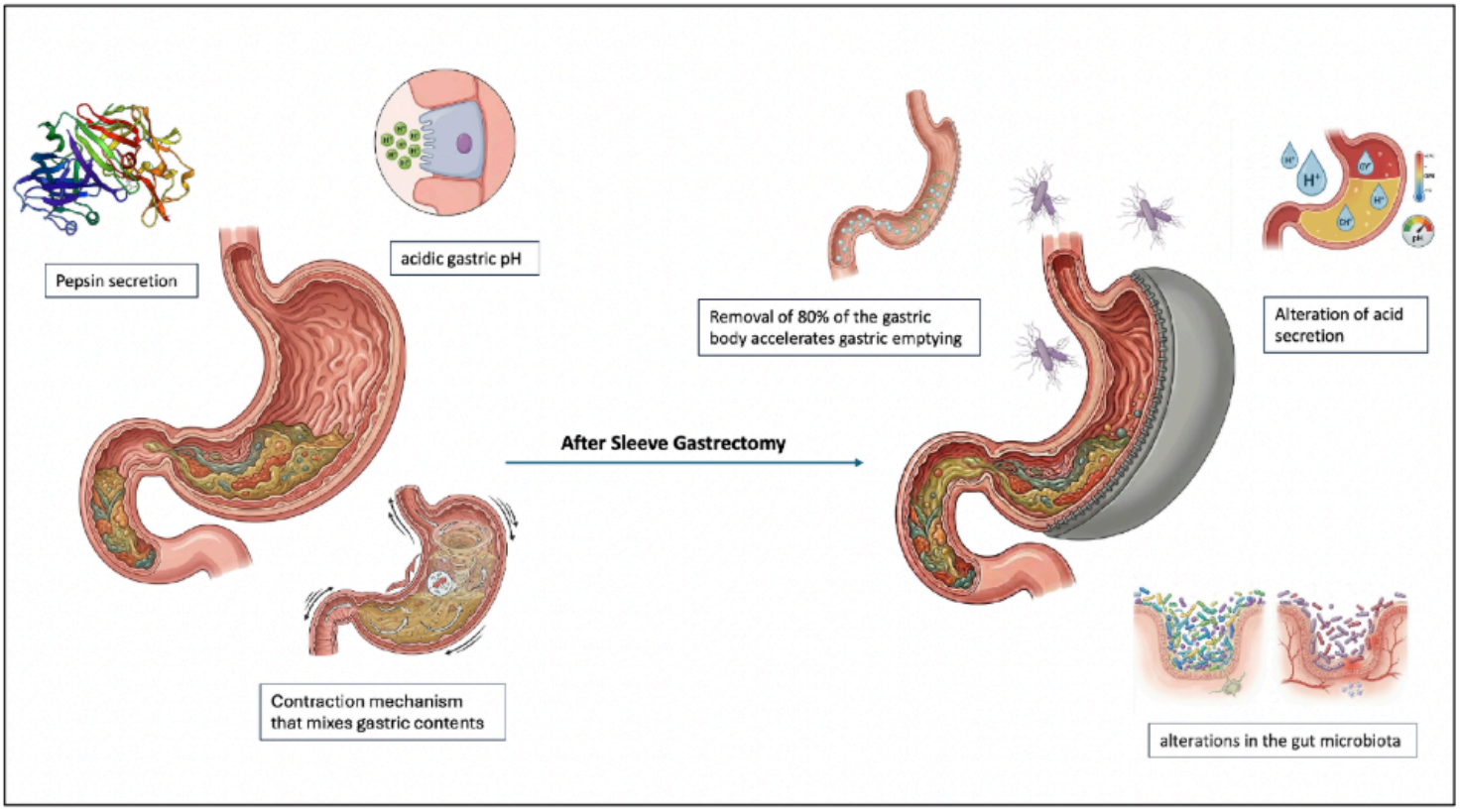

Figure 1

Schematic illustration of the pathophysiological changes in the gastric environment following sleeve gastrectomy, highlighting altered gastric acid secretion, reduced pepsin production, disruption of coordinated gastric contraction, accelerated emptying, and changes in the gut microbiota.